

ULTRASTRUCTURAL STUDY OF REMYELINATION IN AN EXPERIMENTAL LESION IN ADULT CAT SPINAL CORD

MARY BARTLETT BUNGE, Ph.D., RICHARD P. BUNGE, M.D., and
HANS RIS, Ph.D.

From the Department of Zoology and the Department of Anatomy, the Medical School, University of Wisconsin, Madison. Dr. Mary Bunge and Dr. Richard Bunge are now in the Department of Anatomy and Laboratory for Cell Physiology, Columbia University College of Physicians and Surgeons, New York

ABSTRACT

This report presents ultrastructural observations on the cytological events that attend myelin formation occurring in the wake of demyelination in adult cat spinal cord. Lesions were induced in subpial cord by cerebrospinal fluid (c.s.f.) exchange (1, 2). Tissue from eleven cats at nine intervals from 19 to 460 days was fixed *in situ* by replacing c.s.f. with buffered OsO₄ and embedded in Araldite. After demyelination, axons are embraced by sheet-like glial processes. An occasional myelin sheath is first seen at 19 days; by 64 days, all axons are at least thinly myelinated. The cytoplasm of the myelin-forming cells, unlike that of either oligodendrocyte or fibrous astrocyte in normal cord, is dense with closely packed organelles and fine fibrils. Many of the myelinogenic cells become scarring astrocytes and at 460 days the lesion teems with their fibril-filled processes. Oligodendrocytes appear in the lesion after remyelination is under way. Phagocytes disappear gradually. A myelin sheath is formed by spiral wrapping of a sheet-like glial process around an axon. Where the first turn of the spiral is completed, a mesaxon is formed. As cytoplasm is lost from the process, the plasma membrane comes together along its outer and cytoplasmic surfaces to form compact myelin. Only a small amount of cytoplasm is retained; it is confined to the paramesaxonal region and, on the sheath exterior, to a longitudinal ridge which appears in profile as a small loop. This outer loop has the same rotational orientation as the inner mesaxon. These vestiges of spiral membrane wrapping are also found in normal adult and new-born cat cord. Nodes are present in all stages of remyelination and in normal adult cat and kitten cord. These observations suggest that myelin is reformed in the lesion in the same way it is first formed during normal development. The mechanism of myelin formation is basically similar to that proposed for peripheral nerve and amphibian and mammalian optic nerve; it does not agree with present views on the mechanism of myelinogenesis in mammalian brain and cord. This is the first demonstration of remyelination in adult mammalian central nervous tissue.

INTRODUCTION

Loss of myelin ensheathing the axons coursing through subpial white matter of adult cat spinal cord may be induced by repeated withdrawal and reinjection of cerebrospinal fluid (2). Although these axons are completely divested of myelin sheaths, the ultrastructural appearance of their constituent neurofibrils and mitochondria does not change. No histological evidence of axo-

nal degeneration above or below the lesion is observed. These observations indicate that the demyelinated axons remain intact. Thus, by simple manipulation of cerebrospinal fluid, a limited demyelinating lesion may be produced in the adult central nervous system and studied at selected intervals.

This lesion provides an opportunity for evaluating the suggestion that new myelin may be formed in demyelinated areas of nervous tissue (3). This suggestion has never been substantiated largely because suitable experimental demyelinating lesions were lacking. Study of the cerebrospinal fluid exchange lesion by light microscopy indicated that myelin reappears at a time when the animals show neurological improvement from their initial partial paralysis (4, 5). That myelin can be reformed around demyelinated nerve fibers in adult mammalian spinal cord will be demonstrated in this electron microscopic report.

The lesion also permits study of the mechanism by which myelin is reformed. Presently there are diverse opinions regarding the mechanism of first myelin formation in central nervous tissue.

In the earliest ultrastructural study, Luse (6, 7) concluded that in mammals a sheath is formed from a number of glial processes. These processes flatten, their plasma membranes become apposed, and, as they join circumferentially and radially, myelin is formed. This view is shared by Ross, Bornstein, and Lehrer who have studied myelinating cultures prepared from new-born rat cerebellum (8). De Robertis, Gerschenfeld, and Wald (9) proposed quite a different mechanism for myelinogenesis in mammalian spinal cord. Each axon becomes embedded in glial cytoplasm and, within this cytoplasm, vesicles and membranes line up around the axon and flatten and fuse together. This scheme implies that myelin derives from membranous segments synthesized within glial cytoplasm. A third possibility has arisen from researches on amphibian optic nerve by Maturana (10) and Peters (11) and, more recently, on mammalian optic nerve by Peters (12). Their findings suggest that central myelin may be formed by spiral wrapping of a glial cell process and convergence of the plasma membrane into compact myelin as cytoplasm is

Explanation of Scale Marks

Each bar, unless otherwise designated, indicates 1 micron.

FIGURE 1

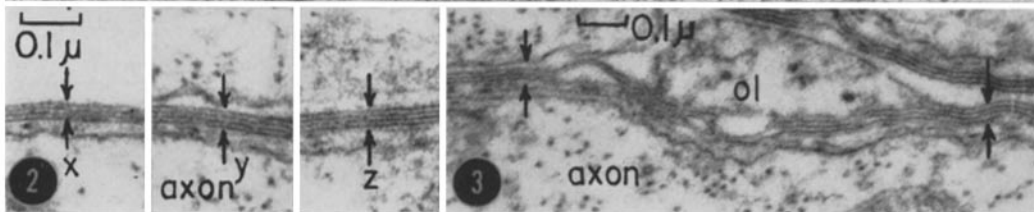
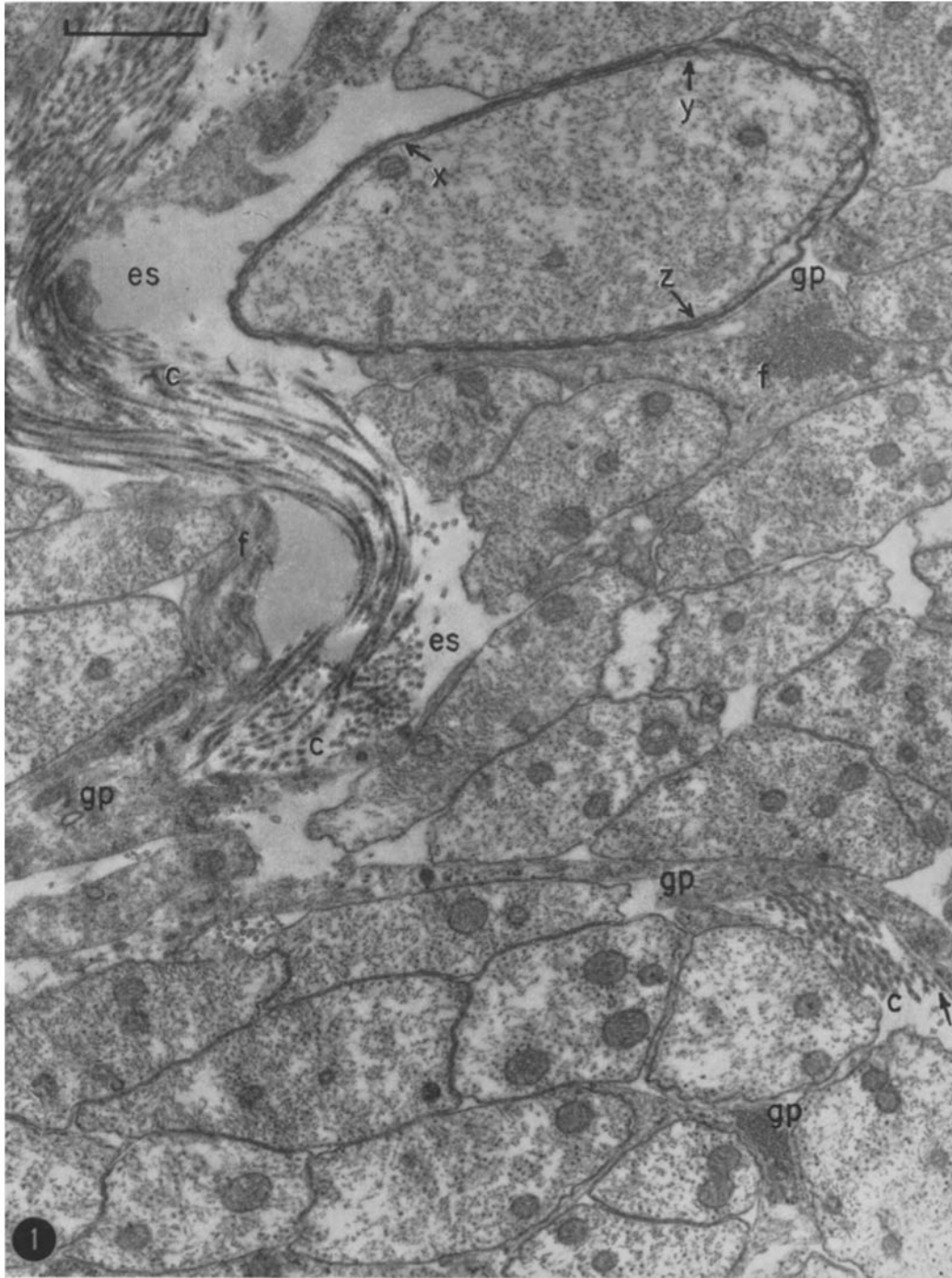
A new myelin sheath is being formed around one of the previously demyelinated axons. The lettered arrows point to portions of the sheath which appear enlarged in Fig. 2. Other axons are not yet invested with myelin and, therefore, remain clustered together but for a few invading glial processes (*gp*). Glial expansions are identified by the contained fibrils (*f*). Lying adjacent to one of the glial processes is a thin dense layer, marked by an arrow, found characteristically near collagen. Collagen (*c*) is present at this site; it is also visible at the upper left where its typical banding may be seen. Note that the collagen appears markedly different from glial fibrils. There is some extracellular space (*es*). Posterior columns, 24 d.p.o. $\times 19,500$.

FIGURE 2

Three portions, *x*, *y*, and *z*, of the sheath appearing in Fig. 1 are enlarged to reveal the characteristic myelin lamellae. Four dense lines, *i.e.* three lamellae, are present in these areas and much of the remaining sheath. Thus, the sheath thickness is uniform with the exception noted in Fig. 3, as would be expected of a spiral disposition of lamellae. $\times 71,500$.

FIGURE 3

A portion of a neighboring sheath contains three lamellae on the right side of the outer loop (*ol*); two, on the left. Most of the remainder of the sheath consists of two lamellae. This finding is consistent with a spiral arrangement of myelin. $\times 65,000$.



lost. This in many ways resembles the mechanism for peripheral myelinogenesis first proposed by Geren (13) and confirmed by Robertson (14, 15). Additional details of these mechanisms appear in the discussion.

Evidence will be presented here that remyelination in the cerebrospinal fluid exchange lesion is accomplished by spiral wrapping of glial cell processes. Ultrastructural data from spinal cord of normal adult and neonatal cat will be included for purposes of comparison. Morphological changes in glial cells during and subsequent to remyelination will be described. Autoradiographic studies of concurrent changes in glial cell metabolism, to be presented elsewhere (16), are summarized in the discussion.

MATERIALS AND METHODS

Cats of either sex, weighing 2.2 to 3.6 kg. and therefore considered mature, were used for this study. They were subjected to repeated withdrawal and reinjection of cerebrospinal fluid (c.s.f.) (2), and the most severely afflicted animals of those so treated were sacrificed 19, 24, 30, 45, 64, 100, 220, 369, or 460 days later. (Radioactive tracers had been injected into the intrathecal space of the 24, 30 (one of three cats), 64, and 369 day animals a few hours prior to sacrifice to permit autoradiographic study (16).) Peripheral cord was fixed *in situ* in the anesthetized animal by replacing all c.s.f. available at cisternal puncture with 3 per cent osmium tetroxide in veronal acetate buffer (pH 7.5). Respiratory movements of the animal ceased abruptly. Following removal of a portion of cervical cord about $\frac{1}{2}$ hour later, it was fixed in 2 per cent buffered osmium tetroxide for an additional $\frac{1}{2}$ hour at 4°C. Only a very shallow band of white matter around the periphery of the cord is fixed by this method but it is within this area that the lesion is located. Normal kitten cord was fixed similarly.

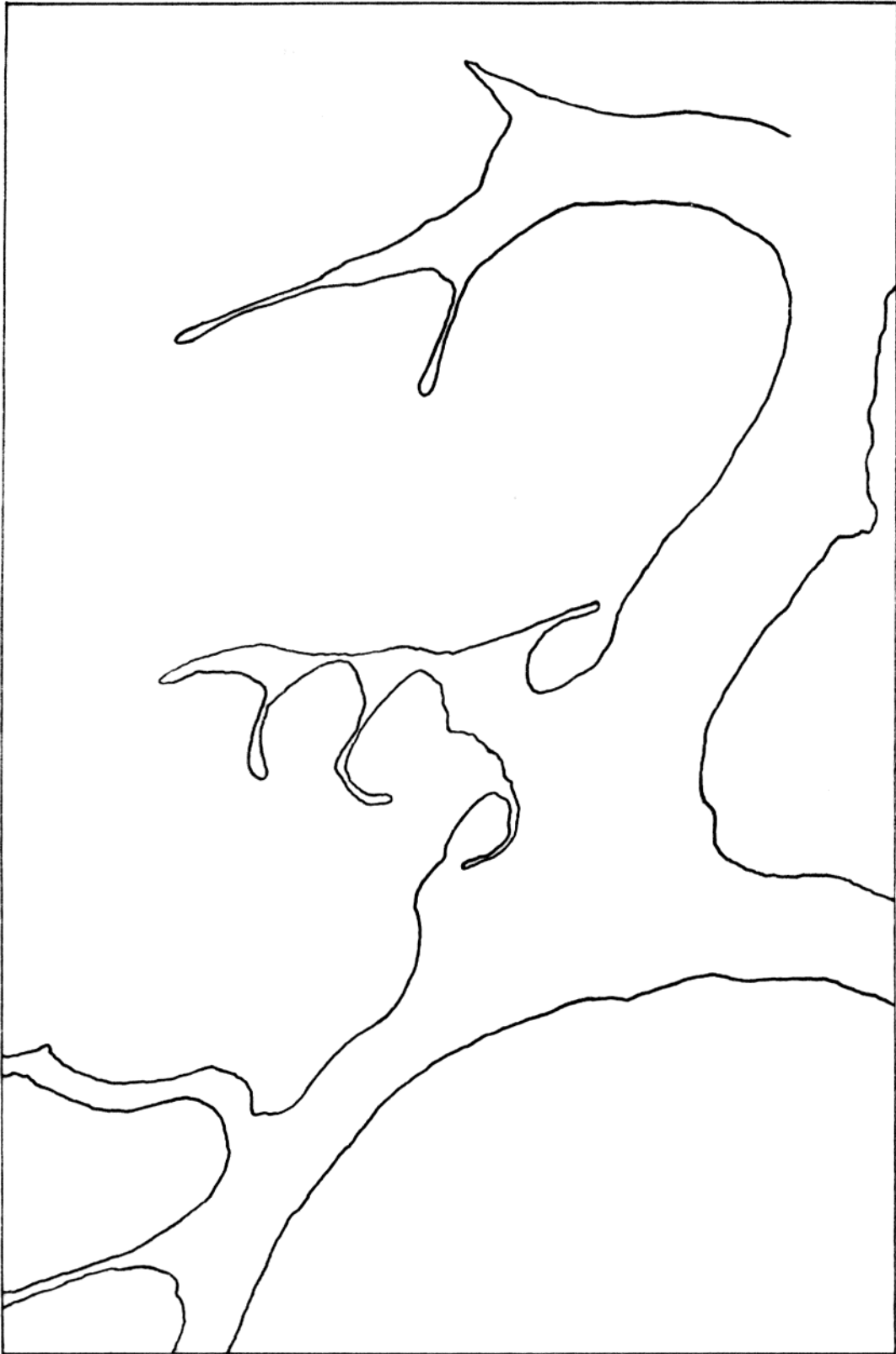
Following dehydration in a graded series of ethanol (70 to 100 per cent), small wedges cut from the cord segment were embedded in Araldite (Ciba

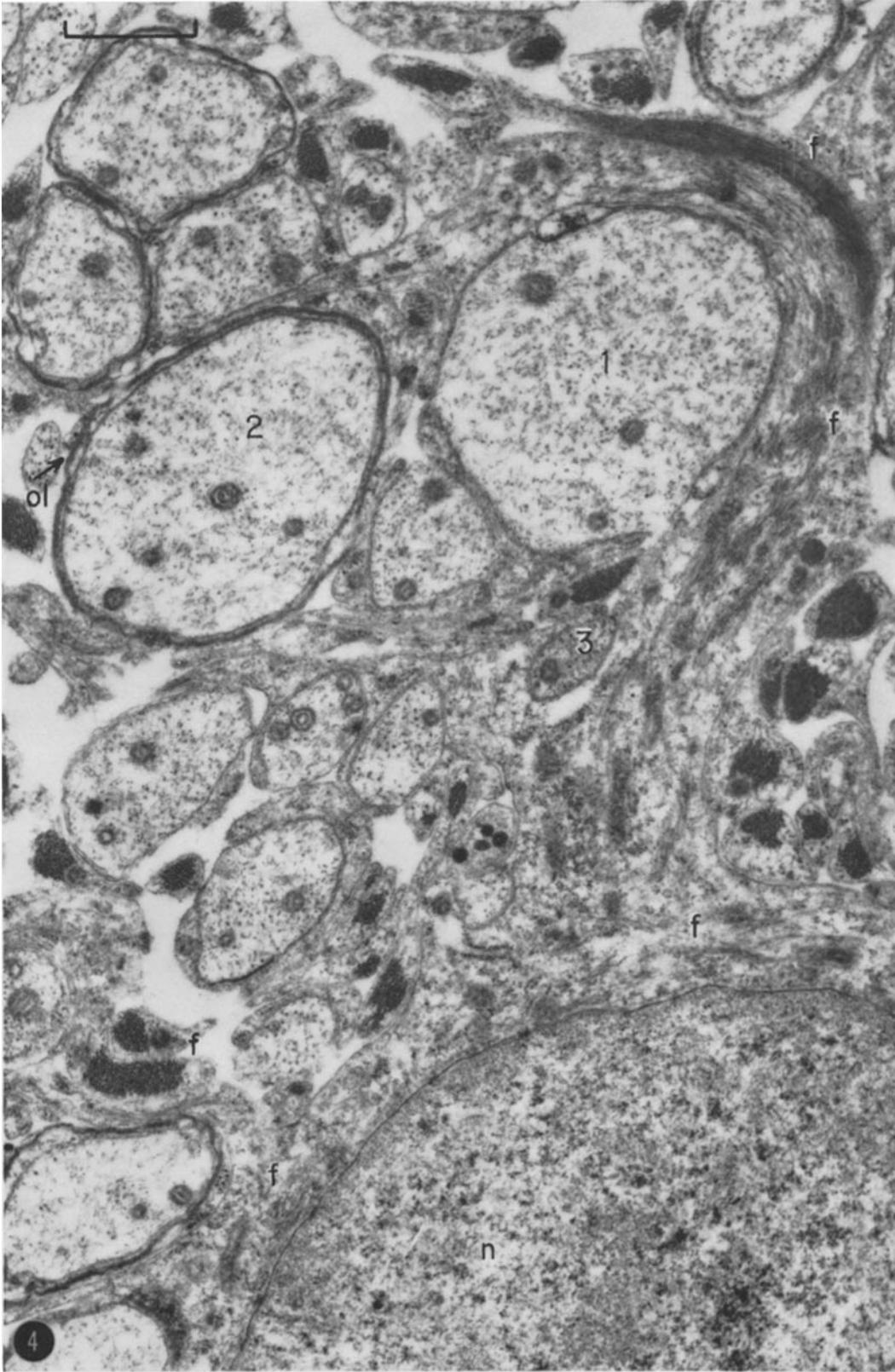
Company Inc., Plastics Division, Kimberton, Pennsylvania). Sections were cut with glass knives on a Servall Porter-Blum microtome and positioned on 400 mesh grids. No supporting films were used. Grids were then immersed in 7.5 per cent uranyl acetate for $2\frac{1}{2}$ hours at room temperature to increase contrast. The reader is referred to reference 2 for more detailed description of these methods. Sections were examined in a Siemens Elmiskop IIB and photographed on Gevaert Scientia 19 D 50 plates, with development in D 19. Initial magnifications of micrographs range from 1400 to 29,000. Satisfactory preparations from one animal at each interval were examined electron microscopically with the exception of the 30 day period in which case lesions from 3 animals were observed.

For permanganate (KMnO₄) fixation of normal adult subpial cord, the following procedure was devised. In one case (A), the fixative consisted of 2 per cent KMnO₄ in veronal acetate buffer, pH 7.6; in another case (B), the buffered 2 per cent KMnO₄ contained 0.56 per cent NaCl and 0.028 per cent CaCl₂. After surgical exposure of a length of cervical cord, a needle was inserted into the cisterna magna and a cut made through the meninges at the caudal end of exposed cord. Ice cold fixative was then injected into the subarachnoid space and, at first, c.s.f. and, subsequently, excess fixative flowed out through the cut. Respiratory movements of the animal halted immediately. Injection of fresh ice cold fixative was continued for 45 minutes and, following extirpation of a large wedge of posterior columns, the tissue was fixed for an additional $2\frac{1}{4}$ (A) or $3\frac{3}{4}$ (B) hours at 4°C. In this way, the successful method of *in situ* fixation was utilized and, at the same time, the tissue was fixed at a low temperature requisite for adequate fixation by KMnO₄ (17). Tissue was rinsed in cold 30 per cent ethanol and brought to room temperature in fresh 30 per cent ethanol. Following dehydration in 50 and 70 per cent ethanol, small wedges of peripheral cord were obtained and these were dehydrated as usual. Embedding was in Araldite (A) as above or Epon (B) (18). A sample of tissue fixed in mixture A appears in Figs. 11 and 12; tissue fixed in B is shown in Fig. 17. Figure 17 was photographed in an RCA EMU 3C in

FIGURE 4

Part of a reactive macroglial cell appears here. Its nucleus (*n*) is surrounded by cytoplasm which extends into many processes outlined on the overlay. Each process may embrace a different axon. Fibrils (*f*) are present within the perinuclear area as small wisp-like aggregations and within the expansions of this glial cell as small and larger bundles and within many neighboring processes as well. Some of the axons, such as axon 1, are not yet myelinated while others do manifest thin sheaths. On the outer surface of the myelin ensheathing axon 2 is a small loop, *ol*. Axon 3 is nearly completely surrounded by a glial process. Lateral columns, 45 d.p.o. $\times 20,000$.





the laboratory of Dr. G. D. Pappas, Department of Anatomy, College of Physicians and Surgeons.

OBSERVATIONS

Axons and Their Sheaths

Following demyelination, complete at 6 days postoperative (d.p.o.), axons are devoid of investing structures. Though these axons then come to lie in close apposition to one another, they are segregated into compact bundles by the greatly enlarging phagocytes. Each cluster of axons is soon dispersed by invading glial processes. At 19 d.p.o., when new myelin is first noted, many axons are embraced by glial processes. As remyelination continues, more and more unmyelinated axons display glial abutments. Throughout the course of myelin breakdown and its subsequent reconstitution, the structural components of axons do not change morphologically and the axons manifest the large size differences present in comparable normal areas.

Many axons are not yet myelinated at 24 days after c.s.f. exchange (Fig. 1). Before an axon is myelinated it may be only partly embraced by a glial process (Figs. 1, 4) or completely enveloped by one turn of a glial process (axon 3, Fig. 4). Sometimes glial cytoplasm is spiralled around an axon of small diameter one and a half to two times. At a given level, more than one glial process may abut on an axon. The axolemma adjacent to glial cytoplasm assumes a ruffled profile. The investing process varies in length and thickness and contains fibrils and other cytoplasmic or-

ganelles (Fig. 4). In both transverse and longitudinal sections, the glial fibrils usually are seen to run parallel to the long axis of the axon. Some processes are very long, skirting many axons along their course. From one large process, smaller ones may emerge, each one completely or nearly completely encircling a different axon (Fig. 4).

Newly formed *myelin sheaths* are first seen at 19 d.p.o. At this time, they occur very infrequently and are composed of only two or three layers. All new sheaths, regardless of axon diameter, are about equal in thickness during the early formative stages (Fig. 5). Moreover, the thickness of each sheath is uniform around (Fig. 6) and along the axon; variation greater than one in the number of myelin lamellae in different areas of the same sheath is rare. These observations were obtained from both transverse and longitudinal sections. The number of lamellae increases gradually so that by 45 d.p.o. eight or more constitute many a sheath. Infrequently a myelin sheath displays a gourd-like profile in transverse section because a portion of the overlarge sheath is doubled up on itself. Such a profile is seen rarely in the completely remyelinated lesion as well. This may result from loss of cytoplasm which had been present in the first turn of glial process while the sheath was forming. This configuration was observed repeatedly in myelinating mammalian central nervous tissue by Luse (6).

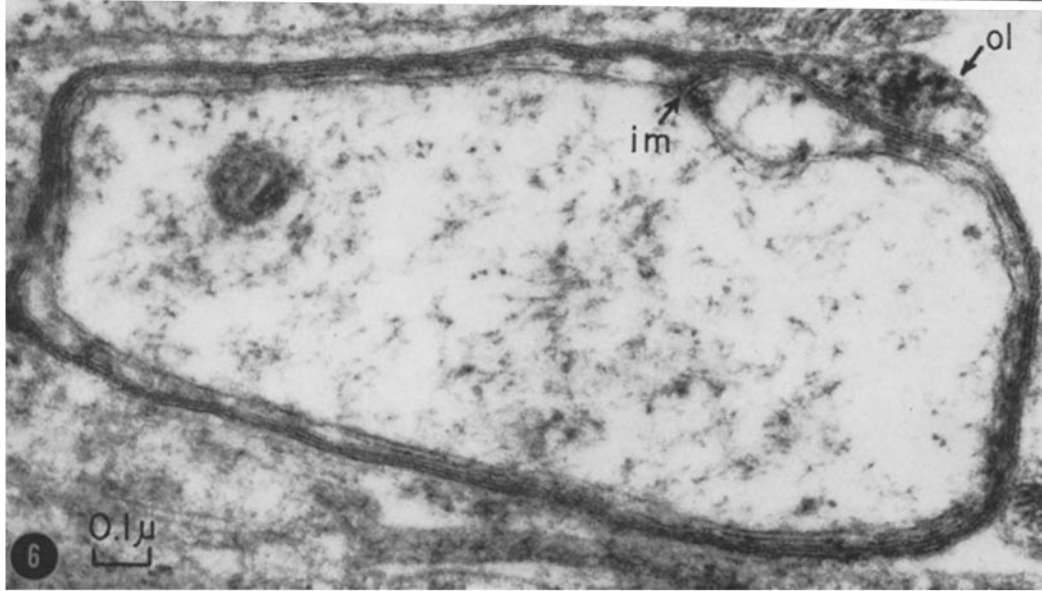
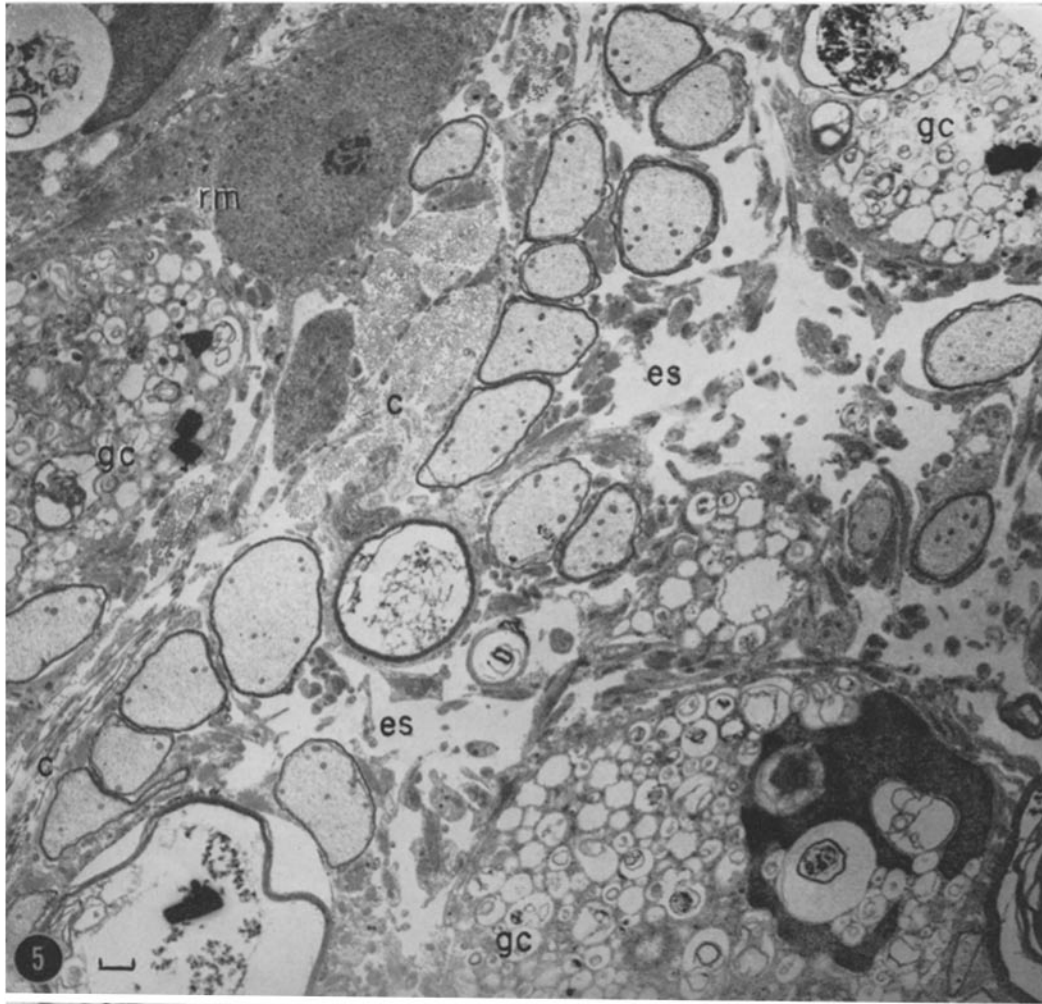
Only an occasional sheath, even during the period of most active myelin formation, appears to be encircled by glial cytoplasm. In these rare cases, the outermost unit of compact myelin splits

FIGURE 5

This figure shows the characteristic features of the remyelinating lesion. Axons are invested with new partly formed sheaths, and reactive macroglia (*rm*) and their many processes, gitter cells (*gc*), collagen (*c*), and extracellular space are present. The nucleus of one of the gitter cells is included in this section. It is markedly indented by adjacent debris in the cytoplasm. The empty-appearing areas (*es*) are extracellular rather than enlarged "clear" glial expansions for a membrane delimiting these areas is never found. Posterior columns, 30 d.p.o. \times 4500.

FIGURE 6

This axon is invested with a myelin sheath only two lamellae thick. It appears that the number of lamellae increases by one in some areas; when cytoplasm is absent from some portions of the first turn of the glial process, the innermost glial membrane approaches compact myelin. An inner mesaxon (*im*) is visible. The outer dense line of this sheath splits and a terminating loop (*ol*) is thus formed. There are particles within this loop as usual. Lateral columns, 45 d.p.o. \times 67,500.



at one locus into two membranes which lie parallel to one another for a short distance. This length of apposed membranes resembles the outer mesaxon of peripheral nerve (14, 19). After a brief parallel course, the two membranes diverge and form the plasma membrane which delimits the surrounding collar of glial cytoplasm. In peripheral nervous tissue, the outer mesaxon is considered a vestige of the spiral mode of myelinogenesis.

Usually there is no complete rim of glial cytoplasm around a central sheath. Sometimes glial cytoplasm is found only on both sides of the outer mesaxon, the remainder of cytoplasm having been lost with attendant fusion of the limiting glial membrane and compact myelin (Figs. 7, 25). More frequently, typical mesaxons are not visible; only a single narrow ridge of glial cytoplasm remains along the internode. In transverse section, this ridge is seen to be a small remnant of cyto-

FIGURE 7

Both an inner and a very short outer mesaxon (*im*, *om*) are present in this sheath in *remyelinating cord*. Dense particles in the glial cytoplasm on both sides of the outer mesaxon are larger than transversely sectioned glial fibrils (*f*) at the upper left. Posterior columns, 45 d.p.o. \times 99,000.

FIGURE 8

In this sheath in *remyelinating cord*, myelin terminates in an outer loop (*ol*) rather than as an external mesaxon. At the right of the loop there are five lamellae; at the left, four. This would be expected of a spiral disposition of membrane to form myelin. Posterior columns, 30 d.p.o. \times 99,000.

FIGURE 9

Continuous with this myelin sheath from *normal kitten cord* is an inner mesaxon (*im*) and an outer loop (*ol*). Particles similar to those visible in Figs. 7 and 8 are present in the retained glial cytoplasm. Lateral columns, 25 days after birth. \times 102,000.

FIGURE 10

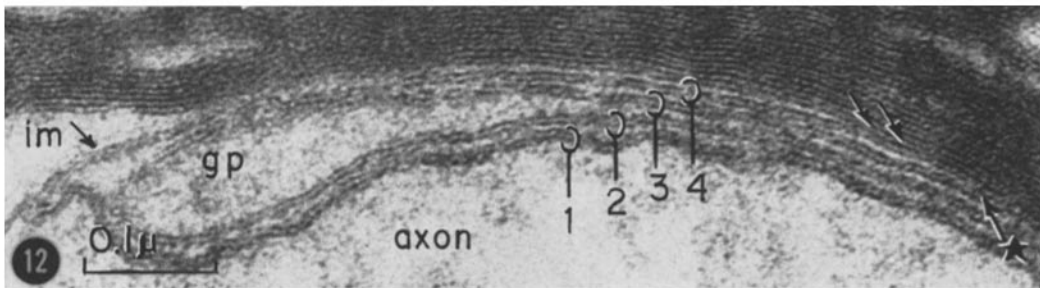
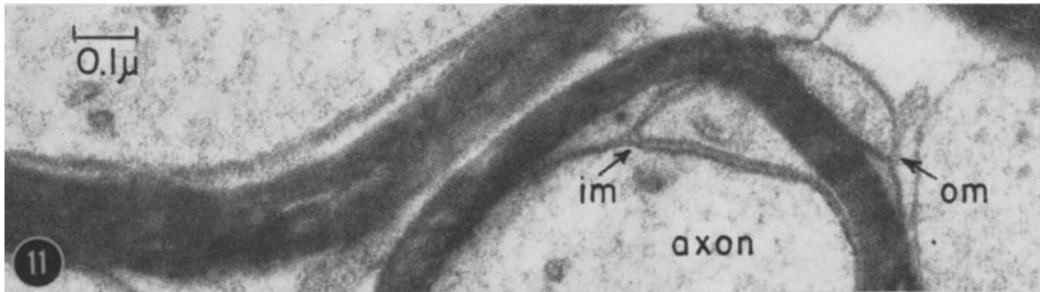
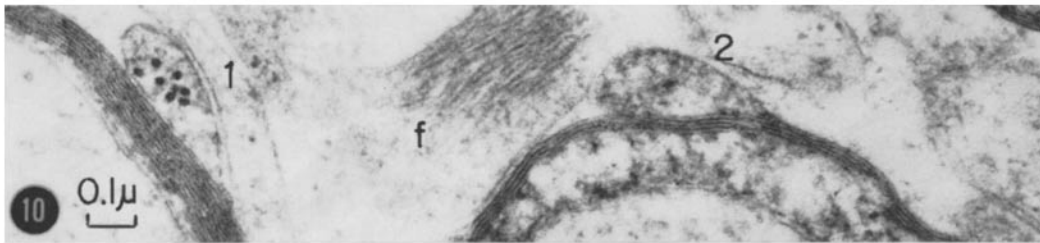
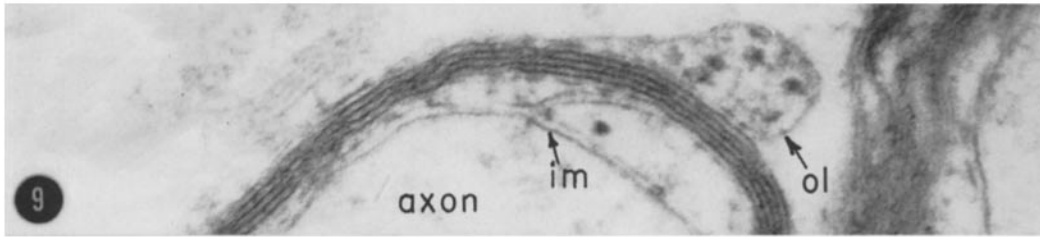
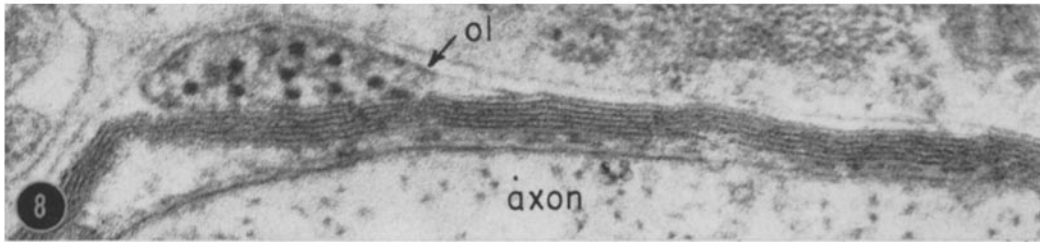
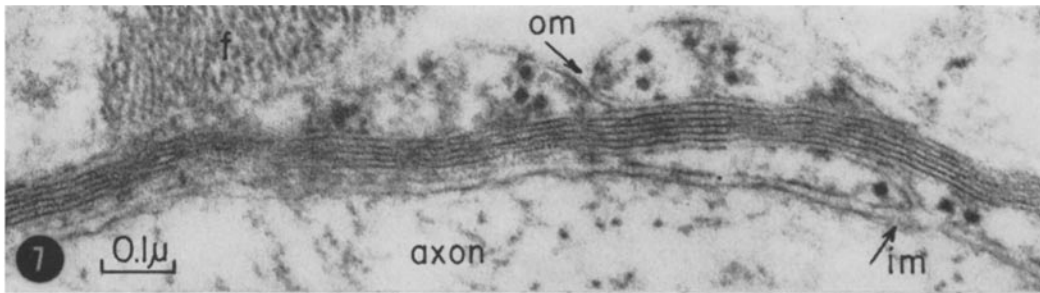
Both outer mesaxons and outer loops are present in *normal kitten cord*. In this figure, outer loops from two adjacent sheaths are visible. Particles in loop 1 are larger in diameter than near-by glial fibrils (*f*). The sheath from which loop 2 emerges is beginning to terminate at a node. Lateral columns, 25 days after birth. \times 55,000.

FIGURE 11

In *normal adult cat cord*, a typical sheath displays an inner mesaxon and either a mesaxon or loop on the outer surface. This sheath exhibits an inner and an outer mesaxon (*im*, *om*). Because this tissue was preserved with permanganate, the plasma membrane appears to be a three layered structure. Posterior columns. \times 73,000.

FIGURE 12

This photograph shows an inner mesaxon (*im*) in *normal adult cat cord*. All encircled areas contain a segment of plasma (unit) membrane which appears to consist of three layers after fixation with permanganate. Circle 1 contains the axolemma. Within circles 2 and 3 is plasma membrane bounding the glial process (*gp*) which first surrounds the axon. Circle 4 also contains glial plasma membrane but from the portion of the process which is near the second turn. Where the cytoplasmic surfaces of this portion of membrane and an adjacent membrane already part of compact myelin unite, a major dense line is seen (arrows). One half a period below this line, a less distinct intraperiod line is present (starred arrow) where the outer surfaces of membrane 3 and 4 have come together. Posterior columns. \times 170,000.



plasm trapped within a loop of plasma membrane at the outer end of the spiralled process (Figs. 3, 6, 8). Fig. 18 diagrams this structure. As with peripheral outer mesaxons, only one cytoplasmic ridge is present on the exterior of a thickening or fully formed sheath. The outer ridge or "loop" may result from loss of cytoplasm on one side of the external mesaxon as has been suggested by both Maturana (10) and Peters (11, 12).

That the contents of the outer cytoplasmic ridge are continuous with cytoplasm of the myelin-forming glial cell is strongly suggested by the presence of intermediates between a glial collar and ridge. This cytoplasm probably retains continuity with a glial cell body after myelination is completed but such a connection has not thus far been obvious to us. When the membranous loop enclosing the cytoplasm is large, mitochondria are sometimes found in the cytoplasm;

regardless of loop size, dense particles are always present (Figs. 3, 6, 8). These particles are ~ 200 to 250 \AA in diameter and are, therefore, larger in diameter than ribosomes or fibrils in adjacent glia. No comparable particles are visible outside the loops. Outer loops in remyelinating cord resemble those visible in myelinating new-born cat cord (Figs. 9, 10). While the loops vary greatly in size during remyelination, they are reduced to a constant small size as this process is completed. Within these small loops, only the dense particles can be resolved. Outer loops in the late lesion resemble their counterparts in comparable areas in normal adult cat cord. Their small size renders them inconspicuous and they are difficult to preserve. These observations may explain why they have not been noted by others studying mammalian spinal cord.

It seemed at first that occasionally there was

FIGURE 13

This longitudinal section demonstrates the presence of a node in *remyelinated cord*. As in the outer loop, the glial process here retains cytoplasm at its edge. Within this cytoplasm are particles which resemble those in Figs. 7 and 8. Sheath endings at a node are diagrammatically depicted in Fig. 18. Lateral columns, 460 d.p.o. $\times 24,500$.

FIGURE 14

This is an ending of a forming sheath in *remyelinating cord*. The four dense lines constituting the sheath end in four loops. The loop farthest from the unmyelinated portion of this axon derives from the innermost myelin unit. The unlabeled arrow points to the axolemma. Longitudinal section of lateral columns, 45 d.p.o. $\times 54,500$.

FIGURE 15

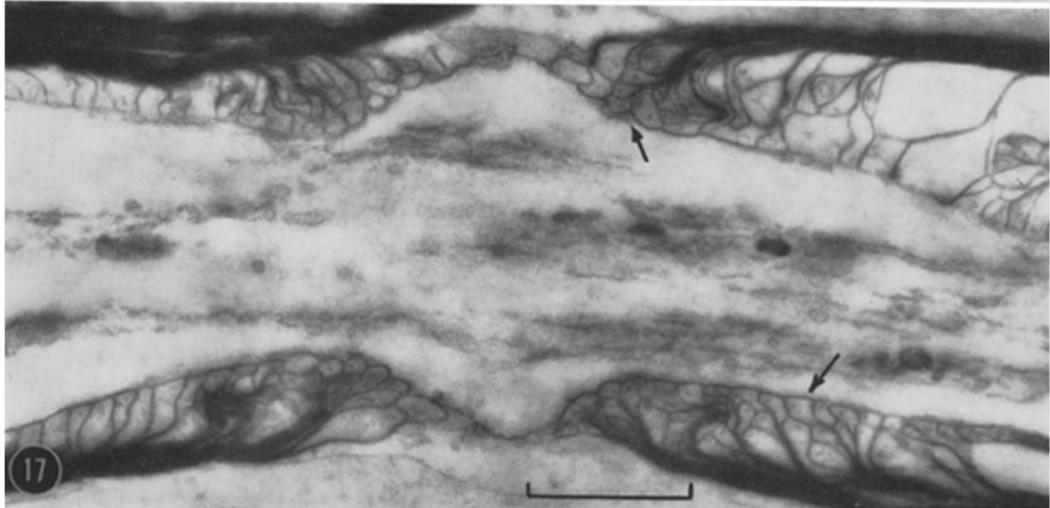
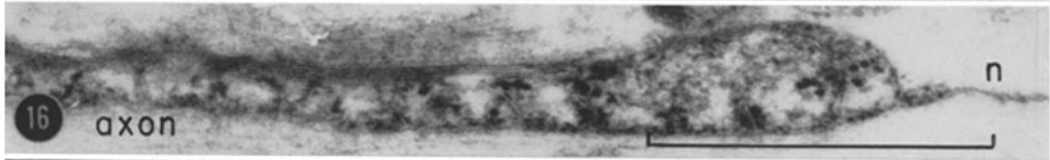
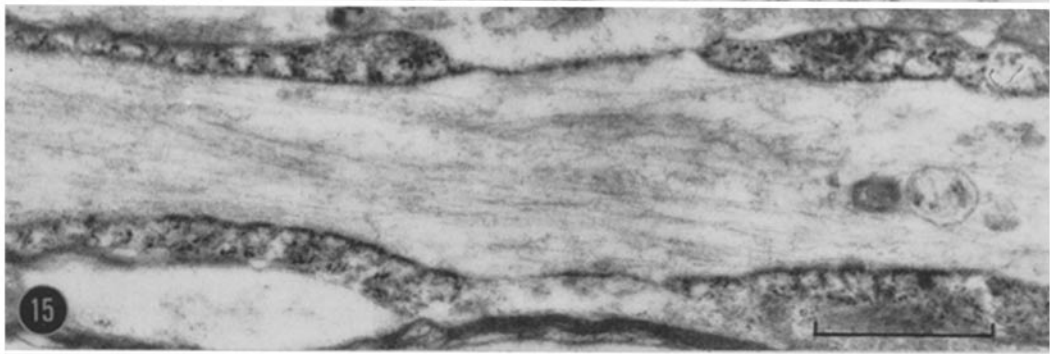

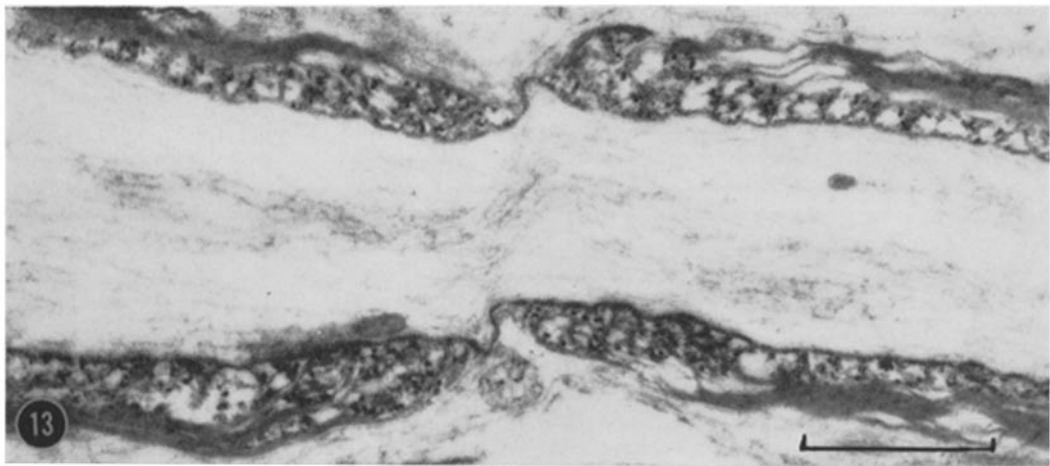
Nodes are also seen during first myelinogenesis in *normal kitten cord* as shown here. Longitudinal section of posterior columns, 25 days after birth. $\times 23,500$.

FIGURE 16

The sheath ending at the upper left of Fig. 15 is enlarged. Note that the inner myelin units terminate in loops farthest from the node (*n*). The loop bordering the node is formed from the outermost myelin unit. Particles similar to those in Figs. 7 and 8 are present in retained glial cytoplasm. The lack of glial processes around the nodal axolemma is typical. $\times 45,500$.

FIGURE 17

This node is from *normal adult cat cord*. It resembles nodes in both remyelinating adult and myelinating kitten cord. When sheaths are thick, as in this figure, the loops are crowded and many of them do not appose the axolemma in a given section (arrows). Within these loops, the particles typically seen after OsO_4 fixation as shown in Figs. 13 and 15 are not visible; this is invariably true when, as in this case, permanganate fixation is employed. Only a vesicle or two can be seen within a typical loop. Posterior columns. $\times 21,500$.



more than one cytoplasm-containing loop on a sheath exterior during remyelination. It was soon realized, however, that these structures were not loops but, instead, additional areas where cytoplasm had been trapped, preventing the outermost membrane from fusing with myelin as usual (see *cy*, Fig. 18). Cytoplasmic inclusions are present in this trapped cytoplasm. Many times during the early phase of remyelination, trapped cytoplasm was observed within more interior layers of a sheath, too. Sometimes the membranes bounding the enclosed cytoplasm are continuous with myelin lamellae; in these cases, the cytoplasm is part of the spiralling glial process. At other times they are not continuous for the membrane can be traced all the way around the cytoplasm; in these cases, the cytoplasm belongs to an extraneous glial process. It is possible that as one process spiralled around an axon, another was caught within by chance. More than one such process may be trapped in a sheath. These processes often contain fibrils.

At the innermost edge of a sheath, glial cytoplasm is also present in varying amounts during remyelination (Figs. 1, 4, 6). Dense particles like the ones in outer loops are visible (Figs. 6, 7). This cytoplasm derives from the glial process which first completes a turn around the axon. That portion of glial plasma membrane nearest the axon encircles the axolemma and veers away

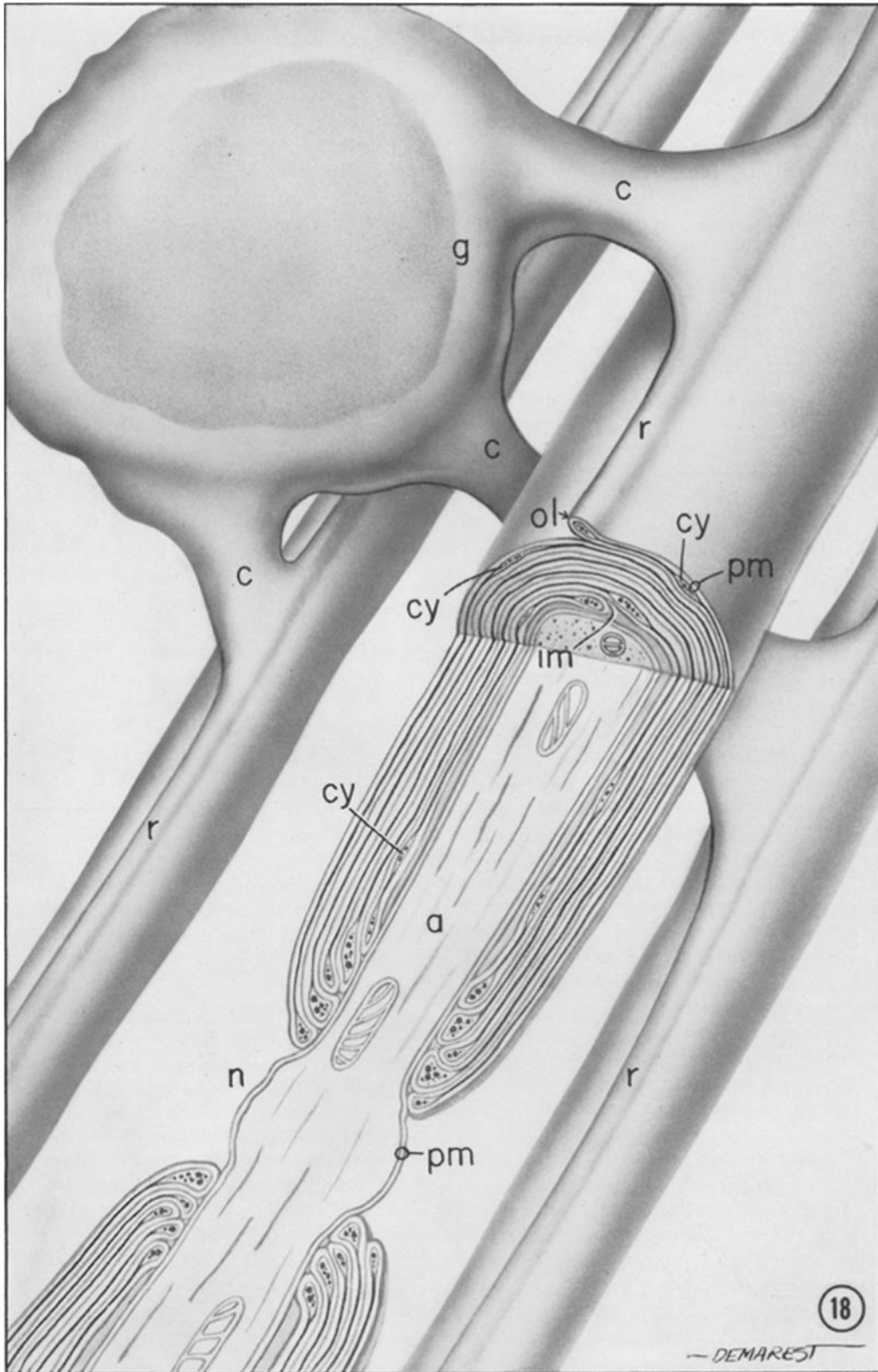
from it as a double membrane which after a short distance merges with compact myelin (Figs. 6, 7, 24; *im*, Fig. 18). This double membrane is formed by apposition of two different parts of limiting membrane of the glial process and, from comparison with studies of peripheral myelinogenesis (13-15), constitutes an internal mesaxon. One and only one inner mesaxon is found within a typical sheath. They are identical to the inner mesaxons which appear during first myelin formation in kitten spinal cord (Fig. 9) and those which remain throughout a normal cat's adulthood (Figs. 11, 12). The direction of the inner mesaxon as it enters the sheath has always been observed to be identical with the direction from which the external loop emerges from compact myelin (Figs. 6, 9, 11). In serial sections of a remyelinating axon, the positions of the external loop and inner mesaxon appear to change relative to each other. Modified inner mesaxons, inner loops as described by Maturana in amphibian optic nerve (10), are rarely seen in the lesion.

During remyelination of an axon, one portion of its length may be ensheathed with compact myelin while, farther along its longitudinal axis, myelin is completely lacking. In the area of transition between myelinated and unmyelinated portions, the spiralled glial process retains cytoplasm along its expanded lateral edges. In longi-

FIGURE 18

Central nervous system myelin glial relationships: This diagram illustrates both known and hypothetical aspects of the mature myelin sheath and its relationship to a glial cell. The unit or plasma membrane (*pm*) is here designated as two lines separated by a space except in the mitochondria where it is represented by a single line. The inner mesaxon (*im*), formed as a glial process completes the initial turn around an axon (*a*) and starts a second, is retained after myelin formation is completed. Some cytoplasm of the glial process is present here. Cytoplasm is trapped occasionally at *cy*. On the fully formed sheath exterior, a bit of glial cytoplasm is also retained. In transverse section, this cytoplasm is confined to a loop (*ol*) of plasma membrane (*pm*) but, along the internode length, it forms a ridge (*r*) which may be continuous with a glial cell body (*g*) at *c*. When viewed transversely, the sheath components are oriented in a spiral, only the inner- and outer-most layers ending in loops; in the longitudinal plane, every myelin unit terminates in a separate loop at both ends of the internode. Within these loops, glial cytoplasm is also retained. We believe that this cytoplasm, contained within the expanded lateral edges of the spiralled glial process, is a continuous cord helically wound around the axon like cable about a spool.

The outer loop, inner mesaxon, and sheath endings at a node (*n*) are illustrated herein and evidence for a spiral arrangement of myelin lamellae is presented. The connection (*c*) between a glial cell body and a mature sheath has not been demonstrated. From our observations, however, it seems likely that this connection is maintained and, furthermore, that several sheaths may be connected to one glial cell.



M. B. BUNGE, R. P. BUNGE, AND H. RIS *Remyelination in Experimental Lesion* 79

tudinal section, this cytoplasm appears contained within loops of plasma membrane (Fig. 18). The myelin unit nearest the axon gives rise to a loop farthest from the unmyelinated portion. The axon is next encased by loops from progressively more peripheral myelin until the area nearest the unmyelinated portion is touched by loops formed from the outermost myelin units. This configuration resembles the termination of a sheath at a node of Ranvier in peripheral nerve (20, 21). Within the helix of retained cytoplasm at both ends of the internode are dense particles like those contained within the cytoplasmic ridge along the sheath exterior. Although an axon may lack ensheathing myelin for a considerable distance, usually an unsheathed portion of axolemma is very short due to a sheath ending encroaching from the opposite direction. This length of bare axolemma is a node.

Nodes appear in adult lesion cord (Figs. 13, 14) and are present in normal adult (Fig. 17) and new-born (Fig. 15) cat cord as well. They resemble nodes in amphibian and mammalian optic nerve (10, 12, 22) and, in many ways, nodes of Ranvier in peripheral nerve (20, 21). In all these sources, the sheath endings are similar. In early remyelination when internodes are composed of only a few layers of myelin, the terminating loops are not always as regularly arranged, and occasionally the loops from adjacent internodes may meet or pass by to obliterate the node. When fully formed sheaths are thick, many of the loops do not touch on the axolemma in a given longitudinal section (Fig. 17). An axon narrows as the nodal region is approached. This is seen in longitudinal sections, and inferred from transverse sections because a typical nodal sheath ending surrounds only axons of small diameter. At the node itself, the axolemma sometimes bulges outward.

There is one striking difference between central and peripheral nodes. Neither a collar of abutting glial processes nor a basement membrane encircles the unmyelinated axolemma. The axolemma directly apposes an adjacent axon, unmyelinated or myelinated, or glial cell (Figs. 13, 15, 16) and, hence, in a transverse section, a nodal axon cannot be distinguished from an unmyelinated axon. After study of longitudinal sections we realized that certain sheaths, which in transverse section appeared modified, had been sectioned near nodes. Examples of this appear in Figs. 19, 22, and 23. When seen in cross-section,

some of the myelin layers are not compact due to contained glial cytoplasm which, in longitudinal sections, is visible within the terminating loops. Dense particles are present within this cytoplasm. Sometimes more than one mesaxon can be resolved. Furthermore, if in a given transverse section compact myelin is present, it is usually at the periphery of the ensheathing layers. This agrees with the finding in longitudinal sections that outermost myelin units terminate nearest the node (Figs. 14, 16, 18). (Fig. 5 in a previous paper (2) displayed a transverse section of a juxtaterminal myelin sheath.)

Following fixation with permanganate, component layers of a single (unit) membrane are more clearly seen and major dense and intraperiod lines within myelin are more readily distinguished (15, 19). After permanganate fixation of normal adult cat spinal cord, we observed that where facing surfaces of the two membranes of an inner mesaxon unite, an intraperiod line appears (Fig. 12). Thus, the intraperiod line results from association of the outer surfaces of two unit membranes. The major dense line, on the other hand, forms as two inner (cytoplasmic) surfaces of plasma membrane come together (Fig. 12). Where the cytoplasmic surfaces of plasma membrane bounding the outer loop converge, a major dense line appears. The same phenomenon exists in the series of loops that constitute the termination of a sheath at a node. Refer to the diagram, Fig. 18. These findings concur with observations made on peripheral nerve by Robertson (19, 21).

More and more axons become myelinated between 19 and 64 d.p.o. By 64 d.p.o., nearly every axon is ensheathed by some myelin. At any one interval, axons of differing sizes are being myelinated simultaneously; myelination of very small or very large axons in a certain order is not observed. It would appear, from study of the 45 day lesion, that some very small axons viewed in transverse sections are the last to be myelinated. But, since an axon exhibits a smaller diameter near the nodal region, the possibility that these axons were sectioned at a near-node or node level should not be overlooked. The number of myelinated axons per unit area in the reconstituted lesion is less than normal because of large and numerous macroglia, a great number of fibrous processes, and persisting extracellular space. At 64 d.p.o. the larger axons are first seen

to possess the thicker sheaths as in comparable normal tissue. The variation in sheath thickness does not, however, reach the normal state. By 460 d.p.o., the latest stage we have studied, the sheaths are generally not as thick as in comparable normal areas (Fig. 23). An occasional sheath displays a bizarre profile beginning at 220 days after c.s.f. exchange. Aside from these differences, myelin sheaths in the late lesion resemble those which were formed during normal development (Figs. 23 to 25). The neurological condition of the experimental animal begins to improve at a time when remyelination begins and has returned to normal by the time most axons are at least partly remyelinated.

Macrogia

No identifiable macroglia¹ are observed directly after insult to the spinal cord but as demyelination is completed, one macroglial cell type appears in the lesion. Since this cell type does not fit the ultrastructural description for either oligodendrocyte or fibrous astrocyte, the two types of macroglia found normally in subpial white matter, it will be referred to as *reactive macroglia*. The differences between reactive macroglia and the normally occurring macroglia have been discussed previously (2). Reactive macroglia form the new myelin which appears in the lesion.

Reactive macroglia contain large, oval, and sometimes indented nuclei which, in many sections, possess prominent nucleoli (Fig. 5). In the dense cytoplasm are unoriented cisternae of endoplasmic reticulum with associated particles presumed to be ribosomes, grouped ribosomes free of membranes, Golgi complex, mitochondria, round bodies varying in density, empty-appearing vesicles, and fibrils (Figs. 4, 20). Fibrils cut in transverse section are clearly distinguishable from ribosomes because they are smaller in diameter. The degree of aggregation of the fibrils varies but generally they are dispersed throughout the dense cytoplasm or aggregated into slender wisps (Fig. 20). The few larger fibril bundles seen in early remyelination are not as compact as in later stages. Infrequently the cytoplasm displays a debris-containing vacuole and a peculiar oval or spindle-shaped dense body with a clear central

¹ Macroglia is used as a generic term for both astrocytes and oligodendrocytes (23).

area (rm_1 and rm_2 , Fig. 19). Occasionally centrioles are visible in the perinuclear area.

These macroglia are large and dispatch many processes which vary greatly in length and thickness. Processes from one cell may embrace many axons (Fig. 4). Fibrils extend into these processes. By 45 d.p.o., longer and stouter processes, containing larger and more compact fibril bundles, are noticeable (Fig. 19). Grouping of axons into fascicles by fibrous processes, a normal relationship which is lost in the early hours of the lesion, is once again observed. At 460 d.p.o., slender fibrous processes dominate the ultrastructural picture; there is a plethora of the processes, each containing a large, highly compact fibril bundle (Figs. 22, 23). No fibrils are found outside cell membranes. Reactive macroglial cell bodies also acquire greatly enlarged compact fibril bundles. A spectrum of intermediate types between reactive macroglia and highly fibrillar glia becomes evident after remyelination is under way. Reactive macroglia display unoriented wisps of fibrils scattered throughout a full cytoplasm as seen in Fig. 20. Neighboring cells exhibit larger fibril aggregates within dense cytoplasm as exemplified in Fig. 21. The most highly fibrillar cells, one of which is pictured in Fig. 22, contain many large compact bundles of fibrils that nearly fill the perinuclear area and often markedly indent the nucleus. At the latest stage examined, 460 d.p.o., fibril-containing cells differ greatly in density of both fibrils and the usual cytoplasmic structures. Some cells still resemble the reactive macroglia present in early remyelinating cord. The predominating cells, however, are the highly fibrillar types which we believe correspond to the fibrous astrocytes characterizing astrocytic scars formed in destructive central nervous tissue lesions. A small number of fibrous cells are present in the pia mater at this late stage.

At 45 d.p.o., when a few reactive macroglia have become noticeably more fibrous, a distinctly different macroglial cell type appears infrequently in the lesion. This type of cell resembles the *oligodendrocyte* found in comparable normal areas. It is smaller than the fibrous cells and displays few processes (Fig. 23). Moreover, a process is short and stout in contrast to the long, slender expansions of the fibril-containing cells. Contained within the cytoplasm are sometimes oriented cisternae of ribosome-studded endoplasmic reticulum, grouped ribosomes, mito-

chondria, Golgi complex, ovoid bodies containing a central area of low density, and, occasionally, centrioles in the perinuclear area. The oriented cisternae of endoplasmic reticulum and ovoid bodies were notable characteristics of oligodendrocytes in normal cord. The nucleus, round or irregularly oval in shape, often exhibits a nucleolus. These cells increase in number with time so that by 460 days there are many in the lesion. At this time, cells like the one in Fig. 23 are seen; others display more or less cytoplasm. Those with more cytoplasm resemble normally occurring oligodendrocytes. Those with less cytoplasm are difficult to classify for the paucity of characteristic cytoplasmic inclusions precludes their identification in electron micrographs. Their nuclei are surrounded by only a thin band of cytoplasm and, within this cytoplasm, ribosomes and an occasional mitochondrion are most prominent. The predominance of free ribosomes is characteristic of embryonic or rapidly dividing cells (24, 25, among others). Whether the cells might be immature oligodendrocytes or less differentiated precursor cells is not known. The light microscopist would probably label them oligodendrocytes.

Phagocytes

Phagocytes (gitter cells), greatly engorged with products of myelin breakdown, abound in the remyelinating as well as the demyelinating lesion (Fig. 5). We know that much of the contained material originated from myelin sheaths because the characteristic ordered lamellae are still visible, even in gitter cells that persist throughout remyelination. These phagocytes are filled with vacuoles which vary in size and contain large rings, distorted whorls or fragments of myelin or amorphous detritus, or appear empty of structured material. Highly dense, irregularly shaped particles are still present in some of the debris.

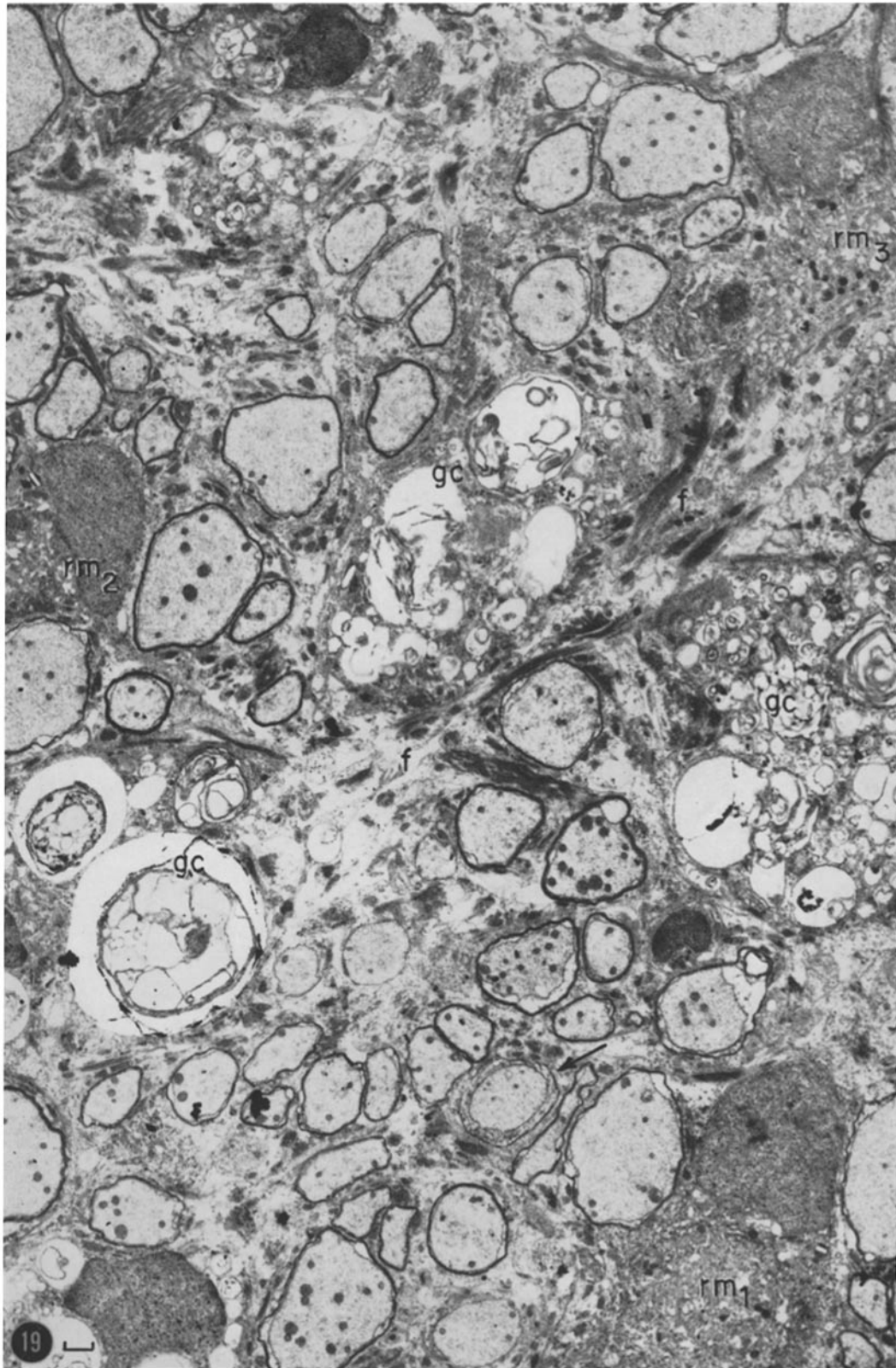
The heterogeneous appearance of debris contained within these gitter cells is very typical. Gitter cell nuclei manifest such a highly indented outline that adjacent vacuoles sometimes appear to be within them (Fig. 5). These nuclei are greatly enlarged and very often contain prominent nucleoli. At 24 and 30 d.p.o., gitter cells are lined up immediately beneath the pia in the cord, forming a layer, sometimes three cells deep, between the cord surface and all axons and glia. There are so many phagocytes, and they reach such large proportions that they "dilute out" axons and glia; their subsequent disappearance may, then, lead to a seeming increase in the number of reactive macroglia within the lesion.

The number of gitter cells decreases slowly at first. By 45 d.p.o., however, many have disappeared from the lesion (Fig. 19). Thus, much of the new myelin is formed before the remnants of former myelin have been removed. But the myelin, except for an occasional large whorl, is taken up by phagocytes before remyelination begins. In the few remaining gitter cells in 64 day lesion cord, the contained debris appears more homogeneous; most vacuoles appear clear. Very few gitter cells remain in the 100-day lesion. Gitter cells, seen only rarely 220 days after c.s.f. exchange, contain large vacuoles which appear almost empty. No gitter cells were found in the lesion thereafter.

In the description of the demyelinating phase, abutment of gitter cells on capillaries, both in cord and pia, was reported (2). At 19 d.p.o., the one cord capillary encountered was surrounded by a phagocyte. From 24 d.p.o. on, debris-containing cells were not contiguous with the moderate number of cord capillaries found, with one exception at 45 d.p.o. One capillary in a 30 day lesion was examined at many levels; at no level was there an adjacent debris-containing cell. Also of interest is the finding that lesion cord capillaries

FIGURE 19

This is the characteristic appearance of the lesion at 45 d.p.o. Most axons are ensheathed with myelin; the sheaths vary slightly in thickness. One sheath is near its ending at a node (arrow). General views such as this usually contain at least one prenatal sheath. Axons which appear unmyelinated at this level may, in fact, have been sectioned through nodes. Three reactive macroglia (*rm*) are present. Long processes containing increasingly compact fibril bundles (*f*) are seen throughout this area. Gitter cells (*gc*), though reduced in number, are still present. Posterior columns. $\times 4500$.



display no abutting glial end-feet. No gitter cells lie between or within endothelial cells or inside capillaries in the remyelinating lesion or overlying pia mater. Some gitter cells or their processes are flattened out on pial capillaries but to a lesser extent than at earlier intervals.

Many gitter cells are present in the pia mater up to 64 d.p.o.; they gradually decrease in number thereafter until 220 d.p.o. when they are no longer seen. They are decidedly smaller than those seen directly beneath the pia in subjacent cord, possibly because much of the contained debris has been expelled. In a few phagocytes, a large vacuole appeared to be open to the extracellular space as if discharging its contents. Some cells contain only a small amount of debris. That much of this debris was derived from myelin was ascertained by finding the regularly arranged lamellae. Other than the presence of this ingested substance, these cells resemble near-by pial macrophages.

Plasma Cells

A few plasma cells were observed in cord or pia mater or both at nearly every time interval studied.

Collagen

Collagen is abundant in the leptomeninges and subpial lesion as well. It is particularly abundant up to 30 d.p.o. and gradually decreases in amount thereafter. In one area of a 30 day lesion, a large array of collagen was ringed by fibroblasts. Characteristic banding of the collagen was often

noted in these stained sections (Fig. 1). In the cord, when collagen is found in patches of extracellular space, a thin amorphous layer of dense material apposes the limiting membranes of the bordering reactive macroglial processes (arrow, Fig. 1). Similar thin dense layers are also found in apposition to pial Schwann cells and endothelial cells. When naked axons or gitter cells occur near the collagen, however, their limiting membranes display no such appending dense substance (Fig. 1).

DISCUSSION

Study of this lesion allows us to conclude that remyelination can occur in an adult mammal and to define the mechanism by which the new myelin is formed. The origin of the myelin-forming cells, the way in which they form myelin, and their role in the concomitant fibrillar scarring will be discussed.

Macroglial Response

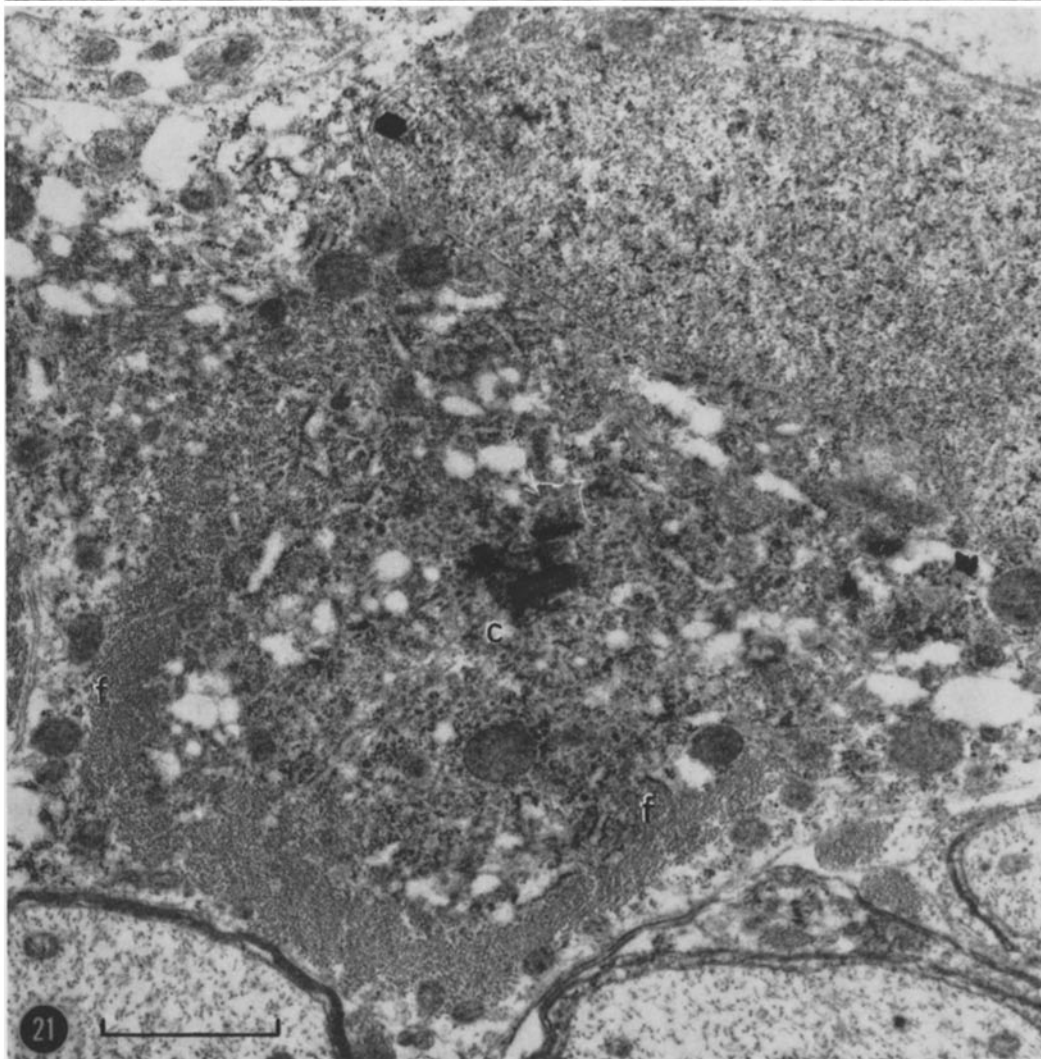
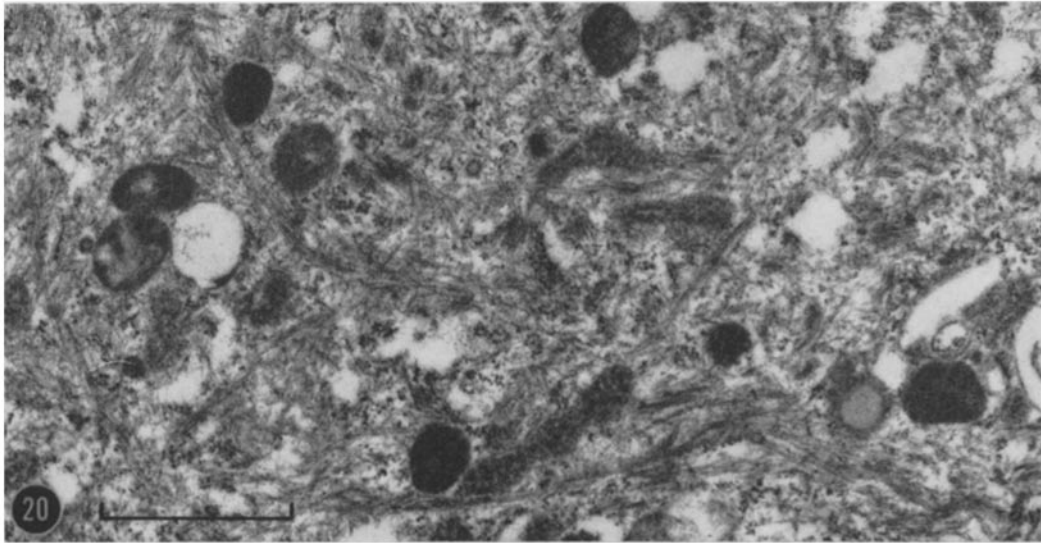
Twenty-nine hours after c.s.f. exchange, normal macroglia are no longer found in the lesion (2). Whether they disintegrate or become phagocytes is not known. About 1 week later, a type of glial cell not normally found in adult white matter enters the lesion and begins to remyelinate axons. The question of where these cells arise and from which glial cells they are derived cannot be adequately studied by the sampling techniques employed in this ultrastructural study. For this reason a concomitant histologic and autoradiographic study was undertaken (16). The results

FIGURE 20

The cytoplasm pictured here is typical of reactive macroglia. Small wisps of fibrils occur at random. Grouped ribosomes and dense bodies of unknown nature are present. Posterior columns, 45 d.p.o. \times 25,000.

FIGURE 21

This cell represents many found in the lesion after remyelination has begun. It typifies an intermediate between the first fibril-containing cells to appear in the lesion, reactive macroglia (see Fig. 20), and the highly fibrous cells seen in the late lesion (see Fig. 22). Here transversely cut fibrils (*f*) appear in a large, compact, U-shaped aggregate. At the same time, there is a high density of other cytoplasmic structures, notably ribosomes. These particles are mostly free but some are in association with membranes of endoplasmic reticulum. Portions of two centrioles (*c*) are present at this level. Below this cell is part of a sheath which contains some cytoplasm. Posterior columns, 30 d.p.o. \times 22,500.



of this study, taken together with recently reported autoradiographic observations on metabolic activity of glia, have allowed us to propose answers for these questions. These studies, therefore, shall now be briefly reviewed.

Koenig, in 1958, reported evidence for incorporation of orotic acid-6-C¹⁴ and adenine-6-C¹⁴ into DNA of normal adult cat central nervous tissue (26). In a subsequent autoradiographic study (27), he demonstrated the uptake of these precursors by RNase-resistant substances in glia of normal spinal cord white matter. This raised the possibility of ongoing mitosis in glial cells commonly believed not to undergo mitotic division in adult tissue (28). More recently, Hain, Rieke and Everett observed H³-thymidine incorporation into glial cells in various areas of mouse, guinea pig, rat, and monkey brain and concluded that adult glia do undergo mitosis (29). Smart has reported H³-thymidine labeling of small, round, dense glial nuclei in mouse brain (abstracted in 30); these cells were considered to be oligodendrocytes predominantly. Though the number of labeled cells was greater in juveniles than in adults, the presence of labeling in the adult nevertheless suggested continuing proliferation. Smart found the first labeling in oligodendrocytic nuclei, but if an adequate interval ensued after injecting the precursor, cells with larger nuclei of the astrocytic type were labeled, though less intensely. Barring DNA synthesis without mitosis, these findings suggest that in adult nervous tissue there may exist cells, presumably oligodendrocytes, which slowly proliferate, their progeny contributing to the stock of more highly differentiated cells, the fibrous and protoplasmic astrocytes. These studies, taken together with recent data on the substantial enzymatic activity (31) and oxygen consumption (32) of certain glia, suggest that the glia are an active and

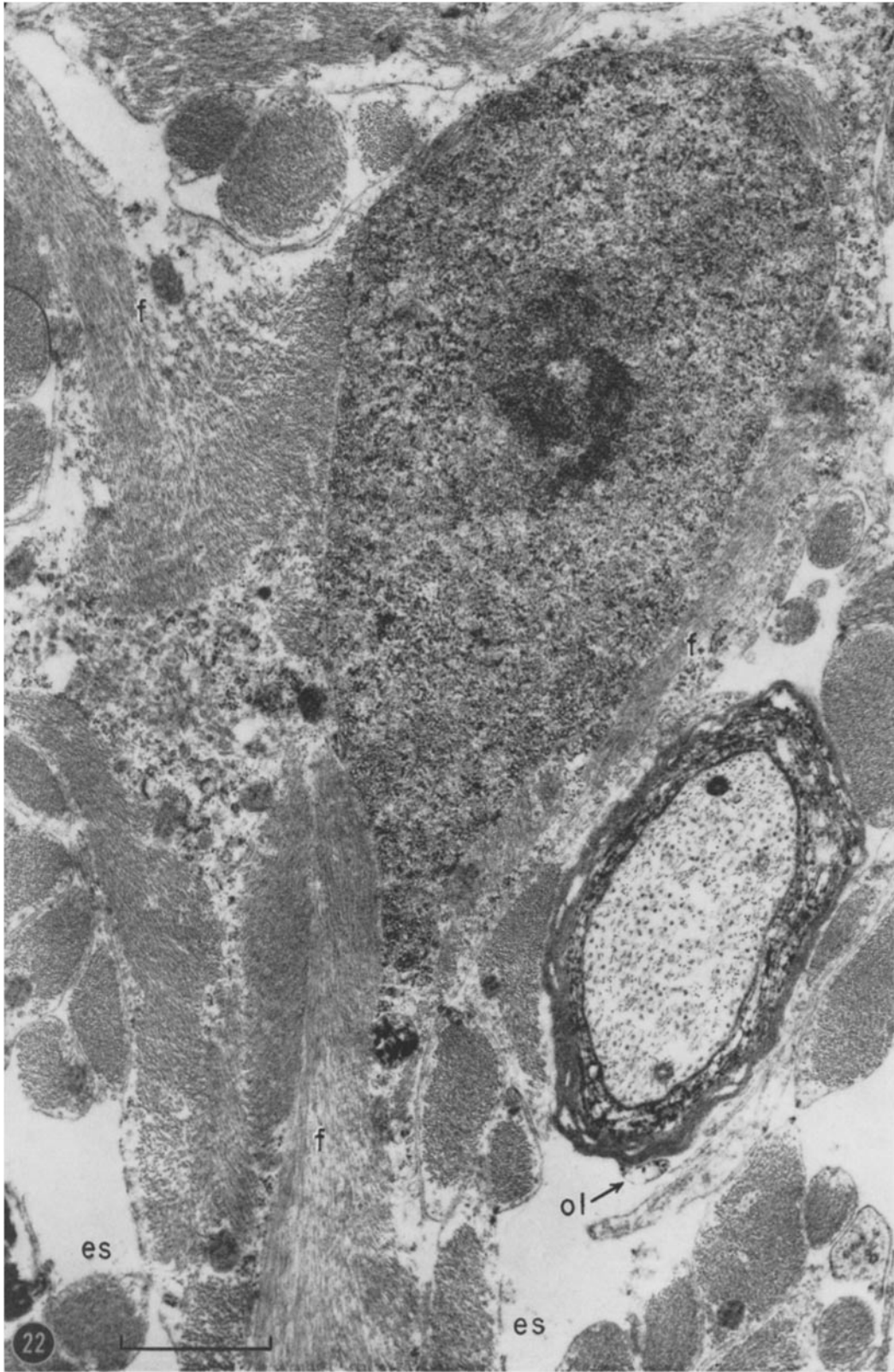
proliferating population rather than the static structural elements their name has so long implied.

We have collaborated with Koenig in an autoradiographic study of the c.s.f. exchange lesion (16). The data obtained corroborate these new concepts of glial activity. If, at 3 d.p.o., normal glial cells in the white matter surrounding the lesion are offered H³-thymidine by way of the subarachnoid space, they will incorporate this DNA precursor into RNase-resistant and DNase-extractable material within 1 hour. Of the glia, oligodendrocytes are labeled predominantly. If labeled thymidine is administered on the 3rd day and the animal allowed to live until the 14th day, the label is then found mainly in the reactive macroglia. These data suggest that the myelin-forming cells arise by mitosis of oligodendrocytes in adjacent undamaged tissue and migrate into the lesion. Studies of adenine-C¹⁴-labeled glial elements after RNase and DNase extractions confirm these observations.

To study RNA and protein synthesis, adenine-C¹⁴ and H³-glycine were injected intrathecally at 1, 3, 14, 30, 64, and 350 d.p.o. Normally these precursors are incorporated rapidly into spinal cord RNA and protein (27, 33). On the 1st and 3rd days after c.s.f. exchange, there is less uptake of labeled adenine in the lesion than in adjacent tissue. Incorporation into RNA is increased in adjacent tissue on the 3rd day. On days 14 and 30, there is intense labeling of reactive macroglia by adenine. Glycine incorporation in the lesion area is reduced at 1 and 3 days, rises at 14 days, and is greatly enhanced at 30 and 64 days after c.s.f. exchange. These experiments indicate that incorporation into RNA and protein is greater than normal during the 14 to 64 day period when much of the remyelination is being accomplished by reactive macroglia.

FIGURE 22

This cell, representative of many in the late lesion, contains a number of compact bundles of fibrils (*f*). Only a small patch of additional cytoplasmic structures is present at this level. Even in this ultrathin section, four processes are seen to emerge from the cell body. Outside the cell there are many small processes each one of which is nearly filled with fibrils. An ensheathed axon is in this field; the modified myelin is typical of a prenodal sheath in a transverse section. Inner myelin layers end in loops first, farthest from the node and, thus, the presence here of compact myelin externally is as expected. On this sheath exterior is a loop (*ol*). Extracellular space (*es*) is still present. Posterior columns, 460 d.p.o. × 23,000.



These data suggest the following sequence of events. Induction of the lesion stimulates mitosis of surviving oligodendrocytes in areas adjacent to the lesion. The resulting cells migrate into the lesion. As remyelination begins about the 20th day these cells, their dense cytoplasm streaked with fibrils, are the only macroglia in the lesion. On the 45th day, oligodendrocytes appear in the lesion along with an increasingly heterogeneous population of fibril-containing macroglia. The latter population ranges from reactive macroglia to cells resembling normal fibrous astrocytes but for their increased fibril-bundle content. These highly fibrillar cells are undoubtedly the scarring astrocytes common to many destructive neuropathological lesions.

Now another question of glial cell lineage arises. Do all the glial cell types present late in the lesion derive from reactive macroglia? We believe, because of the spectrum of fibril-containing cells seen, that the scarring fibrous astrocytes arise from reactive macroglia. The oligodendrocytes may also derive from reactive macroglia by the loss of fibrils and decrease in size but this cannot be established conclusively by our ultrastructural observations. The simplest explanation would be that reactive macroglia represent the embryonic cell type considered to be the progenitor of both astrocyte and oligodendrocyte—the spongioblast. After injury to adult tissue, this embryonic cell type may appear and form both astrocytes and

oligodendrocytes. Until the ultrastructural characteristics of the spongioblast are known this question must remain speculative. It can be stated, however, from evidence presented and reviewed here, that reactive macroglia derive from oligodendrocytes and can differentiate to become the scarring fibrous astrocyte.

It is not known whether a connection between the myelinogenic cell and the mature myelin sheath is maintained after myelination is completed. If a connection is maintained and it could be shown to link mature sheaths with a specific type of glial cell, then the question of glial cell lineage might be more completely answered. We have not been able to demonstrate a connection in the remyelinated lesion or normal cord; such a connection has not thus far been reported in any central nervous tissue. Maturana has discussed the difficulties involved in finding this connection (10).

The presence of fibrils within the cell which forms myelin was unexpected. Myelin formation has traditionally been associated with the oligodendrocyte (del Rio Hortega, 34; 35, among others; reviewed in 36), a cell which has been considered never to contain fibrils normally. Astrocytes as well as oligodendrocytes have been implicated in myelin formation by Alpers and Haymaker (36). Since they made no mention of a fibrillar component in these cells, it is presumed that they referred to protoplasmic astrocytes.

FIGURE 23

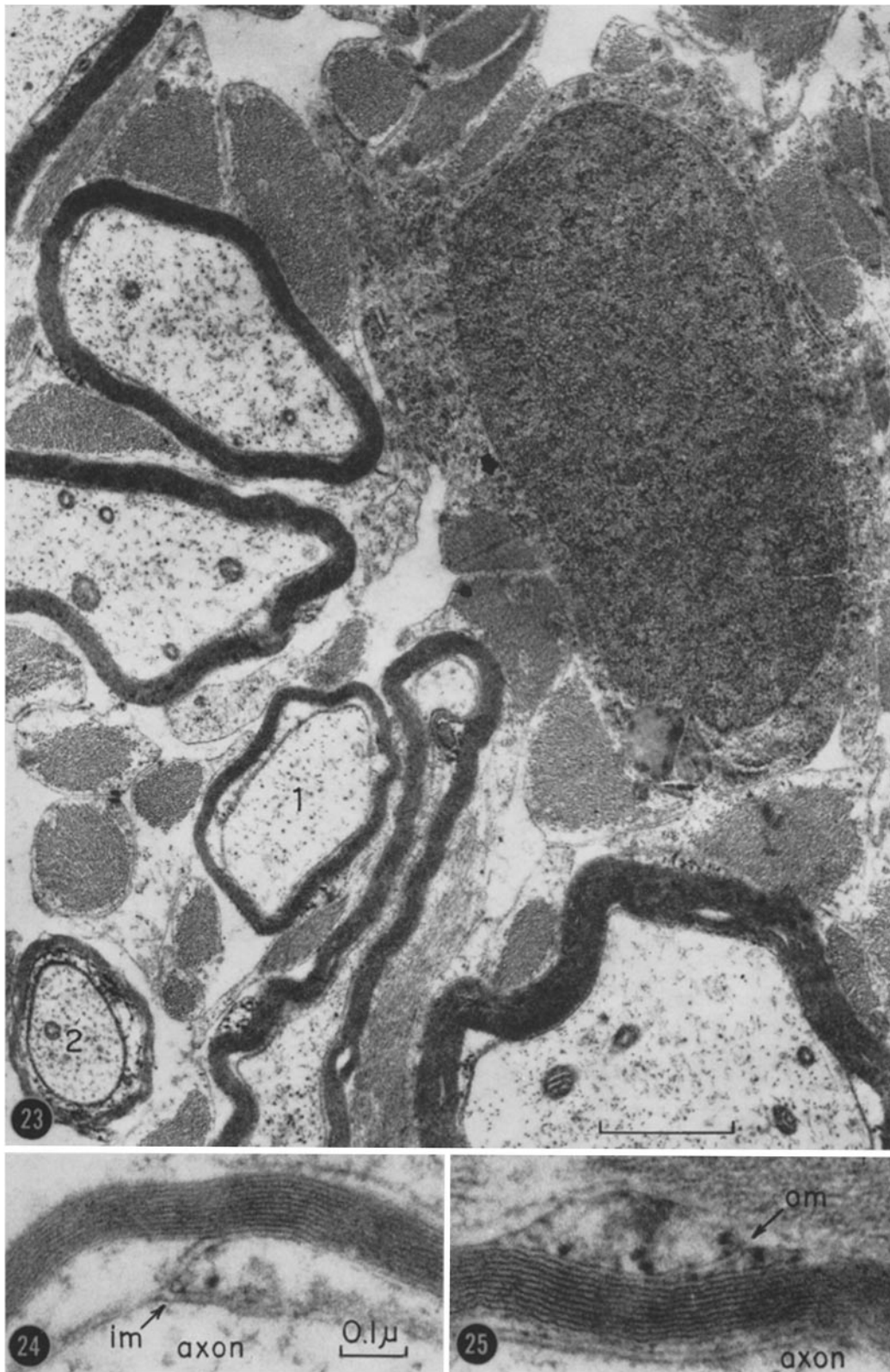
Oligodendrocytes such as this one are found in the lesion after remyelination is under way. In contrast to the cell pictured in Fig. 22, no fibrils are contained within the cytoplasm. At this level, ribosomes, free and associated with endoplasmic reticulum, are most prominent; usually, oriented granular endoplasmic reticulum, Golgi complex, and mitochondria are also evident. Processes of this cell type are short and stout. Each adjacent fibril bundle is bounded by its own plasma membrane and is not, therefore, part of this cell. All axons in the field are remyelinated. Except for decreased thickness and distorted profile, the myelin sheaths in the late lesion resemble those in comparable normal areas. The inner and outer mesaxons of the sheath around axon 1 appear enlarged in the next two figures. The sheath about axon 2 is near a node. Lateral columns, 460 d.p.o. $\times 20,500$.

FIGURE 24

An inner mesaxon (*im*) from a sheath in the late lesion pictured in Fig. 23., $\times 100,000$.

FIGURE 25

An outer mesaxon (*om*) observed in the late lesion, from a sheath included in Fig. 23. $\times 100,000$.



M. B. BUNGE, R. P. BUNGE, AND H. RIS *Remyelination in Experimental Lesion* 89

Although the electron microscopists Luse (6, 7) and De Robertis *et al.* (9) disagree on the mechanism for myelin formation in new-born mammals (see below), they concur that oligodendrocytes are responsible for myelin elaboration. They do not subscribe, however, to the same ultrastructural classification of macroglia. Fibrillar elements in the myelinogenic cells were not mentioned. Peters (12) suggests that the fibril-lacking oligodendrocytes may be the cells which form myelin in optic nerve. Recently, Ross *et al.* have shown that the cells responsible for myelination in explants of new-born rat cerebellum contain long, slender fibril bundles in addition to the usual cytoplasmic organelles (8). We have observed many fibril-containing cells in myelinating kitten cord but have not established that these are the cells responsible for myelination (41).

Scarring: As the lesion ages, more and more reactive macroglia exhibit larger, more compact fibril bundles and, thus, take on the appearance of scarring fibrous astrocytes. This change we believe parallels events in the formation of cerebral cicatrix as described by del Rio Hortega and Penfield (37). It was believed then, as it is generally believed now, that cicatrix-forming cells derive from surviving astrocytes which progress gradually through a swollen or hypertrophied state to the scarring, highly fibrillar form. That this hypertrophied cell might also form myelin was not considered for it was thought that remyelination could not occur. Correlates between reactive macroglia in the c.s.f. exchange lesion and reacting cell types in other neuropathological processes are discussed more fully in reference 2.

The amount of fibril formation described here in the late stage of the lesion conflicts with a previous report of absence of glial scarring (4). We know now that the amount of cicatrix formation depends on the age of the cat. Kittens develop little or no scar tissue; adult cats develop a great deal (5, 38). In the earlier studies, juvenile cats were often used while in the present investigation only fully adult cats were employed.

Myelin Formation

The following points are offered as proof that reactive macroglia form the new myelin in lesion cord. (a) Other than the engorged phagocytes, this is the only parenchymal cell type present, and fibril-containing processes are the only

processes visible when myelination begins. These are the processes which are contiguous with axons. The two normally occurring macroglial cell types, fibrous astrocytes and oligodendrocytes, are not found in the lesion until myelination is well under way. (b) A fibril-containing process is often seen completely encircling an axon and sometimes starting to spiral. (c) Autoradiographic studies indicate that this cell displays high levels of metabolic activity during myelin formation (16).

We believe that reactive macroglia form myelin in the following way. A process of this cell embraces an axon and begins to flatten. Either the leading ends of this process meet and pass by one another or the process completes one turn and starts a second, thus beginning a spiral. Because the process promptly flattens and the plasma membrane comes together, even during the first turn, a long spiralled inner mesaxon is not found. A very short mesaxon is formed, however, where the first turn is completed. On the exterior of the forming sheath, the outer end of the spiralling process is visible as a small amount of retained cytoplasm. We believe but have not proved that spiralling takes place by advance of the inner end of the spiral around the axon. This advance would continue to pull membrane from the macroglial cell process until the entire internode reached full thickness. Because many processes from the same cell encircle different axons, it appears that several axons may be myelinated by a single glial cell.

One major difference between this mechanism of spiral wrapping and that established for peripheral nerve is the amount of cytoplasm retained within the sheath during its formation and around the sheath throughout its adult state. In studies of chick (13) and mouse (15) peripheral myelogenesis, it has been observed that after an axon is surrounded by a Schwann cell and a mesaxon is thus formed, the mesaxon is elongated and spirals within the cytoplasm before the mesaxonal membranes come together to form compact myelin. This is in contrast to the central nervous system mechanism where fusion of membranes may occur even before the first turn of the spiral is completed. Thus, peripheral myelinogenesis occurs by membrane spiralling within cell cytoplasm whereas spinal cord remyelination is accomplished by spiral wrapping of a cell process. In peripheral nerve, Schwann cell cytoplasm is retained as a nearly complete collar both inside

and outside compact myelin, and both internal and external mesaxons are maintained and prominently visible throughout adulthood. In spinal cord remyelination, the external collar of glial cytoplasm about the sheath is either not formed or is largely lost so that only a single narrow ridge or two adjacent narrow ridges separated by a short mesaxon remain along the mature internode. Peripheral myelinogenesis has been discussed in detail by Robertson (39).

Despite these minor variations, the mechanism for myelin formation in the spinal cord lesion appears to be spiral wrapping of plasma membrane as in peripheral nerve, for the following reasons. (a) A glial process spiralled around an axon is occasionally detected; up to two turns have been noted. A clearly demonstrable spiral is not frequently seen because plasma membrane of the encircling process often fuses before the first turn is completed. The resulting myelin unit is difficult to preserve and is often disrupted or ruffled. (b) In small and adequately preserved sheaths, lamellae were counted at different points around the sheath and these counts were consistent with a spiral arrangement. (c) A typical sheath displays vestiges of spiral wrapping—an internal mesaxon and an outer mesaxon or its modified counterpart, an outer loop. That an external loop is formed from a mesaxon with the loss of sheath-encircling glial cytoplasm has been discussed at length by both Maturana (10) and Peters (11, Text-fig. 1, in particular). (d) Entrance of the inner mesaxon into the sheath and exit of the outer loop from the sheath is in the same direction as would be expected of two ends of a spiral. (e) Nodes are observed from the beginning of remyelination. Furthermore, the ending of a forming or fully formed sheath at a node is basically similar to sheath terminations at a peripheral node of Ranvier. All these observations favor a mechanism which is similar to the one proposed for peripheral nerve, namely, spiral deposition of plasma membrane.

Evidence for the spiral disposition of myelin lamellae in amphibian and mammalian optic nerve has recently been presented by Maturana (10) and Peters (11, 12). Their conclusion was based on lamellae counts in different regions of the same sheath and on both the configuration and orientation of membrane at the entrance into and exit from compact myelin. In toad and rat optic nerve, Peters found inner mesaxons and

outer loops. Maturana observed in frog optic nerve internal as well as external loops and suggested that the inner loop as well as the outer loop is a modified mesaxon. Nodes were observed; the sheath endings bordering them were largely similar to those in peripheral nerve. The basic similarity between nodes in mammalian peripheral and optic nerve has been reported by Uzman and Villegas (22). Peters observed, during myelination in toad and rat optic nerve, axons embedded within glial cell cytoplasm and, within this cytoplasm at times, a loosely spiralled mesaxon. This parallels myelinating peripheral nerve. Maturana and Peters conclude that but for the diminution in cytoplasm inside and outside the sheath, important similarities between optic and peripheral nerve strongly implicate a similar mode of myelin formation.

Thus, evidence for a spiral wrapping mechanism of myelinogenesis has been obtained for peripheral nerve in reptiles, birds, and mammals; in optic nerve of amphibians and mammals; and, here, in mammalian spinal cord. The spiral wrapping concept conflicts, however, with two previously published views on myelin formation in mammalian central nervous system. The first, suggested by Luse (6, 7) after study of mouse and rat brain and spinal cord, proposed that each sheath is formed as many abutting glial processes flatten and fuse together. A sheath, then, is constructed as a patchwork quilt of plasma membrane from many different processes. This conclusion is based upon her claim that during formation a sheath may display considerable variation in the number of lamellae in different regions and that many different processes abut on an axon along its length. Ross, Bornstein, and Lehrer (8) arrived at a similar conclusion after studying myelination in explants of new-born rat cerebellum.

In the remyelinating lesion, notable variation in the thickness of compact myelin was seen only rarely and, where this condition existed, unflattened segments of the process substituted for compact myelin. Thus, the variable number of lamellae in different regions of the same sheath resulted from the sustained presence of glial cytoplasm between the membranes rather than the presence of a different number of processes. Furthermore, in longitudinal sections we do not observe a series of flattening processes along an axon; a process continues unbroken and, even in a

forming sheath, the lamellae are continuous. Also notable is the finding that in longitudinal sections axons of large diameter display equal numbers of lamellae on opposite sides. It is difficult to exclude completely that processes other than the one spiralling may contribute to the forming sheath. Often early in remyelination a number of processes abut on an axon, forming occasionally a complex investment of flattened processes. This clustering of processes does not in itself, however, imply that more than one will contribute to the sheath. There may be competition between these processes, only one of them finally prevailing to form the entire sheath (around axon 1 in Fig. 4?). Sometimes an extraneous process is trapped between lamellae but it is probably retracted or expelled. Nodes are seen where sheaths of only two or three layers terminate but these endings are often asymmetrical and display but a few poorly organized loops. If such an area were cut obliquely, it would appear as if a number of processes were clustered on one side of the axon, all fusing to form myelin lamellae. Dense particles characteristic of loops are generally present in such an area, however, and thus allow identification as a sheath ending.

Still another theory of central myelinogenesis has been presented by De Robertis, Gerschenfeld, and Wald (9). These authors concluded from study of kitten brain and spinal cord that myelin is formed by alignment and subsequent fusion of membranous fragments and vesicles within glial cytoplasm surrounding the axon. Thus, myelin is formed from a coalescence of cytoplasmic membranes rather than from plasma membrane. These workers observed no external loops and only rarely an inner mesaxon. We think that the membranous fragments supposedly within glial cytoplasm may be membranes of axons or glial processes broken during preparation of the tissue. In the remyelinating lesion, the glial cytoplasm

adjacent to axons or thickening sheaths contains no similarly aligned membranous fragments and vesicles. Indeed, the forming sheath is generally not embedded in glial cytoplasm during any stage of its formation.

The contradictions in these various reports might be explained in part by different mechanisms of myelin formation in different parts of the central nervous system and/or by different mechanisms for the first myelination and remyelination. With evidence for spiral wrapping of a glial cell process available from amphibian and mammalian optic nerve and new-born, normal adult, and remyelinating adult mammalian spinal cord, we believe the above explanations to be unlikely. The alternate theories cannot explain the two ends of the spiral, the internal mesaxon and the outer loop, consistently observed in these areas. Nor would they seem to explain the development of nodes in these areas. Additional electron microscopic investigations indicating the presence of nodes in cortex (rat, 40), corpus callosum (cat, 41), diencephalon (frog, 42), and medulla (mouse, 43) supplement the light microscopic literature (44) and, thus, further support the spiral wrapping concept.

This study was supported by Grant B-1661 from the National Institute of Neurological Diseases and Blindness, United States Public Health Service; the Research Committee of the University of Wisconsin, from funds contributed by the Wisconsin Alumni Research Foundation; and the Medical School Research Committee and Department of Neurology at the University of Wisconsin. An abstract of this investigation has been published (1).

This investigation was completed during tenure of postdoctoral fellowships. Dr. Mary B. Bunge's fellowship was from the National Institute of Neurological Diseases and Blindness, United States Public Health Service; Dr. Richard P. Bunge's from the National Multiple Sclerosis Society.

Received for publication, February 14, 1961.

LITERATURE CITED

1. BUNGE, M. B., Ultrastructural study of myelin breakdown and reformation in an experimentally induced lesion in adult cat spinal cord, *Dissertation Abstr.*, 1960, **21**, 705.
2. BUNGE, R. P., BUNGE, M. B., and RIS, H., Electron microscopic study of demyelination in an experimentally induced lesion in adult cat spinal cord, *J. Biophysic. and Biochem. Cytol.*, 1960, **7**, 685.
3. MCALPINE, D., COMPSTON, N. D., and LUMSDEN, C. E., *Multiple Sclerosis*, London, E. & S. Livingston, Ltd., 1955.
4. BUNGE, R. P., and SETTLAGE, P. H., Neurological lesions in cats following cerebrospinal fluid manipulation, *J. Neuropath. and Exp. Neurol.*, 1957, **16**, 471.
5. BUNGE, R. P., Regenerative phenomena in the feline spinal cord in late stages of lesions in-

- flicted by cerebrospinal fluid manipulation, *Anat. Rec.*, 1958, **130**, 279.
6. LUSE, S. A., Formation of myelin in the central nervous system of mice and rats, as studied with the electron microscope, *J. Biophysic. and Biochem. Cytol.*, 1956, **2**, 777.
 7. LUSE, S. A., The fine structure of the morphogenesis of myelin, in *The Biology of Myelin*, (S. R. Korey, editor), New York, Paul B. Hoeber, Inc., 1959, 59.
 8. ROSS, L. L., BORNSTEIN, M., and LEHRER, G., Electron microscopic observations on myelin sheath formation in tissue cultures of developing rat cerebellum, *Anat. Rec.*, 1960, **136**, 268.
 9. DE ROBERTIS, E., GERSCHENFELD, H. M., and WALD, F., Cellular mechanism of myelination in the central nervous system, *J. Biophysic. and Biochem. Cytol.*, 1958, **4**, 651.
 10. MATURANA, H. R., The fine anatomy of the optic nerve of Anurans—an electron microscope study, *J. Biophysic. and Biochem. Cytol.*, 1960, **7**, 107.
 11. PETERS, A., The structure of myelin sheaths in the central nervous system of *Xenopus laevis* (Daudin), *J. Biophysic. and Biochem. Cytol.*, 1960, **7**, 121.
 12. PETERS, A., The formation and structure of myelin sheaths in the central nervous system, *J. Biophysic. and Biochem. Cytol.*, 1960, **8**, 431.
 13. GEREN, B. B., The formation from the Schwann cell surface of myelin in peripheral nerves of chick embryos, *Exp. Cell Research*, 1954, **7**, 558.
 14. ROBERTSON, J. D., The ultrastructure of adult vertebrate peripheral myelinated nerve fibers in relation to myelinogenesis, *J. Biophysic. and Biochem. Cytol.*, 1955, **1**, 271.
 15. ROBERTSON, J. D., Structural alteration in nerve fibers produced by hypotonic and hypertonic solutions, *J. Biophysic. and Biochem. Cytol.*, 1958, **4**, 349.
 16. KOENIG, H., BUNGE, M. B., and BUNGE, R. P., Nucleic acid and protein metabolism during experimental demyelination and remyelination. To be submitted.
 17. LUFT, J. H., Permanganate—A new fixative for electron microscopy, *J. Biophysic. and Biochem. Cytol.*, 1956, **2**, 799.
 18. LUFT, J. H., Improvements in epoxy resin embedding methods, *J. Biophysic. and Biochem. Cytol.*, 1961, **9**, 409.
 19. ROBERTSON, J. D., New observations on the ultrastructure of the membranes of frog peripheral nerve fibers, *J. Biophysic. and Biochem. Cytol.*, 1957, **3**, 1043.
 20. UZMAN, B. G., and NOGUEIRA-GRAF, G., Electron microscope studies of the formation of nodes of Ranvier in mouse sciatic nerves, *J. Biophysic. and Biochem. Cytol.*, 1957, **3**, 589.
 21. ROBERTSON, J. D., Preliminary observations on the ultrastructure of nodes of Ranvier, *Z. Zellforsch.*, 1959, **50**, 553.
 22. UZMAN, B. G., and VILLEGAS, G. M., A comparison of nodes of Ranvier in sciatic nerves with node-like structures in optic nerves of the mouse, *J. Biophysic. and Biochem. Cytol.*, 1960, **7**, 761.
 23. GLEES, P., Neuroglia, Springfield, Illinois, Charles C. Thomas, 1955.
 24. PORTER, K. R., Electron microscopy of basophilic components of cytoplasm, *J. Histochem. and Cytochem.*, 1954, **2**, 346.
 25. PALADE, G. E., A small particulate component of the cytoplasm, *J. Biophysic. and Biochem. Cytol.*, 1955, **1**, 59.
 26. KOENIG, H., Incorporation of adenine-8-C-14 and orotic-6-C-14 acid into nucleic acids of the feline neuraxis, *Proc. Soc. Exp. Biol. and Med.*, 1958, **97**, 255.
 27. KOENIG, H., An autoradiographic study of nucleic acid and protein turnover in the mammalian neuraxis, *J. Biophysic. and Biochem. Cytol.*, 1958, **4**, 785.
 28. ADAMS, R. D., Implications of the biology of the neuroglia and microglia cells for clinical neuropathology, in *Biology of Neuroglia*, (W. F. Windle, editor), Springfield, Illinois, Charles C. Thomas, 1958, 245.
 29. HAIN, R. F., RIEKE, W. O., and EVERETT, N. B., Evidence of mitosis in neuroglia as revealed by radioautography employing tritiated thymidine, *J. Neuropathol. and Exp. Neurol.*, 1960, **19**, 147.
 30. SMART, I., DNA synthesis in the brain of juvenile and adult white mice, *Anat. Rec.*, 1960, **136**, 279.
 31. HYDEN, H., Biochemical changes in glial cells and nerve cells at varying activity, in *Biochemistry of the Central Nervous System*, (F. Brücke, editor), New York, Pergamon Press, 1959, 64.
 32. KOREY, S. R., and ORCHEN, M., Relative respiration of neuronal and glial cells, *J. Neurochem.*, 1959, **3**, 277.
 33. KOENIG, H., A radioisotopic study of nucleic acid and protein turnover in white matter of the mammalian neural axis, in *Progress in Neurobiology*, (S. R. Korey, editor), New York, Paul B. Hoeber, Inc., 1959, **4**, 241.
 34. DEL RIO HORTEGA, P., Tercera aportación al conocimiento morfológico e interpretación funcional de la oligodendroglia, *Mem. Soc. esp. Hist. nat. Madrid*, 1928, **14**, 5.
 35. MORRISON, L. R., The role of oligodendroglia in

- myelinogenesis, *Trans. Am. Neurol. Assoc.*, 1931, **163**, 444.
36. ALPERS, B. J., and HAYMAKER, W., The participation of the neuroglia in the formation of myelin in the prenatal infantile brain, *Brain*, 1934, **57**, 195.
 37. DEL RIO HORTEGA, P., and PENFIELD, W., Cerebral cicatrix. The reaction of neuroglia and microglia to brain wounds, *Bull. Johns Hopkins Hosp.*, 1927, **41**, 278.
 38. BUNGE, R. P., unpublished data.
 39. ROBERTSON, J. D., The ultrastructure of cell membranes and their derivatives, *Biochem. Soc. Symposia No. 16*, 1959, 3.
 40. GRAY, E. G., Axo-somatic and axo-dendritic synapses of the cerebral cortex: an electron microscope study, *J. Anat.*, 1959, **93**, 420.
 41. BUNGE, M. B., and BUNGE, R. P., Unpublished data.
 42. METUZALS, J., Ultrastructure of myelinated nerve fibers and nodes of Ranvier in the central nervous system of the frog, European Regional Conference on Electron Microscopy, 1960, Delft, Nederlandse Vereniging Voor Electronenmicroscopie, 1961.
 43. LUSE, S. A., Histochemical implications of electron microscopy of the central nervous system, *J. Histochem. and Cytochem.*, 1960, **8**, 398.
 44. LEHMANN, H. J., Die Nervenfaser, in *Handbuch der Mikroskopischen Anatomie des Menschen*, (W. von Möllendorff, founder), **4**, part 4, Nervensystem, Berlin, Springer-Verlag, 1959, 620.