

## STAINING METHODS APPLICABLE TO SECTIONS OF OSMIUM-FIXED TISSUE FOR LIGHT MICROSCOPY

BRYCE L. MUNGER. From the Armed Forces Institute of Pathology, Washington, D. C. Dr. Munger's present address is Department of Anatomy, Washington University School of Medicine, St. Louis, Missouri

Basophilic and eosinophilic tissue components are difficult to demonstrate by stains commonly used in light microscopy after osmium tetroxide fixation. Baker (2) states that "if only chromatin were left in a state in which it could be differentially stained without difficulty, this fixative would be universally recognized as superior to all others" for light microscopy. The difficulty encountered in staining tissues fixed in osmium tetroxide for light microscopic study limits the direct comparison by light and electron microscopy of the same tissue. In the past several years, the various methods which have been applied to sections of osmium-fixed tissue include the following: routine hematoxylin and eosin (6), Feulgen reaction (8), galloycyanin chrome alum (12, 16), thionine (17), ammoniacal silver (6), Verhoeff's elastica stain (6), aldehyde fuchsin for pancreatic islets (7), the Hale colloidal iron stain (12); and methylene blue has been used as a stain for epoxy resin-embedded tissue (15). None of these methods provide adequate visualization of basophilic and eosinophilic structures. The present report describes a method for obtaining specific nuclear and cytoplasmic basophilia combined with eosinophilic staining by means of Ehrlich's hematoxylin and phloxine (H & P) stain, and modifications of other staining methods applicable to sections of tissue fixed in osmium tetroxide and prepared for electron microscopic study.

### MATERIALS AND METHODS

#### *Preparation of Sections*

The routine method of tissue preparation consisted of fixation for 1 hour in Dalton's chrome-osmium fixative (4) and embedding in methacrylate. Identical results are obtained with buffered osmium tetroxide as a fixative (14), and with either fixation followed by embedding in Epon 812 (10). Sections 0.5 to 2  $\mu$  thick were cut on a Porter-Blum microtome with glass knives, floated onto glass slides with 10 per cent acetone, flattened by warming *gently*, and dried.

Sections of Epon-embedded tissue were also cut with glass knives and flattened on slides as described above. Removal of the plastic with sodium methoxide (11) has been found to produce greatly altered

staining properties, and best results are obtained when the plastic is not removed. The sections are nonetheless placed in xylene, which seems to soften the plastic and permits better staining.

#### A. *The H & P Stain (Ehrlich's Hematoxylin and Phloxine)*:

1. Place in xylene for 1 hour (to remove plastic).
2. Rinse in descending strengths (absolute, 95 per cent, 80 per cent) of ethyl alcohol to distilled water.
3. Leave in peracetic acid reagent (9)—1 hour.
4. Wash in tap water—2 minutes.
5. Stain with Ehrlich's hematoxylin (9)—20 to 30 minutes.
6. Differentiate—wash in tap water for light differentiation, rinse in 0.5 per cent acid alcohol for stronger differentiation. Control microscopically.
7. "Blue" sections in lithium carbonate water (5 drops of a saturated solution in a Coplin jar of water).
8. Stain with 0.2 per cent or 0.5 per cent aqueous phloxine B (National Aniline Division, Allied Chemical & Dye Corp., New York City); intensity of staining depends on concentration used.
9. Drain off excess and let sections dry completely.
10. Rinse in absolute alcohol until no more color comes out. (Can rinse in 95 per cent alcohol for less intense staining.)
11. Clear in two changes of xylene.
12. Mount in Permount.

Nuclear chromatin, nucleoli, and cytoplasmic areas of basophilia are stained shades of blue-black (Figs. 1, 2 *a* and *b*, and 3). Basement membranes, collagen, red cells, background cytoplasm, zymogen granules of acinar pancreas, and alpha granules of endocrine pancreas are stained various shades of red. Glycogen-rich areas of hepatic parenchyma appear gray (unstained) (Fig. 3). Oxidants other than peracetic acid reagent have been tried but are less satisfactory: hydrogen peroxide abolishes cytoplasmic basophilia and makes nuclear staining very difficult; potassium permanganate results in less crisp nuclear staining; performic acid produces identical results but must be made fresh each time it is used. Any hematoxylin will stain following peracetic acid, including Harris's, Weigert's, chrome alum hematoxylin, and iron hematoxylin (9). The length of time in hematoxylin and the degree of differentiation markedly affect the "crispness" of nuclear staining and must be controlled by trial and error. Eosin will stain only faintly in the above procedure.

*B. Aldehyde Fuchsin Stain for Elastica and Pancreatic Islet Beta Cells:*

1. Perform steps 1 through 4 in "A."
5. Place in aldehyde fuchsin (5) for 10 to 60 minutes. (Stain with microscopic control by rinsing in 95 per cent alcohol.)
6. Rinse in 95 per cent alcohol.
7. Rinse in distilled water.
8. Rinse in peracetic acid reagent— $\frac{1}{2}$  to 1 minute.
9. Wash in tap water—2 minutes.
10. Stain with Ehrlich's hematoxylin—20 to 30 minutes.
11. Differentiate in 1 per cent acid alcohol—a few dips; control microscopically.
12. "Blue" in lithium carbonate water.
13. Counterstain as desired; a combination of orange G and light green SF yellowish is useful (5).
14. Rinse in 95 per cent alcohol.
15. Dehydrate, clear, and mount.

Beta cells of pancreatic islets, elastica of arteries and dermis (Fig. 5), and a zone surrounding cells of squamous epithelium are stained shades of purple; nuclei are gray; and background cytoplasm orange. The peracetic acid reagent used following aldehyde fuchsin staining makes nuclear staining much easier.

*C. Periodic Acid-Schiff Stain for Glycogen and Basement Membranes:*

1. Perform steps 1 and 2 in "A."
3. Place in 0.5 per cent periodic acid for 10 minutes.
4. Wash in tap water.
5. Place in Schiff's reagent (9) for 30 minutes.
6. Wash in tap water.
7. Rinse in peracetic acid reagent—a few dips.
8. Perform steps 4 through 7 in "A."
12. Dehydrate, clear, and mount.

Glycogen in cells (Fig. 4) and basement membranes (Fig. 6) are stained intensely with the above method, and nuclei are a crisp blue-black. The peracetic acid-reagent rinse following the Schiff-reagent step permits nuclear staining with ease.

*D. Trichrome Stain for Secretory Granules of Pancreatic Islets:*

1. Perform steps 1 through 4 in "A."
5. Place in 0.5 per cent potassium permanganate for 5 minutes.
6. Wash in water—2 minutes.
7. Bleach in 2 per cent potassium metabisulfite.
8. Wash in water—2 minutes.
9. Place in aldehyde thionine (thionine, 0.5 gm; 70 per cent ethanol, 91.5 ml; paraldehyde, 7.5 ml; HCl (conc.), 1 ml; (13), (Chroma stain, C.I. #52000, Roboz Surgical Instrument Company, Washington, D. C.))—overnight. Best results are obtained with solutions 3 to 8 weeks old.

10. Rinse in 95 per cent alcohol.

11. Perform steps 5 through 12 in "A."

Beta cell granules are stained clear, deep blue (Fig. 7), alpha granules are bright red (Fig. 8), and C cells and acinar cytoplasm are pale gray-pink. Nuclei are a pale but crisp blue. Some staining of zymogen granules by the aldehyde thionine is usually seen.

In all of the above methods, when applied to tissue embedded in epoxy resin, the length of time in the staining solutions must be increased two to five times. Washes and rinses can be maintained to the given time periods, but lithium carbonate must be avoided, or sections wash off the slides; sections should be "blued" in running tap water. The optical quality of epoxy resin-embedded tissue is generally inferior to that of methacrylate, since the plastic can be removed following methacrylate embedding.

## DISCUSSION

Peracetic acid reagent (9) used prior to hematoxylin staining overcomes the difficulty encountered in demonstrating basophilic structures following osmium fixation. Osmium has been considered unreactive with respect to nucleic acids (1), but it could react by producing an unblackened but bound form of osmium (3, 20). Hematoxylin staining is thought to be dependent on ionic binding of the hematoxylin lake to phosphate groups of the nucleic acids (2), and following treatment with osmium, tissues react poorly with hematoxylin (2, 6). Suggestive evidence has been described by Wigglesworth (19) for a binding of osmium to basophilic structures. Assuming that osmium does react with nucleic acids in some manner, peracetic acid reagent most likely solubilizes the bound osmium, liberating stainable phosphate groups.

Peracetic acid following PAS, aldehyde fuchsin, and aldehyde thionine improves nuclear staining, and these three stains depend on a Schiff base for the staining reaction (18). Some binding of these Schiff bases to nucleic acids during the staining reaction would impair hematoxylin counter-staining, and peracetic acid could liberate these blocked reactive groups.

The methods described are thus purely empirical, for the chemistry of the reactions of osmium tetroxide or staining solutions with tissue components is poorly understood. The results of the methods do enable specific staining of cell components for correlation with electron microscopic studies of the same tissue. The advantage of using

Photographs are taken from osmium-fixed, methacrylate-embedded sections cut at 0.5 to 2 $\mu$ , except Figure 2*b* which is from Epon-embedded tissue.

FIGURE 1

H & P-stained rabbit pancreas. A small islet (*I*) is surrounded by acinar tissue. The well-defined nuclei and areas of cytoplasmic basophilia around the zymogen granules are shades of blue in the microscope. Zymogen granules and granules of alpha cells (arrow) are deep red.  $\times 350$ .

FIGURE 2*a*

H & P-stained human pancreas. Zymogen granules (arrow) appear black in this micrograph, photographed with a green filter to intensify the areas of red coloration. Nuclear chromatin within the nuclei (*n*) appears as a delicate net.  $\times 1,500$ .

FIGURE 2*b*

H & P-stained rabbit pancreas, Epon-embedded. Zymogen granules (arrow) are less "crisp" in outline than in Fig. 2*a*.  $\times 1,200$ .

FIGURE 3

H & P-stained rabbit liver. The liver cells are easily demarcated from areas of sinusoid (*s*). A small portal area with portal vein (*v*) and bile duct (*b*) is present in the section. The smallest connections of the bile ducts to the liver plates, the cholangioles, (arrow), can be easily discerned. Unstained areas in the cytoplasm of the hepatic cells represent areas of glycogen accumulation. See Fig. 4.  $\times 350$ .

FIGURE 4

PAS-stained rabbit liver, counter-stained with Ehrlich's hematoxylin. Magenta-colored areas in the tissue appear black in the photomicrograph and represent glycogen-rich areas (*g*). Surrounding the sinusoid (*s*) is a distinct layer of cytoplasm of the lining cells (arrow). The nucleus (*n*) is distinctly colored. A distinct nucleolus can be seen.  $\times 1,500$ .

FIGURE 5

Aldehyde fuchsin-stained human skin, counterstained with Ehrlich's hematoxylin and orange G. The small ramifications of the elastica within the dermis that penetrate into the dermal papillae (arrows) are purple as seen in the microscope and are black in the micrograph. Surrounding the squamous epithelial cells is a faint purple line (*d*) which most likely represents areas of cell-to-cell contact.  $\times 350$ .

FIGURE 6

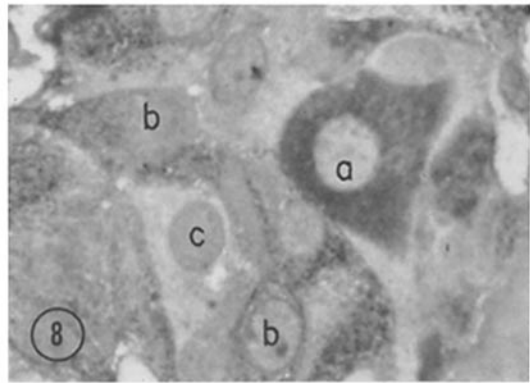
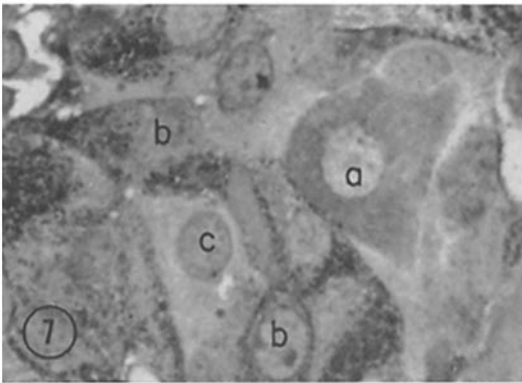
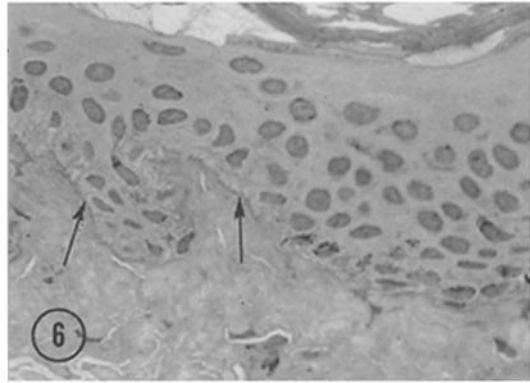
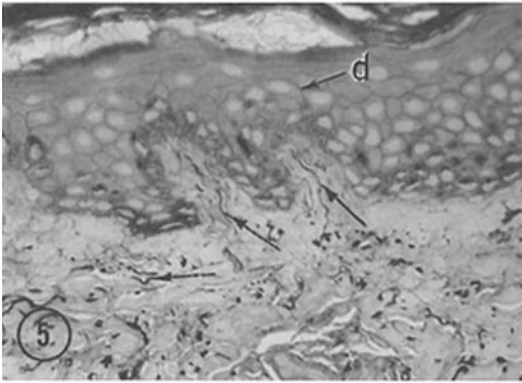
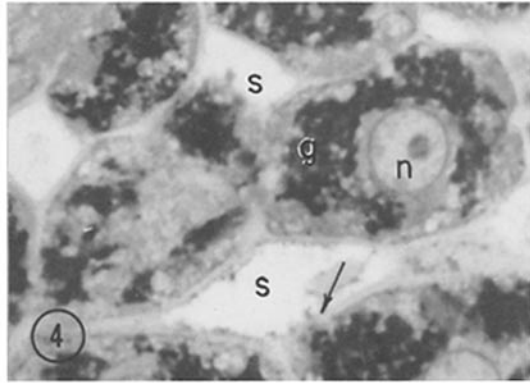
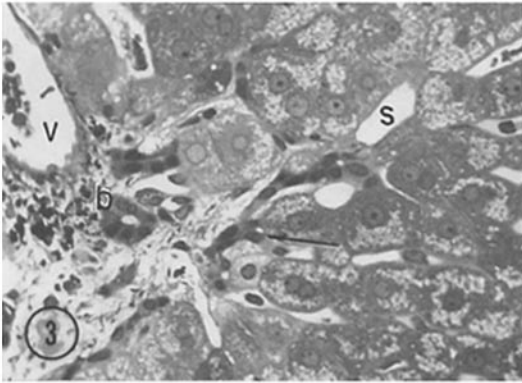
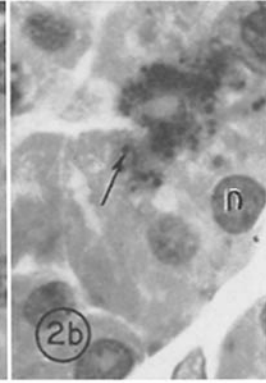
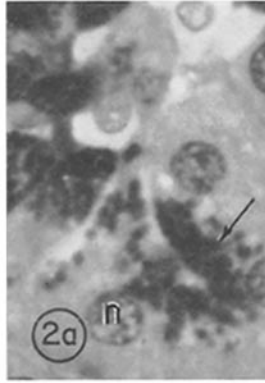
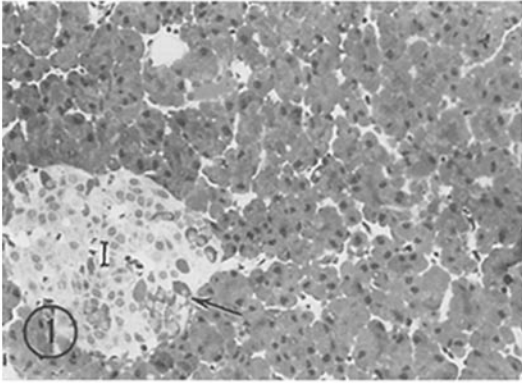
PAS-stained human skin, counterstained with Ehrlich's hematoxylin. At the junction of the epidermis and dermis is an irregular gray line, appearing red in the microscope, representing the basement membrane of the epidermis (arrows).  $\times 480$ .

FIGURE 7

Trichrome-stained rabbit pancreatic islet, photographed with a yellow filter to accentuate the blue color of the beta granules. In the cytoplasm of beta cells (*b*) are numerous black granules, colored blue in the microscope. Alpha cell cytoplasm (*a*) is light gray. (Labels are placed in appropriate nuclei.) Cells lacking specific-staining granules are interpreted as C cells (*c*).  $\times 1,500$ .

FIGURE 8

Same section as in Fig. 7, photographed with a green filter to intensify the red coloration. The cytoplasmic granules in alpha cells (*a*) appear darker than in beta cells (*b*). Density of C cells (*c*) remains relatively the same.  $\times 1,500$ .



methacrylate-embedded tissue cut at 0.5 to 2  $\mu$  for light microscopy is obvious in that the cellular preservation is superior in methacrylate as compared to paraffin, and the resulting greater resolution of cytoplasmic detail can be directly correlated with the ultrastructure of the tissue.

#### SUMMARY

Methods are described for staining sections of osmium-fixed, methacrylate- or epoxy resin-embedded tissue 0.5 to 2  $\mu$  thick for light microscopic study. Included are methods for basophilic and eosinophilic components (the H & P stain), the PAS stain with hematoxylin counterstain, the aldehyde fuchsin stain for elastica and a trichrome stain for endocrine cytoplasmic secretory granules. All of these methods depend on treatment of the sections prior to staining with peracetic acid reagent. Sections embedded in methacrylate are optically superior to those embedded in epoxy resin, for the plastic can be removed prior to staining.

This study was supported in part by a grant (E-201) from the American Cancer Society.

Received for publication, June 21, 1961.

#### REFERENCES

- BAHR, G. F., Osmium tetroxide and ruthenium tetroxide and their reactions with biologically important substances, *Exp. Cell Research*, 1954, 7, 475.
- BAKER, J. R., *Cytological Technique*, New York, John Wiley and Sons, Inc., 1950.
- CRIEGEE, R., Osmiumsäure-ester als Zwischenprodukte bei Oxydationen, *Ann. Chem.*, 1936, 522, 75.
- DALTON, A. J., A chrome-osmium fixative for electron microscopy, *Anat. Rec.*, 1955, 121, 281.
- HALMI, N. S., Differentiation of two types of basophils in the adenohypophysis of the rat and mouse, *Stain Techn.*, 1952, 27, 61.
- HOUCK, C. E., and DEMPSEY, E. W., Cytological staining procedures applicable to methacrylate-embedded tissues, *Stain Techn.*, 1954, 29, 207.
- LACY, P. E., Electron microscopic identification of different cell types in the islets of Langerhans of the guinea pig, rat, rabbit and dog, *Anat. Rec.*, 1957, 128, 255.
- LEUCHTENBERGER, C., DOOLIN, P. F., and KUTSAKIS, A. H., Buffered osmium tetroxide ( $\text{OsO}_4$ ) fixation for cytological and Feulgen microspectrophotometric studies of human rectal polyps, *J. Biophysic. and Biochem. Cytol.*, 1955, 1, 385.
- LILLIE, R. D., *Histopathologic Technic and Practical Histochemistry*, New York, McGraw-Hill Book Co., 1954.
- LUFTH, J. H., personal communication.
- MAYOR, H. D., HAMPTON, J. C., and ROSARIO, B., A simple method for removing the resin from epoxy-embedded tissue, *J. Biophysic. and Biochem. Cytol.*, 1961, 9, 909.
- MUNGER, B. L., The ultrastructure and histophysiology of human eccrine sweat glands, *J. Biophysic. and Biochem. Cytol.*, 1961, 11, 385.
- PAGET, G. E., Aldehyde-thionin: A stain having similar properties to aldehyde fuchsin, *Stain Techn.*, 1959, 34, 223.
- PALADE, G. E., A study of fixation for electron microscopy, *J. Exp. Med.*, 1952, 95, 285.
- RICHARDSON, K. C., JARETT, L., and FINKE, E. H., Embedding in epoxy resins for ultrathin sectioning in electron microscopy, *Stain Techn.*, 1960, 35, 313.
- RUNGE, W. J., VERNIER, R. L., and HARTMANN, J. F., A staining method for sections of osmium-fixed methacrylate-embedded tissue, *J. Biophysic. and Biochem. Cytol.*, 1958, 4, 327.
- SMITH, S. W., "Reticular" and "areticular" Nissl bodies in sympathetic neurons of a lizard, *J. Biophysic. and Biochem. Cytol.*, 1959, 6, 77.
- SPICER, S. S., and MEYER, D. B., Histochemical differentiation of acid mucopolysaccharides by means of combined aldehyde fuchsin-alcian blue staining, *Amer. J. Clin. Path.*, 1960, 33, 453.
- WIGGLESWORTH, V. B., The use of osmium in the fixation and staining of tissues, *Proc. Roy. Soc. London, Series B*, 1957, 147, 185.
- WOLMAN, M., The reaction of osmium tetroxide with tissue components, *Exp. Cell Research*, 1957, 12, 231.