

HISTOCHEMICAL STUDIES ON MUCOPROTEINS IN NERVE CELLS OF THE DOG*

By NORMAN M. SULKIN, Ph.D.

(From the Department of Anatomy, Bowman Gray School of Medicine of Wake Forest College, Winston-Salem, North Carolina)

PLATES 123 TO 127

(Received for publication, May 9, 1955)

INTRODUCTION

The occurrence of a periodic acid-Schiff-positive substance, which is neither glycogen nor lipofuscin, in the cytoplasm of nerve cells in the senile dog was first demonstrated by Sulkin and Kuntz (1). More recently, the nature and distribution of this substance was studied by the present investigator (2) who presented data indicating that neurons in the peripheral nervous system of the senile dog contain a periodic acid-Schiff-positive mucoprotein present in the form of a non-granular cytoplasmic deposition. This was true except in one senile dog in which the PAS-positive mucoprotein was observed in the form of evenly distributed granules in the cytoplasm. The opinion was presented that the granular form of mucoprotein represented an early stage in the accumulation of the cytoplasmic mucoprotein during the process of aging and the non-granular deposition was brought about by the coalescence of the accumulating mucoprotein granules. In order to support this view, it would be necessary to obtain a large series of dogs in the age range of 9 years to 12 years in the belief that in such an age group it might be possible to observe other instances in which the mucoprotein would be in the form of discrete granules. The success of such an undertaking would be very unlikely since healthy dogs in this particular age group are extremely difficult to obtain. Previous studies on human material have indicated that marked alterations, especially in autonomic ganglion cells, are associated with a large variety of pathologic conditions, including infectious diseases, malignant diseases, cardiovascular diseases, and nutritional deficiencies. (1, 3, 4).

Since the earlier publications new methods for the detection of mucoproteins have been introduced which appear to be more sensitive than the conventional periodic acid-Schiff technic.

It has recently been reported by Kramer and Windrum (5) that, in a large variety of tissues that were studied, PAS-positive mucoproteins could be demon-

* This investigation was supported by a research grant (B-342) from the National Institutes of Health, Public Health Service.

strated by their metachromatic staining properties if the tissue sections were treated with concentrated sulfuric acid prior to staining with azure A or toluidine blue. According to these investigators, the treatment resulted in esterification of the carbohydrates which then acquired staining properties similar to those of acid conjugated mucopolysaccharides.

It has furthermore been reported by Scott and Clayton (6) that the presence of various mucopolysaccharides can be demonstrated with the aid of the aldehyde-fuchsin stain, with and without prior oxidation.

The introduction of these methods suggested the feasibility of reinvestigating the mucoproteins in the nerve cells of the dog using these and other procedures in the belief that more sensitive tests might give not only better information about the amounts of material present but might also supply additional data concerning the distribution of these substances in various parts of the nervous system and the form that it takes within the cells.

Materials and Methods

The material used in this study has included portions of brain, spinal cord, autonomic ganglia, and sensory ganglia from a series of 48 dogs ranging from 2 weeks to 19 years of age.

The tissues were removed under neumbutal anesthesia or immediately after death and were fixed in 10 per cent formalin or in Rossman's fluid (90 volumes of 100 per cent alcohol saturated with picric acid and 10 volumes of formalin). Following dehydration, embedding, and sectioning of the tissues in the usual manner glycogen was removed from the sections by placing them in a 37°C. incubator for 1 hour in a 1 per cent solution of diastase prepared according to Lillie (7).

The Schiff reaction was performed on sections without prior oxidation and following oxidation with periodic acid, peracetic acid, and performic acid. The peracetic acid and performic acid were prepared by the methods described by Lillie (8) and Pearse (9).

Acetylation of the tissues was accomplished by placing the sections in a mixture containing 40 parts acetic anhydride and 60 parts pyridine for 24 hours at room temperature. Deacetylation was accomplished by treating acetylated sections with 0.1 N KOH for 40 minutes.

Sulfation of tissues was performed on deparaffinized sections following, in general, the methods of Kramer and Windrum (5, 10). Concentrated sulfuric acid, chlorosulfonic acid, sulfuric acid-acetic acid mixture, and fuming sulfuric acid-acetic anhydride-ether mixture were tried, but since concentrated sulfuric acid appeared to be the simplest to use and gave the most consistent results, it was adopted for all the experiments. Thus deparaffinized sections were hydrated, the excess water was blotted out, and the sections were placed in concentrated sulfuric acid for 2 to 4 minutes. The sulfated sections were washed in tap water for several minutes and stained in a 0.1 per cent aqueous solution of toluidine blue for 2 minutes. The slides were then rinsed in distilled water, dehydrated in the usual manner, and mounted in clarite. Great care must be taken in manipulating the slides to prevent loss of the tissue sections. Kramer and Windrum have recommended that the sections be coated with water-soluble wax prior to treatment with the sulfuric acid but it was found that this slowed up, or interfered with, the sulfation process. Control sections were stained in toluidine blue without prior sulfation. Sections were also treated with concentrated hydrochloric acid, nitric acid, formic acid, phosphoric acid, and glacial acetic acid as substitutes for sulfuric acid in order to determine whether any of these acids would produce metachromasia when

the tissues were stained with toluidine blue. Other sections were oxidized with periodic acid, performic acid, and peracetic acid prior to toluidine blue staining.

Aldehyde-fuchsin stain was prepared according to the method described by Gomori (11). Sections were stained in aldehyde-fuchsin from 5 to 45 minutes following oxidation with periodic acid, oxidation with iodine, sulfation with concentrated sulfuric acid, and without prior treatment. In all instances glycogen was digested with diastase.

The oxidation potential of the PAS-positive materials and metachromatic materials was studied by means of Lillie's (8) modification of Schmorl's (12) ferric-ferricyanide reduction test whereby deparaffinized sections were treated in a solution containing 0.75 per cent ferric chloride and 0.1 per cent potassium ferricyanide for 5 to 10 minutes. According to this method, sites of reducing substances are blue.

Sections prepared for the demonstration of acid fastness in these materials were stained with carbolfuchsin overnight at room temperature, then decolorized with 3 per cent hydrochloric acid in 70 per cent alcohol for times varying from 3 minutes to 4 hours.

OBSERVATIONS

A series of 48 dogs ranging in age from 14 days to 19 years including 14 dogs that were over 10 years of age has been studied. In animals of the latter age group sections of autonomic ganglia (Fig. 1) and sensory ganglia (Fig. 2) show ganglion cells whose cytoplasm contains a periodic acid-Schiff positive deposition resistant to diastase digestion and previously demonstrated to be mucoprotein (2) in nature. In one of the dogs, the mucoprotein appeared in the form of evenly distributed PAS-positive granules which could be readily distinguished from pigment granules by their distribution and histochemical properties (Fig. 3). Examination of sections of other parts of the central nervous system in both young and senile dogs did not reveal the presence of similar staining granules.

The close parallelism between the distribution of PAS-positive material and the metachromatic substance produced by sulfation prior to toluidine blue staining as reported by Kramer and Windrum (5) stimulated a reinvestigation of this substance in nerve cells with the use of the latter technic. In order first to test this method sections of kidney were stained by the PAS method (Fig. 4) with toluidine blue (Fig. 5) and with sulfation followed by toluidine blue (Fig. 6).

Sections of kidney treated with the periodic acid-Schiff reagent revealed a strong positive reaction in the basement membranes of the renal corpuscles and the tubules. There was a suggestion of a light positive reaction in the brush borders of the proximal convoluted tubules. In corresponding sections of the kidney stained with toluidine blue the staining reaction was limited to the nuclei of cells and to a faint basophilic component in the cytoplasm in some of the tubular cells. Sections that were treated with concentrated sulfuric acid prior to staining with toluidine blue indicated that this reaction not only paralleled the PAS reaction but was even stronger. This is particularly noticeable in the brush borders of the proximal convoluted tubules.

The autonomic ganglia (Fig. 7) and sensory ganglia (Fig. 8) of 12 senile dogs examined after treatment with the sulfation technic showed a metachromatic deposition which was similar to the deposition exhibited by the PAS method. In addition to the non-granular deposition, the cytoplasm of autonomic ganglion cells (Fig. 9) and of sensory ganglion cells (Fig. 10) were characterized by the presence of metachromatic granules not observed with the use of the periodic acid-Schiff method.

The autonomic ganglia of one twelve year old dog in which the neurons were characterized by the presence of PAS-positive granules was demonstrated to contain large metachromatic granules when treated by the sulfation-toluidine blue technic (Fig. 11).

Investigation of other portions of the nervous system indicated that neurons from all parts including Purkinje cells of the cerebellum (Fig. 12), pyramidal cells of the cortex (Fig. 13), and ventral horn cells of the spinal cord (Fig. 14) were characterized by the presence of metachromatic granules in the cytoplasm following treatment of the sections with concentrated sulfuric acid prior to staining with toluidine blue.

Since the presence of metachromatic granules following the sulfation technic appeared as a constant feature of nerve cells in the senile dog, an investigation was made on the nervous system of dogs in all age groups from 2 months to 10 years of age. In the young animals, the absence of pigment granules, which also stain following the use of the sulfation technic, made it easier to recognize the metachromatic granules and obviated the necessity of engaging in other histochemical reactions in order to distinguish between the two. As in the case of the senile dogs, the cytoplasm of the neurons of young dogs was characterized by the presence of metachromatic granules following the sulfation method. Such granules were found in neurons of the autonomic ganglia (Fig. 15), sensory ganglia (Fig. 16), Purkinje cells (Fig. 17), ventral horn cells (Fig. 18), and all other neurons that were examined.

Pigment granules can be distinguished from mucoprotein granules, not only by their distribution and general appearance, but by a series of histochemical procedures. Following the sulfation-toluidine blue technic pigment granules were colored in various shades of blue. The mucoprotein granules were purple to red-purple in appearance.

In paraffin sections stained with Sudan black the pigment granules were characterized by a strong sudanophilia whereas the mucoprotein, in both granular and non-granular form, remained unstained. In sections treated with Lillie's modification of Schmorl's ferric chloride-potassium ferricyanide mixture, the pigment stained deep blue in 5 minutes whereas the mucoprotein was not stained by the ferric-ferricyanide mixture. Tests on acid fastness using the carbol-fuchsin HCl technic indicated, as previously reported (17) that the pigment is acid-fast. The mucoprotein does not show acid fastness even with a very short period of destaining.

Pigment granules treated with the Schiff reagent gave a weak to strong reaction. When sections were submitted to the periodic acid-Schiff reaction, the performic acid-Schiff reaction, and the peracetic acid-Schiff reaction the pigment granules were strongly positive. The mucoprotein non-granular deposition in the cytoplasm of the neurons of the autonomic and sensory ganglia of the senile dogs was positive only to the periodic acid-Schiff reaction. The mucoprotein granules which were observed in the perikarya of the peripheral nervous system in one 12 year old dog likewise reacted in a positive manner only to the PAS reaction.

TABLE I
Summary of Histochemical Properties of Lipoid Pigment and Non-granular and Granular Mucoproteins

| | Pigments | Non-granular mucoprotein | Granular mucoprotein |
|--|-------------------|--------------------------|--------------------------------|
| Toluidine blue following sulfation | Shades of blue | Purple to red-purple | Purple to red-purple |
| Sudan black on paraffin sections | Positive | Negative | Negative |
| Oxidation potential by Schmorl's ferric-ferricyanide technic | Reduces in 5 min. | No reduction | No reduction |
| Acid fastness | Positive | Negative | Negative |
| Schiff reagent | Positive | Negative | Negative |
| Periodic acid-Schiff technic | Positive | Positive | Positive in one 12 yr. old dog |
| Performic acid-Schiff technic | Positive | Negative | Negative |
| Peracetic acid-Schiff technic | Positive | Negative | Negative |
| Acetylation followed by PAS | Positive | Negative | Negative |
| Deacetylation followed by PAS | Positive | Positive | Positive in one 12 yr. old dog |
| Acetylation followed by sulfation technic | Blue granules | Negative | Negative |
| Deacetylation followed by sulfation technic | Blue granules | Positive (metachromasia) | Positive (metachromasia) |

Acetylation with a 40 per cent acetic anhydride-60 per cent pyridine mixture prior to periodic acid-Schiff staining or prior to the sulfation-toluidine blue procedure prevents the staining of the PAS-positive or the metachromatic depositions in the case of senile animals and of the metachromatic granules in the case of senile and young animals. This procedure blocks aldehyde formation and has been considered as presumptive evidence for the presence of mucopolysaccharides. The acetyl esters that are formed by the acetylation procedure can be hydrolyzed to restore both the PAS-staining reaction and the sulfation-toluidine blue staining reaction by treating acetylated sections with N/10 potassium hydroxide for 45 minutes prior to staining. These studies have been summarized in Table I.

Attempts to produce the metachromatic reaction with acids other than sulfuric acid, fuming sulfuric acid, and chlorosulfonic acid, resulted in failure. The acids that were employed included concentrated hydrochloric acid, nitric acid, formic acid, phosphoric acid, and glacial acetic acid.

It has been suggested by several investigators that undecolorized fuchsin (13, 14) and aldehyde-fuchsin (15, 6) are able to combine with aldehydes to yield purplish dyes that have staining properties different from the fuchsin itself. Sections of nervous tissue oxidized with periodic acid and treated with the aldehyde-fuchsin stain were characterized by a staining reaction parallel to that which resulted from the use of the sulfation-toluidine blue procedure. In the autonomic and sensory ganglia of the senile dog there was a non-granular cytoplasmic deposition identical to that observed following the periodic acid-Schiff and the sulfation-toluidine blue methods. In addition to the non-granular deposition in the ganglion cells of the senile animal, nerve cells in all parts of the nervous system in young and senile dogs were characterized by the occurrence of deep purple stained granules in the cytoplasm which paralleled the staining of granules observed following the sulfation-toluidine blue procedure. Sections oxidized with peracetic and performic acids prior to staining with aldehyde-fuchsins showed a positive reaction only in pigment granules. Sections from kidneys of dogs oxidized with periodic acid and stained with the aldehyde-fuchsin stain showed a much stronger reaction in the brush borders of the proximal convoluted tubules than did sections stained by the periodic acid-Schiff method. This reaction was similar to that which resulted from staining kidney sections by the sulfation-toluidine blue technic.

Sections of nervous tissue were also stained with the aldehyde-fuchsin stain without prior oxidation and following sulfation. The sections that were stained without prior treatment revealed no positive reaction of the aldehyde-fuchsin stain either in the granules or in the non-granular deposition. However, sections that were stained following treatment with concentrated sulfuric acid revealed a positive reaction. The coloring of this reaction differed somewhat from that obtained following periodic acid oxidation. In the latter instance the granules and non-granular deposition appeared deep purple, while following sulfation these components appeared red. In all these tests the glycogen was removed by means of diastase digestion.

DISCUSSION

The occurrence of large amounts of periodic acid-Schiff-positive mucoprotein in autonomic and sensory ganglion cells of the senile dog and its differentiation from lipofuscin based on a variety of histochemical tests has been previously established (1, 2, 17). The occurrence of PAS-positive mucoprotein in the form of granules has been observed in only one normal senile dog. How-

ever, in a preliminary study of other species (16) it has been observed that in the cat, PAS-positive mucoprotein granules are present in the cytoplasm of ganglion cells in young adult animals. Moreover, preliminary observations on the effect of chronic anoxia on the nerve cells of the dog (16) also revealed that nerve cells in young dogs (under 2 years of age) contain PAS-positive mucoprotein in the form of granules.

Studies of kidney sections indicate that the sulfation-toluidine blue method and the periodic acid-aldehyde-fuchsin method both show a stronger reaction, especially in the brush borders of proximal convoluted tubules, than does the periodic acid-Schiff technic.

This would seem to indicate that the two former methods give a more sensitive reaction to the presence of mucopolysaccharides than does the latter. These data would, in turn, support the view that the cytoplasm of nerve cells in many portions of the nervous system of the dog contain mucoproteins that cannot be demonstrated by the periodic acid-Schiff reaction except in the senile animal but can be demonstrated in animals of all ages by either the sulfation-toluidine blue technic or by periodic acid oxidation followed by the aldehyde-fuchsin stain.

Kramer and Windrum (5) have offered evidence that the treatment of tissue sections with concentrated sulfuric acid results in esterification of carbohydrates which is in turn responsible for the subsequent metachromasia. Their studies on tissue sections of a large variety of tissues and organs all present data which indicated the close parallelism between the distribution of PAS-positive material and the metachromatic substances produced by sulfation. Moreover, they showed by paper electrophoresis that both chondroitin sulfate and the extract of treated (sulfated) reticulin gave well defined metachromatic zones moving as negatively charged material with similar mobilities, while no metachromatic substance was detected in extracts of untreated reticulin, which was itself non-metachromatic. These studies, together with confirmatory data obtained in the present study, support the view that the treatment of tissue sections with concentrated sulfuric acid results in the esterification of carbohydrates. Kramer and Windrum (10) note the possibility that certain bound lipides might be rendered metachromatic by sulfation, as fatty alcohols are readily esterified. The data obtained from earlier studies (2) as well as from the present study indicate that the lipides can be differentiated from the mucoproteins by a number of tests. These include the differences in reactions of these substances to acid fastness, sudanophilic staining, reducibility with the ferric-ferricyanide reagent, and to acetylation and deacetylation procedures. Certain substances of lipoidal nature, such as ceroids, lipofuscin pigments, myelin, adrenal fuchsin pigments, and actinal rod acromere lipid may be oxidized with performic acid or peracetic acid to yield aldehyde, which may then be demonstrated with the

Schiff reagent. According to Pearse (9), if the performic acid-Schiff reaction gives a positive result in a given structure, it must be assumed (in the absence of keratin) that unsaturated lipides are present. It has been demonstrated here that the lipofuscin granules give a positive reaction in sections which were oxidized with peracetic acid or performic acid prior to treatment with the Schiff reagent whereas the mucoprotein, neither in granular nor non-granular form, reacted in such manner.

In comparing the reactions of aldehyde-fuchsin and the Schiff reagent following periodic acid oxidation, Scott and Clayton (6) have reported that they act in much the same way except in beta cell granules in which the aldehyde-fuchsin gives a strong reaction and the Schiff reagent is negative, and in reticular tissue and Paneth cell granules in which the Schiff reagent gives a stronger reaction than the aldehyde-fuchsin stain. According to these workers, aldehyde-fuchsin without prior oxidation stains certain mucopolysaccharides. These include mast cell granules, cartilage and goblet cells which are known to contain a high percentage of chondroitin sulfuric acid which possesses sulfuric groups. It is therefore concluded by Scott and Clayton that aldehyde-fuchsin may have an affinity toward sulfuric groups.

If tissue sections containing mucoproteins are sulfated with concentrated sulfuric acid resulting in esterification of the mucopolysaccharides, it would be expected, then, that such sections would reveal a positive staining reaction with the aldehyde-fuchsin stain assuming that aldehyde-fuchsin does have an affinity for sulfated mucopolysaccharides. The results obtained in this study establish the fact that aldehyde-fuchsin does react in a positive manner to the granules following sulfation of the sections and present further evidence to support the view concerning the presence of mucoprotein in nerve cells.

It is noteworthy that all the methods used indicate that there is a difference in the form and in the quantity of mucoprotein in neurons of the peripheral nervous system of the senile dogs. Although quantitative methods were not employed it is apparent that this substance is greatly increased in the perikarya of the autonomic and sensory ganglion cells of the aged animals. It is peculiar, that although mucoproteins are found in nerve cells of different parts of the nervous system in dogs of all ages, the apparent increase during senility is observed only in the peripheral ganglia. This does not eliminate the possibility that the concentration of mucoprotein varies with age in other portions of the nervous system. It is felt, however, that the methods employed are not sufficiently sensitive to measure anything but a very obvious increase. The parallel staining reactions of the granular form and the non-granular deposition suggest that the difference in form is an expression of a difference in quantity. Further studies are being carried on at present to test this view.

SUMMARY

Autonomic and sensory ganglion cells in the senile dog contain a deposition of PAS-positive substances which has been shown to be mucoprotein in nature.

Data are presented to show that this PAS-positive mucoprotein can be demonstrated by metachromatic staining with toluidine blue after the mucoprotein is sulfated. This procedure indicates that mucoprotein is also present in a granular form in all nerve cells in both senile and young dogs.

The evidence for this is further substantiated by the use of the aldehyde-fuchsin stain following both periodic acid oxidation and sulfation. The granular and non-granular deposition can be demonstrated by the periodic acid-aldehyde-fuchsin method due to the affinity of the aldehyde-fuchsin stain for aldehydes. It can be demonstrated following the sulfation-aldehyde-fuchsin method owing to the affinity of the stain for the sulfuric group. The evidence for this latter phenomenon has been reported by Scott and Clayton (6).

It is concluded that mucoprotein is present in a granular form in all nerve cells in both senile and young dogs but is not concentrated enough in the latter to be demonstrated by the PAS method.

LITERATURE CITED

1. Sulkin, N. M., and Kuntz, A., *J. Gerontol.*, 1952, **7**, 533.
2. Sulkin, N. M., *J. Gerontol.*, 1955, **10**, 135.
3. Kuntz, A., *Arch. Surg.*, 1934, **28**, 920.
4. Kuntz, A., *Biol. Symp.*, 1945, **11**, 101.
5. Kramer, H., and Windrum, G. M., *J. Clin. Path.*, 1953, **6**, 239.
6. Scott, H. R., and Clayton, B. P., *J. Histochem. and Cytochem.*, 1953, **1**, 336.
7. Lillie, R. D., *Histopathologic Technic*, Philadelphia, The Blakiston Co., 1948.
8. Lillie, R. D., *Histopathologic Technic and Practical Histochemistry*, Philadelphia, The Blakiston Co., 1954.
9. Pearse, A. G. E., *Histochemistry, Theoretical and Applied*, Boston, Little Brown and Co., 1953.
10. Kramer, H., and Windrum, G. M., *J. Histochem. and Cytochem.*, 1954, **2**, 196.
11. Gomori, G., *Am. J. Clin. Path.*, 1950, **20**, 665.
12. Schmorl, G., *Die pathologisch-histologischen Untersuchungsmethoden*, Leipzig, F. C. W. Vogel, 1928.
13. Arzac, J. P., *Stain Technol.*, 1950, **25**, 187.
14. Arzac, J. P., *J. Nat. Cancer Inst.*, 1950, **10**, 1341.
15. Gomori, G., *Microscopic Histochemistry*, University of Chicago Press, 1952.
16. Sulkin, N. M., unpublished data.
17. Sulkin, N. M., *J. Gerontol.*, 1953, **8**, 435.

EXPLANATION OF PLATES

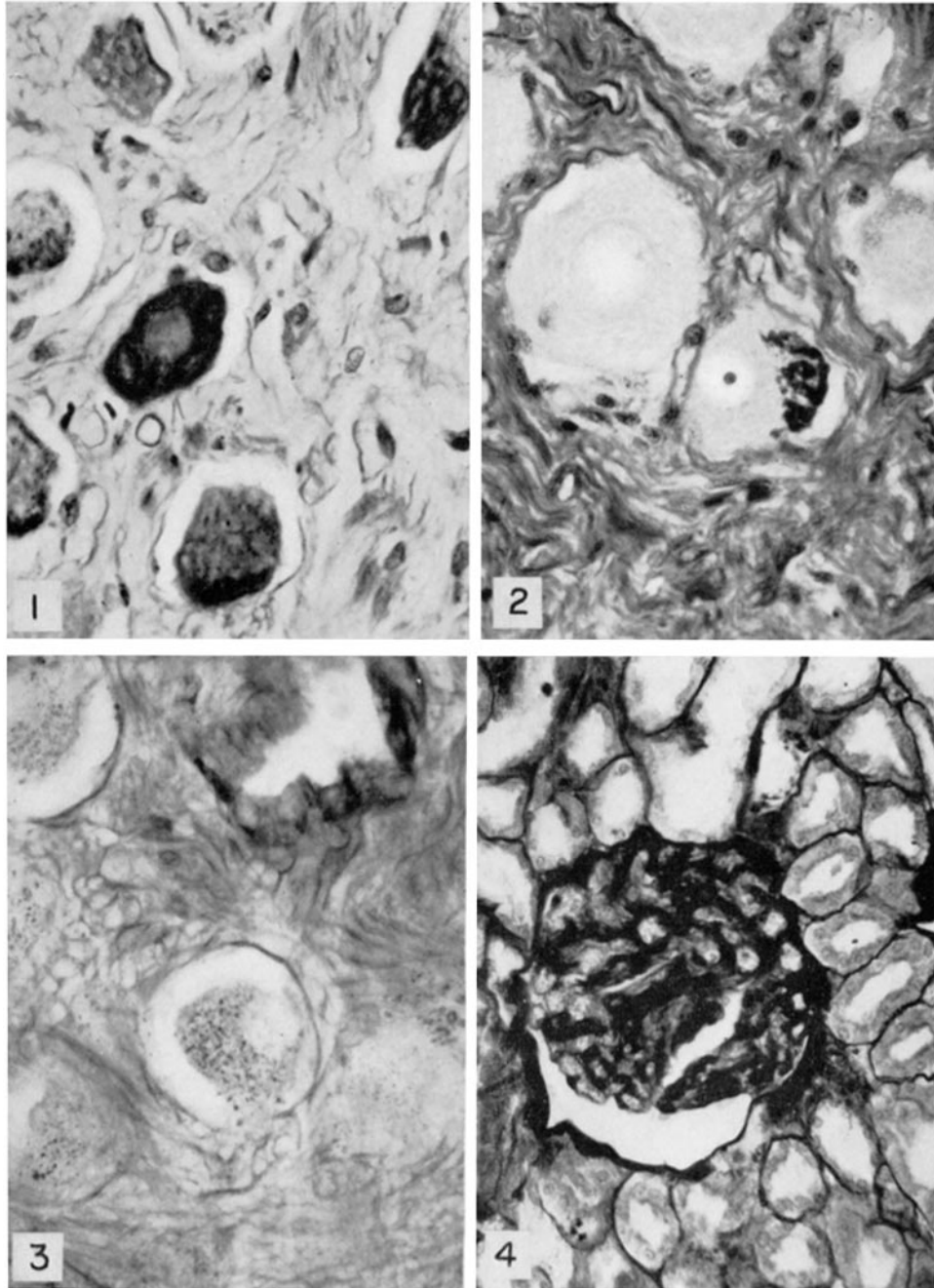
PLATE 123

FIG. 1. Section of autonomic ganglion from 14 year old dog stained by the periodic acid-Schiff method. Ganglion cells contain non-granular cytoplasmic mucoprotein deposition. 10 × ocular; 44 × objective.

FIG. 2. Section of nodose (sensory) ganglion from 14 year old dog stained by the periodic acid-Schiff method. Ganglion cell contains non-granular cytoplasmic mucoprotein deposition. 10 × ocular; 44 × objective.

FIG. 3. Section of autonomic ganglion from 12 year old dog stained by the periodic acid-Schiff method. Ganglion cells contain granular mucoprotein which was observed only in this dog. 10 × ocular; 44 × objective.

FIG. 4. Section of dog kidney stained by the periodic acid-Schiff method showing positive reaction in basement membranes and a weak reaction in the brush borders of some proximal convoluted tubules. 10 × ocular; 20 × objective.



(Sulkin: Mucoproteins in nerve cells)

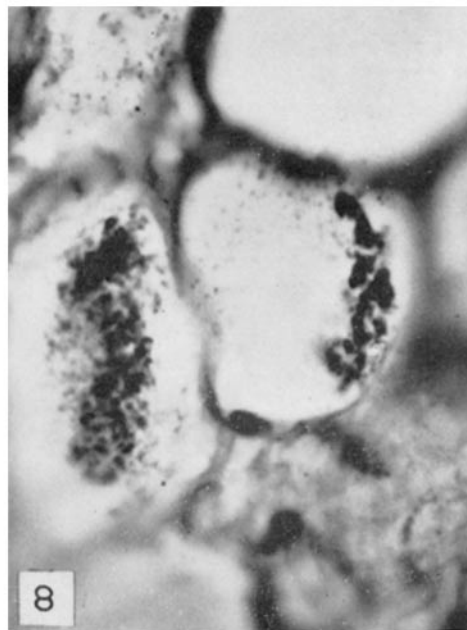
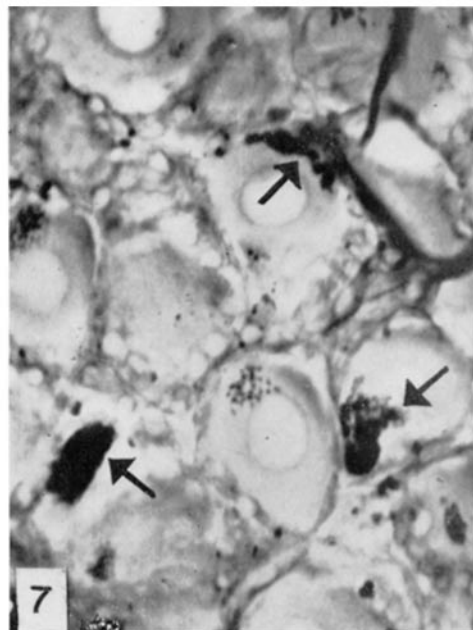
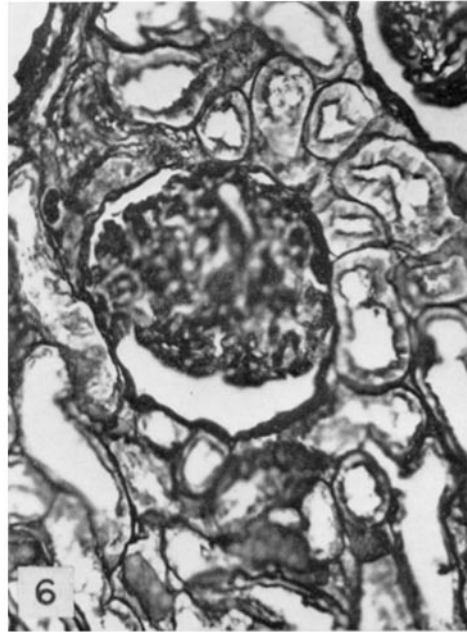
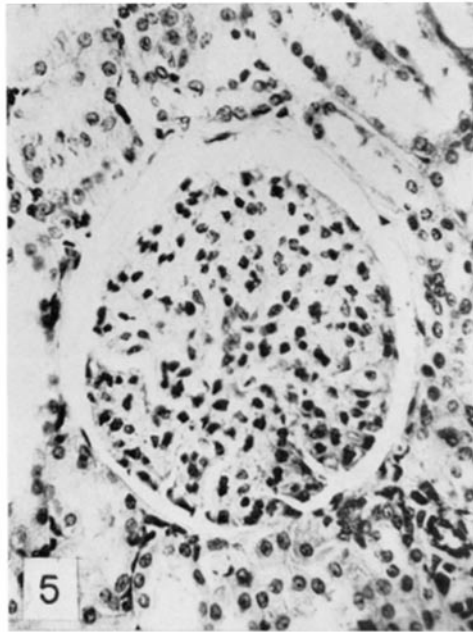
PLATE 124

FIG. 5. Section of dog kidney stained with toluidine blue. The staining reaction is limited mainly to the nuclei and to a lesser extent to the cytoplasm of some basophilic tubular cells. 10 × ocular; 20 × objective.

FIG. 6. Section of dog kidney stained by the sulfation-toluidine blue method. Staining is similar to that produced by the periodic acid-Schiff method except for a stronger reaction in the brush borders of the proximal convoluted tubules. 10 × ocular; 20 × objective.

FIG. 7. Section of autonomic ganglion from 14 year old dog stained with toluidine blue following sulfation showing heavy non-granular depositions with characteristics similar to PAS-positive deposition. 10 × ocular; 90 × objective.

FIG. 8. Section of dorsal root ganglion from 15 year old dog, stained with toluidine blue following sulfation, showing heavy non-granular deposition as well as granules. 10 × ocular; 90 × objective.



(Sulkin: Mucoproteins in nerve cells)

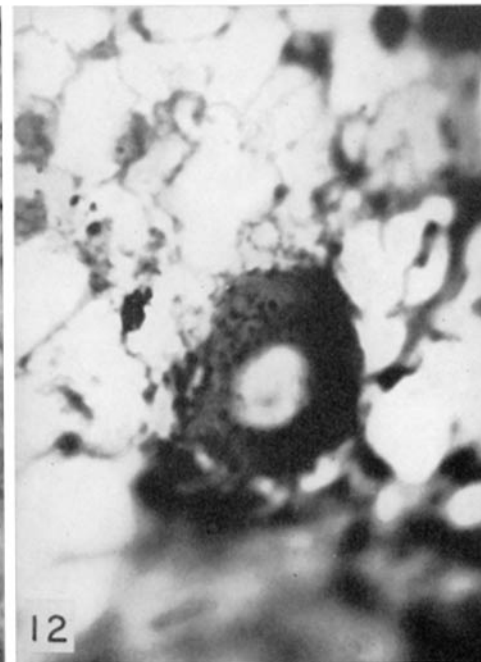
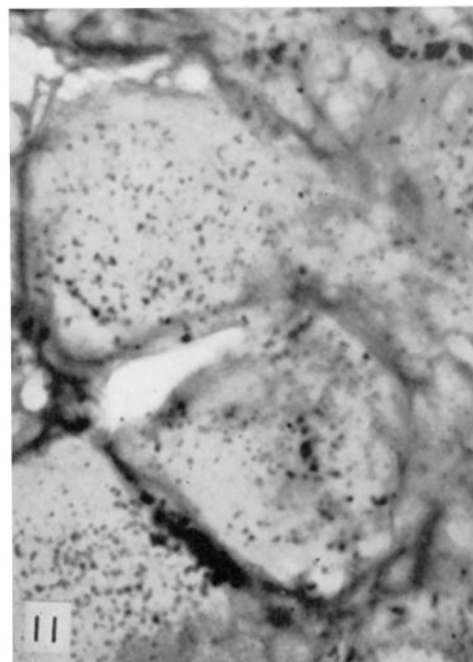
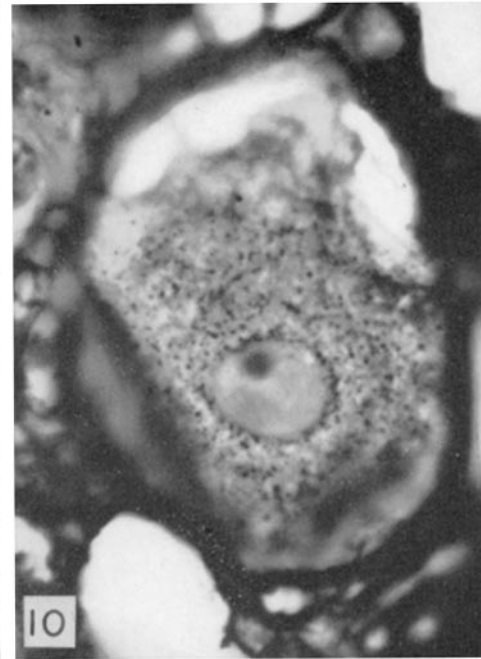
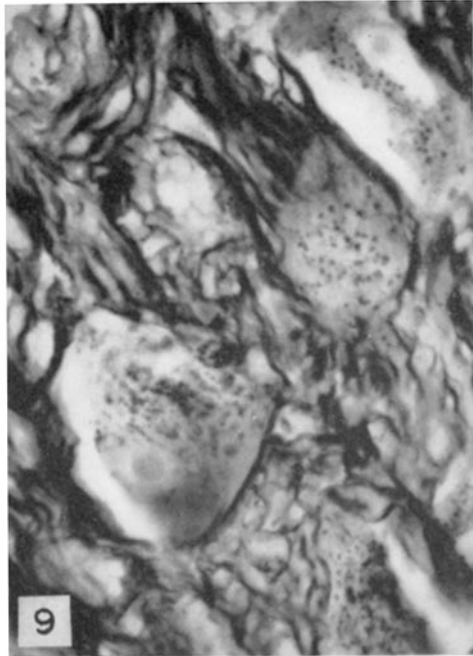
PLATE 125

FIG. 9. Section of autonomic ganglion from 13 year old dog, stained with toluidine blue following sulfation, showing metachromatic granules with same characteristics as non-granular deposition. 10 × ocular; 90 × objective.

FIG. 10. Section of nodose (sensory) ganglion from 14 year old dog, stained with toluidine blue following sulfation, showing distribution of metachromatic granules. 10 × ocular; 90 × objective.

FIG. 11. Section of autonomic ganglion from same dog as in Fig. 3, stained with toluidine blue following sulfation, showing heavy granular distribution of mucoprotein. 10 × ocular; 90 × objective.

FIG. 12. Section of cerebellum of 16 year old dog, stained with toluidine blue following sulfation, showing metachromatic granules in Purkinje cells. 10 × ocular; 90 × objective.



(Sulkin: Mucoproteins in nerve cells)

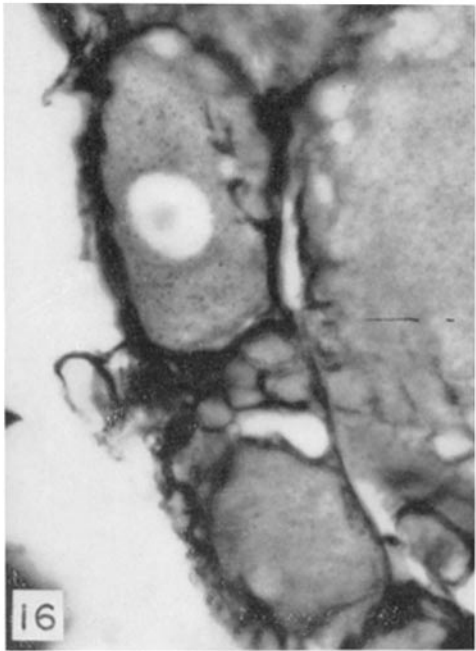
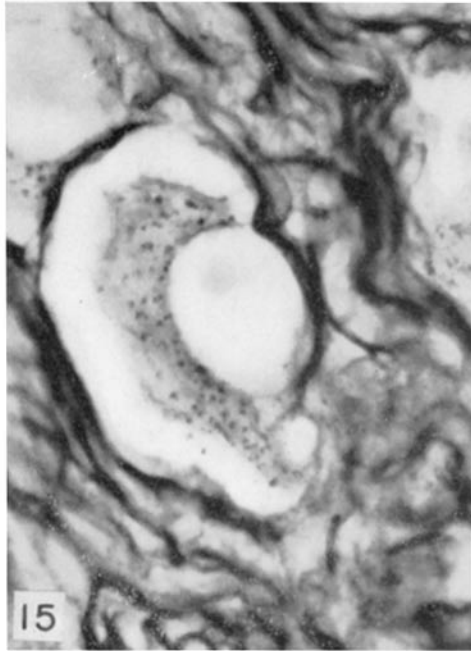
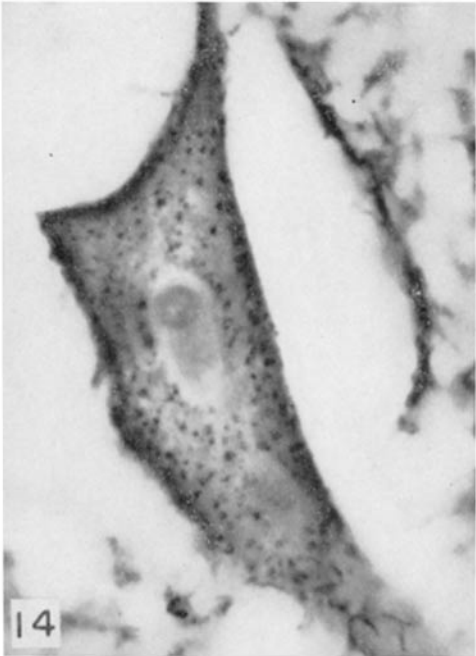
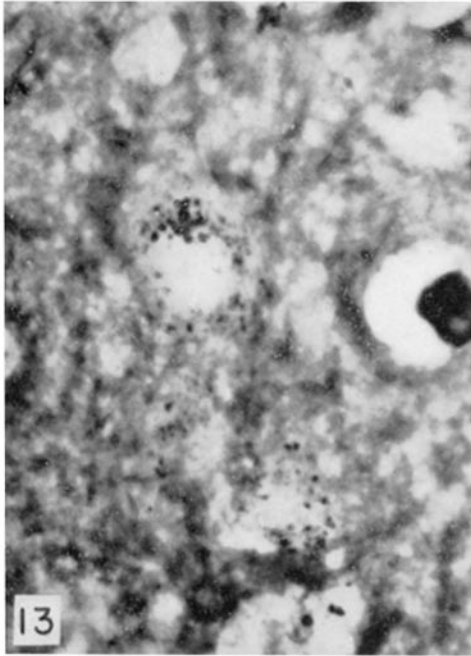
PLATE 126

FIG. 13. Section of motor cortex from 16 year old dog, stained with toluidine blue after sulfation, showing distribution of metachromatic granules. 10 × ocular; 90 × objective.

FIG. 14. Section of spinal cord from 16 year old dog, stained with toluidine blue following sulfation, showing distribution of metachromatic granules in ventral horn cell. 10 × ocular; 90 × objective.

FIG. 15. Section of autonomic ganglion from 3 month old dog, stained with toluidine blue following sulfation, containing metachromatic granules similar to those found in senile dog. 10 × ocular; 90 × objective.

FIG. 16. Section of spinal ganglion from 3 month old dog, stained with toluidine blue following sulfation, showing fine metachromatic granulation. 10 × ocular; 90 × objective.

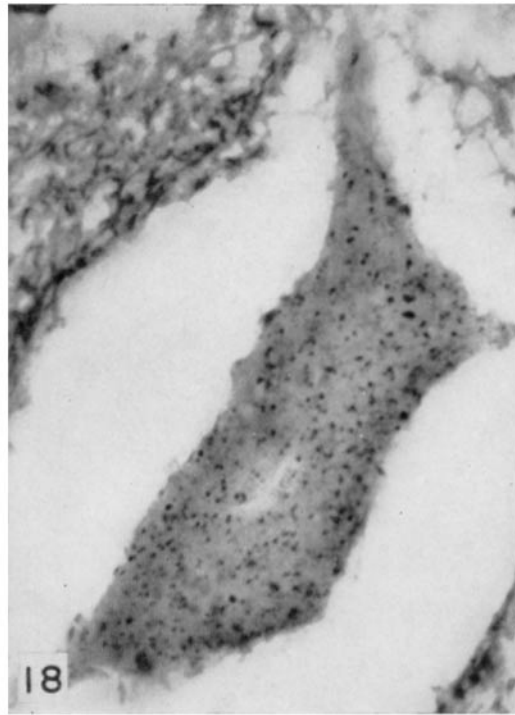
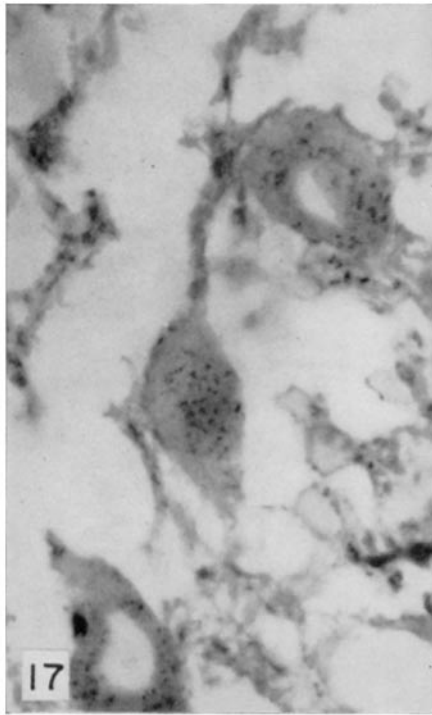


(Sulkin: Mucoproteins in nerve cells)

PLATE 127

FIG. 17. Section from cerebellum of 6 month old dog, stained with toluidine blue following sulfation, showing fine metachromatic granulation in the Purkinje cells. 10 × ocular; 90 × objective.

FIG. 18. Section of spinal cord of 6 month old dog, stained with toluidine blue following sulfation, showing metachromatic granulation. 10 × ocular; 90 × objective.



(Sulkin: Mucoproteins in nerve cells)