

Top 10 differential diagnoses in family medicine: Headache

David Ponka MD Michael Kirlew MD

7. HEADACHE

This is a challenging symptom to work up in primary care because serious causes are rare but devastating if missed. Always ask about these red flags:

- worst headache or thunder clap headache (subarachnoid hemorrhage);
- visual loss (temporal arteritis);
- new onset headache in the elderly;
- positional exacerbation or worsening with valsalva;
- morning headaches;
- headache in pregnancy, especially in the third trimester;
- trauma or intoxication or anticoagulation;
- history of carcinoma; and
- other neurological deficits.

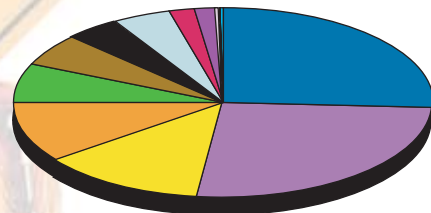
An expanding intracranial mass paradoxically presents with relatively mild unremitting headache.

Much more common causes are of course:

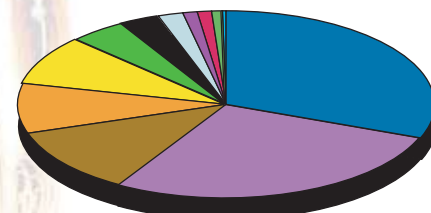
- tension headache;
- migraine;
- cervical disc disease;
- eye disorders including refractive errors;
- sinusitis;
- rebound headache from overuse of analgesia; and
- iatrogenic headache (most commonly nitrates and Ca channel blockers).

Ca—calcium; CNS—central nervous system; CVA—cerebrovascular accident; GI—gastrointestinal; NYD—not yet diagnosed; URI—upper respiratory infection.

Remember to always explore the patients fears, which often include intracranial tumour and hypertension (rarely alone a cause of headache).



Under 45



45 and Older

	AGE	
	Under 45	45 and Over
Headache NYD	25.90 %	28.00 %
Sinusitis	12.80	8.40
Tension Headache	10.30	8.60
Migraine	6.70	4.50
Cervical Disease	5.40	11.40
URI	4.30	3.20
Other Viral Disease	4.20	1.80
Concussion	2.10	1.00
Influenza	1.70	1.30
GI Malignancy	0.03	0.05
CNS Malignancy	0.02	0.02
CVA	0.10	0.90
Meningitis	0.20	0.02
Other	26.00	31.00

For a pdf of the Top Ten Differential Diagnoses in Family Medicine pamphlet or to access the slide show on-line, go to <http://www.familymedicine.uottawa.ca/eng/TopTenDifferentialDiagnosisInPrimaryCare.aspx>.

Dr Ponka is an Assistant Professor and Dr Kirlew is a second-year resident in the Department of Family Medicine at the University of Ottawa in Ontario.

Correspondence to: Dr David Ponka, Assistant Professor, Department of Family Medicine, University of Ottawa; e-mail dponka@uottawa.ca