CANCER OF THE RECTUM

Lecture delivered at the Royal College of Surgeons of England

on

26th April, 1950

by

C. Naunton Morgan, F.R.C.S.

Surgeon, St. Bartholomew's Hospital, St. Mark's Hospital for Diseases of the Rectum and Colon, etc.

HISTORY

LISFRANC WHO EXCISED the rectum in 1826, is most quoted as being amongst the earliest surgeons to perform this operation successfully, though Faget is reported to have amputated the rectum in 1739.

Owing to the high mortality rate associated with abdominal surgery, operations for rectal cancer were at first limited to a perineal or parasacral approach alone, and excision of the rectum was very limited in its extent. In 1884, Czerny, when removing a high rectal growth through the perineum, was forced to combine the perineal with an abdominal approach. A year later Kraske advised excision of the coccyx and a portion of the sacrum in order to obtain a better exposure of the rectum from below.

The pull-through type of operation was introduced by Hochenegg in 1889, in order to prevent the formation of a faecal fistula. At this time, in England, William Allingham described a method of perineal resection with preservation of the sphincters.

At the turn of the century surgeons began to advocate a combined abdominal and perineal attack on rectal cancer and Quenu, in 1898, suggested a two-stage operation. The names of Maunsell and Weir are associated with abdomino-anal excision, with preservation of the sphincters, at about this period. In 1903, Sir Charles Ball recommended the abdominal approach and Dame Aldrich Blake described an abdomino-perineal operation with sphincter preservation.

It was not, however, until 1908 when, as a result of the important researches by Ernest Miles on the mode of spread of carcinoma of the rectum that the need for combined abdomino-perineal excision was firmly established. Lockhart-Mummery, however, still advocated a two-stage perineal excision, since this operation, especially in his hands, produced good results with a very low mortality. Grey Turner and Gabriel modified combined excision by using a perineo-abdominal method.

The lithotomy-Trendelenburg position for performing combined excision was introduced by Bloodgood in 1901, used by Kirschner in Germany in 1934, and then by Devine in Australia. In 1938, my colleague Lloyd-Davies suggested a synchronous combined operation by two surgeons working together, with the patient in this position. After operating together upon several very advanced adherent growths

by this method, we were convinced that this dual approach would make combined excision easier and certainly increase the operability (resectability) rate.

Modern methods of pre-operative and post-operative treatment, the advent of sulphonamides and antibiotics, advances in surgical technique and anaesthesia and especially more accurate information regarding the spread of carcinoma of the rectum, have together revived a new interest in the removal of rectal growths with preservation of the normal mechanism of defaecation. It should be recalled however that such attempts at conservative surgery antedated excision of the rectum by half a century.

INCIDENCE AND SITE

In 1948, the Registrar General reported 6,453 deaths from carcinoma of the rectum (3,901 males and 2,552 females) in England and Wales.

It has been estimated that about 12 per cent. of all malignant tumours arise in the rectum, sigmoid colon and anus and that between 75 per cent. and 80 per cent. of all intestinal cancers develop in these regions. From 1928 to 1948, at St. Mark's Hospital, it was found that adenocarcinoma occurred in the rectum and rectosigmoid in 82 per cent. of cases, adenocarcinoma of the colon in 13 per cent. and squamous epithelioma in 1·5 per cent. More than one malignant neoplasm was present in the large bowel in 3·5 per cent. of specimens.

At a general hospital (St. Bartholomew's), in 481 cases of carcinoma of the large intestine, 62 per cent. were situated in the rectum and 38 per cent. in the colon and caecum.

In the male, cancer of the rectum is only less common than that of the stomach, whilst in the female, it occurs next in frequency to carcinoma of the cervix or breast. Adenocarcinoma commences on the anterior or the posterior wall of the lower, the middle and the upper thirds of the rectum in about equal frequency, and approximately 52 per cent. of all rectal growths have their lower edge less than 10 cms. distant from the anal orifice.

SEX AND AGE

Carcinoma of the rectum is more common in the male and from an analysis of one thousand cases, Dukes reports that the ratio is two males to one female ; Bacon estimates the sex incidence as three males to two females.

Carcinoma of the rectum occurs most frequently between the ages of 40 and 70 and is most common in the fifth decade. It commences slightly earlier in women and more advanced growths are seen in this sex, about 10 per cent. more cases having lymphatic involvement. Although this condition is much less common in early life, between 4 per cent. and 7 per cent. occur before the age of 30.

AETIOLOGY

It is firmly established that the majority of adenocarcinomata of the rectum and large bowel arise in a pre-existing innocent adenoma, which

itself starts in an area of hyperplasia. The importance of removal of all such adenomata will be realised and the possibility of the development of more than one primary malignant tumour must not be forgotten.

Though carcinoma of the rectum is not hereditary, the tendency to epithelial hyperplasia with the formation of multiple adenomatous polypi in the large bowel which undergo malignant change is inherited as a Mendelian dominant (Familial Adenomatosis).

SPREAD OF CARCINOMA OF THE RECTUM

Local.—The growth spreads in a centrifugal manner but extends circumferentially a little more rapidly than in the longitudinal axis. Miles stated that the growth took between 18 months to two years to become completely annular, and Glover and Waugh report that about one-quarter of the circumference of the rectum is involved by the growth in six months. Spread in the submucous layer, except in anaplastic growths, extends only for a few millimetres from the visible edge of the neoplasm. Implantation of growth also occurs either as extension down a fistulous track or into the suture line at operation.

Lymphatic.—At St. Mark's Hospital this has been found to be present in a little more than 50 per cent. of cases. The zones of spread via the lymphatics originally described by Miles, namely upwards, laterally and downwards, have been investigated very thoroughly in the past 25 years by Dukes, Gabriel and Bussey, David and Gilchrist and others, and much important information has been obtained.

Upward Spread.—When the lymphatics are involved, extension upwards along the lymph nodes accompanying the superior haemorrhoidal and inferior mesenteric vessels is the most constant and most common pathway, and in the large majority of instances proceeds along this route in an orderly manner, extending from gland to gland. In less than 4 per cent. of examined specimens it was found that neoplastic cells had skipped glands.

Wide removal of this upward mesenteric lymphatic field is therefore essential in whatever operation is employed to eradicate a rectal carcinoma. (Fig. 1.)

Downward Spread.—Retrograde lymphatic spread is uncommon except in anaplastic or advanced carcinomata. In 836 cases, Dukes found that downward lymphatic or venous spread occurred in about 4 per cent. and extended beyond 5 cms. below the lower edge of the neoplasm only in 2 per cent. The growth was of a high grade of malignancy in three-quarters of the specimens which showed downward spread. (Fig 2.)

David and Gilchrist report that in 4·3 per cent. of their cases there was downward spread to a distance of from 1 to 5 cms.

Lateral Spread.—The subperitoneal portion of the rectum is ensheathed in the pelvic fascia and grasped by the pubococcygeus muscles. In this situation, in addition to the constant upward spread, there is also a choice of extension outwards along the levators, pelvic fascia and

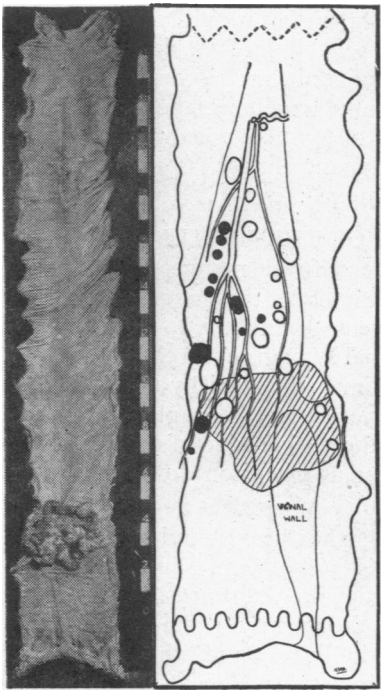

Fig. 1

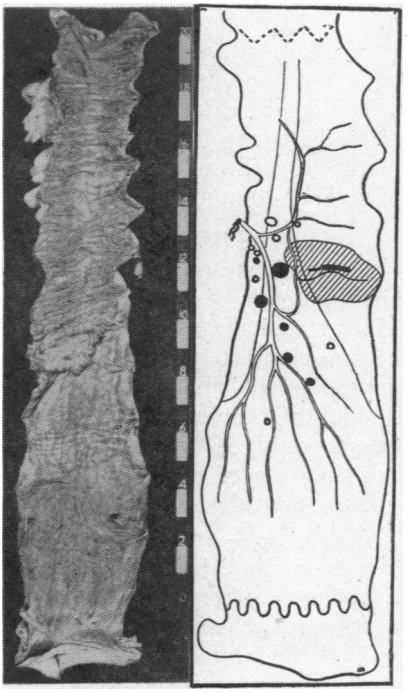

Fig. 2

Fig. 1. Upward Lymphatic Spread.
(*Pathological Department, St. Mark's Hospital*)

Fig. 2. Downward Lymphatic Spread in a Supraperitoneal Growth.
(*Pathological Department, St. Mark's Hospital*)

lymphatics accompanying the middle haemorrhoidal vessels. (Fig. 3.) Further, growths low in the rectum may involve the lymphatics accompanying the inferior haemorrhoidal vessels.

Though there are no figures available regarding the frequency of lateral spread, the prognosis for growths with lymphatic involvement situated in the subperitoneal rectum is only half as good as for those above the peritoneal cul de sac and even when there is no lymphatic spread, the survival rate for subperitoneal growths is slightly the poorer. David and Gilchrist have shown that for growths with lymphatic involvement, situated below the level of the peritoneum, the local recurrence rate is 23 per cent., as compared with 3·6 per cent. for similar growths located above the peritoneal reflection. These facts suggest that lateral spread is an important factor when a growth is situated below the peritoneal reflection and therefore wide excision of the levators, pelvic fascia and ischiorectal fat is essential, in addition to removal of the upward lymphatic pathway. In other words, all such growths require a combined excision

because this portion of the rectum and mesorectum may be regarded as being wrapped up in the pelvic fascia and levator ani muscles, and these structures should be removed *en bloc* with the rectum.

The size of a growth alone is no indication as to the likelihood of lymphatic spread. A tiny anaplastic neoplasm may have extensive lymphatic metastases. The type of growth, protuberant or ulcerating, does, however, usually have a bearing on lymphatic extension. The lymphatics are involved later in growths that are hypertrophic and protrude into the lumen, and earlier where there is ulceration and extension through the wall of the bowel. It is unusual for a growth to implicate the lymphatic glands until it has extended through the whole thickness of the bowel wall.

Dukes, following Lockhart-Mummery, has classified carcinoma of the rectum in four stages :—

A. (Stage 1) where the growth is limited to the bowel wall.

B. (Stage 2) where the growth has involved the perirectal tissues.

C. (Stage 3) where the lymphatics are involved.

D. (Stage 4) those in which there are distant metastases.

The proportion of growths found in each of the first three stages is shown in Fig. A.

As might be expected, anaplastic neoplasms involve the lymphatics more readily than growths of low-grade malignancy ; and from an analysis of 1,262 cases by Dukes it was found that growths of low-grade malignancy involved the lymphatics in 16·8 per cent., whereas those of a high grade did so in 95·5 per cent.

Venous Spread.—This may occur immediately the growth has invaded the submucosa, and at St. Mark's Hospital examination of operation specimens shows that venous spread is present in about 15 per cent. This does not mean that if no venous involvement is found in a dissected specimen that an embolus of malignant cells has not already escaped to the liver, neither is it by any means certain that when growth is found in the veins this indicates hepatic metastasis. Venous involvement however, was present in half the patients having hepatic deposits revealed at post-mortem.

COMBINED EXCISION

Incidence of A, B and C cases and Prognosis

Group	Operation Survivals	Untraced (as dead)	Died in Less than 5 Years	Alive at 5 Years	% of 5 Years' Survivals
A.	46 (12·6%)	—	7	39	84·8
B.	122 (33·3%)	1	43	78	63·9
C.	198 (54·1%)	3	129	66	33·3
Total :	366	4	179	183	50·0

Fig. A (*From the Pathological Department, St. Mark's Hospital, London*)

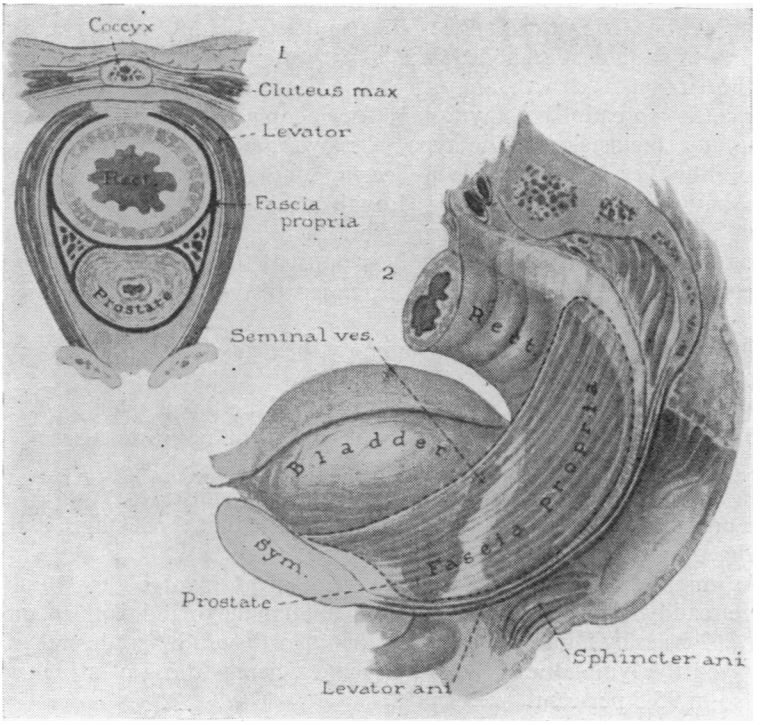

Fig. 3. Relation of the fascia propria and levators to rectum and prostate. Vernon C. David in Dean Lewis's " Practice of Surgery." (*W. C. Prior Co. Inc., Hagerstown, Maryland*)

Just as in the case of lymphatic spread, anaplastic growths involve the veins most frequently. Venous spread occurs in over 30 per cent. of growths of high-grade malignancy, as compared with less than 3 per cent. of those of low-grade malignancy. Extension upwards or downwards within the veins may result in eruption of the growth back into the rectal wall at several places. Venous extension is usually associated with lymphatic spread. (Fig. 4.)

SYMPTOMS

The early symptoms of carcinoma of the rectum are unfortunately slight and vague and usually pass unnoticed by many patients unless they are carefully questioned. The systemic effects of a rectal growth such as anaemia, loss of weight, loss of energy and cachexia occur late in the disease and augur a poor prognosis, except in a few cases where the growth is very infected, with severe inflammation and oedema of the rectal wall associated with excessive mucous discharge and toxic absorption.

When the growth is situated in the upper third of the rectum or recto-sigmoid, the symptoms are obstructive and there may be abdominal

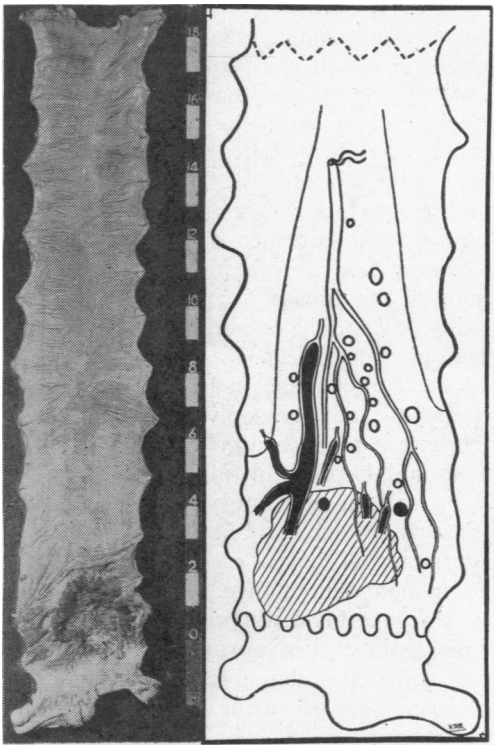

Fig. 4. Venous Spread and Lymphatic Spread.
(*Pathological Department, St. Mark's Hospital*)

discomfort with distension, colic and alternating constipation and diarrhoea. Ampullary or mid-third neoplasms produce tenesmus with the passage of frequent and small stools. A low growth will give rise to some pain when it involves the anal canal, but pain is not an early symptom and usually occurs when there is degeneration of the growth.

The most constant early symptoms are the passage of a little blood on defaecation and some slight alteration in bowel habit. The fact that there is a change in bowel habit can only be elicited by taking a careful history. The patient should be asked not only how often he passes a motion but also how frequently he has the desire to do so. The constant call to defaecate with only the passage of blood and mucus and flatus occurs only when the growth has reached a considerable size.

Bleeding occurs early in about three-quarters of the cases and a change in bowel habit in over one-half.

DIAGNOSIS

Early diagnosis will be made only as a result of a careful history and thorough examination of the whole rectum in all cases passing blood or

in whom there is even a slight change in bowel habit. Between 80 and 90 per cent. of rectal carcinoma can be diagnosed on digital examination. The growth can be felt directly or through a fold of mucous membrane or through the whole thickness of the bowel wall. The typical firm or hard everted edge of an ulcer or the cauliflower-like projection of an hypertrophic neoplasm will be palpated. An anaplastic growth may occur as a small ulcer or a submucous nodule from which submucous induration or a cord of lymphatic permeation extends.

Abdominal examination, together with bimanual rectal examination and bi-digital recto-vaginal examination, will give useful information regarding the extent of the disease.

Finally sigmoidoscopy should be performed without previous preparation and even if no growth be seen, the finding of a fleck of blood in the upper reaches of the bowel makes a barium enema imperative. X-ray examination should be advised only after thorough palpation and endoscopy. Otherwise a rectal cancer may be easily overlooked.

Biopsy.—This should be done in all cases through a sigmoidoscope or proctoscope. Provided a satisfactory portion of the tumour is removed this method is most trustworthy and in 2,118 biopsies, Dukes showed the diagnosis to be correct in all but 17 cases, of which, 15 cases were villous tumours undergoing malignant change. Palpation of the biopsy specimen between the fingers will readily distinguish a fragment of soft compressible mucous membrane from a firm portion of a tumour. Biopsy is not only important for differential diagnosis, but the finding of an anaplastic tumour will have some bearing on the type of operation to be employed and is useful in prognosis.

Amongst the conditions arising intrinsically which may have to be occasionally considered in differential diagnosis are a villous tumour, an adenoma, diverticulitis, solitary ulcer, inflammatory stricture, sarcoma, carcinoma of the sigmoid colon lying in the pelvis and invading the rectal wall and endometriosis.

Infiltration of the pelvic peritoneum or the cellular tissues by deposits from a carcinoma of the stomach or ovary, by carcinoma of the prostate, chronic pelvirectal cellulitis and parametritis are some of the extrinsic causes of a mass involving the rectal wall.

OPERATIVE TREATMENT

Combined Excision.—Careful investigation and pre-operative treatment, including decompression of the bowel, are essential. Rarely is a preliminary colostomy necessary and a two-stage operation is only indicated when obstruction cannot be relieved by medical measures.

Combined Abdomino-Perineal Excision (*Miles*) which removes all the zones of lymphatic spread is the most radical operation for cancer of the rectum. During the past 12 years many of us at St. Mark's Hospital have been carrying out this method of excision by placing the patient in the lithotomy-Trendelenburg position, using the lithotomy crutches

devised by Lloyd-Davies, so that the abdominal and perineal operation fields are available at the same time. This allows two surgeons to work together, one in the abdomen and the other in the perineum, without any inconvenience to either surgeon—Synchronous Combined Excision—or, of course, a single surgeon can carry out the operation.

In this position, the perineal dissection can be performed with anatomical precision and the various muscle and fascial planes more readily displayed and excised widely. (Mayo, 1910.) Alteration of the position of the patient during the course of an operation is undesirable: this is obviated by adopting this position.

The pelvic peritoneal floor is closed over an empty pelvis, after the freed rectum has been withdrawn either through the abdominal or perineal incision. This makes closure easier, especially in fat patients with friable peritoneum, and also allows of wide excision of peritoneum. The perineo-abdominal method also has this advantage.

When two surgeons operate together, excision of large advanced fixed growths which often fill the pelvis is much more readily carried out. The abdominal surgeon assesses resectability by trial dissection on the fixed aspects of the tumour, and, in the presence of distant secondaries or a second primary carcinoma, any alteration in plan is made before the perineal dissection commences. When it has been decided to perform a synchronous combined excision, the abdominal surgeon proceeds with the operation which may require isolation of the ureters, resection of other organs such as the uterus, caecum or coils of small intestine, whilst simultaneously the perineal dissection is being carried out. Difficulties arising from infiltration of the lateral ligaments deep into the pelvis or from fixity anteriorly are lessened and severe haemorrhage more easily dealt with by means of the dual approach from above and below at the same time. Combined excision of the rectum is made easier by using the lithotomy-Trendelenburg position and for this reason more advanced growths may be excised, resulting in an increased operability (resectability) rate.

The inferior mesenteric vessels should be ligatured as high as possible but an adequate blood supply to the terminal colostomy must be retained. Because the anatomical arrangement of the branches of the inferior mesenteric artery is variable, the site of origin of the first sigmoid and left colic arteries should be located before the ligature is applied. The terminal colostomy may thus be supplied either through the first sigmoid artery, the descending branch of the left colic artery or occasionally by a large marginal artery. In about half the cases the first sigmoid and left colic arteries have a common origin or are often close together.

In the female, when the growth is situated below the level of the posterior vaginal fornix, the posterior wall of the vagina is excised with the rectum owing to the frequency of recurrence in the posterior vaginal wall in such cases.

Perineal Excision (*Lockhart-Mummery*).—Because this operation fails to allow of thorough removal of the upward lymphatic field it is not a desirable method, though comparative survival rates show that when there was no lymphatic spread, perineal excision was as radical as a combined method. However, when lymphatic metastasis has occurred, the prognosis after perineal excision was only half as good as that following combined excision. This operation should be considered as a palliative procedure and only employed as such, since the extent of the disease cannot be accurately gauged clinically.

Anterior Excision.—Hartmann's operation may be extended by removal of the rectum down to the pelvic floor and is useful in the few patients with high growths who would not stand combined excision or who are too advanced for a restorative operation. As already mentioned, when a growth is situated below the peritoneal reflection, removal of the levators and pelvic fascia is essential, and this requires perineal excision, in addition to an abdominal operation, in order to remove the upward lymphatic field.

OPERABILITY (Resectability)

The terminal stages of a patient with carcinoma of the rectum are so distressing that every effort should be made to remove the primary growth. In fact the only satisfactory palliative method of treatment is excision of the primary lesion.

Except in the very few cases presenting with clinical evidence of gross hepatic metastases, peritoneal deposits with ascites or distant secondaries such as pulmonary, cerebral, etc., accurate assessment of operability can only be decided by exploratory laparotomy.

An estimated replacement of one-half of the liver substance by secondary deposits should not in itself bar palliative excision or resection. Excision of the primary growth under these circumstances often increases the remaining span of life, and also makes the patient much more comfortable. Widespread peritoneal metastases preclude palliative excision but deposits situated only in the vicinity of the growth may be removed by extra wide excision of the peritoneum together with the rectum, though of course the prognosis is poor. Occasionally a solitary secondary deposit in the left lobe of the liver will justify partial hepatectomy.

The resectability of a growth fixed in the pelvis should be decided upon, as already mentioned, by trial dissection, since local fixity is often due to inflammation. Extension of the growth to the bladder base anteriorly, when the patient is otherwise well and there is no evidence of distant metastases, occasionally warrants cystectomy with transplantation of the ureters. In the female hysterectomy should always be carried out when necessary.

As a result of bolder methods made possible by the lithotomy-Trendelenburg position and the co-operation of two surgeons, the operability (resectability) rate in 287 personal cases, which include all patients with malignant disease of the rectum and anal canal seen either

as Out-patients, In-patients or outside the Hospital between 1946 and 1950, was 94 per cent. (270 in 287 cases).

Mortality Rate.—A high operability rate tends to increase the mortality rate, yet the mortality rate for all Synchronous Combined Excisions performed during the same period (1946-1950) as the result of the skilful and unselfish help of my colleagues was 5·4 per cent. — 11 deaths in 202 operations. The majority of these combined excisions, namely 180, were performed at St. Mark's Hospital, with 8 deaths—a mortality rate of 4·4 per cent. The remaining 68 cases were treated by other methods of excision or resection, particularly restorative resection, though this latter operation was used in only 18 per cent. of all the growths removed and included a number of palliative resections.

Prognosis following Combined Excision.—Prognosis greatly depends upon the stage of the growth at operation. This is illustrated in Fig. A. The five years' survival rate for all cases of carcinoma is about 50 per cent. but the presence of lymphatic metastases markedly affects the prognosis. When lymphatic metastases are present the five year survival rate is about 33 per cent. as compared with about 70 per cent. for growths without lymphatic involvement.

Anaplastic neoplasms have an extremely poor prognosis owing to the frequent and rapid involvement of lymphatics and veins.

RESTORATIVE RESECTION

It is too early yet to present any final conclusions regarding the ultimate value of these operations and we are adopting a cautious attitude. Approximately one in five cases of carcinoma, including palliative resections, are treated by these methods at the present time at St. Mark's Hospital. Certain criteria, however, can be laid down regarding the type of operation and the selection of cases.

Type of Operation.—Any operation which restores continuity of the large bowel ought to allow normal defaecation with complete control. It is therefore necessary to preserve not only the sphincter mechanism intact but also a portion of the rectal wall and the whole of the anal canal with its sensitive lining and nerve supply. In addition, a restorative operation must permit radical removal of the upward lymphatic field; thus a parasacral or perineal approach alone is totally inadequate. The inferior mesenteric vessels should be ligatured as high as recommended in combined excision. The rectum and meso-rectum must be removed *en bloc* for at least two inches (5 cms.) below the lower border of the neoplasm, owing to the possibility, though infrequent, of retrograde lymphatic extension.

Intrapelvic restorative resection (anterior resection) abdomino-anal and abdomino-sacral resection fulfil these needs, but the increased morbidity of the abdomino-sacral operation made us, at St. Mark's, discard this method. Abdomino-anal resection requires an extra long portion of colon and mesentery and its use is thus more limited than intrapelvic anastomosis. Abdomino-anal excision has been employed

as a palliative operation and occasionally for small early protuberant growths just at or below the peritoneal reflection. The lithotomy-Trendelenburg position is ideal for the performance of either intrapelvic or abdomino-anal resection.

Selection of cases.—There is no doubt that when there are irremovable distant secondary deposits, providing that the primary growth can be resected, palliative removal with restoration of continuity should be the aim. Radical restorative operations are reserved for early growths situated above the pelvic peritoneal cul de sac. This usually means that the lower edge of the growth is not less than 10 cms. from the anal orifice. Resection of bulky growths with evidence of extrarectal spread will increase the chances of local recurrence involving, as it does, the anastomosis or retained bowel. This sequela of the operation makes the patient's lot a very unhappy one and should be avoided.

Anaplastic neoplasms are likewise unsuitable for restorative operations.

An adequate length of viable proximal colon must obviously be available, and thus the vascular arrangement of the branches of the interior mesenteric artery is a limiting factor. Occasionally, however, mobilisation of the splenic flexure and transverse colon, supplied by the left branch of the middle colic artery, will allow this portion of the bowel to be brought down without tension to the depths of the pelvis.

The build of the patient is also of consequence, since a stocky fat subject with a fat-laden short mesentery and a small pelvis will make the operation very difficult and therefore usually inadvisable. Diverticulitis or other pathological processes in the colon also preclude restoration of continuity.

The possibility of transplantation of malignant cells at operation should be borne in mind. An effort to minimise this is being made by the use of 1 in 500 perchloride of mercury at operation for swabbing the lumen of the bowel and its divided ends.

Whatever the final decision regarding these operations, it is felt that for growths situated in the rectosigmoid region (at the level of the promontory of the sacrum or just below) and most certainly for those of the lowest part of the sigmoid colon, combined excision will give place to a Restorative Operation.

Team work, careful selection of cases, meticulous technique are all necessary for the best results, but time is also essential for a clear assessment to be made of the place of restorative procedures in the treatment of carcinoma of the rectum.

REFERENCES

BACON, H. E. (1949) *Anus, Rectum, Sigmoid Colon: Diagnosis and Treatment.* 3rd Edit. Philadelphia and London. Lippincott.
DUKES, C. E. (1944) *Proc. R. Soc. Med.* **37**, 131.
GABRIEL, W. B., DUKES, C. and BUSSEY, H. J. R. (1935) *Brit. J. Surg.* **23**, 396.
GILCHRIST, R. K. and DAVID, V. C. (1947) *Ann. Surg.* **126**, 421.
GOLIGHER, J. C. (1949) *Brit. J. Surg.* **37**, 157.
LLOYD-DAVIES, O. V. (1939) *Lancet* **2**, 74.