

## THE CAVIAR LESION UNDER THE TONGUE

By WILLIAM BENNETT BEAN, M.D.

IOWA CITY

Every now and then my curiosity gets me into trouble. Something excites my interest which has not stimulated anyone else to make systematic observations.

In clinical medicine the tongue has been the cynosure in deficiency disease, weather vane of fluid balance, milestone in estimating anemia, landmark of cyanosis and the traditional key to diagnosis of our medical forefathers. Thus one would suppose the tongue to be barren of new clinical interest. Strangely, the lower surface of the tongue has not had the attention given to the more readily inspected tip, dorsum and sides. Hidden along the under surface of the tongue may be found clusters of small dilated and varicose veins which occasionally reach a large size and occupy almost the whole under surface of the tongue. Their round shape and black color has suggested a resemblance to caviar, whence the title of this paper which considers their clinical significance.

At the outset it is appropriate to review the structures which appear on the under surface of the tongue. Even anatomical texts have a uniform vagueness about the structures which present themselves to view when the lower surface of the tongue is inspected. Going from the root of the tongue to the tip the structures are as follows: (1) The centrally placed ostia of the sublingual gland ducts in an elevation from which (2) the frenulum takes its origin. Usually there are two sets of veins which can be seen without difficulty; (3) the superficial dark blue sublingual veins and, more centrally placed and deeper in the tongue. (4) the ranine veins which appear as rather light blue translucent strips beneath

---

From the Department of Medicine of the College of Medicine of the State University of Iowa and the University Hospitals, Iowa City, Iowa.

the somewhat triangular shaped (5) plica fimbriata. There is a remarkable variation from one person to another in the size and location of veins. In some along the lateral margin running down into the ranine veins at an angle which points to the tongue's base are many connecting veins and venules. In other persons these are not seen. The main arterial supply and the main collecting veins of the tongue in its free and distal portions are near the lower surface whereas the upper three-fourths is composed chiefly of muscle tissue and surface structures. The mucosal surface of the lower portion of the tongue is extremely thin and translucent. This permits ready inspection of submucosal vascular structures. Furthermore, the supporting connective tissue framework is fragile and ill-developed so that dilatation and varicose changes may occur as a result of stimuli which do not have such pronounced effects in centrally located veins or in those with firmer support.

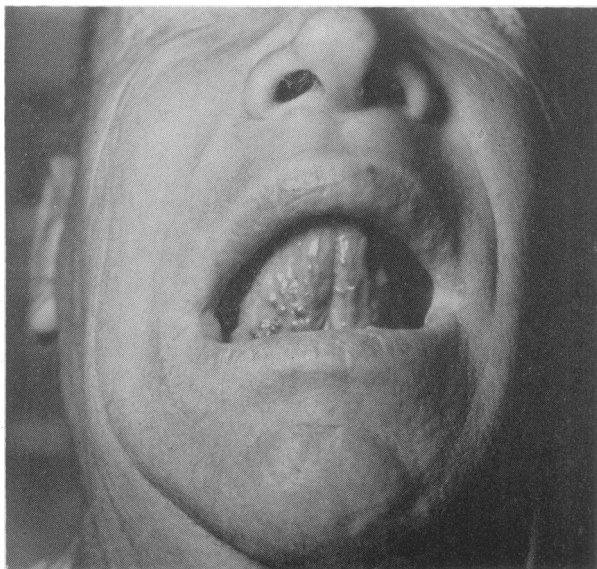


FIGURE 1. Scattered caviar lesions both medial and lateral to the sublingual veins.

The caviar lesion, (Fig. 1.) a roughly spherical varicose enlargement in the collecting vein system, occurs in three sites. The commonest is along the large superficial veins under the surface of the tongue lateral to the sublingual vein. Frequently it is in the small connecting channels which link the ranine veins and the lateral lingual veins. The next commonest location is in the floor of the mouth near the ostia of the sublingual glands. The third location is along the under surface of the lateral portions of the tongue. All these regions may be affected. It is very rare to find caviar lesions on the lateral aspect or near the ostia of the ducts without their being more plentiful and larger along the main collecting system of veins. (Fig. 2.)

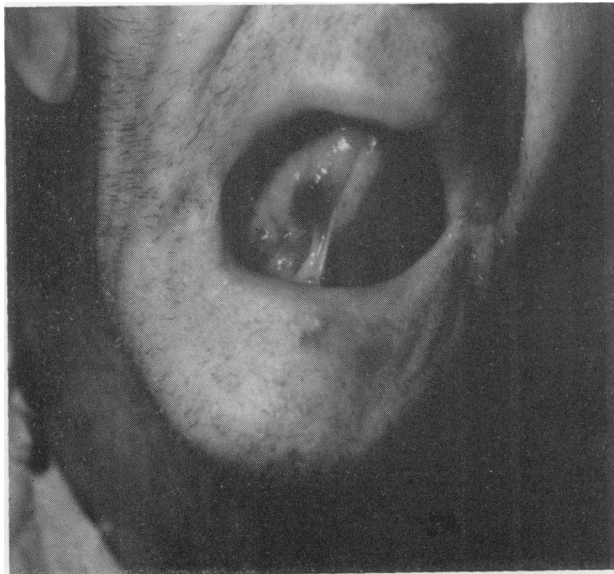

FIGURE 2. Infrared photograph of a large caviar lesion.

The earliest change is a small outpouching at a branch of one of the communicating veins, with no elevation of the overlying mucosa. Later such small varicosities become more numerous and

when they reach the size of  $\frac{1}{2}$  mm. they elevate the overlying thin glistening mucosa. The dark color suggests buckshot or caviar with an iridescent surface.

#### OBSERVATIONS

Although it is difficult for most patients to elevate and hold the tongue so that these vascular lesions are clearly exposed, occasionally patients can cooperate well and one can examine them at leisure and test the effect of pressure. If a glass slide is pressed against the surface one observes the lesion disappear as the blood is squeezed into one of the larger connecting vessels. As soon as the pressure is released the varicule refills rapidly and within several seconds the external silhouette has resumed its previous contour. Where such changes are very profuse, knots and clusters of caviar lesions are found along both sides of the under surface of the tongue. Anatomically the caviar lesion is a dilated vein. Inflammatory changes are absent. The endothelium is hypoplastic but the wall is fairly thick and cellular.

I have examined the under surface of the tongue in 700 patients seen on the medical wards and in consultation. Their ages ranged from 16 to 85. At least 50 men and 50 women in each decade between the ages of 30 and 80 were examined. At the same time I looked for arterial spiders, venous stars, cherry angioma (commonly called senile angioma or de Morgan's spot) and palmar and plantar erythema. Chart 1 reveals that caviar lesions were not found before the 4th decade and were encountered only in a few women in the 4th decade. After this period they became increasingly frequent and their incidence rose rapidly with age especially in men; in women much less rapidly though by the 8th decade I found them slightly more commonly in women than in men. In the 40's and 50's men were affected twice as often as women and thereafter their incidence was approximately even. By the 60's and 70's roughly two-thirds of the persons examined had demonstrable caviar lesions. They were large and spectacular, however, in only about 5% of all persons who had them. There

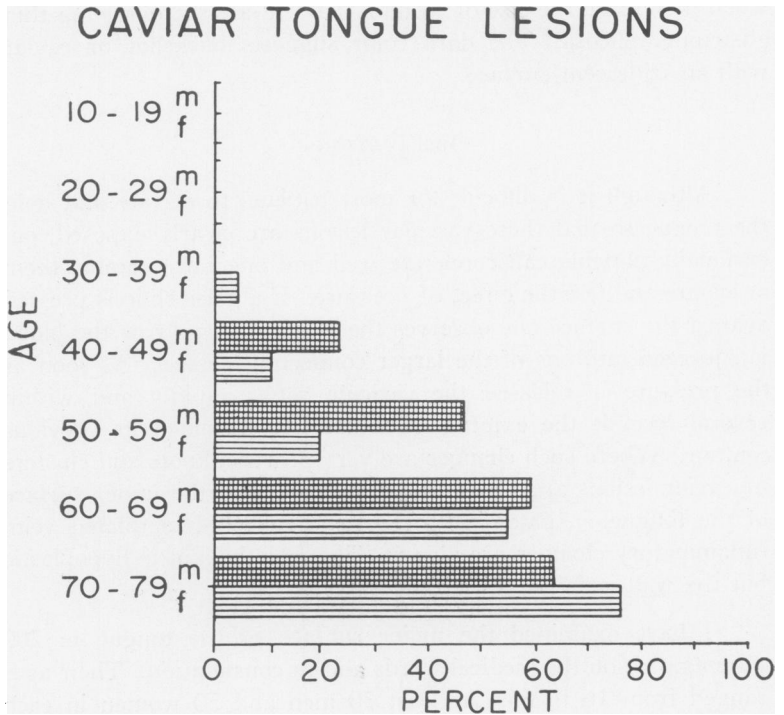


CHART 1. Incidence of caviar lesions by age and sex. Persons having even a single lesion were included.

was no clear correlation of caviar lesions with any disease of the vascular system: arteriosclerosis which was relatively mild in the very old patients, pulmonary disease, congestive heart failure, emphysema or chronic cough. The incidence of venous stars showed striking differences and some correlation with the caviar lesion. Venous stars began to become prevalent in the 20's and I have seen them in the teens. They were commoner in women than in men at all ages and at their greatest incidence did not affect more than half the group concerned. These points are brought out in Chart 2. Even more radically different is the incidence of the cherry

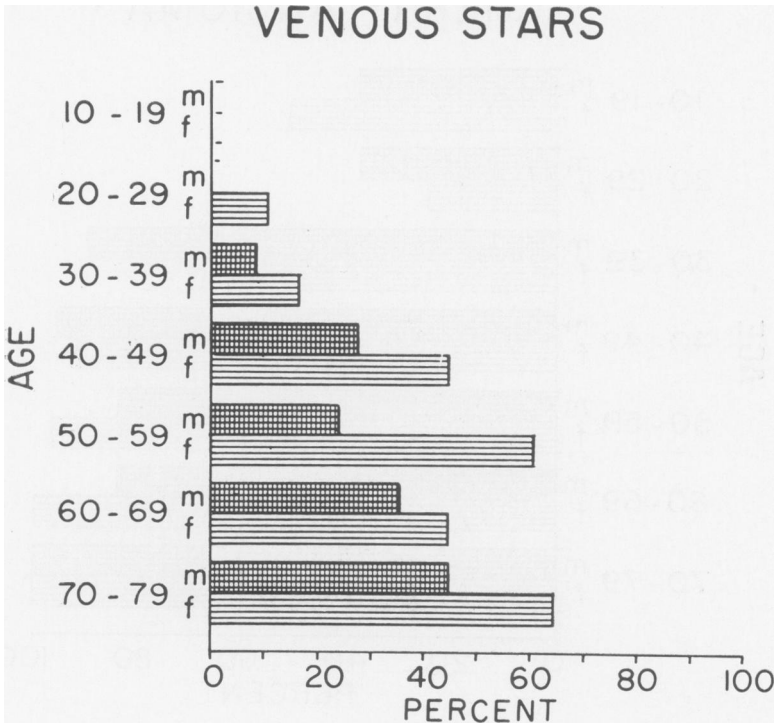


CHART 2. Incidence of venous stars by age and sex.

angioma, a term I have used instead of senile angioma since even in the second decade they occurred in more than a third of the persons examined. Chart 3 indicates the comparatively high incidence and the fact that they were encountered in all the very old persons examined. Chart 4 shows the age pattern of men and women who had cherry angiomas, venous stars and caviar tongue lesions and those who had none. Those in the younger age groups had a tendency to have none of the lesions whereas as age advanced frequently all three occurred.

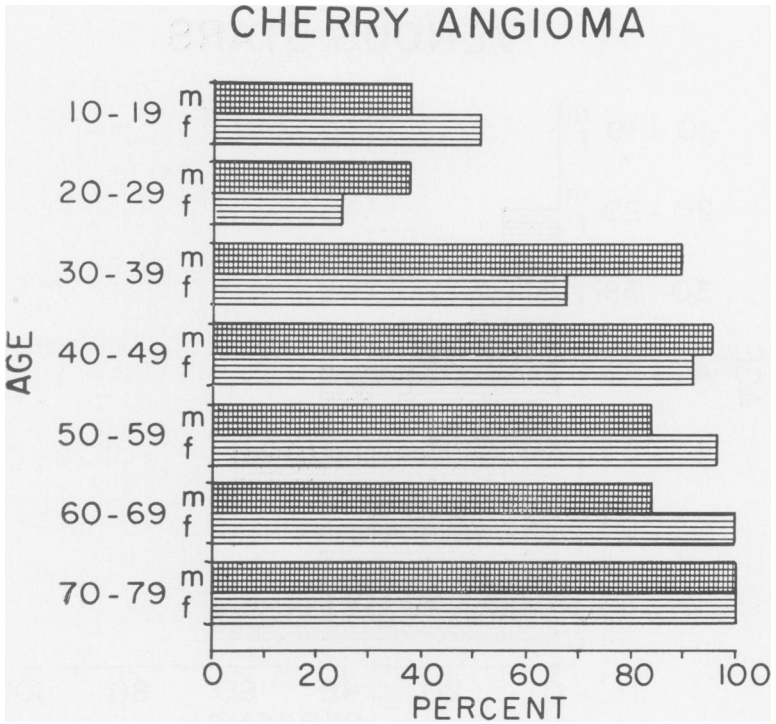


CHART 3. Incidence of cherry angiomas by age and sex.

Other observations include the comparison of black and white and infrared photographs. The results of such studies vary. Occasionally the lesions show up very poorly or disappear on infrared photography when they are clear in the ordinary black and white picture. Comparison with color photographs reveals that when the caviar lesion is pinkish or contains blood with a considerable component of oxyhemoglobin it disappears from view. When it is dark blue it shows up even better in infrared photographs than in black and white.

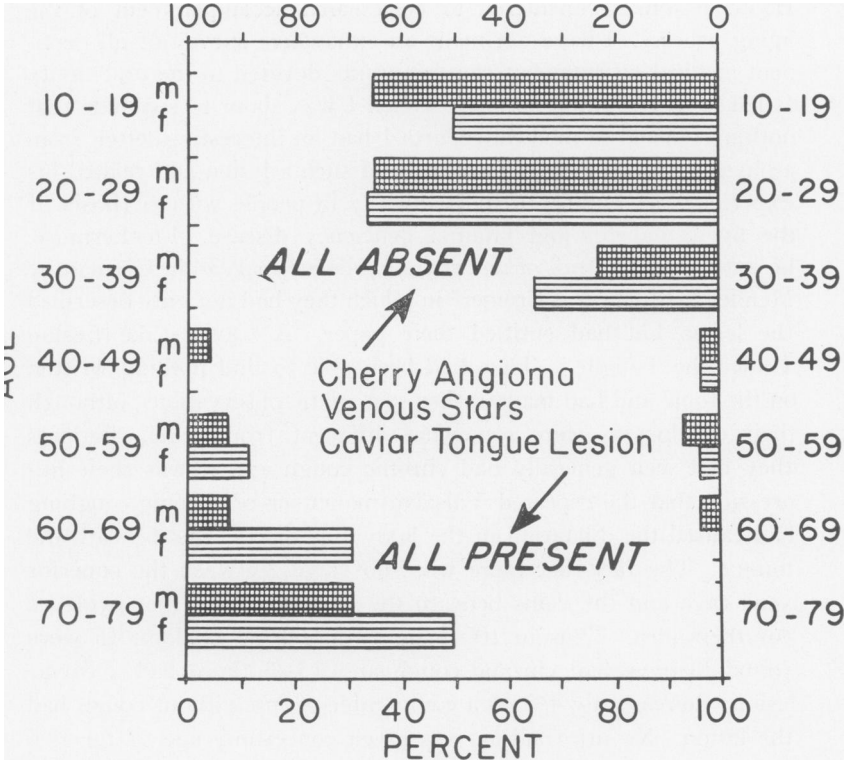


CHART 4. Age and sex distribution of persons with all three vascular lesions and those with none.

INTERPRETATION

A review of the state of health or kind of disease in all the patients examined failed to reveal any regular relationship with the presence or absence of the caviar lesion or the size and abundance of the lesions in person so affected. The only striking correlation was that of the increasing incidence with age. Since within the limitations of the observation the increase in age has not been correlated closely with cardiovascular or pulmonary disease, the



caviar lesion is considered to be a banal accompaniment of the aging process. I have not made an exhaustive survey of all pertinent medical writings but standard texts devoted to the oral cavity failed to discuss these lesions. When I was about to conclude that nothing existed in medical reports I had an interesting letter from a physician<sup>1</sup> who enclosed a picture of such a lesion and related his experience of finding them frequently in people with cirrhosis of the liver, diabetes and vitamin deficiency disease. Furthermore, he put me on the trail of an article published in 1930 in German by Mendes DaCosta and Cremer<sup>2</sup> in which they had not only described the lesion but had entitled their paper "A Caviar-Like Lesion Under the Tongue." They had been able to find nothing written on the topic and had made rather systematic observations, although their conclusions were somewhat different from mine. Patients they had seen generally had chronic cough and it was their impression that the repeated Valsalva maneuver of chronic coughing had caused the dilatation in the laxly supported veins beneath the tongue. The fact that there were no valves between the superior vena cava and the veins beneath the tongue was further evidence for their idea. Thus in 100 patients chosen at random, 15 were found to have had chronic cough and 13 of those had a caviar lesion whereas only 4% of a comparable group without cough had the lesion. No information was given concerning age of the two groups. My conclusion is that in spite of this one article there is not enough evidence that such lesions are connected with disease, emphysema, pulmonary or vascular disorders except insofar as these are commonly found in older people. Though the lesion has some superficial resemblance to the lymphangioma of the tongue, it can be distinguished from this more serious lesion by careful inspection. One patient I have encountered had been alarmed by her physician because of the possibility that the caviar lesion was a neoplasm and on this point I was able to put her mind at rest. Having observed them in a few people over a period of many years. I have found no evil consequence. I therefore conclude that they are lesions whose only significance is that they are insignificant.

At the risk of seeking dignity for clinical trivia and exceeding the bounds of modest decorum and dusty propriety I conclude with a few words wrenched from Act I, Scene I of Shakespeare's Coriolanus

. . . "and small inferior veins  
From me receive that natural competency  
Whereby they live."

#### REFERENCES

1. WANNAMAKER, C. C.: Personal Letter.
2. DA COSTA, S. M. and CREMER, G.: Kaviarähnliche Körner unter der Zunge, *Dermat. Wochenschrift* 91: 1206, 1930.

#### DISCUSSION

DR. JOHN B. YOUMANS (Nashville): I am sure we have all seen these dilated veins under the tongue. I am sure we have all wondered what they meant, if anything, but I know of no one who has come up with any particular idea regarding their meaning. I think very few, in fact I know of no one except Dr. Bean, who has done anything about it.

Generally, they are brought to my attention by the patient who worries about their significance. I have always told them I thought they had no significance. It is worthwhile pointing out that advances in medicine, most of them, come about because someone sees something that is unusual in his experience, wonders about it, and then does something about it. The number who do something about it is much smaller than the number who just see it and wonder. It is a very fine thing, indeed, that we have the people with Dr. Bean's insatiable curiosity which forces them to go ahead and do something about it.

DR. F. JANNEY SMITH (Detroit, Michigan): I would like to ask Dr. Bean if he has noticed any relationship between cardiac failure and this condition. I have had one such patient with an extremely marked caviar lesion in whom the veins were so dilated that he had difficulty in talking and using his tongue, and at the time I first saw him, he was in cardiac failure. He was a man about fifty. After he was successfully treated for congestive failure, there was enough decrease in the size of the vessels that his speech became practically normal, and there was a good deal of relief from his complaint of "thick tongue."

DR. FRANK EVANS (Pittsburgh): I would like to ask if there is any relationship to age and to stilbestrol. A lady of 90, whom I have treated for 25 years and who had these lesions under her tongue, developed a carcinoma of the breast for which stilbestrol was prescribed. When it was stopped menstrual bleeding occurred and the lesions under the tongue which had become worse receded.

DR. THOMAS E. MACHELLA (Philadelphia, Penna.): Before I heard Dr. Bean's fine paper, I wondered whether the type of lesion he was going to describe resembled black or pink caviar. Since he has described a lesion resembling black caviar, the opportunity presents itself to say a few words about the one which looks like the yellow or pink variety. I am sure Dr. Bean is familiar with it.

The lesion which resembles yellow or pink caviar is well known to dermatologists as lymphangioma circumscripta; other names are, lupus lymphaticus, lymphangioma capillare varicosum and lymphangioma cavernosum. It consists of small deep seated vesicles with normal mucous membrane or skin between and resembles frogs "spawn." The vesicle may be colorless, yellow, pink, or have a rose tint. The vesicles occur in groups, 8 to 20 mm. in diameter, in various parts of the body: upper part of the extremities, axilla or mucous membrane of mouth, pharynx, or tongue. The contents of a vesicle consist of clear fluid or of coagulated lymph and lymphocytes. In most instances, the lesion is of congenital origin, tends to persist, and only occasionally regresses.

DR. THOMAS HALE HAM (Cleveland, Ohio): I wonder if Dr. Bean would comment on the relationship of these lesions to the progressive development of hereditary telangiectasia? I gather, although I do not pretend to understand, that as the owner of that particular ailment increases in age, the lesions change considerably. I wonder if you could instruct us on that?

DR. JOSEPH H. HOLMES (Denver): In trying to collect salivary samples, either by cup or cannulae from submaxillary-sublingual ducts, we have frequently seen these caviar lesions and I am delighted to have a name for them. We have been impressed by the anatomical variations in this region especially in the edentulous person. I would like to ask Dr. Bean if he has noted these lesions more frequently in the edentulous person and if there is any correlation between occurrence of these lesions and the anatomy of this region.

DR. WILLIAM B. BEAN (Closing): I have enough questions to give another paper.

Dr. Smith, as far as congestive failure is concerned, we are all aware that we can observe increases in venous pressure in veins under the tongue.

In my experience, they are made more readily visible but do not actually grow under those circumstances. However, there still remains the theme of increase in venous pressure as an important cause, and since I think caviar lesions are small varicose veins, it is quite reasonable that people who have had repeated episodes of congestive failure display them.

Dr. Evans commented on age. These slides showed spectacular increase in such lesions with age. As far as estrogens having an effect on the vessels of the tongue, I believe that they have an effect on blood vessels all over the body, venous as well as arterial. However, I have not seen anyone who had a flare-up of such vascular lesions of the tongue under estrogen therapy. I have seen the development of mucosal spiders in the mouth under such circumstances.

I am glad Dr. Machella brought up the problem of other brands of caviar lesions. Lymphangioma may become a malignant tumor or it may be very much like the lymphangioma in other parts of the body, producing varicose lymphatics.

Dr. Ham's comment about the changes in vascular lesions in Osler's disease, hereditary telangiectasia, leads me to say this. Commonly, they are not seen in youngsters. Usually they appear between the age of puberty and the twenties. Bleeding often begins at the age of puberty. Serious bleeding is common in the thirties and forties and thereafter. The correlated observations on the pulmonary arterio-venous anastomosis is that they continue to grow and proliferate. They may recur in other lobes after removal of the lung or lobe of the lung. I thought of them as static, but now I am of the opinion that they are probably dynamic and may change slowly, fresh lesions developing and the new vessels lack the characteristic muscle and elastic support which normal vessels have. That is the characteristic lesion in Osler's disease.

I agree with Dr. Holmes that there is a remarkable variation in tongues, not only in what they say and what their surfaces show, but what lies beneath them. Anatomical textbooks are very vague about pattern. There is an enormous variation.

It might be apropos in this hotel to remind you that these caviar lesions, in terms of significance, are like Mark Twain's comment about the weather. Everyone talks about it, but no one does anything about it. Thank you.