

Accuracy of pregnancy diagnosis in swine by ultrasonography

Sara I. Williams, Pablo Piñeyro, R. Luzbel de la Sota

Abstract – Early and accurate diagnosis of nonpregnant sows and gilts has the potential to increase reproductive efficiency and the financial income in pig production by reducing non-productive days per sow per year. The objectives of this study were to compare the efficiency of pregnancy diagnosis between Doppler Echo⁺ and real time ultrasonography (RTU) and to compare the efficiency by using RTU at different days post-mating (days 17 to 24) under commercial conditions. In the 1st study, using crossbreed sows and gilts ($n = 107$), pregnancy diagnoses were done with Doppler Echo⁺ and then with RTU. Between 28 and 65 days of gestation, Doppler Echo⁺ had 85% sensitivity and 32% specificity, and efficiency was 73%. In the 2nd study, sows ($n = 142$) were scanned for pregnancy diagnosis between 17 and 24 d post-mating (PD1) and reconfirmed between 38 and 45 days of gestation (PD2). After 21 days of gestation, RTU had over 90% sensitivity and 45% specificity, and 70% efficiency. Accuracy between PD1-farrowing was 75.5% and between PD1 and PD2 was 80.6%. In the 3rd study, sows were diagnosed pregnant by RTU ($n = 151$) at 17 to 24 days of gestation or A-mode ultrasound ($n = 172$) at 28 to 30 days of gestation. There were no significant differences in conception rate ($P > 0.09$) and farrowing rate ($P > 0.67$) between both groups. Hence, there was no improvement in fertility and farrowing rate by using RTU instead of A-mode ultrasound under commercial conditions.

Résumé – Exactitude de l'échographie dans le diagnostic de gestation de la truie. Le diagnostic précoce et exact de la non-gestation chez les truies et les cochettes a le potentiel d'augmenter l'efficacité reproductive ainsi que les revenus tirés de la production porcine en réduisant le nombre de jours non productifs par truie par année. Les objectifs de cette étude étaient de comparer l'efficacité du diagnostic de gestation réalisé dans des conditions commerciales d'élevage par Doppler Echo⁺ et échographie en temps réel (ETR) et de mesurer l'efficacité de l'ETR à différents jours après l'accouplement (jours 17 à 24). Dans la première étude réalisée sur des truies et des cochettes de race croisée ($n = 107$), les diagnostics de gestation ont été fait avec le Doppler Echo⁺ puis avec l'ETR. Entre le 28^e et le 65^e jour de gestation, le Doppler Echo⁺ avait une sensibilité de 85 %, une spécificité de 32 % et une efficacité de 73 %. Dans la 2^{ième} étude, les truies ($n = 142$) ont été soumises à un échogramme pour le diagnostic de gestation entre les j. 17 et 24 après l'accouplement (AA1), puis de nouveau entre les j. 38 et 45 de gestation (AA2). Après 21 jours de gestation, l'ETR avait plus de 90 % de sensibilité, 45 % de spécificité et une efficacité de 70 %. L'exactitude entre AA1 et la mise bas était de 75,5 % et de 80,6 % entre AA1 et AA2. Dans la 3^{ième} étude, le diagnostic de gestation chez les truies ($n = 151$) a été effectuée par ETR entre 17 et 24 jours de gestation ou par échographie (mode) A ($n = 172$) entre 28 et 30 jours de gestation. Il n'y avait pas de différences significatives entre le taux de conception ($P > 0,09$) et le taux de mise bas ($P > 0,67$) entre les 2 groupes. Dans des conditions commerciales d'élevage, il n'y avait pas d'amélioration des taux de fertilité et de mise bas avec l'utilisation de l'ETR au lieu de l'échographie (mode) A.

(Traduit par Docteur André Blouin)

Can Vet J 2008;49:269–273

Introduction

Early and accurate diagnosis of nonpregnant sows and gilts has the potential to increase reproductive efficiency in pig production by reducing nonproductive days (NPD) per sow per year. Although using a boar for heat detection may have an accuracy of 98% (1), Glossop and Foulkes (2) have suggested

that the accuracy can vary widely between herds, and hence caution should be taken when used as method for detecting open sows returning to heat 21 ± 3 d after natural mating or after artificial insemination.

Several other methods have been used for pregnancy diagnosis. Such methods include the use of Doppler, A-mode

Instituto de Teriogenología (Williams, de la Sota); Instituto de Patofisiología (Piñeyro), Facultad de Ciencias Veterinarias, Universidad Nacional de La Plata, Calle 60 y 118, B1900AVW, La Plata, Argentina.

Address all correspondence and reprint requests to Dr. Sara I. Williams; e-mail: swilliams@fcv.unip.edu.ar

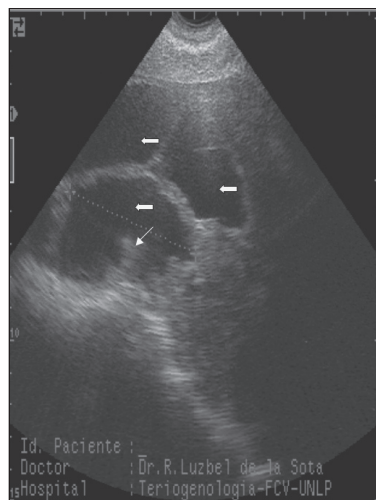


Figure 1. Pregnancy diagnosis before 35 d of gestation, visualizing the embryonic vesicle (↖) and the developing conceptus (→) (transabdominal scan, sector transducer).

ultrasound, B-mode ultrasound, or real time ultrasonography (RTU). The Doppler method allows identification of any liquid movement, such as blood flow in the middle uterine artery or umbilical arteries, and the fetal heart beat (3).

The A-mode ultrasound converts the returning sound wave echo signal in an audible tone or a green light (4). A positive result for pregnancy diagnosis is obtained when the sound waves reflect a structure full of liquid, such as a uterus with the fetal fluid, and the echo is converted into an audible tone. However, sound waves can be obtained from other fluid-filled structures, like the urinary bladder, leading to false positive diagnoses. Pregnancy diagnoses with Doppler and A-mode ultrasound can be performed by a nonveterinarian.

Real time ultrasonography produces a 2 dimensional real time image of the scanned tissues on a screen. A hand transducer that emits and receives the sound waves that penetrate the tissues produces the images. Differences in the density of tissues are displayed on the screen as a series of dots, in a 256-tones grey scale (from black to white). There are sector or linear transducers with different frequency ranges (3.5, 5.0, 6.0, 7.5, 8.0, and 10 MHz). The B-mode RTU is useful in swine production to diagnose pregnancy at 21 ± 3 d postmating, to reconfirm pregnancy between 42 and 63 d postmating, and to diagnose ovarian and uterine lesions (4–6). In all cases, infertile sows can be culled immediately. Because the gynaecological examination by ultrasonography requires a thorough knowledge of anatomy, physiology, and pathology, this technique must be performed by a veterinarian.

Both Doppler and A-mode ultrasound are inexpensive and easier to use, but they produce more false positive and false negative diagnoses and they cannot be used before 30 to 35 d of gestation, in contrast to B-mode RTU, which allows pregnancy to be diagnosed at 21 d postmating (5–12) with more sensitivity, specificity, and an efficiency of close to 95% (9,13–14). Furthermore, B-mode RTU can also be used as early as day 18 to 22 postmating to decide immediately if open sows will be induced to estrus or culled from the herd.

Table 1. Sensitivity, specificity, predictive value of a positive result, and efficiency of Doppler Echo⁺ compared with that of real time ultrasonography

	28 to 63 d of gestation	28 to 35 d of gestation	36 to 63 d of gestation
Sensitivity	85%	87%	83%
Specificity	32%	31%	33%
Predictive value of + result	80%	83%	78%
Efficiency	73%	—	—

The objectives of this study were 1) to evaluate the efficiency of pregnancy diagnosis with Doppler Echo⁺ compared with RTU, between 28 to 63 d postmating, 2) to determine the efficiency of pregnancy diagnosis by RTU between 17 to 24 d postmating, and 3) to evaluate the benefits of using RTU under commercial conditions.

Materials and methods

Trial 1

Efficacy of pregnancy diagnosis using Doppler and B-mode ultrasound — This study was done on a commercial swine herd, using a total of 107 crossbreed sows from different parities between 28 and 63 d of gestation. All females were bred by naturally and pregnancy diagnoses were done 1st with Doppler (Echo⁺; Medata, West Sussex, UK) and then with the RTU, using a sector transducer of 5.0/7.5 MHz, (Pie Medical S100; Maastrich, Holland).

To perform the diagnoses, females were placed in a crate to reduce forward and lateral movements and to allow easy access to the lateral abdominal wall. All the diagnoses were done transabdominally; a gel (Obstetrical lubricant; Gel PharmaClean, Brouwer de Koning y CIA, SA, Argentina) was applied to the sow's skin to obtain good transmission of the sound wave to and from the probe. The transducer was held against the gel on the ventral skin surface of the abdomen, cranial to the hind leg, ventral to the flank folds, but dorsal to the last 3 mammary glands.

For the RTU diagnosis, the probe was moved parallel to the sagittal axis of the sow, to scan the abdominal cavity, with the bladder serving as a point of reference. When RTU pregnancy was diagnosed before day 35 of gestation, visualizing the embryonic vesicles (least dense object, black or anechoic image, Figure 1) and the developing conceptus (more dense object, white or hyperechoic image, Figure 1) were the criteria used to diagnose a sow as being pregnant. After day 35 of pregnancy, visualizing fetal structures, such as heart beating, stomach cavity, spinal cord, and ribs, were the criteria used to diagnose a sow as being pregnant. The portable Doppler Echo⁺ model was manufactured without headphone and wires, and the returning sound wave was converted and displayed as a green light.

Sensitivity, specificity, predictive value of a positive result, and efficiency of Doppler diagnosis compared with RTU were calculated by using the Bayesian theory (15). The sensitivity was defined as the number of pregnant females diagnosed correctly/total number of females diagnosed as pregnant; the specificity as the number of nonpregnant females diagnosed

Table 2. Sensitivity, specificity, predictive value of a positive result, and efficiency for pregnancy diagnosis with real time ultrasonography between 17 and 24 d postmating compared with farrowing results.

	Days postmating			
	17 to 18 (n = 35)	19 to 20 (n = 46)	21 to 22 (n = 43)	23 to 24 (n = 18)
Correctly diagnosed pregnant	19	24	28	14
Incorrectly diagnosed pregnant	8	13	7	2
Correctly diagnosed open	4	4	2	1
Incorrectly diagnosed open	4	5	6	1
Sensitivity (%)	82.6	85.7	93.3	93.7
Specificity (%)	33.3	27.8	46.1	33.3
PPR ⁺ (%)	70.3	64.8	80.0	88.2
Efficiency (%)	65.7	60.8	69.7	83.3

PPR⁺ — predictive value of a positive result**Table 3.** Comparative results for conception and farrowing rate between groups (number of sows between brackets)

	RTU group	CON group
Conception rate	85.4% (129/151)	76.1% (131/172)
Farrowing rate	76.8% (116/151)	75.0% (129/172)

RTU — real time ultrasonography

CON — control (A-mode ultrasound)

correctly/total number of females diagnosed as nonpregnant; the predictive value of a positive result as the probability that pregnancy exists in a female diagnosed as pregnant; and the efficiency or accuracy was defined as the number of females diagnosed correctly (either pregnant or nonpregnant)/total females diagnosed.

The sensitivity, specificity, and predictive value of a positive result were calculated for all the sows scanned ($n = 107$), for those scanned for early pregnancy diagnosis (between 28 and 35 d of gestation, $n = 60$), and for those scanned between 36 and 63 d, postmating ($n = 47$). The efficiency was calculated for all sows scanned.

Trial 2

Efficacy of pregnancy diagnosis at different days postmating — The study was done on a commercial swine farm. A total of 142 sows (from different parities) were evaluated for pregnancy between 17 and 24 d postmating (PD1) and reconfirmed pregnant between 38 and 45 d of gestation (PD2). All females were bred naturally and kept in groups in stalls until day 30 postmating. Then, they were placed in individual crates. The RTU was performed transabdominally with a sector transducer of 5.0/7.5 MHz of frequency (Pie Medical S100). The females were moved to an individual crate adapted to reduce lateral movements during diagnosis. After the diagnosis had been made, the females were returned to the collective stalls.

The earliest positive pregnancy diagnosis was made when the image of small and dark anechoic circles was interpreted as the presence of fluid in the allantois, amnion, or both, within the uterine lumen (12,13). The RTU image of the embryonic conceptus was visualized as an echoic mass surrounded by the dark anechoic fluid of the vesicle (9,13).

Results at PD1 were divided into 4 groups: 17 to 18 d, 19 to 20 d, 21 to 22 d, and 23 to 24 d postmating. Sensitivity,

specificity, and predictive value of a positive result, and efficiency were calculated by using the Bayesian theory (15). The sensitivity, the specificity and the predictive value of a positive result were calculated between PD1 and farrowing, because of commercial conditions. The efficiency was calculated between PD1 and farrowing and between PD1 and PD2.

Trial 3

Advantage of using RTU versus A-mode ultrasound (CON) under commercial conditions — The study was done on a commercial swine herd with natural mating. All the sows were kept in collective stalls until 30 d of gestation and thereafter in individual crates. A total of 323 crossbred sows from different parities were randomly assigned to 1 of 2 methods for pregnancy diagnosis. All the females were controlled for heat detection twice daily, and then diagnosed for pregnancy by 1 of the following methods. In the early pregnancy diagnosis group (RTU, $n = 151$), sows were subjected to pregnancy diagnosis by real-time ultrasonography 17 to 24 d postmating, using a sector transducer of 5.0/7.5 MHz of frequency (Pie Medical S100). The diagnoses were done transabdominally and all the sows were kept in an individual crate to reduce lateral and forward movement. In the control group (CON, $n = 172$), pregnancy diagnosis was performed at 28 to 30 d of gestation with A-mode ultrasound. To perform A-mode diagnosis, the probe was held in the same place as in RTU method. A positive result for pregnancy was obtained when the sound waves reflected a structure full of liquid and converted the echo to an audible tone. Conception and farrowing rates of the 2 groups were compared by the chi-square test.

Results

Trial 1

Efficacy of pregnancy diagnosis using Doppler and B-mode ultrasound — The sensitivity, specificity, and predictive value of positive result values for all the scanned sows ($n = 107$), for those scanned for early pregnancy diagnosis (between 28 and 35 d of gestation, $n = 60$), and for those scanned for pregnancy diagnosis 36 to 63 d postmating ($n = 47$) are shown in Table 1. For all the sows studied, the efficiency (percent of correct pregnant and nonpregnant diagnosis) of Doppler Echo+ compared with RTU was 73%.

Trial 2

Efficacy of pregnancy diagnosis at different days postmating — Table 2 shows the sensitivity, specificity, and predictive value of a positive result comparing results from PD1 with farrowing, using RTU. The efficacy between PD1-farrowing was 75.5%, and between PD1-PD2, 80.6%.

Trial 3

Advantage of using RTU versus A-mode ultrasound (CON) under commercial conditions — There were no significant differences in the conception and the farrowing rate between the CON and the RTU group ($P > 0.09$; $P > 0.67$; Table 3).

Discussion

Based on these results, Doppler Echo⁺ had an adequate sensitivity but a very low specificity, thereby missing nonpregnant females. Furthermore, the sensitivity values for Doppler Echo⁺ compared with these for RTU in this study are lower than those reported for other pregnancy diagnosis methods. Moriyoshi et al (16) reported a sensitivity of 97.6% when comparing progesterone in feces with RTU at day 20 to 25 of gestation; whereas, Vos et al (17) reported a similar value (96.5%) for fecal estrones, compared with RTU, on day 26 to 32 of gestation.

Flowers et al (13) compared the sensitivity and specificity of A-mode and B-mode ultrasound with farrowing results. Although they reported sensitivity greater than 96% for both methods, A-mode ultrasound was less specific and could not detect nonpregnant sows, and the diagnoses were made 1 or 2 wk later than those made with RTU.

Based on the results from this study, Doppler Echo⁺ has lower sensitivity, specificity, and efficiency compared with RTU. Therefore, when it is available, RTU should be selected as the preferable method for early pregnancy diagnosis. An accurate and early pregnancy diagnosis has immediate benefits; gilts and sows accurately diagnosed as nonpregnant by day 21 postmating/artificial insemination (AI) can be culled or rebred immediately, thereby significantly reducing nonproductive days in many herds. Culling open sows earlier allowed improved reproductive efficiency by increasing the farrowing rate and the number of piglets born per year, on a 100 sow basis.

The best time for pregnancy diagnosis is at 21 d postmating due to the accumulation of the fluid in the embryonic vesicle (13). Before this time, the images of the uterine horns are not as clear and confirmation of the presence of corpora lutea (ovarian images) is required (12). Sensitivity before 21 d of gestation reported in this study (17 to 18 d, 82.6%; 19 to 20 d, 85.7%) was higher than that reported by Flowers et al (13) (17 to 20 d, 78.3%). However, the sensitivity after 21 to 22 d of gestation in this study was lower than that reported by these authors (13) (93.3% versus 97.7%). Similar results were reported by Viana et al (14); in their study, who reported an increase in sensitivity from days 17 to 20, achieving 100% on d 21 of gestation.

In this study, specificity for days 17 to 18 (33.3%) and days 21 to 22 (46.1%) of gestation was lower than that reported by Flowers et al (13). They reported 50.4% specificity for days 17 to 20 of gestation and 62.1% for days 21 to 23 of gestation.

De Rensis et al (18) reported that efficiency for RTU post AI was 71%, 83%, 75%, and 91% on days 15, 16, 17, and 18 of gestation, respectively. Our results show a similar trend for the same days, but with lower values.

Serum progesterone concentrations have been used for early pregnancy diagnoses in sows. Sensitivity obtained measuring progesterone levels at 17 to 20 d after breeding was 94.6% and specificity was 35.7% (19). These values are similar to those reported with the use of RTU by us and others (13). However, when all sows returning to estrus outside the normal range of 18 to 24 d were excluded, the sensitivity dropped to 52.1%. Furthermore, sampling problems were reported in half of the farms studied. Hence, the use of progesterone as a diagnostic method may not be applicable in commercial units because of the sampling problems and because of irregular estrus returns that are not detected, thus reducing the sensitivity of the test. More recently, in another study in which progesterone levels were used as a diagnostic method between 17 and 22 d post AI, the accuracy for the positive and negative cases was 98.8% and 80%, respectively (20).

A single injection of a combination of equine chorionic gonadotrophin (eCG) and human chorionic gonadotrophin (hCG) was compared with RTU at 16 to 19 d postmating as a method of early pregnancy diagnosis (21). The results from this experiment showed no significant differences in accuracy and farrowing rate between the 2 groups, although the authors reported a lower time allotted for diagnosis and a lower cost per sow with gonadotropin, the routine use of hormones in all sows may be questionable.

With RTU, the sensitivity and the predictive value of a positive result increased with days postmating, because the images obtained were clearer as gestation progressed. The later in gestation the diagnosis is made, the higher the chances are of having a higher efficiency.

The swine farm where this study was performed had a high overall conception rate (pregnant sows at day 21/total females mated, 82.4%) and farrowing rate (number of females that farrowed/total females mated, 74.2%). Therefore, when the RTU and CON groups were compared, the RTU conception rate was numerically higher but not significantly different (Table 3). It is very likely that if a greater number of animals were included in the field trial, these differences would become significant. Nevertheless, diagnosis of nonpregnant sows by RTU allows remating sows earlier with an improvement in the conception rate and a reduction of nonproductive days.

Because the initial cost of purchasing the RTU equipment is constantly diminishing and the size of the herds is increasing, in large herds where the conception rate is low, use of the RTU technique may have a great economic impact.

In conclusion, Doppler Echo⁺ had lower sensitivity, specificity, predicted value of a positive result, and efficiency for early pregnancy diagnosis compared with RTU at both 28 to 35 d and 36 to 63 d of gestation. The efficiency of RTU increased from 17 to 24 d postmating. There was no improvement in fertility and farrowing rates by using RTU over A-mode ultrasound under commercial conditions.

CVJ

References

1. Almond GW, Dial GD. Pregnancy diagnosis in swine: a comparison of the accuracies of mechanical and endocrine tests with return to oestrus. *J Am Vet Med Assoc* 1986;189:1567–1571.
2. Glossop CE, Foulkes JA. Occurrence of two phases of return to oestrus in sows on commercial units. *Vet Rec* 1998;122:163–164.
3. Weiss G. Possibilities and limits of pregnancy diagnosis in domestic animals using the ultrasonic Doppler technique. *Schweiz Arch Tierheilkd* 1975;117:123–134.
4. Taverne MA, Oving L, van Lieshout M, Willemse AH. Pregnancy diagnosis in pigs: a field study comparing linear-array real-time ultrasound scanning and amplitude depth analysis. *Vet Q* 1985;7:271–276.
5. Inaba T, Nakazima N, Matsui N, Imori T. Early pregnancy diagnosis in sows by ultrasonic linear electronic scanning. *Theriogenology* 1983;20:97–191.
6. Botero O, Martinat-Bottè F, Bariteau F. Use of ultrasound scanning in swine for detection of pregnancy and some pathological conditions. *Theriogenology* 1986;26:267–278.
7. Kauffold J, Ritcher A. Two years of ultrasonography in swine gynaecology-experiences [abstract]. *Reprod Dom Anim* 1997;32:S 115.
8. Kauffold J, Ritcher A, Sobiraj A. Results and experiences of a two-year investigation in the use of sonographic pregnancy control in sows at different stages of gestation *TierärztlPrax* 1997;25:429–37.
9. Kauffold J, Richter A, Sobiraj A. Ultrasonography in swine gynaecology — Applications and perspectives. *Proc Int Conf Pig Prod, Beijing, 1999:647–651.*
10. Waberski D, Weitze KF. Sonographic diagnosis of reproductive failures in the pig — New aspects. *Prakt Tierarzt* 1998;79:41–44.
11. Waberski D, Kunz-Schmidt A, Wagnerrietschel H, Kerzel I, Weitze KF. Ultrasonography in swine gynaecology — Possibilities and limits. *Prakt Tierarzt* 1998;79:257–262.
12. Knox RO, Althouse GC. Visualizing the reproductive tract of the female pig using real-time ultrasonography. *Swine Health Prod* 1997;4:207–215.
13. Flowers WL, Armstrong JD, White SL, Woodard TO, Almond GW. Real-time ultrasonography and pregnancy diagnosis in swine. *Proc Am Soc Anim Sci Indianapolis, 1999:1–9.*
14. Viana CHC, Gama RD, Vianna WL, Alvarenga MFV, Barnabe RC. Avaliacao do desempenho da técnica de ultra-sonografia, para o diagnostico precoce de gestacao, em femeas suinas. *Proc X Cong Brasileiro Vets Especialistas Suinos, Brasil, 2001:187–188.*
15. Martin SE, Meek AH, Willeberg P. *Veterinary Epidemiology. Principle and Methods.* Iowa State Univ Pr, 1987:343–354.
16. Moriyoshi M, Nozohi K, Ohtaki T, Nakada K, Nakao T. Early pregnancy diagnosis in the sow by fecal gestagen measurement using a bovine milk progesterone qualitative test EIA kit. *J Reprod Develop* 1997;43:345–350.
17. Vos EA, van Oord R, Taverne MAM, Kruip TAM. Pregnancy diagnosis in sows: direct ELISA for estrone in feces and its prospects for an on-farm test, in comparison to ultrasonography. *Theriogenology* 1999;51:829–840.
18. De Rensis F, Bigliardi E, Parmigiani E, Peter AR. Early diagnosis of pregnancy in sows by ultrasound evaluation of embryo development and uterine echotexture. *Vet Rec* 2000;147:276–270.
19. Glossop CE, Foulkes JA, Whitworth A, Cornwell E. Use of an on-farm progesterone assay kit to determine pregnancy in sows. *Vet Rec* 1989;124:115–117.
20. Chadio S, Xylouri E, Kalogiannis D, Michalopou E, Evagelatos S, Menegatos I. Early pregnancy diagnosis in swine by direct radioimmunoassay for progesterone in blood spotted on filter paper. *Anim Reprod Sci* 2002;69:65–72.
21. Krüger D, Bilkei G. Comparison of efficacy and costs between real time ultrasonography (RTU) and gonadotropin estimation for pregnancy diagnosis. *Pig J* 2002;50:93–100.