

CASE REPORT

Fibrous Dysplasia of the Cranial Bones: A Case Report and Review of the Literature

Pervin K. Iseri,^{a*} Husnu Efendi,^a Ali Demirci,^b
and Sezer Komsuoglu^a

^a*Department of Neurology, University of Kocaeli, Derince, Izmit, Turkey and*

^b*Department of Radiology, University of Kocaeli, Derince, Izmit, Turkey*

Fibrous dysplasia (FD) is a relatively uncommon disorder that affects primarily the cranial region; its occurrence in the cranial base in combination with hindbrain herniation and aneurysmal bone cyst (ABC) constitutes an extremely rare condition. We report a case of polyostotic fibrous dysplasia with progressive occipital, temporal, and clival involvement. Clinical findings and differential diagnosis with special emphasis on the imaging features were discussed. A small posterior fossa volume has been thought to lead to hind brain herniation. The resultant obstruction to the CSF pathways at the level of the foramen magnum has been implicated in the development and subsequent progression of syringobulbia.

INTRODUCTION

Fibrous dysplasia (FD) is characterized by slow, progressive replacement of a localized area of bone by an abnormal proliferation of isomorphic fibrous tissue intermixed with poorly formed, haphazardly arranged trabeculae of woven bone [1]. In 1937, McCune and Bruch first suggested that among all of the abnormalities of bone formation, this disorder should have its own place as a distinct clinical entity. The following year, Lichtenstein introduced the term “fibrous dysplasia” [2]. The lesion of fibrous dysplasia appears in three distinctive clinical patterns: 1) single bone involvement (monostotic form), which is the most common

presentation (70 percent of patients); 2) multiple bone involvement (polyostotic form), a less common form (30 percent); 3) McCune-Albright syndrome, a rare variant of polyostotic form with pigmentation and endocrinologic abnormalities [3].

Cranial bone involvement of FD usually presents as an enlarging mass with symptoms resulting from the mass effect exerted by the lesion. Abnormalities in the posterior fossa have been implicated in the pathophysiology of hindbrain herniation which has been thought to be responsible for the occurrence of syringobulbia [4].

Aneurysmal bone cyst (ABC) is viewed as a secondary, uncommon, reactive lesion of bone, consisting of an arterio-venous malformation. ABC occurs

*To whom all correspondence should be addressed: Dr. Pervin K. Iseri, Department of Neurology, University of Kocaeli, Derince, Izmit, Turkey, E-mail: pervin.iseri@gmail.com. Tel.: 90-262-332-21-60. Fax: 90-262-233-54-61. GSM: 90-532-500-07-66.

†Abbreviations: ABC, Aneurysmal bone cyst; CSF, cerebrospinal fluid; FD, fibrous dysplasia; MRI, Magnetic resonance imaging.

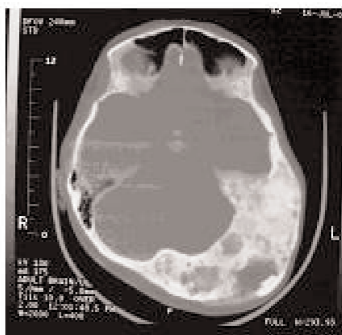

Figure 1

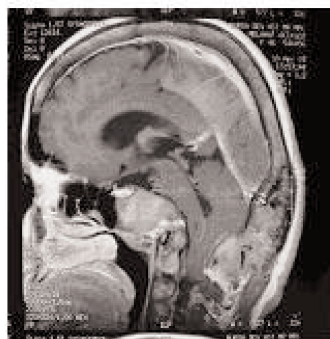


Figure 2

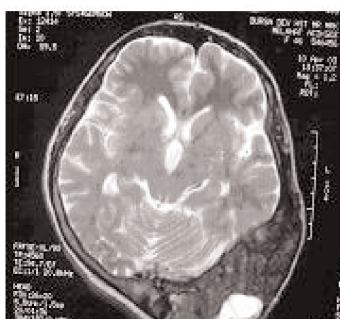


Figure 3

Figure 1. (cranial CT findings) : Computerized axial tomographic scan showing the expansion of the occipital bone with “ground glass” appearance of fibrous dysplasia.

Figure 2. (cranial MRI findings): Sagittal magnetic resonance image showing fibrous dysplasia of occipital bone and clivus and hind brain herniation.

Figure 3. (cranial MRI findings): Axial T2-weighted magnetic resonance image showing fibrous dysplasia of temporal, occipital bones and skull base with an associated ABC of the occipital bone.

most commonly in long bones. One of the primary diseases that may be associated with ABC is FD. Only a few cases of ABC affecting the cranial bones with fibrous dysplasia have been reported [3, 5, 6].

To the best of our knowledge, in the English literature, case reports with the diagnosis of FD do not include all of these symptoms together. In this paper, we report the case of a patient with FD of occipital, temporal, parietal bones, clivus and skull base in combination with ABC, hindbrain herniation, and syringobulbia.

CASE

A 35-year-old woman presented with gait disturbance, swallowing difficulty, slurring of speech, vertigo, and altered sensation of hands. These problems had been progressive over the last several months and were accompanied by progressive hearing loss and tinnitus in the left ear. More recently, the patient had developed hoarseness. Her physical exam-

ination revealed a bulging, slightly tender mass over her left occipital area. No café-au-lait spots or other skin stigmata were found. Neurological examination showed horizontal nystagmus, diminished gag reflex, wasting and weakness of both upper limbs, pyramidal signs in the lower extremities, and dissociated sensory loss C4 to C8 dermatomes. Serum levels for alkaline phosphatase, calcium, and PO₄ were normal. Detailed endocrinological tests, including thyroid and parathyroid function tests and serum hormone levels (ACTH, growth hormone) were performed, and normal values were obtained.

CT of the head showed fibrous dysplasia of the clivus, temporal, occipital bones and skull base with an associated ABC of the occipital bone (Figure 1). Magnetic resonance imaging (MRI) confirmed the findings of FD, hind-brain herniation, syringobulbia, and ABC (Figures 1 and 2). A radionuclide bone scan skeletal survey was performed. She had cranial bone involvement without manifestations

in the remainder of the body. An audiogram demonstrated an ipsilateral conductive hearing loss of 65 dB. Brainstem auditory evoked responses confirmed the retrocochlear involvement of the auditory nerve on the left side.

The patient was consulted by neurosurgery and ENT surgeons. Total removal of the lesion was considered impossible to perform, and a surgical posterior decompression was decided upon. The patient was advised of the unpredictability of FD and recommended decompression of the skullbase, but she did not accept the operation due to high surgical risks that were explained to her.

Since the patient refused surgery, we had planned to treat her with alendronat monosodium trihydrate, which is a bisphosphonate. In addition, serial CT scanning was planned to follow the disease process and progression. She is still on medical therapy and has no progression.

DISCUSSION

Fibrous dysplasia of the cranium is a well-described entity of unknown etiology in which normal bone is replaced by abnormal fibro-connective tissue proliferation [1, 5-7]. Polyostotic FD involving the skull base and ABC of the occipital bone are rare diseases. In addition, only one case with hindbrain herniation and syringobulbia due to FD of skull base has been reported [4]. Our case deserves a special attention that both ABC and syringobulbia due to FD appeared on the same patient.

In the polyostotic form with extensive skeletal dissemination, the incidence of craniofacial involvement increases to 100 percent [8, 9]. The incidence of the location of the FD lesions involving the cranium is controversial. In one study, it was suggested that the most affected cranial bones are the ethmoid (71 percent), sphenoid (43 percent), frontal (33 percent), maxillary bones (29 percent), and less fre-

quently involved are the temporal (24 percent) and occipital bones (5 percent) [5]. In other studies, it was reported that the frontal bones were most commonly involved followed by the sphenoid, ethmoid, parietal, temporal, and occipital bones [8, 10]. Our case was a polyostotic fibrous dysplasia involving clivus, occipital, parietal, and temporal bones. Due to intense occipital involvement, the foramen magnum was narrowed. The dysplastic growth of the bone of the posterior fossa has led to progressive hindbrain herniation through the foramen magnum and development of a syringobulbia [4].

In the case of FD of the skull base and cranium, the natural history of the disease can be more complicated because of the possibility of neural structure impingement. Craniofacial lesions usually present with symptoms resulting from the mass effect exerted by the lesion. Expansive lesions of the bony jugular foramen may encroach on lower cranial nerves and may cause cranial neuropathies [11]. In this case, complications of cranial base FD were caused by jugular foramen and fossa involvement resulting in IX and X nerve paralysis. In addition, impingement of neurovascular structures due to hindbrain herniation, secondary to decreased posterior volume, resulted in abnormal cerebellar findings, syringobulbia, and retrocochlear involvement of the 8th nerve. In the chiari malformation, decreased volume of the posterior fossa has been thought to be responsible for the occurrence and progression of hindbrain herniation, which causes augmentation of cerebrospinal fluid (CSF) pressure [12]. The theory of craniospinal CSF pressure dissociation has been suggested to explain the syringomyelia [13]. Assuming the above relationship is valid in our patient, slow progression of hindbrain herniation secondary to FD could be the cause of syringobulbia.

The majority of published cases of FD report an early age of onset of symptoms

[14]. In our patient, symptoms of hindbrain herniation did not manifest until the third decade of life. This may be explained by the very slow progression of disease that began early in development.

The radiographic characteristics of FD, as described by Fries in 1957, are pagetoid (56 percent), a mixture of dense and radiolucent areas of fibrosis; sclerotic (23 percent), massif homogeneously dense; and cystic (21 percent), a spherical or ovoid lucency surrounded by a dense boundary [1]. CT is the study of choice for diagnosis and follow-up because of its superior bony detail and accurate assessment of extent of the lesion. Furthermore, CT can often assist with differentiating fibrous dysplasia from other osteodystrophies of the skull base, including otosclerosis, osteogenesis imperfecta, Paget disease, and osteopetrosis [5]. In our case, a CT of the brain was performed and revealed findings consistent with FD of the clivus, left temporal, and occipital bones. In addition to hindbrain herniation and syringobulbia, aneurysmal bone cyst formation with a bony shell and soft tissue-appearing center was also readily apparent on MRI. Although the development of ABC is a well-known occurrence throughout the skeletal system, they have not been frequently described within the skull base [5]. The occurrence of a concomitant FD and ABC in the occipital bone is exceedingly rare. Only three cases of FD and ABC affecting the cranial bones have been reported [3, 5, 6].

The onset of craniofacial involvement is usually insidious, characterized by a barely noticeable, gradually increasing, painless swelling in the neurocranium. Although FD is a benign and slowly progressive disorder, in the late stage of the disease expansion of the cranial bones can cause mass effect on the cranial structures. As in our case, the progressive growth of these lesions may cause difficulties in management. When the disease produces symptoms, conservative treatment is the

preferred management. Subtotal resection with close follow-up is required, particularly if important and vital structures are placed at risk [5]. Radiation therapy is ineffective and contraindicated because of possibility of malignant transformation [8]. Some pharmacological agents recommended avoiding the progress of the disease. Although bisphosphonates have been used for treating patients with osteodystrophies, their effects have been limited in patients with FD. Bisphosphonates effects by inhibiting osteoclastic bone resorption and limits expansion of the bone. In the absence of curative medicine for fibrous dysplasia, surgery becomes the major therapy. In this patient, we had to use the medical therapy since she did not pursue posterior decompression surgery.

FD of cranial bones is a progressive disease that can cause severe complication if removing of the dysplastic tissue cannot be done in the early stage of the disease, as in our patient. In some studies, it is reported that surgical treatment is needed when the patients have significant clinical symptoms [2, 5]. Since lesions in the late stage of FD in the skull base can cause life-threatening problems, we think that the surgery can be done before significant clinical symptoms occur.

REFERENCES

1. Megerian CA, Sofferan RA, McKenna JM, Eavey RD, and Nadol JB. Fibrous dysplasia of the temporal bone: ten new cases demonstrating the spectrum of otologic sequelae. *American J Otol* 1995;16:408-19.
2. Papadakis CE, Skoulakis CE, Prokopakis EP, Nikolidakis AA, and Bizakis JG. Fibrous dysplasia of the temporal bone: report of a case and a review of its characteristics. *Ear Nose Throat J* 2000;79:52-57.
3. Itshayek E, Spector S, Gomori M, and Segal R. Fibrous dysplasia in combination with aneurysmal bone cyst of the occipital bone and the clivus: case report and review of the literature. *Neurosurgery* 2002;51:815-8.
4. Chandy MJ. Occipital fibrous dysplasia tonsillar herniation and cervical syringomyelia. *Br J Neurosurg* 1999;13(2):217-218.

5. Lustig LR, Holliday MJ, McCarthy FE, and Nager GT. Fibrous dysplasia involving the skull base and temporal bone. *Arch Otolaryngol Head Neck Surg* 2001;127:1239-1247.
6. Rappaport ZH. Aneurysmal bone cyst associated with fibrous dysplasia of the skull. *Neurochirurgia* 1989;32:192-194.
7. Xenellis J, Býbas A, Savy L, Maragoudakis P, and Nomicos P. Radiology in focus. Monostotic fibrous dysplasia of the temporal bone. *J Laryngol Otol* 1999;113:772-4.
8. Nager GT and Holliday MJ. Fibrous dysplasia of the temporal bone: update with case reports. *Ann Otol Rhinol Laryngol* 1984;93:630-633.
9. Pouwels ABPM and Cremers CWRJ. Fibrous dysplasia of the temporal bone. *J Laryngol Otol* 1988;102:171-2.
10. Van Tillburg W. Fibrous dysplasia. In: Vinken P, and Bruyns G, eds. *Handbook of Clinical Neurology*. Amsterdam, the Netherlands: North Holland Publishing Company; 1972:163-212.
11. Brown EW, Megerian CA, McKenna MJ, and Weber A. Fibrous dysplasia of the temporal bone: imaging findings. *AJR* 1995;164:679-82.
12. Oldfield EH, Muraszko K, Shawker TH, et al. Pathophysiology of syringomyelia associated with Chiari I malformation of the cerebellar tonsil. *J Neurosurg* 1994;80:3-15
13. Kumar C, Panagapoulos K, Kalbag RM, et al. cerebellar astrocytoma presenting as a syringomyelia syndrome. *Surg Neurol* 1987;27:187-90.
14. Smouha EE, Edelman DR, and Parisier SC. Fibrous dysplasia involving the temporal bone: report of three new cases. *The Am J Otol* 1987;8:103-7.