

The incidence of *Cyclospora cayetanensis* in stool samples submitted to a district general hospital

S. C. CLARKE* AND M. MCINTYRE

Department of Microbiology, Wexham Park Hospital, Slough, Berkshire SL2 4HL

(Accepted 26 January 1996)

SUMMARY

Cyclospora cayetanensis is the cause of a prolonged diarrhoeal syndrome. In the UK most cases are seen in travellers who have returned from countries in which the organism is endemic. The purpose of this investigation was to determine the incidence of *C. cayetanensis* in stool samples submitted to a district general hospital. A total of 6151 stools from 5374 different patients were screened for the presence of *C. cayetanensis* over a 1-year period using the modified Ziehl–Neelsen technique. Oocysts of *C. cayetanensis* were found in 7 stools (0·1%) from 4 patients (0·07%). All four patients were adult travellers who had visited countries in which *C. cayetanensis* is known to be endemic. In the population of this study, *C. cayetanensis* was found to be a rare cause of diarrhoea. Although *C. cayetanensis* infection should be considered in individuals of all ages who have lived in, or have travelled to endemic areas, there is no need to screen stool samples for the organism in those without such a travel history.

INTRODUCTION

Organisms now known as *Cyclospora cayetanensis* [1] were first described as a possible cause of gastrointestinal illness in humans in 1979 [2]. Symptoms seen in patients infected with *C. cayetanensis* include diarrhoea, nausea, vomiting, anorexia, weight loss and abdominal pain [3, 4]. Fever may also be present [4, 5]. Symptom-free carriage of *C. cayetanensis* appears to be rare [6].

Oocysts are excreted in human faeces in the undifferentiated oocyst form [7] and require environmental exposure to develop fully. They are circular, between 8 and 10 μm in diameter and often possess an internal morulla of 6–7 μm in diameter. This internal morulla has a green tinge under light microscopy and

has a number of inclusions about 2 μm in diameter [8, 9].

C. cayetanensis appears to have a worldwide distribution. Reports of infection have come from individuals who live in, or have visited, the United States [10, 11], Caribbean Islands [5], Central and South America [5, 12], South and Southeast Asia [5, 9, 13–15] and Eastern Europe [12].

Small screening studies in the UK have shown that the incidence of *C. cayetanensis* infection seen in travellers is low [14, 16]. In one study [16], no cases were found after screening 115 stool samples. In another report [14], which described preliminary results from this study, two cases were found after screening 1333 samples. Detection rates appear to be similar in the USA. In a large study by Wurtz and colleagues [17], 6525 samples were screened over 29 months and 34 positive samples from 27 cases were found. However, 20 of these cases were from a single outbreak [10, 18]. In another study, 1042 samples

* Author for correspondence: S. C. Clarke, Department of Microbiology and Immunology, University of Leicester, School of Medicine, Medical Sciences Building, PO Box 138, University Road, Leicester LE1 9HN.

were screened and 5 positive samples from 3 patients were found [11]. *C. cayetanensis* infection may be seen in individuals of all ages [19].

A large screening programme to determine the incidence of *Cyclospora cayetanensis* in stool samples submitted to a district general hospital has not yet been reported in the UK. One previous screening programme [16] has been described but was of short duration and the sample size was small. In this paper we present data and case reports from a 1-year screening programme of stool samples submitted to a district hospital in the UK. Preliminary case reports were published elsewhere [14].

METHODS

All stool samples submitted to the microbiology department of a district general hospital were examined for one year between October 1993 and September 1994 for the presence of oocysts of *Cyclospora cayetanensis*. There was no selection of samples; they were from immunocompetent and immunocompromised individuals of all ages, including those who had and had not travelled abroad. Twenty stool samples from 20 normal, healthy individuals without any recent history of gastrointestinal complaints were also screened to act as negative controls.

The screening procedure was performed using faecal smears stained by the modified Ziehl–Neelsen technique [20]. The staining procedure was initially controlled using a sample known to contain oocysts of *Cryptosporidium* spp. Once the first *C. cayetanensis* positive sample was found, positive smears were made and used to control the staining procedure. Stained smears were viewed at $\times 500$ magnification using standard light microscopy.

For any suspicious cyclospora-like acid-fast bodies, the presence of autofluorescence in a wet mount preparation was determined using a Leitz Laborlux 12 fitted with a Ploemopak 2.5 fluorescence vertical illuminator and Leitz filter block (excitation range 350–460 nm). The filter covered UV, violet and blue light including the required UV wavelength for the autofluorescence of *C. cayetanensis* (365 nm). The wet mount preparation was also used to observe the internal contents of suspect oocysts under light microscopy. The size of oocysts was also determined using an eyepiece micrometer which was calibrated using a stage micrometer. The diameter of ten oocysts

Table 1. *Confirmation of identity of Cyclospora cayetanensis*

Criterion 1	General size, shape and staining morphology as determined by staining with the modified ZN method. Oocysts are of consistent diameter staining variably from dark red to not at all.
Criterion 2	Oocyst diameter between 8 and 10 μm as measured with a microscope eyepiece graticule.
Criterion 3	Internal morphology under light microscopy showing a sphere of <i>c.</i> 7 μm in diameter and containing green-tinged refractile bodies.
Criterion 4	Blue autofluorescence of the oocyst circumference under ultraviolet light at a wavelength of 340–380 nm.

was measured and the mean calculated. The identity of oocysts of *C. cayetanensis* was therefore confirmed by four criteria (Table 1).

Upon demonstration and confirmation of oocysts of *C. cayetanensis* in a stool sample, the patients' physician was contacted. A comprehensive questionnaire was completed detailing clinical symptoms, recent travel, eating habits and animal contact. A case history was then compiled for each patient from whom oocysts of *C. cayetanensis* were demonstrated.

RESULTS

Stool samples (6151) from 5374 different patients were screened for the presence of oocysts of *C. cayetanensis*. The numbers of samples received and screened by month over the 12-month screening period are shown in Figure 1. Oocysts of *C. cayetanensis* were found in 7 stools (0.1%) from 4 patients (0.07%). The oocysts were identified according to the criteria described. No oocysts of *C. cayetanensis* were found in the 20 control samples.

Case reports of patients found to be infected with *C. cayetanensis*

Case 1, October 1993

A 29-year-old air hostess presented with a 10-day history of diarrhoea, nausea, vomiting, anorexia, weight loss and colicky abdominal pain which commenced whilst on holiday in Bali. She did not have a fever at any time. Her illness commenced 11 days after her arrival – she had been careful to avoid

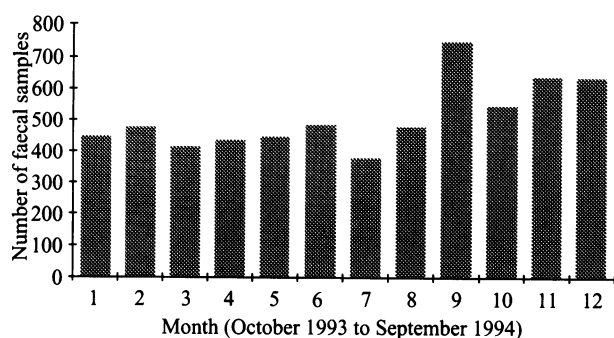


Fig. 1. Monthly distribution of faecal samples screened for *Cyclospora cayetanensis* between October 1993 and September 1994.

drinking untreated water. Oocysts of *C. cayetanensis* were found in her stools and routine bacteriological investigations were negative. No faecal leucocytes were seen. Her symptoms started to abate after 4 weeks of illness. Oocysts were still being excreted in low numbers 38 days after the onset of her illness. No antimicrobial agents were given during her illness.

Case 2, November 1993

A 29-year-old male presented with an 11-day history of diarrhoea, nausea, anorexia, weight loss, dyspepsia and a fever. No vomiting was reported. He had lived with his family in Indonesia for the past 4 months, from June to November, but had also recently travelled to France only 1 week before. Oocysts of *C. cayetanensis* and cysts of *Blastocystis hominis* were present in his stools. No faecal leucocytes were seen. Routine bacteriological investigations were negative. No antimicrobial agents were given to the patient. The patient had been careful to avoid drinking untreated water but had been in contact with a dog in Indonesia. The patient's wife and baby son experienced similar symptoms although faecal specimens were not received from them.

Case 3, June 1994

A 28-year-old male presented with a 3-week history of diarrhoea, anorexia, weight loss and fever with occasional vomiting. He had been travelling for a year throughout South America and South-East Asia. Oocysts of *C. cayetanensis* were seen in his faeces. No faecal leucocytes were present. The patient was not given any antimicrobial agents and his symptoms began to abate after 7 weeks of illness. The patient was travelling alone and it is not known whether any untreated water or improperly cooked food was

consumed. Routine bacteriological investigations were negative.

Case 4, July 1994

A 28-year-old female teacher presented with a 5-day history of diarrhoea, vomiting, anorexia and weight loss 2 days after returning from a 2-week holiday in India. No antimicrobial agents were given to the patient but complete remission of her symptoms occurred after only 6 days of illness. The patient reported drinking untreated water whilst in India. Two stool samples were received from the patient. The first, taken upon presentation, grew *Shigella flexneri* and oocysts of *C. cayetanensis* were present. The second sample, taken 1 week later, also grew *S. flexneri* but oocysts of *C. cayetanensis* and cysts of *Entamoeba coli* and *Endolimax nana* were also present. No faecal leucocytes were present in either sample. The patient remained well and no pathogens, including oocysts of *C. cayetanensis*, were isolated from stool samples taken 2 and 9 months later.

DISCUSSION

The role of *C. cayetanensis* in the aetiology of gastrointestinal complaints has been explored. The screening period covered one full year thereby including the potential for any seasonal variation in infection rates. We found that the modified ZN stain was an effective method for the screening of stool samples for the presence of oocysts of *C. cayetanensis*. The organisms were readily identified by their size and staining characteristics. The criteria used to confirm the identity of suspect oocysts were found to be reliable.

The number of stool samples received each month over the 12 month period was fairly constant except for the months of June, July, August and September. In these months there was an increase in the number of stool samples received. It is during these months that many individuals return from holidays and therefore an increase in the number of cases of diarrhoea may be expected. In this study on 6151 stool samples from 5374 different patients, four patients were found to be infected with the organism. *C. cayetanensis* was therefore not a common cause of diarrhoea in this study. The four case patients were adult travellers who had visited countries already known to confer an increased risk for the acquisition of *C. cayetanensis* [5, 12, 13, 15]. Oocysts of *C.*

cayetanensis were absent in the 26 negative control stool samples. Although only a small number of control individuals were screened in this study, this finding confirms that symptom-free carriage of the organism is rare and is in agreement with other workers [6].

The clinical symptoms of the four patients found to be infected with *C. cayetanensis* in this study were similar to those described in other patients [3, 4]. Two of the four case patients had fever during their illness. This symptom is not always present but has been described [4, 5]. Clinical illness in one of the four patients lasted 6 days and in another lasted 49 days. Symptoms lasted at least 11 days in the other two. The remarkable variability in the duration of the illness in this study agrees with previous reports [4]. Although viral investigations were not performed in these patients, another true pathogen, namely *Shigella flexneri*, was found in only one of the four. *Entamoeba coli* and *Endolimax nana* were also present in this patient and these are not usually considered pathogenic in humans. *Blastocystis hominis* was found in one other patient although its role as a gastrointestinal pathogen remains controversial. These findings agree with those of Hoge and colleagues [6].

C. cayetanensis was also found in 10 stool samples from 3 patients outside the 1-year screening period. One of the cases was found incidentally during screening for cryptosporidia whilst the other two were detected because the prolonged nature of the symptoms and the history of foreign travel suggested a possible diagnosis of *C. cayetanensis* infection.

The first case was a 2-year-old boy who presented in May 1995 with a 3-week history of diarrhoea and vomiting with slight weight loss and a poor appetite. He had visited Bangladesh for 8 weeks with his family and his illness developed during the seventh week. During routine screening for cryptosporidia by the modified ZN technique, oocysts of *C. cayetanensis* were seen in 4 out of 5 stool samples. *Salmonella javiana* and rotavirus were also present in the same samples. No faecal leucocytes were seen in any of the samples. The patient was symptomatic for 10 weeks in total.

The second case was a 46-year old Australian female who had travelled through South-East Asia and presented in June 1995 with protracted diarrhoea accompanied by upper abdominal pain. She had flown from Australia stopping at Bali for 4 days and then Java for 2 days. Her symptoms developed upon her arrival in England and 10 days later a stool sample

was submitted in which oocysts of *C. cayetanensis* were found. No other ova, cysts or parasites were present and no bacterial pathogens were isolated. No faecal leucocytes were seen. Her symptoms continued for a total of 17 days.

The third case was a 29-year-old female who presented in July 1995 after travelling to Indonesia for 3 weeks. She had a 21-day history of diarrhoea, vomiting, fever, weight loss, malaise and cervical lymphadenopathy which had commenced 1 week after her arrival in Indonesia. The patient provided two stool samples, taken 21 days and 28 days after her symptoms commenced. Oocysts of *C. cayetanensis* were present in both samples. No other ova, cysts or parasites were found and no faecal leucocytes were seen. Routine bacteriological investigations were negative.

C. cayetanensis was therefore not a common cause of diarrhoea in this study. These findings are probably applicable to the whole of the UK and indicate that indigenously-acquired *C. cayetanensis* infection is very rare in the UK. This would suggest that there is no need to screen faecal samples for the organism unless there is a history of travel to the USA, Caribbean Islands, Central and South America, South and Southeast Asia or Eastern Europe. Screening in those who have travelled to these countries should be considered in individuals of all ages and both sexes, particularly in those with unexplained, prolonged diarrhoea.

ACKNOWLEDGEMENTS

Dr D. P. Casemore, Rhyl PHL and Dr G. Nichols, Central Public Health Laboratory for their helpful advice during the study; and all the staff of the Department of Microbiology, Wexham Park Hospital for their support.

REFERENCES

1. Ortega YR, Gilman RH, Sterling CR. A new coccidian parasite (Apicomplexa: Eimeriidae) from humans. *J Parasitol* 1994; **80**: 625–9.
2. Ashford RW. Occurrence of an undescribed coccidian in man in Papua New Guinea. *Ann Trop Med Parasitol* 1979; **73**: 497–500.
3. Soave R, Dubey JP, Ramos LJ, Tummings M. A new intestinal pathogen? *Clin Res* 1986; **34**: 533A (abstract).
4. Schlim DR, Cohen MT, Eaton M, Rajah R, Long EG, Ungar BLP. An alga-like organism associated with an outbreak of prolonged diarrhoea among foreigners in Nepal. *Am J Trop Med Hyg* 1991; **45**: 383–9.

5. Gascon J, Corachan M, Valls ME, Gene A, Bombi JA. Cyanobacteria-like body (CLB) in travellers with diarrhea. *Scand J Infect Dis* 1993; **25**: 253–7.
6. Hoge CW, Schlim DR, Rajah R, *et al.* Epidemiology of diarrhoeal illness associated with coccidian-like organism among travellers and foreign residents in Nepal. *Lancet* 1993; **341**: 1175–9.
7. Wurtz R. Cyclospora: a newly identified intestinal pathogen of humans. *Clin Infect Dis* 1994; **18**: 620–3.
8. Long EG, Ebrahimzadeh A, White EH, Swisher B, Callaway CS. Alga associated with diarrhea in patients with acquired immunodeficiency syndrome and in travelers. *J Clin Microbiol* 1990; **28**: 1101–4.
9. Long EG, White EH, Carmichael WW, *et al.* Morphologic and staining characteristic of a cyanobacterium-like organism associated with diarrhea. *J Infect Dis* 1991; **164**: 199–202.
10. Wurtz R, Kocka FE, Kallick C, Peters C, Dacumos E. Blue green algae associated with a diarrheal outbreak [abstract c-21]. In: Proceedings of the Annual Meeting of the American Society for Microbiology. Washington DC: American Society for Microbiology, 1991.
11. Ooi WW, Zimmerman SK, Needham CA. Cyclospora species as a gastrointestinal pathogen in immunocompetent hosts. *J Clin Microbiol* 1995; **33**: 1267–9.
12. Lebbad M, Linder E. Nyupptäckt organism bakom diarrésjukdom. *Lakartidningen* 1993; **90**: 951–2.
13. Smith PM. Travellers diarrhoea associated with a cyanobacterium-like body. *Med J Aust* 1993; **158**: 724.
14. Clarke SC, McIntyre M. Human infection with *Cyclospora*. *J Infect* 1994; **29**: 112–3.
15. Deluol A, Junod C, Poirot J, Heyer F, N'Go Y, Cosnes J. Travellers diarrhea associated with *Cyclospora* sp. *J Eukary Microbiol* 1994; **41**: 32S.
16. McIntyre M, Lyons M. Screening of patients with diarrhoea in the UK for cyanobacterium-like bodies. *J Infect* 1992; **26**: 107–9.
17. Wurtz R, Kocka FE, Peters CS, Weldon-Linne CM, Kuritza A, Yungbluth. Clinical characteristics of seven cases of diarrhea associated with a novel acid fast organism in the stool. *Clin Infect Dis* 1993; **16**: 136–8.
18. Anonymous. Outbreaks of diarrheal illness associated with Cyanobacteria (blue-green algae)-like bodies – Chicago and Nepal, 1989 and 1990. *MWR* 1991; **40**: 325–7.
19. Ortega YR, Sterling CR, Gilam RH, Cama VA, Diaz F. Cyclospora species – a new protozoan pathogen of humans. *N Engl J Med* 1993; **328**: 1308–12.
20. Casemore DP. Laboratory methods for diagnosing cryptosporidiosis. *J Clin Pathol* 1991; **44**: 445–51.