

## Synergistic Role of Gaseous Ammonia in Etiology of *Pasteurella multocida*-Induced Atrophic Rhinitis in Swine

T. D. C. HAMILTON,\* J. M. ROE, AND A. J. F. WEBSTER

*Aerobiology Group, Division of Animal Health and Husbandry, Department of Clinical Veterinary Science, University of Bristol, Langford, Bristol BS18 7DU, England*

Received 27 December 1995/Returned for modification 17 April 1996/Accepted 12 June 1996

**One-week-old Large White piglets were weaned and allocated to 14 experimental groups, each composed of five animals. Each group was housed in a separate Rochester exposure chamber and exposed continuously to gaseous ammonia at either 0, 5, 10, 15, 25, 35, or 50 ppm (two groups per exposure level). One week after ammonia exposure commenced, the pigs from one group at each exposure level were inoculated intranasally with  $9 \times 10^7$  CFU of *Pasteurella multocida* type D. After a further 4 weeks of exposure, all the pigs were euthanized and the extent of turbinate degeneration was assessed by using a morphometric index (J. T. Done, D. H. Upcott, D. C. Frewin, and C. N. Hebert, *Vet. Rec.* 114:33–35, 1984) and a subjective scoring system (Ministry of Agriculture, Fisheries and Food, *Atrophic Rhinitis: a System of Snout Grading*, 1978). Exposure to ammonia at a concentration of 5 ppm or greater resulted in a significant increase in the severity of turbinate atrophy induced by *P. multocida* compared with that occurring in pigs kept in 0 ppm of ammonia. This effect was maximal at 10 ppm but decreased progressively at concentrations above 25 ppm. Regression analysis revealed a significant relationship between the severity of turbinate degeneration and the number of *P. multocida* organisms isolated from the nasal epithelium at the end of the experiment ( $R^2 = 0.86$ ). These findings suggest that exposure to ammonia facilitates the growth and/or survival of *P. multocida* within the upper respiratory tract of the pig, thereby contributing to the severity of the clinical disease atrophic rhinitis. Furthermore, exposure of pigs to ammonia at 10 ppm or greater, in the absence of either *P. multocida* or *Bordetella bronchiseptica*, induced a mild but statistically significant degree of turbinate atrophy. The findings of this study demonstrate that exposure to ammonia, at concentrations within the range encountered commonly in commercial piggeries, contributes to the severity of clinical lesions associated with atrophic rhinitis.**

Atrophic rhinitis is a disease of the upper respiratory tract of swine characterized clinically by atrophy and degeneration of the bony and cartilaginous structures of the upper airways, in particular the nasal turbinates and septum, and in severe cases visible shortening or twisting of the snout occurs (7). The etiology of this disease is complex, with toxigenic strains of *Bordetella bronchiseptica* and *Pasteurella multocida* types A and D implicated as primary etiological agents by experimental studies (5, 12, 18, 21). The more severe form of the disease is known as progressive atrophic rhinitis and is attributed specifically to colonization of the pig's nasal cavity by toxigenic strains of *P. multocida* (17, 21, 25). However, the failure to consistently reproduce the clinical disease in experimental studies without depriving pigs of passive immunity, withholding colostrum (16), or pretreating pigs' nasal cavities prior to challenge with a chemical irritant such as acetic acid (18) suggests that external factors are involved in the etiology of this disease.

Epidemiological surveys have indicated an association between the severity of atrophic rhinitis and elevated levels of aerial pollutants within the buildings in which the pigs were reared (2, 19). Intensive housing systems expose animals to high concentrations of aerial pollutants in the form of organic dust, noxious gases such as ammonia, and bacterial endotoxins (19). Research to date has failed to clarify the specific effects that exposure to these pollutants has on the health of inten-

sively housed stock. (9, 15, 24). The objective of this study was to determine whether exposure to ammonia, at concentrations encountered in commercial piggeries, influences the severity of the clinical disease progressive atrophic rhinitis.

### MATERIALS AND METHODS

**Animals.** Seventy minimal-disease piglets were derived from Large White sows obtained from the Institute of Animal Health, Compton Laboratory, Newbury, England. The piglets were weaned at 1 week of age and randomly assigned to 14 experimental groups of five animals. Each group was housed separately in a Rochester exposure chamber built to the design of Timbrell et al. (26). Before the experiment commenced, all of the pigs were screened for the presence of *P. multocida* and *B. bronchiseptica* by nasal lavage with 10 ml of phosphate-buffered saline as described by Chanter et al. (3). The recovered fluid was cultured overnight at 37°C on 5% horse blood agar plates with added antibiotics (22) and Bordet-Gengou media supplemented with antibiotics (20) and examined for the respective organisms.

**Exposure chambers.** Each group of pigs was housed for a total of 5 weeks in a 1.4-m<sup>3</sup> stainless-steel Rochester exposure chamber built to the design of Timbrell et al. (26). The chambers were run at  $-70$  kPa, giving an air exchange rate of 60 air changes per h. Air entered each chamber via a HEPA filter and after traversing the chamber was vented via a HEPA filter to prevent release of biological material. Within each chamber the air was maintained at a temperature of  $30 \pm 1.0^\circ\text{C}$  and at a relative humidity of  $50\% \pm 5\%$ .

Ammonia from a compressed-gas cylinder (BOC Special Gases, London, United Kingdom) was introduced into the air inlet pipe of each chamber and adjusted by using a flow tube (BOC Special Gases). The concentration of ammonia in each chamber was measured twice daily by using gas diffusion tubes (Ammonia 5/a 20501; Draeger, Lubeck, Germany) and maintained to within 10% of the target level.

**Bacterial inoculum.** *P. multocida* LFB<sub>3</sub>, a toxigenic isolate from a clinical case of atrophic rhinitis in a British pig (21) was supplied by the Institute of Animal Health, Compton Laboratory. The isolate was stored at  $-70^\circ\text{C}$  in brain heart infusion broth containing Robertson's cooked meat granules and 5% glycerol.

Immediately prior to use *P. multocida* LFB<sub>3</sub> was cultured overnight under aerobic conditions on 5% horse blood agar at 37°C. A single colony from this plate was used to inoculate 10 ml of brain heart infusion broth, which was then incubated overnight under aerobic conditions at 37°C. The number of organisms

\* Corresponding author. Mailing address: Aerobiology Group, Division of Animal Health and Husbandry, Department of Clinical Veterinary Science, University of Bristol, Langford House, Langford, Bristol BS18 7DU. Phone: (0117) 9289478. Fax: (01934) 853443. Electronic mail address: Tim.Hamilton@bris.ac.uk.

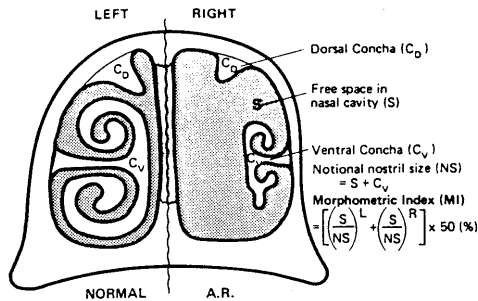


FIG. 1. Transverse section of a pig's snout showing the areas used in calculating the MI. L, left; R, right; A.R., atrophic rhinitis.

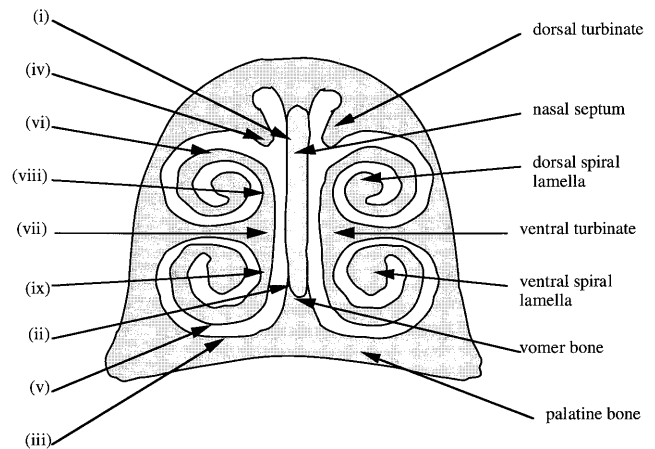


FIG. 2. Transverse section of a pig's snout showing the sites at which histological measurements were made.

in the broth was determined by a modified method of Miles and Misra (4) using 5% horse blood plates.

**Experimental protocol.** Groups of pigs were exposed to ammonia at one of seven concentrations (0, 5, 10, 15, 25, 35, and 50 ppm), with two groups per exposure level. One week after exposure to ammonia commenced, the pigs from one group at each of the seven exposure levels were given a bilateral intranasal inoculation with  $9 \times 10^7$  CFU of *P. multocida* (strain LFB<sub>3</sub>) in 1 ml of brain heart infusion broth. After a further 4 weeks of exposure to ammonia all the pigs were euthanized by an intravenous injection of sodium pentobarbitone and subjected to a postmortem examination.

**Necropsy.** Immediately after death, tissue samples (with an approximate surface area of 1 cm<sup>2</sup>) were taken aseptically from the tonsil and the nasal epithelium at the caudal extremity of the ventral conchal bone. Any macroscopic signs of disease were noted. The snout was removed by transverse cutting at the level of the second premolar (13) with a band saw and fixed by immersion in 10% neutral buffered formalin for 1 week.

**Bacteriology.** Each necropsy tissue sample was weighed and homogenized in 2 ml of phosphate-buffered saline in a 15-mm-diameter glass homogenizer (Fisons Scientific, Loughborough, United Kingdom). The homogenates were diluted by using a 10-fold dilution series and plated onto 5% horse blood agar containing neomycin, actidione, and bacitracin (22) by a modified Miles and Misra technique (4). After overnight incubation under aerobic conditions at 37°C, colonies of *P. multocida* were identified by colony morphology and counted and the number of organisms per gram of tissue was calculated. Representative colonies were further tested by gram staining and indole reactions. The identity of representative colonies was confirmed by using API 20E test strips (API-bioMerieux UK Limited). The homogenates were also screened for the presence of *B. bronchiseptica* by plating onto Bordet-Gengou medium (Unipath Ltd., Basingstoke, Hants, United Kingdom) with antibiotics as described by Rutter (20).

**Snout sections.** After fixation in 10% formalin the pig snouts were sectioned transversely at 5-mm intervals with a band saw. Visual grading of the sections was performed as described by the Ministry of Agriculture, Fisheries and Food (13). Radiographs of the sections were taken onto Min-RE film (Kodak Ltd., Hemel Hempstead, United Kingdom) in detail screen cassettes (Kodak Ltd.) using an exposure of 42 KV and 6.4 MAS. The radiographic images of the nasal cavity were analyzed with a computerized image analysis system (VIDS III; Analytical Measuring Systems, Oxford, United Kingdom). A morphometric index of atrophy was calculated on the basis of the ratio of the areas of the nasal cavity to that of the ventral turbinate (8) as illustrated in Fig. 1.

**Histopathology.** Transverse histological sections of the pigs' snouts at the level of the second premolar teeth were prepared and stained either with Harris's hematoxylin and eosin or by the periodic acid-Schiff technique. Using the computerized image analyzer (VIDS III) measurements were taken at nine points within the nasal cavity (see Fig. 2 for identification of these sites): on the nasal septum adjacent to the tip of the dorsal turbinate (i); at the junction with the vomer bone (ii); on the ventral wall of the nasal cavity overlying the palatine bone (iii); at the most ventral point of the dorsal turbinate (iv); and on the ventral turbinate at its ventral (v) and dorsal (vi) extremities, centrally on its medial aspect (vii), and medially inside the coils of the dorsal (viii) and ventral (ix) spiral lamella. Measurements of (i) the thickness of the nasal epithelium, (ii) the length of cilia, (iii) the number of cells constituting the thickness of the epithelium, (iv) the number of and relative area occupied by goblet cells per unit length of epithelium, (v) the area of the submucosa and the proportion of this occupied by glandular tissue within a unit length, and (vi) the number of osteoclasts per unit area within the ossified core at the tips of the ventral and dorsal spiral lamella of the ventral turbinate were taken. In addition, any morphological or inflammatory changes within the epithelium, submucosa, and ossified turbinate core were noted and scored subjectively.

**Statistics.** Statistical analysis was performed by using a general linear model of variance and simple regression analysis.

## RESULTS

**Clinical signs.** Throughout the experiments all animals retained a healthy appetite and exhibited normal behavior. Clinical signs of disease were restricted to sporadic sneezing by some of the pigs in the groups inoculated with *P. multocida*.

**Macroscopic findings.** The effect of ammonia and *P. multocida* infection on the severity of turbinate degeneration of the young pig is shown in Fig. 3. When *P. multocida* infection was combined with prolonged ammonia exposure, the severity of turbinate degeneration increased at all exposure levels (as assessed by the general linear model of variance [ $P < 0.001$ ]). The detrimental effect of ammonia was maximal at 10 ppm, with a mean morphometric index (MI) of 73.8% (standard deviation [SD],  $\pm 7.16\%$ ) compared with a mean MI of 57.87% (SD,  $\pm 1.03\%$ ) for *P. multocida*-infected pigs maintained at 0 ppm ammonia. At ammonia exposure levels above 10 ppm the severity of turbinate degeneration declined progressively to a mean MI of 62.41% (SD,  $\pm 1.99\%$ ) at 50 ppm of ammonia.

For pigs maintained free of *P. multocida*, exposure to ammonia at 10 ppm or greater resulted in a statistically significant increase in the level of turbinate degeneration compared with a control group maintained at 0 ppm of ammonia (as assessed by the general linear model of variance [ $P < 0.001$ ]). The

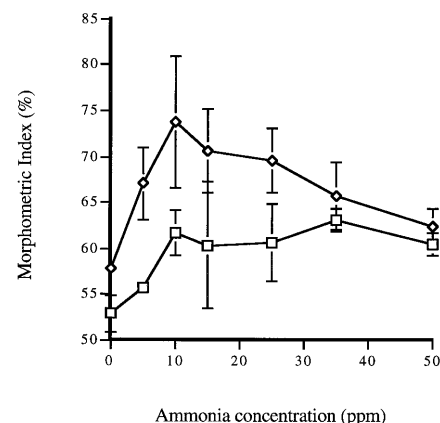


FIG. 3. Relationship between the severity of turbinate atrophy, as measured by the MI, and ammonia exposure levels. ◇, pigs infected with *P. multocida*; □, pigs kept free of *P. multocida*.

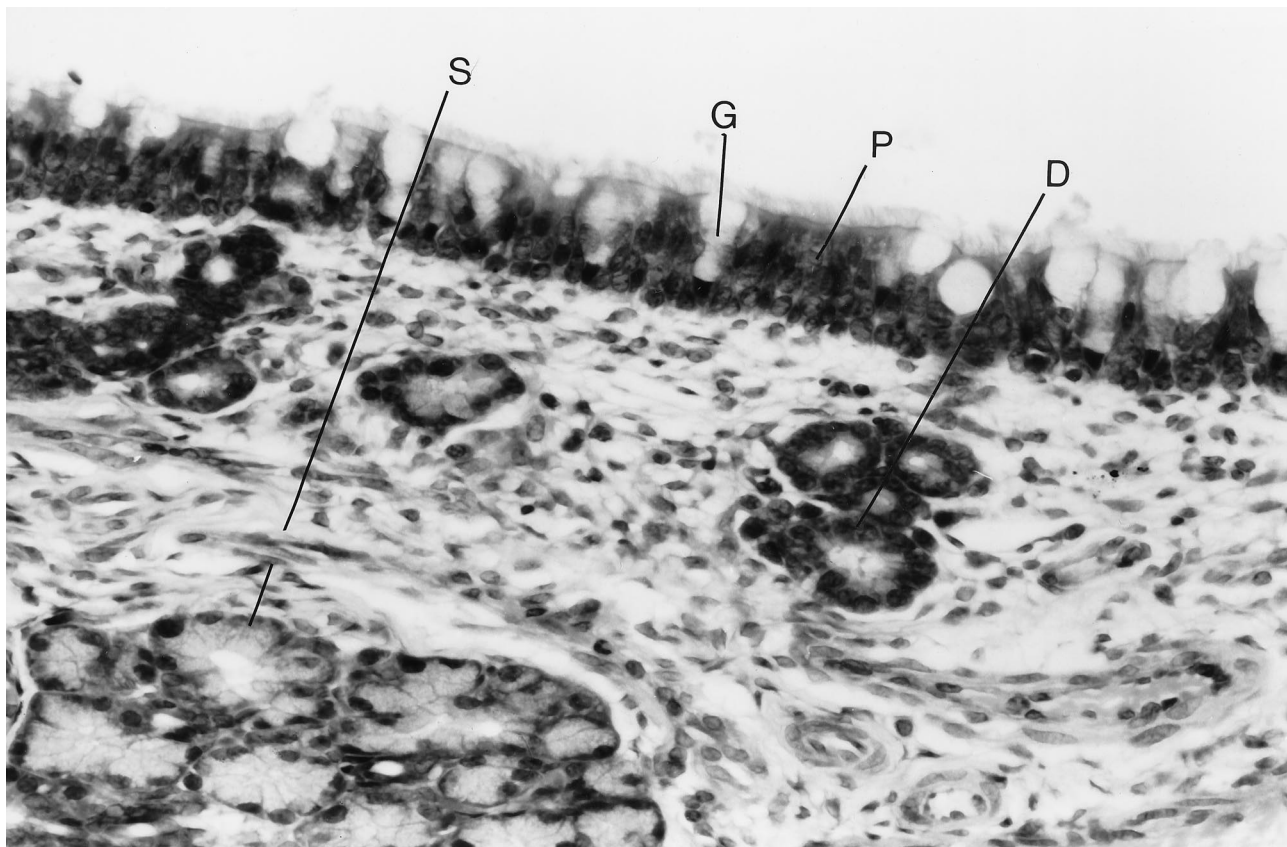


FIG. 4. Micrograph of the mucosal membrane overlying the nasal septum (Fig. 2, position i) from a pig in the control group, i.e., a group kept in clean air and not challenged with toxigenic *P. multocida*, showing pseudostratified ciliated epithelium (P) containing numerous goblet cells (G) and the lamina propria containing submucosal glands (S) and ducts (D). The membrane was stained with hematoxylin and eosin. Magnification,  $\times 312$ .

degree of severity of turbinate degeneration was consistently lower than that induced in the presence of *P. multocida*. Exposure to ammonia resulted in an increase in the mean MI from 52.92% (SD,  $\pm 1.98\%$ ) at 0 ppm to 61.69% (SD,  $\pm 2.41\%$ ) at 10 ppm, above which ammonia concentration there was no further substantial increase in MI.

**Histopathological findings.** There were a number of changes in the nasal mucosa in response to ammonia exposure in the absence of *P. multocida*. These changes included epithelial hyperplasia, goblet cell hypoplasia, and a mild inflammatory cell infiltrate (Fig. 4 and 5).

Hyperplasia of the pseudostratified ciliated epithelium lining the nasal cavity was characterized by gross thickening and an increase in the number of cells. Those characteristics were most pronounced on the ventral and dorsal extremities of the dorsal and ventral turbinates, respectively (Fig. 2, sites iv and vi). Goblet cell hypoplasia was accompanied by a decrease in the amount of mucus stored within individual goblet cells. Changes to the goblet cells were most marked in the epithelium overlying the nasal septum at a point adjacent to the ventral tip of the dorsal turbinate (Fig. 2, site i), where a statistically significant reduction in the area of the epithelium occupied by goblet cells occurred at all ammonia exposure levels from 10 to 50 ppm ( $P < 0.05$ ) (general linear model of variance; data not shown).

The inflammatory cell response was confined to a slight increase in the number of intraepithelial lymphocytes in the epithelium and a mild inflammatory cell infiltrate within the submucosa (data not shown). In addition, exposure to ammo-

nia at 10 ppm or greater evoked the formation of microcysts within the nasal epithelium. In pigs exposed to 35 and 50 ppm, these cysts tended to contain necrotic cell debris and to be grossly distended, causing the overlying epithelium to be distorted into irregular folds. The bony core of the ventral turbinates had a normal histological appearance; however, analysis revealed that the number of osteoclasts per unit area of spicular bone increased significantly at ammonia exposure levels of 10, 25, 35, and 50 ppm ( $P < 0.05$ ) (general linear model of variance) (Table 1).

When ammonia exposure was combined with *P. multocida* infection, there was a marked increase in the severity of inflammatory response compared with that induced by exposure to ammonia alone. Within the epithelium this was seen as a marked increase in the number of intraepithelial lymphocytes. The population of inflammatory cells within the submucosa was also markedly increased and tended to be concentrated around the ducts leading from submucosal glands (Fig. 6).

The principal change associated with turbinate atrophy was a loss of intramembranous bone at the core of the ventral turbinates, characterized by a loss of bony spicule and a marked influx of fibrous connective tissue.

**Bacteriological findings.** All pigs were found to be free from *P. multocida* and *B. bronchiseptica* at the commencement of the experiment. Furthermore, all tissue samples collected from the pigs at necropsy were found to be free of *B. bronchiseptica* and those samples collected from pigs not inoculated with *P. multocida* were also free of that pathogen.

The influence of prolonged ammonia exposure on the num-

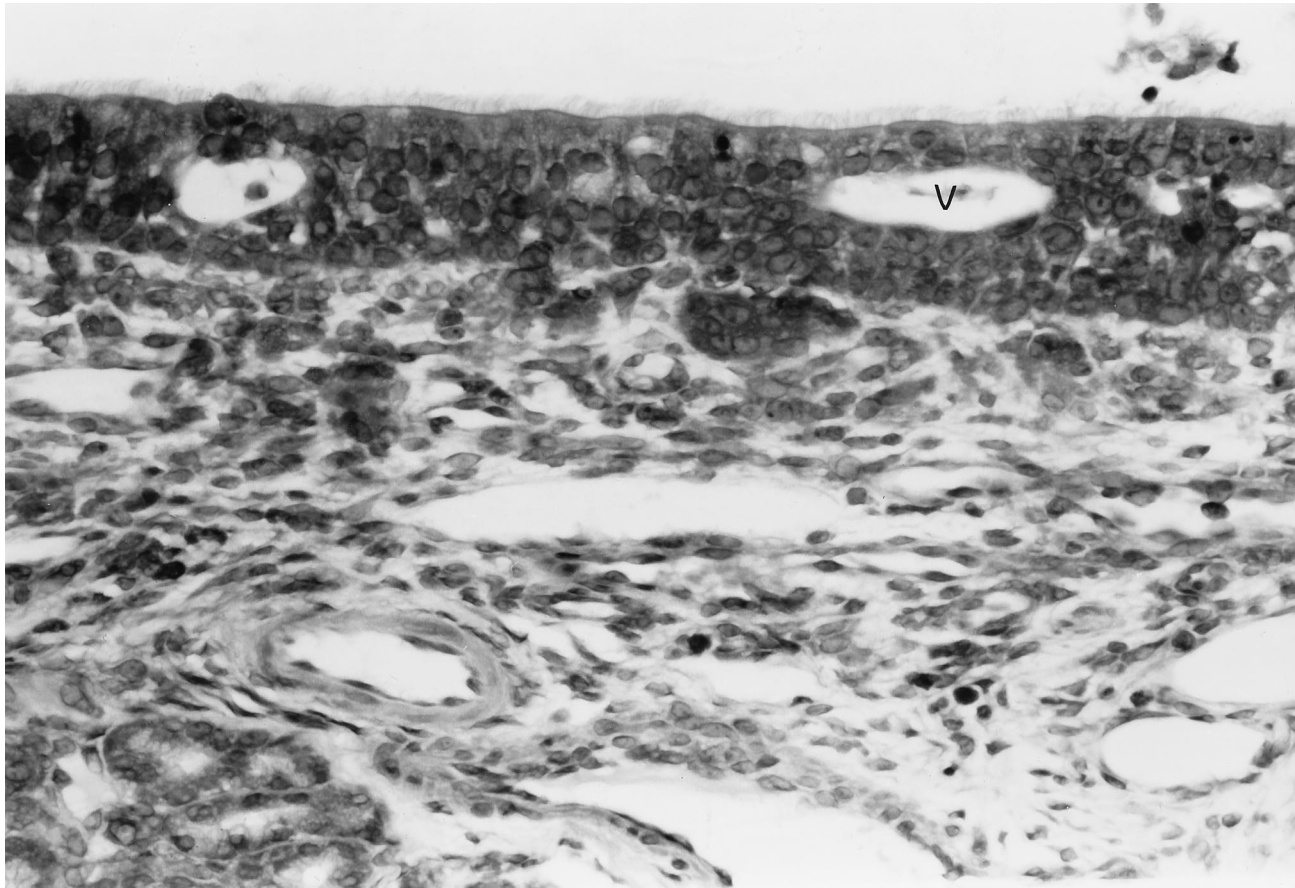


FIG. 5. Micrograph of the mucous membrane overlying the nasal septum (Fig. 2, position i) from a pig exposed to 10 ppm of aerial ammonia only, showing the epithelial hyperplasia, a loss of goblet cells, and intraepithelial vesicles (V). The membrane was stained with hematoxylin and eosin. Magnification,  $\times 312$ .

ber of *P. multocida* organisms isolated from the upper respiratory tract of the pig is shown in Fig. 7. The number of organisms isolated per gram of tissue was significantly higher for the tonsil than it was for the nasal epithelium at all exposure levels. The number of *P. multocida* organisms isolated from the tonsil increased progressively with increasing ammonia exposure levels to reach a maximum at 35 ppm and decline again by 50 ppm. In contrast, the number of *P. multocida* organisms isolated from the nasal epithelium increased at higher ammonia levels to a plateau between 10 ppm and 25 ppm and declined thereafter. Regression analysis revealed a significant relationship between the number of *P. multocida* organisms (CFU per gram) isolated from the nasal membrane

and the severity of turbinate damage ( $R^2 = 0.86$ ). In contrast, regression analysis for the tonsils failed to demonstrate significance ( $R^2 = 0.51$ ).

## DISCUSSION

Pigs reared in intensive production systems are exposed continuously to gaseous ammonia released during the microbial degradation of their excrement. Ammonia levels within commercial pig buildings are typically in the region of 10 to 25 ppm (2, 14, 19); however, in some instances levels as high as 90 ppm have been recorded (23).

Ammonia is a colorless gas with a characteristic odor. It is extremely soluble in water, in which it hydrolyzes to form ammonium ions. Ammonia is highly toxic to mammalian cells and at concentrations of 100 ppm and above evokes marked irritation of the mucous membranes of the eyes, nose, and throat (6).

The findings of this study confirm an association between prolonged exposure to ammonia (5 to 50 ppm) and the severity of turbinate degeneration induced by *P. multocida*, as predicted by epidemiological surveys (2, 19). Particularly noteworthy in this context is the observation that the exacerbating effect of ammonia on turbinate degeneration was greatest over the ammonia exposure range encountered commonly in commercial piggeries, i.e., 10 to 25 ppm.

Quantitative microbiology revealed that the tonsil harbored consistently larger numbers of *P. multocida* organisms than

TABLE 1. Numbers of osteoclasts per unit of area in the ventral aspect of the ventral turbinate in pigs exposed to ammonia only at concentrations of 0, 10, 15, 25, 35, and 50 ppm

Ammonia concn (ppm)	Mean osteoclast concn (no./mm <sup>2</sup> )	SD
0	8.14	2.69
5	6.07	4.01
10	13.19	4.61
15	9.30	3.33
25	11.73	5.24
35	13.63	8.56
50	14.67	3.81

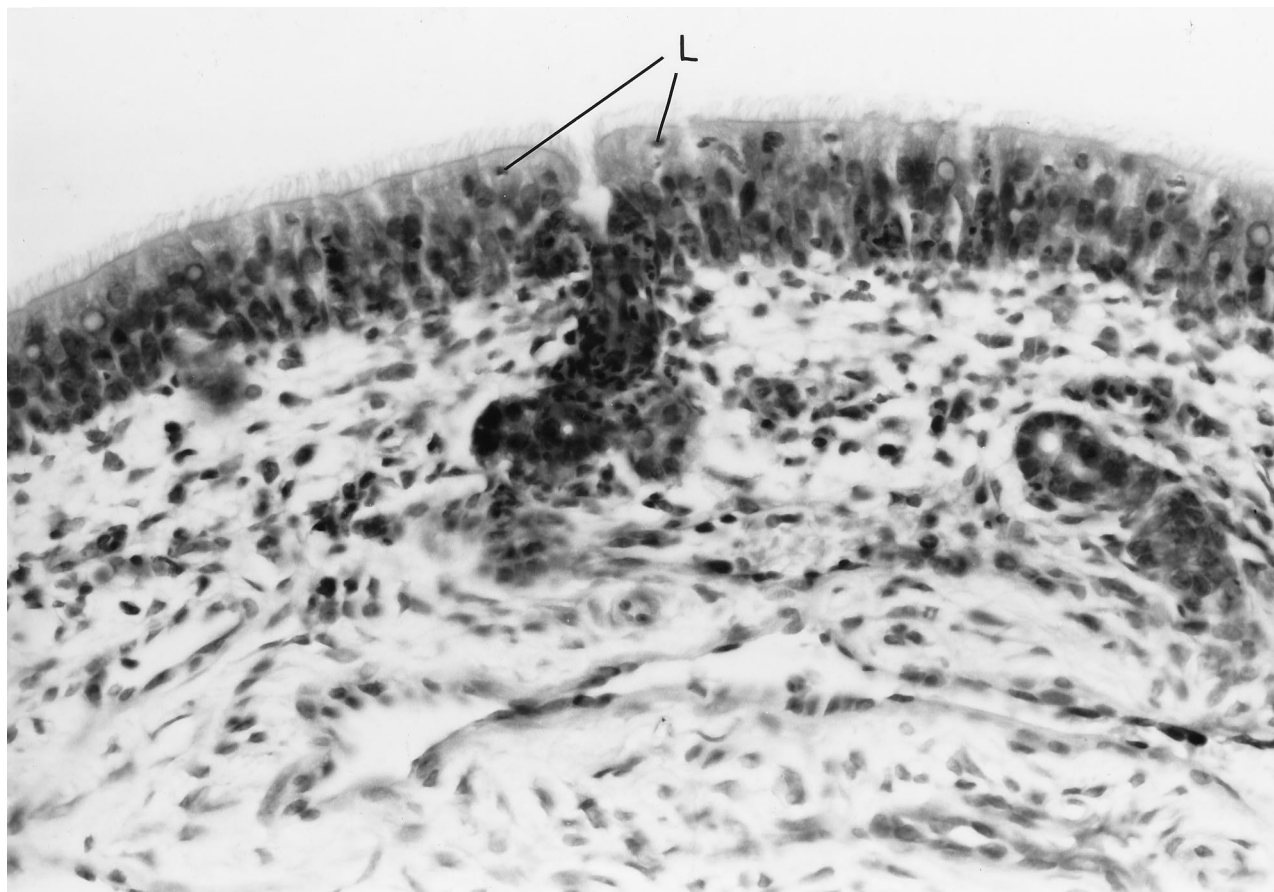


FIG. 6. Micrograph of the mucous membrane overlying the ventral turbinate (Fig. 2, position vi) from a pig exposed to 10 ppm of aerial ammonia and inoculated with toxigenic *P. multocida*, showing numerous intraepithelial lymphocytes (L) and a low-grade inflammatory response in the lamina propria concentrated around the duct of a submucosal gland. The membrane was stained with hematoxylin and eosin. Magnification,  $\times 312$ .

were present on the nasal epithelium. A predilection by *P. multocida* for the tonsil as a colonization site has been reported previously, and the potential for osteolytic toxin absorption at this site has been discussed (1). However, despite the larger numbers of *P. multocida* isolated from the tonsil, analysis revealed a closer correlation between the severity of turbinate degeneration and the number of *P. multocida* organisms iso-

lated from the nasal epithelium ( $R^2 = 0.86$  compared with 0.51 for the tonsil). This finding suggests that local absorption of osteolytic toxin across the nasal mucosa is more important in inducing turbinate atrophy than is absorption occurring at the tonsil, possibly because the latter route necessitates systemic transfer. Of potential importance in this context is the inflammatory response seen around the ducts and associated submucosal glands of pigs infected with *P. multocida*. This response could indicate proliferation of *P. multocida* within subepithelial structures, where the organism would be partially protected from the nonspecific mucociliary defenses of the epithelium.

The mechanism by which ammonia enhances colonization by *P. multocida* is unclear. It is possible that exposure to ammonia alters the conditions within the upper respiratory tract to create an environment more favorable to the growth of *P. multocida*. Potentially this could be achieved by one or more of the following mechanisms: (i) disrupting the integrity of the host's mucosal defenses, (ii) altering the competing commensal flora, and (iii) directly affecting the viability and/or growth of the pathogen. No attempt to evaluate the latter two mechanisms was made during the course of this study. However, for the first mechanism, histological examination revealed direct evidence of the pathological effects of ammonia on the mucosal lining of the upper respiratory tract. Similar pathological changes have been observed in the epithelial lining of the tracheas of pigs exposed to ammonia at 50 ppm, and these changes correlated with a reduction in the rate of bacterial

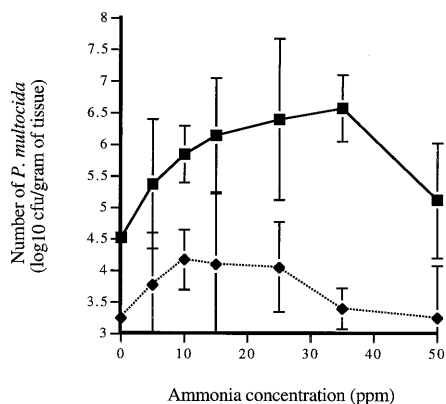


FIG. 7. Effect of ammonia concentration on the numbers of *P. multocida* organisms isolated from the tonsil (■) and nasal mucosa (◆) at necropsy.

clearance (10, 11). It is therefore likely that the damage caused to the mucosal defenses of the nasal cavity by ammonia facilitates colonization by *P. multocida*.

In the present study the severity of pathological changes to the nasal mucosa increased progressively across the ammonia exposure range investigated. In contrast, the effects of ammonia on both the severity of turbinate atrophy and the number of *P. multocida* organisms isolated from the upper respiratory tract followed a curvilinear profile, initially rising and then falling back. It therefore follows that while the damaging effect of ammonia exposure on the integrity of the upper respiratory tract mucosa may contribute to enhanced colonization by *P. multocida*, this mechanism alone is unlikely to be the sole explanation for the exacerbating effect of ammonia. A possible explanation for the decline in population density of *P. multocida* seen at higher ammonia exposure levels includes the bactericidal effect of ammonia at high concentrations (27) and the increasing inflammatory response observed both here and in the study of Doig and Willoughby (6). Further studies are needed to clarify the mechanisms by which ammonia influences the colonization of the pigs' upper respiratory tract by *P. multocida*.

In addition to the effect of ammonia on atrophic rhinitis induced by *P. multocida*, exposure to ammonia at 10 ppm or greater in the absence of either *P. multocida* or *B. bronchiseptica* resulted in a slight but statistically significant level of turbinate degeneration. The explanation for this finding is unclear; however, the observed increase in the number of osteoclasts per unit of area within the intramembranous bone of the nasal turbinates suggests that the underlying mechanism is one of increased bone absorption.

In conclusion, the findings of this study demonstrate that exposure to ammonia, at concentrations within the range encountered commonly under commercial conditions, markedly increased the severity of lesions associated with the clinical disease atrophic rhinitis. It follows that the severity of atrophic rhinitis in commercial pig herds could be markedly reduced by improving air hygiene.

#### ACKNOWLEDGMENTS

This investigation was supported by a grant from the Biotechnology and Biological Sciences and Research Council (formally the Agricultural and Food Research Council).

We thank C. Hayes and A. Norris for their technical assistance.

#### REFERENCES

- Ackerman, M. R., N. F. Cheville, and J. E. Gallagher. 1991. Colonisation of the pharyngeal tonsil and respiratory tract of the gnotobiotic pig by a toxigenic strain of *Pasteurella multocida* type D. *Vet. Pathol.* **28**:267-274.
- Baekbo, P. 1990. Air quality in Danish pig herds, p. 395. *In* Proceedings of the 11th Congress of the International Pig Veterinary Society.
- Chanter, N., T. Magyar, and J. M. Rutter. 1989. Interactions between *Bordetella bronchiseptica* and toxigenic *Pasteurella multocida* in atrophic rhinitis of pigs. *Res. Vet. Sci.* **47**:48-53.
- Corry, J. E. L. (ed.). 1979. Quality assurance and quality control of microbiological culture media, p. 21-37. International Union of Microbiological Societies International Committee of Food Microbiology and Hygiene.
- De Jong, M. F., J. L. Oie, and G. J. Testenburg. 1980. Atrophic rhinitis pathogenicity tests for *P. multocida* isolates, p. 211. *In* Proceedings of the 6th Congress of the International Pig Veterinary Society.
- Doig, P. A., and R. A. Willoughby. 1971. Response of swine to atmospheric ammonia and organic dust. *J. Am. Vet. Med. Assoc.* **159**:1353-1361.
- Done, J. T. 1983. Atrophic rhinitis: pathomorphological diagnoses, p. 3-12. *In* K. B. Pedersen and N. C. Nielsen (ed.), *Atrophic rhinitis in pigs*. Commission of European Communities, Luxembourg.
- Done, J. T., D. H. Upcott, D. C. Frewin, and C. N. Hebert. 1984. Atrophic rhinitis: snout morphometry for quantitative assessment of conchal atrophy. *Vet. Rec.* **114**:33-35.
- Done, S. H. 1991. Environmental factors affecting the severity of pneumonia in pigs. *Veterinary Rec.* **128**:582-586.
- Drummond, J. G., S. E. Curtis, R. C. Meyer, J. Simon, and H. W. Norton. 1981. Effects of atmospheric ammonia on young pigs experimentally infected with *Bordetella bronchiseptica*. *Am. J. Vet. Res.* **42**:963-968.
- Drummond, J. G., S. E. Curtis, and J. Simon. 1978. Effects of atmospheric ammonia on pulmonary clearance in the young pig. *Am. J. Vet. Res.* **39**:211-212.
- Il'ina, Z. M., and M. I. Zasukhin. 1975. Role of Pasteurella toxins in the pathogenesis of infectious atrophic rhinitis. *Sb. Nauchn. Rab. Sib. Nauchno. Issled. Vet. Inst. Onsk* **25**:76-81.
- Ministry of Agriculture, Fisheries and Food. 1978. Atrophic rhinitis: a system of snout grading. MAFF booklet LPD 51. Pinner, London.
- Nicks, B., D. Marlier, and B. Carart. 1993. Air pollution levels in pig houses, p. 635-642. *In* Proceedings of the American Society of Agricultural Engineers, livestock environment IV.
- Owen, J. E. 1982. The influence of buildings on respiratory disease. *Pig Vet. Soc. Proc.* **9**:24-35.
- Pearce, H. G., and C. K. Roe. 1966. Infectious atrophic rhinitis: a review. *Can. Vet. J.* **7**:243-256.
- Pedersen, K. B., and K. Barford. 1981. The aetiological significance of *Bordetella bronchiseptica* and *Pasteurella multocida* in atrophic rhinitis of swine. *Nord. Veterinaarmed.* **33**:513-522.
- Pedersen, K. B., and F. Elling. 1984. The pathogenesis of atrophic rhinitis in pigs induced by toxigenic *Pasteurella multocida*. *J. Comp. Pathol.* **94**:203-214.
- Robertson, J. F., D. Wilson, and W. J. Smith. 1990. Atrophic rhinitis and the aerial environment. *Anim. Prod.* **50**:173-182.
- Rutter, J. M. 1981. Quantitative observations on *Bordetella bronchiseptica* infection in atrophic rhinitis of pigs. *Vet. Rec.* **108**:451-454.
- Rutter, J. M., and X. Rojas. 1982. Atrophic rhinitis in gnotobiotic piglets: differences in pathogenicity of *Pasteurella multocida* in combined infections with *Bordetella bronchiseptica*. *Vet. Rec.* **110**:531-535.
- Rutter, J. M., R. J. Taylor, W. G. Crighton, I. B. Robertson, and J. A. Benson. 1984. Epidemiological study of *Pasteurella multocida* and *Bordetella bronchiseptica* in atrophic rhinitis. *Vet. Rec.* **115**:615-619.
- Skarp, S. U. 1972. Managing livestock wastes. American Society of Agricultural Engineers, St. Joseph, Mo.
- Strang, M. M. 1982. The influence of feed and feed delivery systems on respiratory disease. *Pig Vet. Soc. Proc.* **9**:36-46.
- Switzer, W. P., and D. O. Farrington. 1975. Infectious atrophic rhinitis, 687-711. *In* H. W. Dunne and A. D. Leman (ed.), *Diseases of swine*, 4th ed. Iowa State University Press, Ames.
- Timbrell, V., J. W. Skidmore, A. W. Hyett, and J. C. Wagner. 1970. Exposure chambers for inhalation exposure experiments with standard reference samples of asbestos of the International Union Against Cancer (IUGC). *Aerosol Sci.* **1**:215-223.
- van Demark, P. J., and B. L. Batzing. 1987. The microbes, an introduction to their nature and importance. Benjamin/Cummings Publishing Company, Inc., Wokingham, United Kingdom.