

## Isolation of a Novel *Helicobacter* Species, *Helicobacter cholecystus* sp. nov., from the Gallbladders of Syrian Hamsters with Cholangiofibrosis and Centrilobular Pancreatitis

CRAIG L. FRANKLIN,\* CATHERINE S. BECKWITH, ROBERT S. LIVINGSTON, LELA K. RILEY, SUSAN V. GIBSON, CYNTHIA L. BESCH-WILLIFORD, AND REUEL R. HOOK, JR.

Department of Veterinary Pathobiology, University of Missouri, Columbia, Missouri 65211

Received 2 February 1996/Returned for modification 9 April 1996/Accepted 25 August 1996

**A filamentous, gram-negative, motile bacterium with a single polar sheathed flagellum was isolated from gallbladders of hamsters with cholangiofibrosis and centrilobular pancreatitis. Bacteria grew under microaerophilic conditions at 37 and 42°C, were oxidase, catalase, arginine aminopeptidase, and L-arginine arylamidase positive, reduced nitrate to nitrite, were resistant to cephalothin, and exhibited intermediate susceptibility to nalidixic acid. Sequence analysis of the 16S rRNA gene indicated that the bacterium was a novel member of the *Helicobacter* genus, most closely related to *Helicobacter pametensis*. We propose to name this bacterium *Helicobacter cholecystus*. In epidemiologic studies, isolation of *H. cholecystus* correlated strongly with the presence of cholangiofibrosis and centrilobular pancreatitis; however, further studies are needed to define the role of this bacterium in pathogenesis.**

In recent years, the genus *Helicobacter* has expanded rapidly to include 12 named species (3, 7). The type species of the genus is *Helicobacter pylori*, a bacterium that colonizes the stomach of humans and has been associated with gastritis and peptic ulcer disease (14, 15). Several *Helicobacter* species and the genetically related bacterium "*Flexispira rappini*" have been isolated from rodents (6, 7, 13, 16, 20). Like *H. pylori*, these bacteria inhabit parts of the intestinal tract; however, none have been consistently associated with severe intestinal disease. In addition to colonizing the intestine, two recently identified murine helicobacters, *H. hepaticus* and *H. bilis*, have been shown to infect the liver, and their presence has been associated with hepatitis and hepatic neoplasia (6, 28, 29). The human pathogen *H. cinaedi* has been isolated from the intestinal tracts of hamsters, but no disease or histologic lesions have been associated with this infection (9). To date, no helicobacters have been isolated from extraintestinal sites of hamsters.

In 1965, Chesterman and Pomerance described a cirrhotic liver syndrome in a closed colony of Syrian hamsters (2). Since that time a similar syndrome, referred to by a variety of names, including cholangiofibrosis (10), cholangiohepatitis (8) and chronic hepatitis and cirrhosis (1), has been reported sporadically. Although affected hamsters exhibit no clinical signs, there is extensive damage to the biliary system, and affected hamsters may have elevated levels of serum alanine aminotransferase, alkaline phosphatase, bile acids, and cholesterol (1). In one report, hamsters with cholangiofibrosis had concurrent centrilobular pancreatitis and it was suggested that these lesions may have a common etiology (8). The etiology of cholangiofibrosis and centrilobular pancreatitis in hamsters is unknown; proposed etiologies range from contamination of food with aflatoxin to an immune-mediated cause (10). In this report, we describe the isolation of a novel helicobacter from the gallbladders of hamsters with cholangiofibrosis and centri-

lobular pancreatitis. We propose to name this novel bacterium *Helicobacter cholecystus*.

### MATERIALS AND METHODS

**Animals and culture procedures.** Four male and four female hamsters of each of four age groups (3, 4, 5, and 8 weeks old) were obtained from a colony known by prior examinations to be affected with cholangiofibrosis. Hamsters were euthanized and the abdominal cavity was aseptically exposed. The left dorsocaudal liver lobe was stabbed with a culture loop, which was then used to inoculate multiple plates of Trypticase soy agar that contained 5% sheep blood (blood agar). The gallbladder was located and incised, and the mucosal surface was gently scraped with a culture loop, which was then used to inoculate blood agar plates.

**Bacterial isolation and biochemical characterization.** Gallbladder and liver cultures were incubated at 37°C under aerobic and anaerobic conditions for up to 72 h. Bacteria isolated under anaerobic conditions were cultured in 90% N<sub>2</sub>, 5% CO<sub>2</sub>, and 5% H<sub>2</sub>, an environment previously shown to be ideal for growth of other rodent helicobacters (6, 7).

To further characterize isolates, phenotypic tests commonly used to characterize helicobacters were performed. Growth was examined at 25, 37, and 42°C. Tolerance to bile salts was determined by culturing bacteria in brucella broth (Difco Laboratories, Detroit, Mich.) supplemented with 5% bile salts and 5% fetal bovine serum (Sigma Chemical Company, St. Louis, Mo.). Tolerances to 1% (wt/vol) glycine and 1.5% NaCl were determined as previously described (7). Bacteria were Gram stained, tested for urease activity by a selective rapid urea test (Remel, Lenexa, Kans.), and examined for oxidase and catalase activities by

TABLE 1. Oligodeoxyribonucleotide primers used to amplify the 16S rRNA gene sequence of *H. cholecystus*

Primer	Sequence (5' to 3') <sup>a</sup>	Position <sup>b</sup>
C70f	AGAGTTTGTATYMTGGC	8-23
H276f	TATGACGGGTATCCGGC	277-293
593f	TAAGTCAGATGTGAAATCC	593-611
p93E	CCGACAAGCGGTGGAGCA	930-950
B37r	TACGGYTACCTTGTTACGA	1513-1495
H676r	ATTCCACCTACCTCTCCA	676-658
H573r	GCCATAGGATTTACATCT	573-554
419r	AATCCTAAAACCTTCATCCTC	419-406
293r	GCCGGATACCCGTCATA	293-277

\* Corresponding author. Mailing address: Department of Veterinary Pathobiology, College of Veterinary Medicine, University of Missouri, Columbia, MO 65211. Phone: (314) 882-6623. Fax: (314) 882-2950. Electronic mail address: vmcraig@vetmed.missouri.edu.

<sup>a</sup> Standard International Union of Biochemistry codes for bases and ambiguity.  
<sup>b</sup> The positions within the *Escherichia coli* 16S rRNA gene sequence that correspond to the 5' and 3' ends of each primer are shown. Approximate positions are given for *Helicobacter*-specific primers.

TABLE 2. Incidence of *H. cholecystus* gallbladder colonization, cholangiofibrosis, and centrilobular pancreatitis in Syrian hamsters

Age (wk) <sup>a</sup>	Sex <sup>b</sup>	No. of hamsters with:		
		<i>H. cholecystus</i> colonization	Cholangiofibrosis	Centrilobular pancreatitis
3	F	2	2	2
	M	2	1	2
4	F	3	3	3
	M	1	1	1
5	F	4	4	4
	M	3	2	3
8	F	4	4	4
	M	3	3	4

<sup>a</sup> Four hamsters per group.<sup>b</sup> M, male; F, female.

standard microbiological methods (4). Motility was observed by phase-contrast microscopy. The following biochemical analyses were performed with the An-Ident system (bioMerieux Vitek, Inc., Hazelwood, Mo.): alkaline phosphatase, histidine aminopeptidase, arginine aminopeptidase, and leucine aminopeptidase activities and hydrolysis of indoxyl-acetate. Gamma-glutamyltransferase, L-arginine arylamidase, and alkaline phosphatase activities, hydrolysis of hippurate, reduction of nitrate, and production of hydrogen sulfide were analyzed with the Campy identification system (bioMerieux Vitek). Susceptibilities to cephalothin and nalidixic acid were determined by culturing isolates in the presence of antibiotic-impregnated discs (Becton Dickinson and Co., Cockeysville, Md.).

**Electron microscopy.** Bacteria were collected from blood agar plates, placed in

phosphate-buffered saline, pH 7.4 (PBS), and centrifuged at 12,000 × g. Pellets were washed gently three times in deionized water. A small droplet of sample in a 4% solution of phosphotungstate was deposited on a carbon-coated grid and examined with a Hitachi H-6700 transmission electron microscope.

**DNA isolation.** Bacteria isolated from the gallbladder were propagated in brucella broth supplemented with fetal bovine serum and pelleted by centrifugation at 10,000 × g. The bacterial pellet was washed with PBS and bacterial DNA was extracted with a QiAmp Tissue Kit (Qiagen Inc., Chatsworth, Calif.) by following the manufacturer's instructions.

**Oligonucleotide primers.** Oligonucleotide primers (Table 1) were synthesized at the DNA Core Facility, University of Missouri, Columbia. Sequences of the following primers were adapted from previous studies: p93E from the work of Relman et al. (17), C70f and B37r from the work of Fox et al. (7), and H276f, 593f, 419r, and H676r from the work of Riley et al. (18).

**PCR amplification.** To determine if our gallbladder isolate was a member of the *Helicobacter* genus, bacterial DNA was amplified by PCR with the *Helicobacter* genus-specific primers H276f and H676r as previously described (18).

**DNA sequencing.** Sequencing templates were prepared by PCR as described above by using the following primer sets: (i) C70f and B37r, (ii) C70f and H676r, and (iii) H276f and B37r. Templates were purified on 3.5% polyacrylamide gels, and the gene sequence was determined by using the *Taq* dideoxy chain termination method and a commercially available kit (*Taq* Dye Terminator Cycle sequencing kit; Applied Biosystems, Inc., Foster City, Calif.). Sequencing reactions were performed with each of the primers listed in Table 1.

**Sequence analysis.** All sequence analyses were performed with the sequence analysis software package (Genetics Computer Group, Inc., Madison, Wis.). The sequence of the gallbladder isolate was aligned with sequences of 24 bacteria previously used in phylogenetic analyses of helicobacters (3, 6, 7). A matrix of pairwise evolutionary distances between aligned sequences (similarity matrix) was constructed; both uncorrected distances and corrected distances obtained by the Jukes-Cantor method (11) were calculated. A phylogenetic tree was created by the neighbor-joining method (19, 24, 25). Sequence data for comparisons were obtained from GenBank.

**Histologic examination.** Sections of all lobes of the liver and the splenic and gastric lobes of the pancreas were preserved in neutral buffered 10% formalin and processed for paraffin embedment. Tissue sections were stained with hema-

TABLE 3. Biochemical and morphologic characteristics of *H. cholecystus* in comparison to closely related helicobacters<sup>a</sup>

Characteristic	<i>H. cholecystus</i> (no. of strains) <sup>b</sup>	<i>H. pametensis</i>	<i>H. cinaedi</i>	<i>H. hepaticus</i>	<i>H. bilis</i>	<i>H. muridarum</i>	" <i>Flexispira rappini</i> " <sup>c</sup>
<b>Enzyme activities</b>							
Catalase	+ (2)	+	+	+	+	+	+
Urease	- (2)	-	-	+	+	+	+
Oxidase	+ (2)	+	ND	+	+	+	+
Alkaline phosphatase	+ (2)	+	-	ND	ND	+	-
Gamma-glutamyl-transferase	- (2)	-	-	ND	ND	+	+
H <sub>2</sub> S production	- (2)	-	-	+	+	+	ND
Indoxyl-acetate hydrolysis	- (2)	-	-	+	-	+	ND
Hippurate hydrolysis	- (2)	-	-	-	ND	-	ND
Nitrate reduction	+ (2)	+	+	+	+	-	-
<b>Flagellar morphology<sup>c</sup></b>							
Periplasmic fibers	- (1) <sup>d</sup>	-	-	-	+	+	+
No. of flagella	1 (1) <sup>d</sup>	2	1-2	2	3-14	10-14	10-20
Location	Polar (1) <sup>d</sup>	Bipolar	Polar, bipolar	Bipolar	Bipolar	Bipolar	Bipolar
<b>Growth conditions</b>							
1% Glycine	+ (2)	+	+	+	+	-	-
1.5% NaCl	- (2)	-	- <sup>e</sup>	+	-	-	ND
25°C	- (2)	ND	-	-	-	-	ND
37°C	+ (2)	+	+	+	+	+	+
42°C	+ (2)	+	-	-	+	-	+
Anaerobic	+ (2)	Weak	-	+	ND	+	-
Aerobic	- (2)	-	-	-	ND	-	-
<b>Antibiotic susceptibilities</b>							
Cephalothin	R (1) <sup>d</sup>	S	I	R	R	R	R
Nalidixic acid	I (1) <sup>d</sup>	S	S	R	R	R	R

<sup>a</sup> Data for helicobacters other than *H. cholecystus* were obtained from references 3, 6, 7, 13, 20, and 27. R, resistant; S, susceptible; I, intermediate susceptibility; ND, not determined.

<sup>b</sup> Two strains were tested.

<sup>c</sup> Morphology of the filamentous form of *H. cholecystus* was used for comparison.

<sup>d</sup> One strain was tested.

<sup>e</sup> Growth in 2% NaCl.

toxylin and eosin and examined histologically for cholangiofibrosis and centrilobular pancreatitis.

**Statistical analysis.** The incidence of *H. cholecystus* colonization was compared between sexes and among age groups by using a row-by-column chi-square test for contingency (22). Chi-square analysis was also used to compare the isolation of bacteria with the presence of histologic disease.

**Nucleotide sequence accession number.** The 16S rRNA gene sequence of *H. cholecystus* Hkb-1<sup>T</sup> is available from GenBank under accession number U46129.

## RESULTS

**Bacterial isolation and growth characteristics.** To investigate the microflora associated with cholangiofibrosis, the livers and gallbladders of 3-, 4-, 5-, and 8-week-old hamsters were cultured under aerobic and anaerobic conditions. No aerobic or anaerobic bacterial growth was evident in liver cultures from any of the age groups examined. After 72 h of anaerobic incubation, transparent pinpoint bacterial colonies were evident on gallbladder cultures from 22 of 32 hamsters (Table 2). No growth was evident in any of the aerobic gallbladder cultures.

A representative gallbladder isolate, Hkb-1<sup>T</sup>, from a 3-week-old animal was selected for further characterization. Compared with growth under anaerobic conditions, growth was improved in 90% N<sub>2</sub>-5% H<sub>2</sub>-5% CO<sub>2</sub> at 37°C, a microaerophilic environment shown to be ideal for several rodent helicobacters. Bacteria grew on blood agar plates as well as in brucella broth supplemented with 5% fetal bovine serum. Bacterial cells varied in morphology from short gram-negative rods to coccobacilli. Results of biochemical and growth analyses commonly used to characterize helicobacters are summarized in Table 3. In addition, Hkb-1<sup>T</sup> grew in the presence of 5% bile salts, had arginine aminopeptidase and L-arginine arylamidase activities, and lacked histidine aminopeptidase, leucine aminopeptidase, and gamma glutamyltransferase activities. Growth characteristics and biochemical analyses suggested that Hkb-1<sup>T</sup> was a member of the *Helicobacter* genus.

**Ultrastructure.** Approximately 5% of bacteria were fusiform rods with a single polar sheathed flagellum and no periplasmic fibers. These rods averaged 3.65 μm in length and 0.56 μm in width (Fig. 1A). The majority of bacteria were coccoid to short curved rods with one to several flagella (Fig. 1B). Coccoid forms were approximately 1 μm in diameter. Flagella of coccoid forms varied in length and often contained terminal bulb-like structures. The morphology, including flagellar number and location, of the filamentous form of Hkb-1<sup>T</sup> was used for comparison to other helicobacters.

**Genetic analysis.** Amplification of DNA from Hkb-1<sup>T</sup> by PCR using *Helicobacter* genus-specific primers yielded the expected 374-bp product, which provided additional evidence that this bacterium was a member of the *Helicobacter* genus. To investigate this further, a 1,425-bp region of the 16S rRNA gene was sequenced. A 1,420-bp fragment of the *H. cholecystus* sequence was aligned with sequences (up to 1,446-bp fragments) from bacteria of the genera *Helicobacter*, *Campylobacter*, "*Flexispira*," "*Gastrospirillum*," *Arcobacter*, and *Wolinella*. A similarity matrix table was generated (Table 4), and a phylogenetic tree was constructed (Fig. 2). Hkb-1<sup>T</sup> was most closely related to *H. pametensis* (97.89% similarity) and clustered with *H. pametensis*, *Helicobacter* species Bird B, *Helicobacter* species Bird C, and *H. mustellae*. Hkb-1<sup>T</sup> was closely related to all murine helicobacters, having 95.35 to 96.89% similarity with *H. muridarum* and *H. bilis*, respectively. Collectively, results indicated that Hkb-1<sup>T</sup> was a novel member of the *Helicobacter* genus and it was tentatively named *H. cholecystus*.

To validate the sequence data from Hkb-1<sup>T</sup> and to confirm that *H. cholecystus* was present in animals from all four age

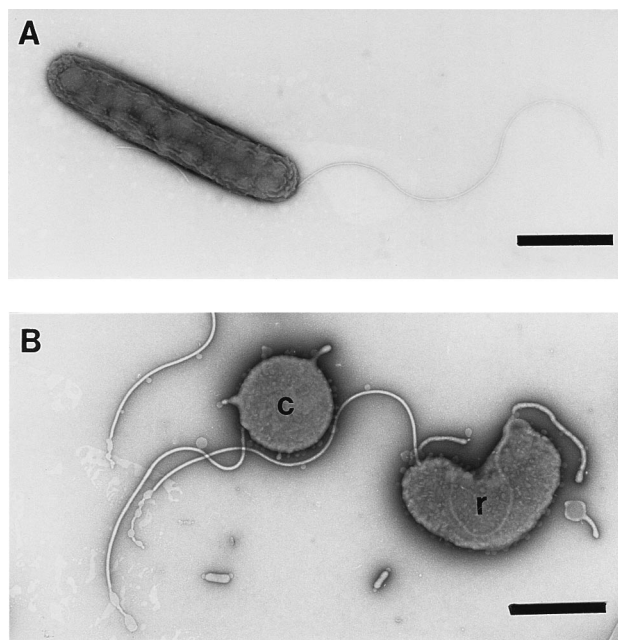


FIG. 1. (A) Negatively stained preparation of fusiform *H. cholecystus* Hkb-1<sup>T</sup> demonstrating a single sheathed polar flagellum; (B) negatively stained preparation of coccoid (c) and short curved rod forms (r) of *H. cholecystus*. Bars, 1 μm.

groups, *Helicobacter*-specific DNA from the livers of two affected hamsters from each age group was amplified. A 1,420-bp sequence was obtained from each of the eight additional isolates. Comparison of sequences with that of Hkb-1<sup>T</sup> revealed 100% similarity among all isolates, indicating that *H. cholecystus* was present in livers of affected hamsters from all age groups.

**Histologic examination.** Lesions typical of cholangiofibrosis were seen in 20 of 32 hamsters (Table 2). Mild lesions were characterized by portal neutrophilic to lymphoplasmacytic infiltrates with occasional bile duct hyperplasia (Fig. 3A). Moderate lesions were characterized by large portal lymphoplasmacytic aggregates which often formed lymphoid follicles. In these animals, lymphocytes and occasional neutrophils were often seen between hyperplastic bile duct epithelial cells. Moderately affected livers also contained extensive bile duct hyperplasia and mild pericholangial fibrosis. Severe lesions were characterized by extensive bile duct hyperplasia and fibrosis that often bridged adjacent portal triads. Lymphoplasmacytic infiltrates usually accompanied these bridging lesions.

Centrilobular pancreatitis was seen in 23 of 32 hamsters (Table 2). Mild lesions consisted of mild periductular neutrophilic and lymphocytic infiltrates. Moderate lesions consisted of more extensive periductular inflammation with migration of inflammatory cells into the pancreatic ductal epithelium (Fig. 3B). In severe lesions, inflammation extended into the surrounding pancreatic parenchyma, resulting in interstitial pancreatitis.

**Statistical analysis.** Females had a slightly higher incidence of *H. cholecystus* colonization, but this difference was not statistically significant. Pooled data from the 3- and 4-week-old groups was compared with those from the 5- and 8-week-old groups. Results indicated that hamsters 5 weeks old and older had a significantly ( $P = 0.054$ ) higher incidence of *H. cholecystus* colonization. The isolation of *H. cholecystus* was then compared with the presence of lesions. Twenty of twenty-two

TABLE 4. Matrix of pairwise evolutionary similarity between aligned sequences of the 16S rRNA gene<sup>a</sup>  
% Sequence similarity

Species	<i>H. cholecystus</i>	<i>H. pametensis</i>	<i>Helicobacter</i> sp. Bird B	<i>Helicobacter</i> sp. Bird C	<i>H. bilis</i>	<i>H. hepaticus</i>	<i>H. pullorum</i>	" <i>F. rappini</i> "	<i>H. muridarum</i>	<i>H. cinaedi</i>	<i>H. canis</i>	<i>H. mustelae</i>	<i>W. succinogenes</i>	<i>H. pylori</i>	<i>H. fennelliae</i>	<i>H. nemestrinae</i>	<i>H. acinonyx</i>	<i>H. felis</i>	" <i>G. hominis 1</i> "	<i>C. concisus</i>	<i>C. coli</i>	<i>A. butzleri</i>	<i>A. cryaerophilus</i>	<i>C. rectus</i>	<i>A. skirrowii</i>	
<i>Helicobacter cholecystus</i>	2.14	97.89	96.90	96.90	96.89	96.76	95.91	95.56	95.35	94.72	94.50	94.44	93.37	93.03	92.61	92.37	91.69	91.31	91.04	86.13	85.63	85.48	85.13	84.14	84.07	
<i>Helicobacter pametensis</i>	3.16	2.58	97.46	97.46	95.77	95.46	96.05	95.35	95.35	94.23	93.73	95.00	93.24	93.67	92.68	92.16	92.18	91.53	90.70	86.22	85.23	85.71	84.94	84.51	84.52	
<i>Helicobacter</i> sp. Bird B	3.17	2.58	2.00	98.03	95.77	95.46	94.64	94.79	95.42	94.15	94.01	96.41	93.52	93.03	91.83	91.67	91.84	91.46	90.55	85.15	84.65	86.34	85.07	83.79	84.86	
<i>Helicobacter</i> sp. Bird C	3.17	3.84	4.36	3.99	96.12	95.62	94.78	95.28	95.84	94.43	94.08	95.63	94.01	93.45	91.90	92.08	92.11	91.38	90.62	85.56	85.00	85.91	84.71	84.56	84.57	
<i>Helicobacter bilis</i>	3.32	4.17	4.68	4.51	2.40	97.64	95.69	98.02	95.83	97.46	96.68	94.00	92.86	92.66	93.23	91.86	90.90	90.23	91.03	86.17	85.60	85.31	84.75	84.32	83.69	
<i>Helicobacter hepaticus</i>	4.20	4.05	5.56	5.41	4.44	4.95	95.21	96.67	96.92	95.78	94.81	93.52	92.78	92.14	92.54	91.21	91.09	90.24	90.50	85.67	85.26	84.52	83.71	83.70	82.58	
<i>Helicobacter pullorum</i>	4.58	4.80	5.41	4.88	2.00	3.40	5.64	94.57	93.93	94.08	95.00	93.45	91.67	93.23	92.46	91.80	91.54	91.10	91.32	85.91	84.92	85.75	85.05	84.05	83.92	
" <i>Flexispira rappini</i> "	4.81	4.81	4.73	4.28	4.29	3.15	6.33	5.34	94.85	94.43	93.65	93.31	92.45	92.04	92.17	90.39	91.13	90.40	89.98	84.77	84.21	85.12	83.71	83.49	83.57	
<i>Helicobacter muridarum</i>	5.48	6.01	6.09	5.78	2.58	4.34	6.17	2.07	94.85	94.43	93.65	93.31	92.45	92.04	92.17	90.39	91.13	90.40	89.98	84.77	84.21	85.12	83.71	83.49	83.57	
<i>Helicobacter cinaedi</i>	5.71	6.55	6.24	6.17	3.39	5.38	5.18	4.96	6.63	5.41	6.62	93.66	90.62	90.99	90.63	89.96	89.44	88.63	89.34	84.43	83.93	83.58	83.09	82.86	81.89	
<i>Helicobacter canis</i>	5.78	5.17	3.68	4.50	6.25	6.78	6.86	6.47	7.01	7.55	6.62	93.66	90.62	90.99	90.63	89.96	89.44	88.63	89.34	84.43	83.93	83.58	83.09	82.86	81.89	
<i>Helicobacter mustelae</i>	6.94	7.08	6.78	6.25	7.50	7.59	8.83	8.43	7.95	8.66	10.02	8.97	91.84	90.56	90.61	90.50	90.26	89.35	89.35	83.66	83.52	84.79	84.08	82.73	83.31	
<i>Wohlnella succinogenes</i>	7.32	6.62	7.31	6.85	7.72	8.30	7.09	8.26	8.41	8.73	9.60	8.64	10.48	90.22	89.99	89.12	88.80	88.06	88.00	84.94	84.94	84.94	85.49	84.58	84.50	83.94
<i>Helicobacter pylori</i>	7.78	7.71	8.65	8.58	7.10	7.86	7.95	7.71	8.27	7.63	10.01	10.09	10.75	10.41	90.28	89.99	89.12	88.80	88.06	84.94	84.94	84.94	85.49	84.58	84.50	83.74
<i>Helicobacter fennelliae</i>	8.05	8.28	8.83	8.36	8.62	9.35	8.69	9.17	10.29	9.56	10.77	10.60	11.75	10.41	90.28	89.99	89.12	88.80	88.06	84.94	84.94	84.94	85.49	84.58	84.50	83.74
<i>Helicobacter nemestrina</i>	8.81	8.25	8.64	8.33	9.71	9.49	8.97	10.01	9.44	10.00	11.39	10.16	12.13	10.41	12.29	12.09	6.63	6.09	93.66	92.43	92.96	84.64	83.93	83.65	82.38	81.68
<i>Helicobacter achonnyx</i>	9.23	8.99	9.07	9.15	10.46	10.45	9.48	10.37	10.28	10.60	12.33	10.43	13.08	10.41	12.29	12.09	6.63	6.09	93.66	92.43	92.96	84.64	83.93	83.65	82.38	81.68
<i>Helicobacter felis</i>	9.54	9.93	10.10	10.02	9.56	10.16	9.22	9.62	10.76	9.94	11.50	11.49	13.08	6.74	11.33	7.39	7.92	6.61	94.15	92.49	83.17	82.46	84.08	82.82	82.17	82.82
" <i>Gastrospirillum hominis 1</i> "	15.34	15.23	16.55	16.04	15.29	15.91	15.61	14.92	17.02	15.69	17.45	18.43	16.82	17.60	17.18	16.87	19.06	19.75	18.20	83.64	82.55	83.05	82.77	81.84	81.63	81.63
<i>Campylobacter concisus</i>	15.95	16.45	17.17	16.74	15.99	16.41	16.84	15.52	17.73	16.56	18.08	18.61	16.82	18.32	18.08	18.21	19.98	21.16	19.86	7.32	93.02	87.08	86.74	93.79	85.83	85.83
<i>Campylobacter coli</i>	16.13	15.85	15.08	15.61	16.35	17.34	15.80	16.94	16.59	17.28	18.53	17.89	16.12	16.28	18.44	17.41	17.89	19.49	19.21	14.18	16.39	85.28	85.91	91.56	84.80	84.80
<i>Archeobacter butzleri</i>	16.57	16.81	16.65	17.10	17.05	18.36	16.67	17.47	18.37	17.99	19.17	17.89	16.22	17.70	20.08	17.95	19.52	20.78	20.78	14.59	15.60	96.73	85.12	95.97	94.36	97.15
<i>Campylobacter rectus</i>	17.82	17.35	18.26	17.29	17.60	18.38	17.93	17.12	18.65	17.73	19.46	19.63	17.36	19.15	19.09	19.51	20.37	21.45	20.80	6.48	8.96	16.59	17.54	94.36	97.15	97.15
<i>Archeobacter skirrowii</i>	17.90	17.34	16.91	17.28	18.40	19.83	18.10	19.00	18.55	19.35	20.73	18.88	18.07	18.32	21.01	19.67	17.52	19.85	21.07	15.70	16.99	4.14	2.90	18.07	18.07	18.07

<sup>a</sup> Numbers above the diagonal represent percent similarity based on uncorrected distances. Numbers below the diagonal represent distances corrected by the Jukes-Cantor method (11).

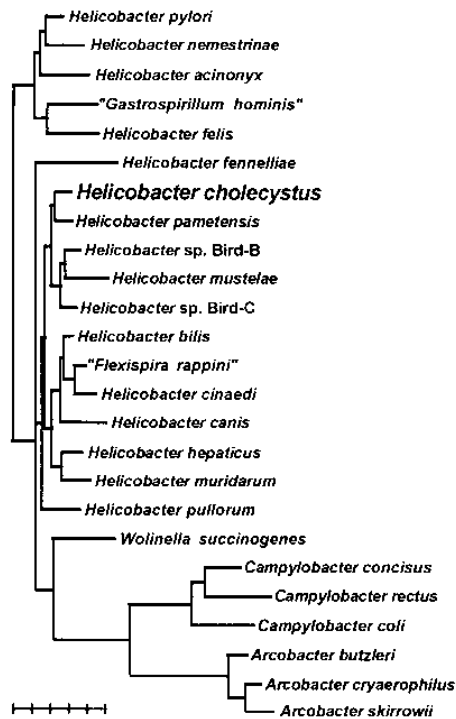


FIG. 2. Phylogenetic tree of members of the genera *Helicobacter*, *Campylobacter*, "*Flexispira*," "*Gastrospirillum*," *Wolinella*, and *Arcobacter* prepared by the neighbor-joining method (19, 24, 25). Phylogenetic distances between bacteria are calculated by totaling horizontal branches between bacteria. The bar represents five base substitutions per 100 residues.

hamsters with *H. cholecystus* infection had cholangiofibrosis, and 22 of 22 *H. cholecystus*-positive hamsters had centrilobular pancreatitis. Except for one 8-week-old animal with centrilobular pancreatitis, hamsters that were free from *H. cholecystus* colonization lacked histologic evidence of cholangiofibrosis or pancreatitis. When the isolation of *H. cholecystus* and the presence of lesions were compared statistically, no significant differences were detected ( $P \leq 0.0001$ ). These findings indicated that there was a strong correlation between the isolation of *H. cholecystus* and the presence of disease.

## DISCUSSION

In this report we describe the isolation of a novel *Helicobacter* sp. from the gallbladders of Syrian hamsters affected with cholangiofibrosis and centrilobular pancreatitis. We propose to name this bacterium *Helicobacter cholecystus*.

There is only one previous report of isolation of a *Helicobacter* species from hamsters. Gebhart et al. isolated *H. cinaedi* (9), a bacterium associated with enteritis, proctocolitis, and asymptomatic rectal infections in humans, from hamsters and proposed that hamsters are a reservoir for this bacterium. To ensure that our isolate was not *H. cinaedi*, sequence data from the two bacteria were compared, and the DNAs were determined to be only 94.72% similar. In addition, *H. cholecystus* and *H. cinaedi* differed in their production of alkaline phosphatase, abilities to grow at 42°C and under anaerobic conditions, sensitivities to cephalothin and nalidixic acid, and number and location of flagella; *H. cinaedi* may possess one to two polar or bipolar flagella, whereas *H. cholecystus* possesses a single polar flagellum.

*H. cholecystus* was phylogenetically and biochemically most

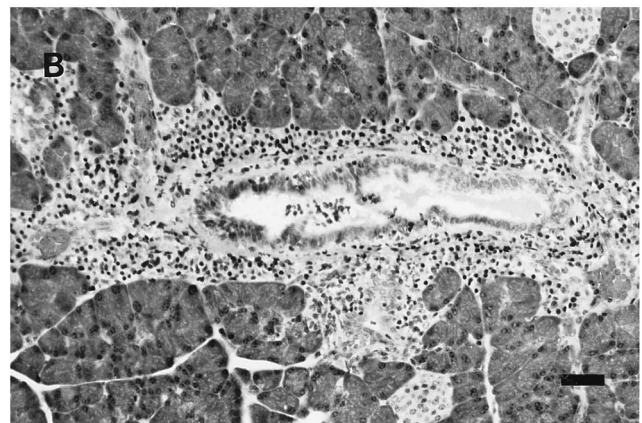
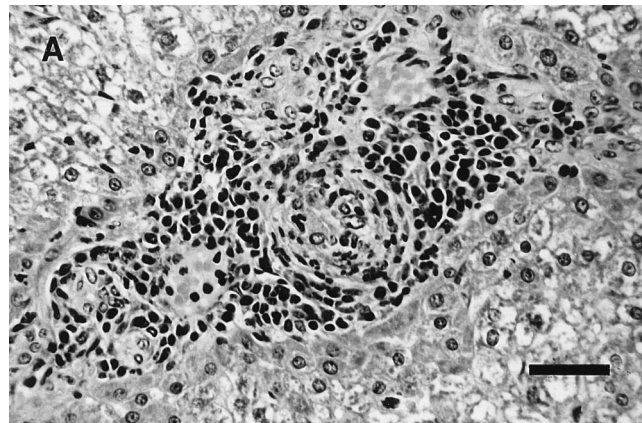


FIG. 3. Histologic lesions of cholangiofibrosis characterized by portal and ductular lymphoplasmacytic infiltrates and bile duct hyperplasia (A) and centrilobular pancreatitis characterized by periductular and ductular lymphoplasmacytic infiltrates (B), visualized by hematoxylin and eosin staining. Bars, 30  $\mu$ m.

closely related to *H. pametensis*, a bacterium isolated from wild birds and a domestic pig (3). *H. cholecystus* and *H. pametensis* differ in their susceptibilities to cephalothin and nalidixic acid and morphologically in that *H. pametensis* possesses two bipolar flagella compared to the single polar flagellum of *H. cholecystus*. The significance of this close phylogenetic relationship is unknown. To date, *H. pametensis* has not been isolated from any rodent species and has not been associated with clinical disease in its natural host.

*H. cholecystus* was compared phylogenetically, biochemically, and morphologically to the other rodent helicobacters. Phylogenetically, *H. cholecystus* was closely related to all of the known rodent helicobacters. *H. cholecystus* produced a unique biochemical profile compared to the other rodent helicobacters. The most notable biochemical feature of *H. cholecystus* was its lack of urease activity. Of the rodent helicobacters, only *H. cinaedi*, whose true definitive host is unknown, is urease negative. The role of urease in rodent *Helicobacter* infections has not been determined. In *H. pylori*, a gastric helicobacter, urease has been associated with virulence and has been proposed to play a role in colonization and survival in the acidic environment of the stomach (12).

*H. cholecystus* was morphologically distinct from the rodent helicobacters. *H. cholecystus* had a fusiform shape similar to the shapes of *H. bilis* and "*F. rappini*," (7, 20), but, unlike these bacteria, *H. cholecystus* possessed only one polar flagellum and had no periplasmic fibers; *H. bilis* and "*F. rappini*" have

periplasmic fibers and bipolar tufts of flagella. *H. hepaticus* also has no periplasmic fibers but it possesses single bipolar flagella and is slightly curved (6). *H. cholecystus* bore little resemblance to *H. muridarum*, which is spiral and has bipolar tufts of flagella and periplasmic fibers (13).

The role of *H. cholecystus* in cholangiofibrosis and centrilobular pancreatitis remains uncertain; however, three pieces of evidence suggest that this bacterium may play a role in the disease progression. First, isolation of *H. cholecystus* from the gallbladder strongly correlated with the presence of either cholangiofibrosis or centrilobular pancreatitis. Second, pancreatic and hepatic lesions were found concurrently in the majority of affected hamsters. Because the hamster possesses a common duct joining the bile and pancreatic ducts prior to emptying into the intestinal tract (26), it is conceivable that these lesions could result from an ascending infection of the common duct. Although the intestinal tract was not cultured in this study, uncharacterized *Helicobacter* species have been identified by PCR in feces of Syrian hamsters, indicating that helicobacters inhabit the intestinal tract (unpublished data). Third, other members of the genus *Helicobacter* have been associated with hepatic disease; these include *H. hepaticus* and *H. bilis* in mice and *H. pullorum* in poultry (23). Taken together, these findings suggest that *H. cholecystus* may ascend from the intestinal tract via the common bile duct and initiate or exacerbate lesions of cholangiofibrosis and centrilobular pancreatitis.

It is also possible that the presence of *H. cholecystus* in the gallbladders of affected hamsters is secondary to the presence of disease. Bacteria have been found in the bile ducts of human patients with obstructive biliary diseases (21), and an organism morphologically consistent with "*Flexispira rappini*" was identified in rats experimentally infected with the liver fluke *Fasciola hepatica*. In the latter study, the investigators speculated that the trematode infection may have altered the bile, allowing the bacterium to grow in a normally hostile environment (5). It is conceivable that the biliary environment of hamsters with cholangiofibrosis is altered to the point that it favors *H. cholecystus* growth. Studies are currently ongoing in our laboratory to define the role of *H. cholecystus* in cholangiofibrosis and centrilobular pancreatitis.

*H. cholecystus* was isolated from the gallbladder of one hamster without hepatic lesions, but this hamster had pancreatic lesions. This animal may represent an early infection that had progressed into the pancreatic duct system but not into the biliary system. One hamster in our study had mild pancreatic lesions without isolation of *H. cholecystus*. Since we cultured only the gallbladder, it is possible that *H. cholecystus* may have been present in the pancreatic duct but not in the gallbladder, and thus, this animal was considered culture negative.

In conclusion, we have described the isolation of a novel *Helicobacter* sp., which we have designated *H. cholecystus*, from the gallbladder of Syrian hamsters. The isolation of *H. cholecystus* correlated with the presence of histologic lesions of cholangiofibrosis and centrilobular pancreatitis, indicating that this bacterium may play a role in this disease syndrome. Additional studies are ongoing in our laboratory to define the role of this bacterium in the development of pancreatic and hepatic disease.

**Description of *Helicobacter cholecystus* sp. nov.** *Helicobacter cholecystus* (kō.lə'sis.tus. N.L. n. *cholecyst*, gallbladder; N.L. gen. n. *cholecystus*, relating to the gallbladder). Filamentous cells are 0.5 to 0.6 μm by 3.0 to 5.0 μm. Coccoid forms are 0.8 to 1.2 μm in diameter. Cells are gram negative, do not form spores, and are motile by means of a single sheathed polar flagellum. Colonies are pinpoint. Cells grow under microaero-

philic and anaerobic conditions but do not grow aerobically. There is growth at 37 and 42°C but not at 25°C. There is growth in the presence of 1% glycine and 5% bile salts but not in the presence of 1.5% NaCl. *H. cholecystus* has oxidase, catalase, arginine aminopeptidase, and L-arginine arylamidase activities but not urease, histidine aminopeptidase, leucine aminopeptidase, or gamma glutamyltransferase activities. Nitrate is reduced. Indoxyl acetate and hippurate are not hydrolyzed. Cells are resistant to cephalothin and exhibit intermediate sensitivity to nalidixic acid. The type strain, Hkb-1<sup>T</sup>, was isolated from the gallbladder of a hamster with cholangiofibrosis.

#### ACKNOWLEDGMENTS

We thank Connie Caffrey, Rick Knowles, Beth Livingston, Dawn Shaffer, Preston Stogsdill, and Thomas Shannon for exceptional technical assistance and Howard Wilson for photography.

#### REFERENCES

1. Brunnert, S. R., and N. H. Altman. 1991. Laboratory assessment of chronic hepatitis in Syrian hamsters. *Lab. Anim. Sci.* **41**:559-562.
2. Chesterman, F. C., and A. Pomerance. 1965. Cirrhosis and liver tumors in a closed colony of golden hamsters. *Br. J. Cancer* **19**:802-811.
3. Dewhirst, F. E., C. Seymour, G. J. Fraser, B. J. Paster, and J. G. Fox. 1994. Phylogeny of *Helicobacter* isolates from bird and swine feces and description of *Helicobacter pametensis* sp. nov. *Int. J. Syst. Bacteriol.* **44**:553-560.
4. Finegold, S. M., and W. J. Martin. 1982. *Diagnostic microbiology*, 6th ed., p. 660-677. C. V. Mosby Co., St. Louis.
5. Foster, J. R. 1984. Bacterial infection of the common bile duct in chronic fascioliasis in the rat. *J. Comp. Pathol.* **94**:175-181.
6. Fox, J. G., F. E. Dewhirst, J. G. Tully, B. J. Paster, L. Yan, N. S. Taylor, M. J. Collins, P. L. Gorelick, and J. M. Ward. 1994. *Helicobacter hepaticus* sp. nov., a microaerophilic bacterium isolated from livers and intestinal mucosal scrapings from mice. *J. Clin. Microbiol.* **32**:1238-1245.
7. Fox, J. G., L. L. Yan, F. E. Dewhirst, B. J. Paster, B. Shames, J. C. Murphy, A. Hayward, J. C. Belcher, and E. N. Mendes. 1995. *Helicobacter bilis* sp. nov., a novel *Helicobacter* species isolated from bile, livers and intestines of aged, inbred mice. *J. Clin. Microbiol.* **33**:445-454.
8. Franklin, C. L., S. V. Gibson, J. E. Wagner, C. J. Caffrey, and T. R. Shannon. 1989. Cholangiohepatitis in Syrian hamsters. *Lab. Anim. Sci.* **39**:469.
9. Gebhart, C. J., C. L. Fennell, M. P. Murtaugh, and W. E. Stamm. 1989. *Campylobacter cinaedi* is normal intestinal flora in hamsters. *J. Clin. Microbiol.* **27**:1692-1694.
10. Hamilton, J. M., T. Reynolds, and P. G. Saluja. 1983. Cholangiofibrosis in the Syrian golden hamster. *Vet. Rec.* **112**:359-360.
11. Jukes, T. H., and C. R. Cantor. 1969. Evolution of protein molecules, p. 21-132. In H. N. Munro (ed.), *Mammalian protein metabolism*, vol. 3. Academic Press, Inc., New York.
12. Lee, A., J. Fox, and S. Hazell. 1993. Pathogenicity of *Helicobacter pylori*: a perspective. *Infect. Immun.* **61**:1601-1610.
13. Lee, A., M. W. Phillips, J. L. O'Rourke, B. J. Paster, F. E. Dewhirst, G. J. Fraser, J. G. Fox, L. I. Sly, P. J. Romaniuk, T. J. Trust, and S. Kouprach. 1992. *Helicobacter muridarum* sp. nov., a microaerophilic helical bacterium with a novel ultrastructure isolated from the intestinal mucosa of rodents. *Int. J. Syst. Bacteriol.* **42**:27-36.
14. Marshall, B. J. 1990. *Campylobacter pylori*: its link to gastritis and peptic ulcer disease. *Rev. Infect. Dis.* **157**:465-471.
15. Marshall, B. J., and J. R. Warren. 1984. Unidentified curved bacilli in the stomach of patients with gastritis and peptic ulceration. *Lancet* **i**:1311-1314.
16. Phillips, M. W., and A. Lee. 1983. Isolation and characterization of a spiral bacterium from the crypts of rodent gastrointestinal tracts. *Appl. Environ. Microbiol.* **45**:675-683.
17. Relman, D. A., S. Jeffery, M. B. Loutit, T. M. Schmidt, S. Falkow, and L. S. Tompkins. 1990. The agent of bacillary angiomatosis—an approach to the identification of uncultured pathogens. *N. Engl. J. Med.* **323**:1573-1580.
18. Riley, L. K., C. L. Franklin, R. R. Hook, Jr., and C. Besch-Williford. 1996. Identification of murine helicobacters by PCR and restriction enzyme analysis. *J. Clin. Microbiol.* **34**:942-946.
19. Saitou, N., and M. Nei. 1987. The neighbor-joining method: a new method for reconstructing phylogenetic trees. *Mol. Biol. Evol.* **4**:406-425.
20. Schauer, D. B., N. Ghori, and S. Falkow. 1993. Isolation and characterization of "*Flexispira rappini*" from laboratory mice. *J. Clin. Microbiol.* **31**:2709-2714.
21. Sherlock, S. 1989. *Diseases of the liver and biliary system*, 8th ed., p. 289-300. Blackwell Scientific Publications, Oxford.
22. Snedecor, G. W., and W. G. Cochran. 1989. *Statistical methods*, 8th ed., p. 124-129. The Iowa State University Press, Ames.
23. Stanley, J., D. Linton, A. P. Burnens, F. E. Dewhirst, S. L. W. On, A. Porter,

- R. J. Owen, and M. Costas.** 1994. *Helicobacter pullorum* sp. nov.—genotype and phenotype of a new species isolated from poultry and from human patients with gastroenteritis. *Microbiology* **140**:3441–3449.
24. **Studier, J. A., and K. J. Keppler.** 1988. A note on the neighbor-joining algorithm of Saitou and Nei. *Mol. Biol. Evol.* **5**:729–731.
25. **Swofford, D. L., and G. J. Olsen.** 1990. Phylogeny reconstruction, p. 411–501. *In* D. M. Hillis and C. Moritz (ed.), *Molecular systematics*. Sinauer Associates, Inc., Sunderland, Mass.
26. **Takahashi, M., P. Pour, J. Althoff, and T. Donnelly.** 1977. The pancreas of the Syrian hamster (*Mesocricetus auratus*). I. Anatomical study. *Lab. Anim. Sci.* **27**:336–342.
27. **Totten, P. A., C. L. Fennell, F. C. Tenover, J. M. Wezenberg, P. L. Perine, W. E. Stamm, and K. K. Holmes.** 1985. *Campylobacter cinaedi* (sp. nov.) and *Campylobacter fennelliae* (sp. nov.): two new *Campylobacter* species associated with enteric disease in homosexual men. *J. Infect. Dis.* **151**:131–139.
28. **Ward, J. M., M. R. Anver, D. C. Haines, and R. E. Benveniste.** 1994. Chronic active hepatitis in mice caused by *Helicobacter hepaticus*. *Am. J. Pathol.* **145**:959–968.
29. **Ward, J. M., J. G. Fox, M. R. Anver, D. C. Haines, C. V. George, M. J. Collins, Jr., P. L. Gorelick, K. Nagashima, M. A. Gonda, R. V. Gilden, J. G. Tully, R. J. Russell, R. E. Benveniste, B. J. Paster, F. E. Dewhirst, J. C. Donovan, L. M. Anderson, and J. M. Rice.** 1994. Chronic active hepatitis and associated liver tumors in mice caused by a persistent bacterial infection with a novel *Helicobacter* species. *J. Natl. Cancer Inst.* **86**:1222–1227.