

# **PURE AND MIXED HILUS-CELL TUMOURS OF OVARY**

**Arris and Gale Lecture delivered at the Royal College of Surgeons of England**

**on**

**14th November 1966**

**by**

**R. Salm, M.D., F.C.Path.**

**Department of Histopathology, Royal Cornwall Hospital (Treliske), Truro, Cornwall**

HILUS-CELL TUMOURS, as the name implies, arise from specific cells in the ovarian hilum. Although ovarian hilus-cells were identified more than 40 years ago (Berger, 1922), their characteristics are still not widely known so that, for example, Shaw and Dastur failed to recognize them in 1949, and Lees and Paine (1958) mistook them for adrenal rests. Thus it may be useful to summarize briefly their cytological and hormonal properties.

## **NORMAL HILUS- AND LEYDIG-CELLS**

Hilus-cells are rather large, epithelioid, liver-like cells, measuring on an average 20 microns in diameter, with spherical, eccentrically placed vesicular nucleus, measuring 7 to 10 microns in diameter, displaying sparse chromatin clumps and one or more nucleoli. The wide cytoplasmic rim is usually granular and eosinophilic, and may contain inclusions, viz, lipids, lipochrome pigment and occasional crystalloids of Reinke, which are slender, rod-like, mono-refringent protein bodies with rounded ends which may be surrounded by a narrow clear halo, and may measure up to 30 microns in length. Occasionally their cytoplasm is vacuolated due to a high lipid content.

These cells are found, lying in small groups, mainly in the ovarian hilum, being more numerous at either pole, but are never met with in the broad ligament, mesosalpinx or parametria (Brannan, 1927). Hilus-cells are frequently situated near blood and lymph vessels, but occur so often near or within hilar nerves that it has been suggested that nerves may serve as organizers (Merrill, 1959).

According to Brannan (1927) and Loubet and Loubet (1961) hilus-cells can be found from birth to old age, and Kohn (1928) mentions their presence in an anencephalic infant (an observation which I have been unable to confirm in several such cases). Other authors (Merrill, 1959; own observations) have failed to demonstrate hilus-cells in neonates and infants, and Berger (1945) records that they disappear after the sixth month of gestation and become prominent only at puberty, differentiating from connective tissue fibroblasts. Brannan encountered them in 12.5 per cent, and Sternberg (1949) in at least 80 per cent of adult ovaries, from reproductive life to old age. During pregnancy hilar cells become hyperplastic and hypertrophic, staining deep red with eosin (Brannan, 1927; Sternberg, 1949).

It is necessary to stress already here the close analogy between ovarian hilus-cells and the interstitial- or Leydig-cells of the testis. These display an identical developmental cycle, decreasing in number during the second half of intra-uterine life (Zondek and Zondek, 1965), and reappear at puberty, differentiating from the intertubular connective tissue. Leydig-cells of extratesticular localization are not unusual, and small nests may be present in epididymis and spermatic cord. They possess the same morphological and tinctorial characteristics as ovarian hilus-cells, and may contain the same cytoplasmic inclusions, including Reinke's crystalloids, structures, incidentally, which do not occur in any other species of animal but man (Collins and Pugh, 1964; Cotchin, 1965). With the single exception of an adrenal ganglioneuroma (Scully and Cohen, 1961) Reinke's crystalloids have never been found in any other type of cell.

### **HILUS- AND LEYDIG-CELL TUMOURS**

Both hilus- and Leydig-cells are considered to be the source of gonadal secretion of androgens, and hence it is of particular interest to study tumours arising from them. The first Leydig-cell tumours were identified by Waldeyer in 1872, and the first hilus-cell tumour was recorded by Berger in 1942. Both tumours are rare. In Dixon and Moore's (1952) series of testicular tumours the incidence of Leydig-cell tumours was 1.2 per cent, and in Collins and Pugh's (1964) series 1.4 per cent. Ovarian hilus-cell tumours are presumably even less frequent in view of the organ's propensity to tumour formation. Boivin and Richart were able to collect but 33 previously published cases in 1965.

In man prepubertal Leydig-cell tumours cause precocious sexual development, deepening of the voice and a premature virile appearance which has been aptly called "Infant Hercules". In adults they are associated in from 10 per cent (Dixon and Moore, 1952) to 43 per cent (Collins and Pugh, 1964) of cases with gynaecomastia, and may cause loss of libido, impotence and aspermia.

In women hyperplasia or tumours of hilus-cells usually cause virilization. The complete syndrome encompasses secondary amenorrhoea, facial and generalized hirsutes, receding frontal hair line and partial baldness, seborrhoeic skin and acne, pubic hair distribution of male type, atrophy of breasts, enlargement of larynx and deepening of the voice, enlargement of clitoris, and masculine appearance. However, some reports have recorded evidence of hyperoestrinism due to hilus-cell tumours.

It is proposed to discuss these paradoxical hormonal effects and other related problems after describing a series of six hilus-cell tumours.

### **STAINING REACTIONS**

In haematoxylin-eosin stains hilus-cells presented frequently as liverlike cells with granular or uniform, strongly eosinophilic cytoplasm. If their lipid content was high the cytoplasm was foamy in appearance, and

frozen sections would confirm the presence of isotropic and anisotropic lipoid material. Brownish lipochrome granules were P.A.S.-positive and fuchsinophil. Silver impregnations demonstrated the presence of a moderately coarse but regular reticulin framework which supported a rich capillary network suggestive of an endocrine function.

The cytoplasm of hilus-cells appeared azure in Giemsa, fuchsinophil in Vines, pale ochre in P.A.S., pale reddish-brown in P.T.A.H., and pale magenta in trichrome stains. In sections overstained with eosin hilus-cells stood out very clearly on account of their marked affinity for the dye.

No single staining method employed proved to be either specific or reliable in demonstrating Reinke's crystalloids. Although strongly eosinophilic in haematoxylin-eosin stains, they were often difficult to detect within the eosinophilic cytoplasm, unless clearly demarcated by a halo. They were P.A.S.-negative and usually strongly fuchsinophilic in Vines's stain, though not well-defined within the likewise fuchsinophil cytoplasm. Heidenhain's method stained Reinke's crystalloids, but as all structures stain black with this stain they were often difficult to detect, and distinguishing them from artefacts was sometimes impossible. Safranin, staining all structures red, had no advantages over eosin. In P.T.A.H. stains Reinke's crystalloids were mostly stained dark violet and formed a good contrast to the but lightly stained tissue background. In trichrome stains these inclusions were often conspicuous, staining a bright red. But all staining reactions were variable and inconsistent. For example, some crystalloids, in trichrome stains, would stain red, some appeared pale magenta, and others, in the same section, had not taken up any stain, their outlines being sometimes only just discernible owing to a slight refraction of the transmitted light. Artefacts that had to be excluded were erythrocytes, viewed side-on, in haematoxylin-eosin and trichrome stains, and capillary endothelia in P.T.A.H. stains.

## CASE REPORTS

### Case 1

W.M.M., aged 44 years, gave a two-year history of amenorrhoea. Twelve months previously her voice had become hoarse, so that she had had to discontinue singing in the church choir. During the past four months she had developed hairs on lips and cheeks necessitating frequent shaving and treatments by a beauty specialist, her breasts had become smaller and she complained of lower abdominal pain. On examination her blood pressure was 140/70, the clitoris measured  $3.5 \times 1.5$  cm., and her right ovary was enlarged. The results of all other investigations were within normal limits including the values of urinary 17 ketosteroids, which fluctuated between 5.4 and 12 mg./24 hours. A right oöphorectomy was carried out. Post-operatively, the 17 KS values ranged from 6.9 to 11.5 mg./24 hours, the growth of facial hair ceased, but her other symptoms had not changed a year later.

The excised ovary measured  $4 \times 2 \times 2$  cm. and weighed 10 Gm. In its proximal pole, and close to its base, it incorporated a round, soft, dark tan, well-defined mass, measuring 2 cm. in diameter.

*Microscopical examination (64/2640).* A sharply circumscribed, non-encapsulated, round tumour adjoins the ovarian hilum, which contains a few rete tubules, but no hilus-cells. Superiorly the mass is covered by a crescent of ovarian cortex which

## PURE AND MIXED HILUS-CELL TUMOURS OF OVARY

incorporates a few small simple cysts and a number of arterioles with thick hyaline walls. The growth is composed of closely spaced, uniform, typical hilus-cells with indistinct borders, possessing round vesicular nuclei with coarse nucleoli and much eosinophil, largely granular cytoplasm (Fig. 1). Mitotic figures are very scanty. Sex chromatin is discernible in 22 per cent of the nuclei. No cytoplasmic inclusions are demonstrable in paraffin and frozen sections. The growth is well supplied with small capillaries, and a moderately fine reticulin network is surrounding groups of cells.

*Diagnosis.* Pure hilus-cell tumour associated with virilization.

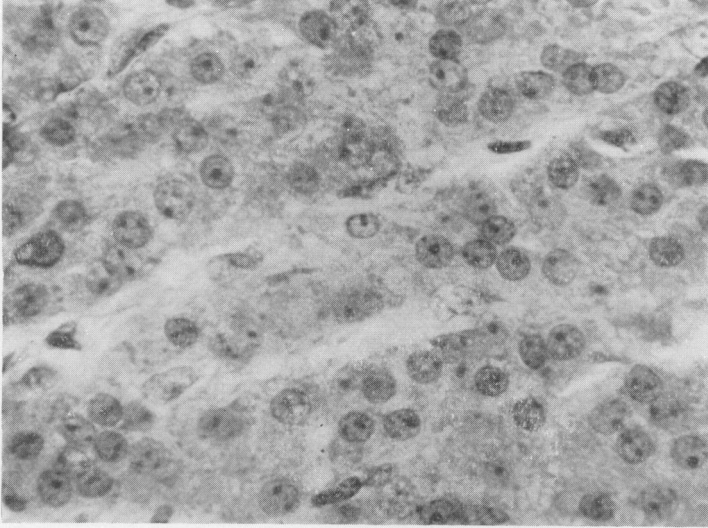


Fig. 1. Case 1. High-power view of hilus-cell tumour. Note vesicular nuclei, coarse nucleoli, granular cytoplasm and indistinct cell borders. Haematoxylin-eosin.  $\times 100$ .

### Case 2

B.W., 79 years. Four years previously the patient had complained of menorrhagia and an adenomatous polypus had been removed. A hysterectomy had been considered advisable, but the patient had refused an operation. She was readmitted for recurring menorrhagias, a simple polypus was removed followed by hysterectomy and bilateral salpingo-oophorectomy.

The uterine cavity was lined by polypoidal endometrium, measuring 5 mm. in height. Both ovaries were large for the patient's age, measuring  $2.5 \times 2$  cm. and  $2.3 \times 1.7$  cm. respectively. One ovary contained a round, brownish, well delimited mass measuring 1.4 cm. across.

*Microscopic examination (872/60).* The myometrium is made up of well-developed smooth muscle fibres, and is of premenopausal appearance. The endometrium is high and there is an endometrial polypus, measuring  $2 \times 0.5$  cm. The endometrial stroma is active and cellular and many of the glands are cystically dilated. Contrasting sharply with this cystic hyperplastic endometrium is a fair-sized area of endometrium with crowded acini which are lined by several rows of atypical epithelial cells with comparatively large vesicular nuclei (Fig. 2a). Small numbers of mitoses are present amongst these cells as well as in the adjacent stroma.

One of the ovaries, 4 mm. below the surface, contains a non-encapsulated but sharply defined tumour mass, measuring  $1.4 \times 1.1$  cm. It is made up of closely spaced thin trabeculae composed of typical uniform hilus-cells with round vesicular nuclei, distinct nucleoli and much eosinophilic cytoplasm (Fig. 2b). Sex chromatin is demonstrable in 30 per cent of the nuclei. The cell borders are indistinct. The tumour is well supplied with small capillaries, and a meshwork of reticulin fibres is present throughout.

A very occasional mitotic figure is discernible, but lipochrome granules and Reinke's crystalloids are absent. The ovarian cortex measures up to 7 mm. in width, presents the features of hyperthecosis and is studded with corpora albicantes. Small clusters of cells with large nuclei and eosinophilic cytoplasm, the nature of which is debatable, are occasionally met with. They could be either of hilar or of luteal origin. No hilus-cells are detectable in the hilum, but a single small clump of luteal cells lies below the lower margin of the growth.

The contralateral ovary is likewise large for the patient's age and also possesses a thick thecomatous cortex, measuring up to 1.7 cm. in width, which contains many corpora albicantes and arterioles with thick hyaline walls. Similar cells to those found in the tumour-bearing ovary, which could be either of hilar or of luteal origin, and which do not contain cytoplasmic inclusions, are distributed haphazardly in the cortical tissues. The hilum exhibits a well-developed rete ovarii, but there are only a very few hilus-cells.

*Diagnosis.* (1) Pure hilus-cell tumour associated with hyperoestrinism. (2) Early endometrial adenocarcinoma. (3) Bilateral hyperthecosis.

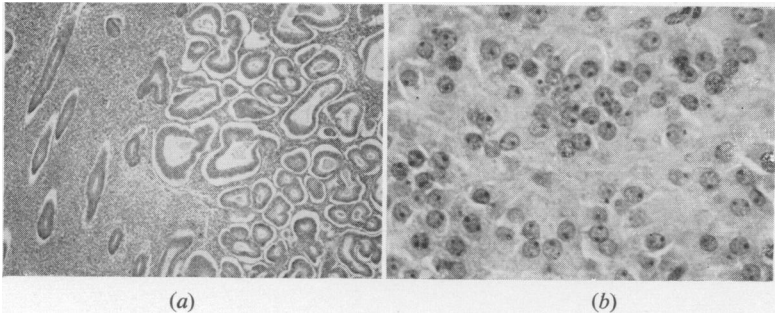


Fig. 2. Case 2. (a) Sharp demarcation between normal endometrium and endometrial adenocarcinoma. H. and E.  $\times 20$ . (b) Typical hilus-cell tumour. H. and E.  $\times 20$ .

### Case 3

Mrs. C., aged 48 years, presented with a sensation of weight and discomfort in the lower abdomen. Menstruation had ceased abruptly six years previously. Since six months she had noticed loss of hair from the temples whilst hairs had started to grow on her face so that she had to shave daily, and her voice had become deeper. On examination the only additional findings were a slightly elevated blood pressure (160/100) and a mass in the right pelvis. External genitalia and distribution of pubic hair were normal. No hormone studies were carried out.

A large right-sided ovarian tumour was removed at laparotomy. A month later menstruation recommenced and three months later her symptoms had regressed. There was no longer any loss of hair from the scalp, her facial hirsutes had started to disappear and her voice had become softer.

The tumour was a roughly spherical solid mass with smooth surface, measuring 9 cm. in diameter. On sectioning its tissues were firm, yellowish-orange, and of a small-nodular pattern.

*Microscopical examination (65/1684).* The multiple blocks cut show a bulky growth with well-defined periphery, covered by a fairly thin zone of rather fibrous ovarian cortex. It is of a nodular or plexiform pattern and supported by either acellular or moderately cellular fibrous tissue. The greater part of the neoplasm is made up of spindle-shaped granulosa-cells with moderately large, vesicular nuclei which are arranged either in solid sheets or as intersecting bundles. Mitoses are present in small numbers. Here and there the tumour displays acinar and tubular differentiation, with direct transitions between the two patterns (Fig. 3a). Patchy aggregations of siderophages are indicative of previous focal haemorrhage. In sharp contrast to the darker staining granulosa-cells are clumps of typical hilus-cells, with small round nuclei, distinct nucleoli and partly granular, strongly eosinophilic cytoplasm. Occasionally

## PURE AND MIXED HILUS-CELL TUMOURS OF OVARY

their cytoplasm is foamy or vacuolated. Lipochrome pigment is very scanty, but frozen sections demonstrate the presence of much intracytoplasmic neutral fat and, patchily distributed, small numbers of short, needle-shaped, birefractile crystals, and these lipids are also seen in granulosa-cells. Typical Reinke's crystalloids can be discerned in many areas (Fig. 3*b*), and are occasionally numerous. A few intracytoplasmic eosinophil, P.A.S.-negative globules are also discernible. Sex chromatin is distinguish-

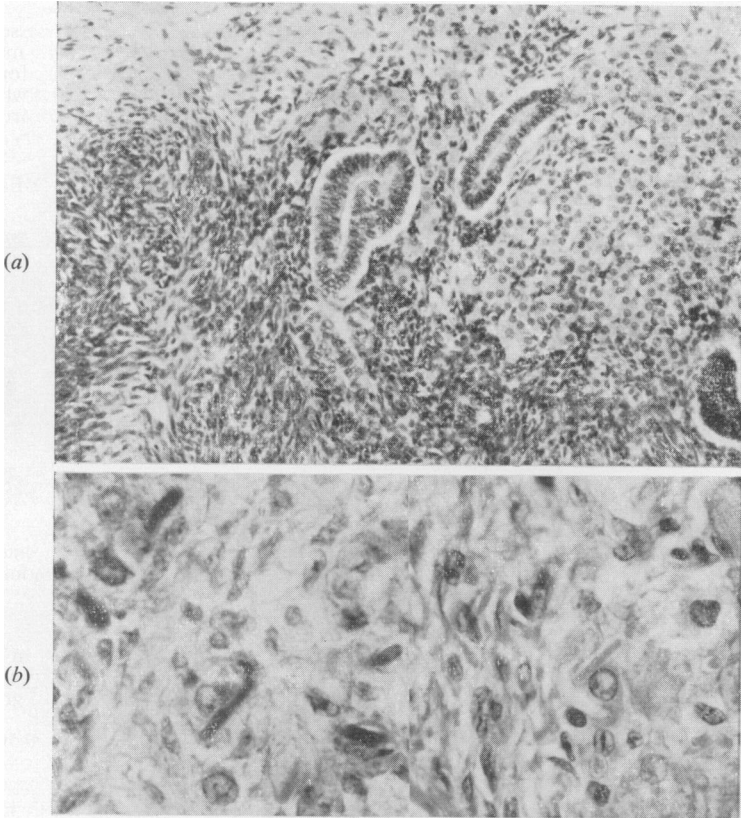


Fig. 3. Case 3. (a) Diffusely growing granulosa-cell tumour with tubular differentiation. Area of hilus-cells to right of centre. H. and E.  $\times 40$ . (b) Composite picture of Reinke's crystalloids. At left stained with Mallory's trichrome, at right H. and E. Note surrounding halo at right.  $\times 100$ .

able in the nuclei of 28 per cent of hilus- and in 38 per cent of granulosa-cells. Transitions between stromal fibroblasts and hilus-cells can be traced, but although hilus-cells often invest the peripheries of granulosa-cell masses they are everywhere sharply demarcated from each other.

*Diagnosis.* Mixed granulosa/hilus-cell tumour associated with virilization.

### Case 4

The patient, aged about 24 years, gave 12 months' history of amenorrhoea, hirsutism and deepening of the voice. An enlarged ovary was removed. No follow-up information is available.

The enlarged ovary contained a well-circumscribed though non-encapsulated tumour mass, measuring  $2.7 \times 1.8$  cm.

*Microscopical examination* (D3938). Superiorly the tumour is covered by a thin rim of normal ovarian cortex, measuring up to 4 mm. in width, incorporating numbers of ova and a few follicular cysts. The bulk of the growth is a typical granulosa-cell tumour of varying microfolliculoid or trabecular pattern (Fig. 4a). Mitotic figures are present but scanty. At the margins the granulosa-cells are columnar in shape. There is a fair amount of moderately cellular fibrous stroma. Lying within this fibrous tissue, and differentiating from it, are groups of typical hilus-cells possessing small vesicular nuclei, distinct nucleoli and strongly eosinophilic cytoplasm, but mitoses, lipochrome pigment and Reinke's crystalloids are absent. Although granulosa- and hilus-cells are intimately mixed in some areas, there are no transitions between these two types of cell. In a few areas hilus-cells are so plentiful that their bulk equals that of the interdigitating granulosa-cell trabeculae (Fig. 5). Sex chromatin is discernible in the nuclei of 45 per cent of hilus- and 47 per cent of granulosa-cells (Fig. 4b).

*Diagnosis.* Mixed granulosa/hilus-cell tumour associated with virilization.

### Case 5

H.S., aged 65 years, had had three postmenopausal vaginal bleedings. Externally there were no abnormalities. Her blood pressure was 170/90. No further investigations were done. A routine hysterectomy and bilateral salpingo-oophorectomy was carried out for uterine fibroids. A vaginal smear, taken 10 days post-operatively, showed the pattern of senile vaginitis.

The excised uterus weighed 345 Gm. Its enlargement was due to multiple fibroids. The endometrium was 3 mm. high, smooth and pale. A large endometrial polypus was attached to the fundus, measuring  $3.5 \times 2.5 \times 1.1$  cm. The left ovary measured  $2 \times 1.5$  cm., the right  $3 \times 2$  cm. and this contained a well-defined, soft, tan-coloured mass, measuring  $2.5 \times 1.5$  cm.

*Microscopical examination* (65/1072). The myometrium is composed of well developed smooth muscle fibres of premenopausal type, and displays a minor degree of subendometrial adenomyosis. The endometrium is of moderate height, but many of its glands are cystically dilated, producing a "Swiss cheese" pattern (Fig. 6a). Their lumina are filled with thin, or small-globular, or thick, inspissated secretion. The endometrial glands are lined preponderantly by one but sometimes by several rows of high columnar epithelial cells with vesicular nuclei, exhibiting an occasional mitotic figure. The endometrial stroma is cellular, well endowed with capillaries, and occasional mitoses are discernible. Small numbers of lymphocytes are scattered diffusely, or form small stromal aggregations.

The endometrial polypus displays similar features. Its stroma is cellular and patchily oedematous, and its glands are markedly dilated, measuring up to 5 mm. across.

The left ovary is large considering the age of the patient, and shows marked hypertecosis and numbers of corpora albicantes.

The right ovary contains a spherical, non-encapsulated but well-circumscribed mass, the lower margin of which abuts upon the hilum. It is covered by ovarian cortex, measuring up to 5 mm. in width, which likewise displays the features of hypertecosis. The tumour is made up of two different, intimately mixed, interdigitating but separate components, present in about equal proportions. One shows the characteristics of a trabecular or plexiform granulosa-cell tumour with oval, vesicular nuclei. Sometimes the cells form small compact masses, and small numbers of mitotic figures are discernible. The second tumour element is composed of typical hilus-cells with round vesicular nuclei and coarse nucleoli, surrounded by much strongly eosinophilic cytoplasm (Fig. 7). Some hilus-cells contain lipochrome pigment, and occasional mitoses are present, but no Reinke's inclusions are discernible. Frozen sections demonstrate that intracellular isotropic and anisotropic lipids are confined to the granulosa-cell part of the tumour. Sex chromatin is present in the nuclei of 45 per cent of hilus- (Fig. 6b) and 24 per cent of granulosa-cells.

*Diagnosis.* Mixed granulosa/hilus-cell tumour associated with hyperoestrinism.

### Case 6

P.T., a girl aged 13 years, was seen on account of recent deepening of her voice, failure of breast development and abdominal enlargement. A partly cystic, partly

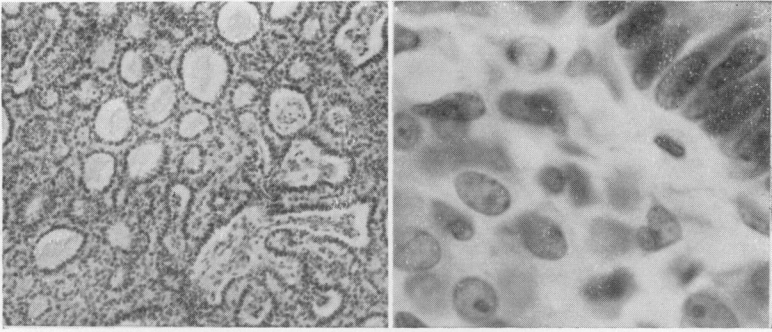


Fig. 4. Case 4. (a) Microfolliculoid granulosa-cell tumour. H. and E.  $\times 26$ . (b) Sex chromatin is visible in central hilus-cell and just discernible in granulosa-cells to the right. H. and E.  $\times 666$ .

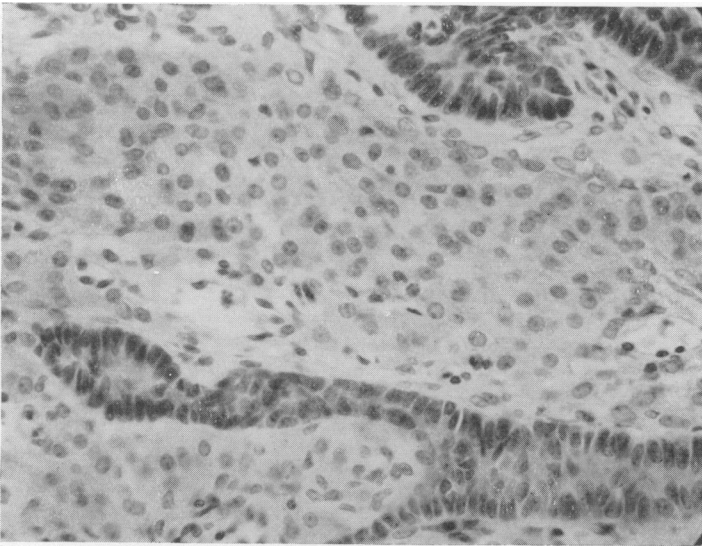


Fig. 5. Case 4. Large hilus-cell masses between granulosa-cell trabeculae. H. and E.  $\times 40$ .

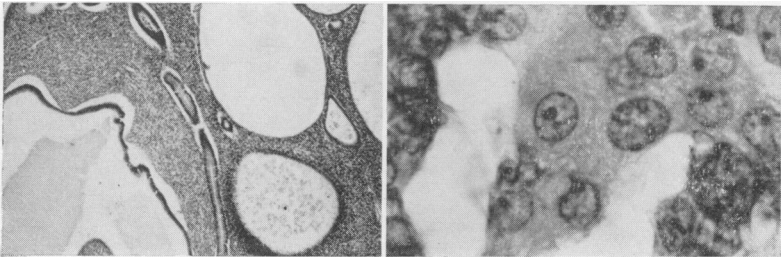


Fig. 6. Case 5. (a) Cystic endometrial hyperplasia. H. and E.  $\times 23$ . (b) Sex chromatin is clearly visible in the three central hilus-cells. H. and E.  $\times 571$ .



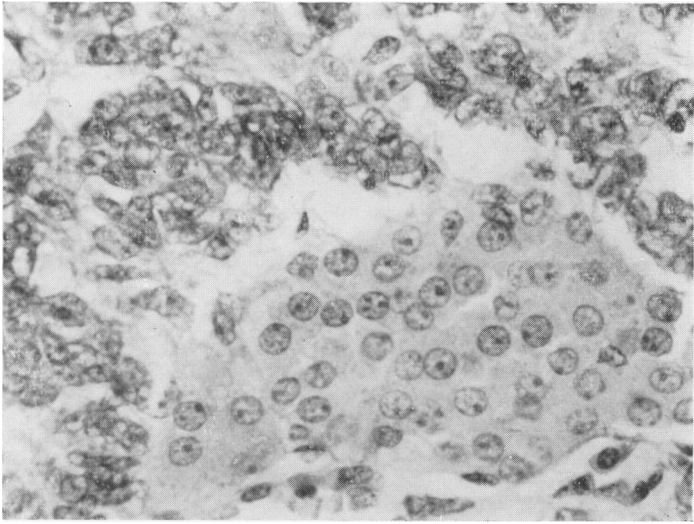


Fig. 7. Case 5. Mass of typical hilus-cells surrounded by rim of granulosa-cells. H. and E.  $\times 100$ .

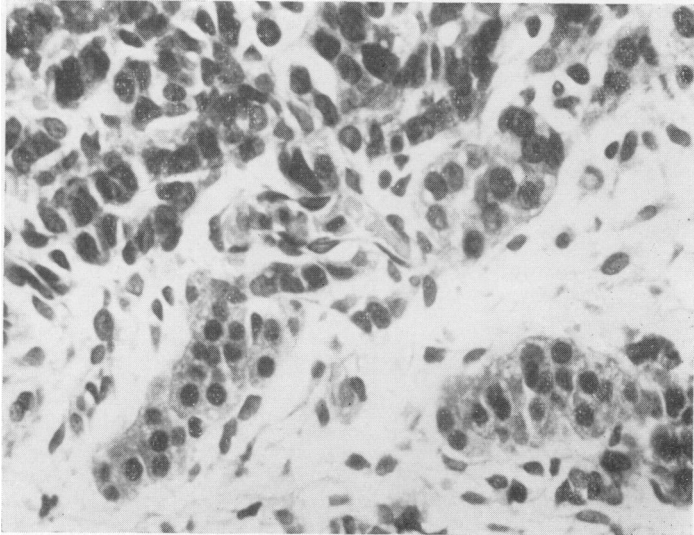


Fig. 8. Case 6. Malignant granulosa-cells at top, trabecular hilus-cell differentiation at bottom. H. and E.  $\times 100$ .

## PURE AND MIXED HILUS-CELL TUMOURS OF OVARY

solid, right-sided ovarian tumour was removed measuring 22 × 12 cm. Six years later she was reported to be in good health and developing normally.

*Microscopical examination* (R2048). The tumour consists mainly of moderately sized, pleomorphic cells with predominantly vesicular but sometimes hyperchromatic nuclei which vary in size. Numbers of abnormal mitotic figures are discernible. Some tumour cells contain eosinophilic, P.A.S.-positive globules. The cellular areas are supported by acellular oedematous connective tissue, and patchy cystic degeneration is a feature. In most parts the tumour cells form compact masses, but in others the neoplasm is of a thin-trabecular pattern and here, frequently distributed along the trabecular margins, are strands composed of cells of hilus-cell type with small, round, somewhat hyperchromatic nuclei and eosinophilic, granular or foamy cytoplasm (Fig. 8). These do not display any mitotic figures. The material is not suitable for the determination of the nuclear sex.

*Diagnosis.* Malignant granulosa-cell tumour with hilus-cell differentiation associated with virilization.

## DISCUSSION

Hilus-cell tumours of ovary are rare tumours. No figures for their incidence are quoted in the literature, but my own material of the past 20 years comprises 135 primary ovarian carcinomas, 1 dysgerminoma, 83 benign solid ovarian growths (granulosa-cell tumours, thecomas, luteomas, adenofibromas, fibromas, leiomyomas and eight Brenner tumours), and one of the pure and one of the mixed granulosa/hilus-cell tumours just described.

Boivin and Richart (1965) collected 33 previously reported cases from the literature to which they added three of their own. The ages of the patients reviewed varied from 4 to 86 years, an increased incidence being noted after the menopause. Masculinization was present in 80 per cent of the cases. Seven patients did not show any virilizing signs and in three of these endometrial hyperplasia was observed, accompanied in one case by adenocarcinoma. In one case a hilus-cell tumour was associated with a pseudomucinous cystadenoma, and in another with a Brenner tumour. Dougherty *et al.* (1958) reported a granulosa- and a hilus-cell tumour occurring in one ovary as two separate neoplasms.

Hilus-cell tumours are well circumscribed, soft, non-encapsulated brownish masses, varying in size from 1 to 9 cm., the majority measuring less than 5 cm. in diameter. Microscopically they present as sheets of typical liver-like hilus-cells which are supported by a moderately coarse reticulin framework and are well supplied with capillaries.

All hilus-cell tumours recorded so far have been benign. Stewart and Woodard (1962) reported a growth which they regarded as the first malignant hilus-cell tumour observed. But their diagnosis was, probably correctly, rejected by Gore, Scully and Hertig (addendum in reprint of Boivin and Richart, 1965), who regarded it as a tumour of the granulosa-theca type.

Seventeen ketosteroid excretion patterns, similar to those of Leydig-cell tumours, have been inconsistent, but the hormonal aspect will be discussed later in more detail.

### **Differential diagnosis**

It may be very difficult, in the absence of Reinke's crystalloids, to distinguish hilus-cells from thecal, luteal and adrenal cells.

The cells of the newly formed theca interna investing the periphery of a young corpus luteum bear a striking resemblance to hilus-cells. Although this similarity diminishes in time so that, for example, the cells of a persisting theca-cell ring around a corpus luteum tend to present darker pyknotic nuclei and deeply staining eosinophil cytoplasm, it is evident that when dealing with isolated or small groups of such cells, as seen in diffuse hilus-cell hyperplasia in solid or cystic ovaries (Alexander and Beresford, 1953), the differential diagnosis from theca-cells may be impossible.

On the other hand the cytoplasm of lipid-laden hilus-cells may appear foamy or vacuolated, so that they may be mistaken for luteal or adrenal cells.

Adrenal rest tumours have been invariably reported as encapsulated, of an organoid structure and of a bright yellow colour. The steroids secreted will be of adrenal type and they will respond to specific hormonal stimulation and depression like other cortical adrenal tumours (Segaloff *et al.*, 1955; Epstein *et al.*, 1957; Merrill, 1959, Case 2; Teter *et al.*, 1961). It should be remembered that they are very rare.

Luteomas may also produce virilization (Novak and Wallis, 1937; Rottino and McGrath, 1939; Lees and Paine, 1958; Merrill, 1959, Case 3). They are likewise encapsulated, may be large, are yellow or orange in colour and, although their cells may resemble adrenal cortical cells, luteomas present as solid, uniform growths and lack any trabecular, "organoid" structure. Transitions between identifiable theca and luteal cells may be demonstrable. In general luteomas tend to occur before the menopause, and ovarian adrenal cortical tumours in older women (Lees and Paine, 1958).

Although the presence of Reinke's crystalloids is diagnostic for both Leydig- and hilus-cell tumours, their absence does not invalidate the diagnosis. These specific inclusions have been found only in from 6 per cent (Merrill, 1959) to 25 per cent (Dixon and Moore, 1952) of Leydig-cell tumours, and in about 44 per cent of hilus-cell tumours (Boivin and Richart, 1965).

It should also be remembered that, as already mentioned, Reinke's crystalloids do not occur in animal species other than man. Yet Leydig-cell tumours arise in various domestic animals, especially in dogs, and these are histologically typical in spite of the absence of intracytoplasmic crystalloids.

**Mixed granulosa/hilus-cell tumours**

In rare instances ovarian tumours may be composed of both granulosa- and hilus-cells. Since granulosa-cells usually secrete oestrogens, and hilus-cells androgens, these mixed tumours have been called "gynandroblastomas".

This concept is based on the view that ovarian cells normally produce oestrogens, and that hence androgen-producing ovarian cells must be of male origin, or at least "male-directed" (Teilum, 1949, 1951, 1958)—a rather mystic and incomprehensible term. Such an assumption is quite unwarranted. Not only have normal and neoplastic hilus-cells been shown to possess female sex chromatin (Sohval and Gaines, 1955; Dougherty *et al.*, 1958; Krone and Kübler, 1961; Teter *et al.*, 1961), but both oestrogens and androgens are normally secreted in both sexes by the adrenal cortex, and as yet it has not been found necessary to stipulate the presence of "female"- or "male"-directed adrenal cortical cells to explain this property. Thus the term "gynandroblastoma" should be discarded.

Since the specificity of hilus-cells was not recognized until 1922 (Berger), and since the first hilus-cell tumour was reported as recently as 1942 (Berger), it is evident that unrecognized examples of mixed granulosa/hilus-cell tumours must have been present amongst the heterogeneous collection of previously published "arrhenoblastomas". Some of these were traced. Thus Bell (1915) recorded a beautifully illustrated case with virilization in a girl of 19 and stressed that the large eosinophilic interstitial-cells of the ovarian tumour "resembled exactly the interstitial-cells of the testicle". Novak and Long (1933) depict another example, and Schiller (1935/36) records virilization in a 17-year-old-girl by such a mixed tumour. Further cases were reported by Mechler and Black (1943), Härb (1953), Morris and Scully (1958) and Emig *et al.* (1959). Willis (1960) briefly mentions others. A mixed granulosa/hilus-cell tumour reported by Scully (1953a) was associated with hyperoestrinism and early endometrial adenocarcinoma.

Other tissue elements may occur occasionally alongside hilus- and granulosa-cell tumours. Thus tubules of pseudomucinous type were observed by Bergstrand (1934, Case 4); Benecke (1935); Hughesdon and Fraser (1953); Pope and Yoon (1958, Case 1); Ross *et al.* (1959) and Krone and Kübler (1961) noted these in a case of mixed malignant granulosa-cell tumour with hilus-cell differentiation. Boivin and Richart (1965, Case 2) recorded a Brenner next to a hilus-cell tumour, and Solomons and Dockerty (1940) noted cartilage in a malignant granulosa-cell tumour; Hughesdon and Fraser mention, in addition to cartilage, bone, adipose tissue, and smooth and striated muscle as occurring at times in granulosa-cell tumours.

The presence of such varying tissue elements alongside hilus- and granulosa-cell tumours must be ascribed to a process of metaplasia. Other

mesenchymal tissues, and the stroma of different tumours, may produce metaplastic cartilage, bone, etc. (Willis, 1958). They are not teratomatous since the predominating tumour tissues, hilus-cell, granulosa-cell and Brenner tumour, and pseudomucinous acini and tubules, are all of ovarian origin. The explanation of such tumour combinations must be sought in divergent differentiation from the common parent tissue, the ovarian parenchyma (Hughesdon and Fraser, 1953; Mackinley, 1957; Merrill, 1959; Willis, 1958 and 1960), which is known to give rise to other well-known tumour combinations, such as, for example, Brenner tumours and pseudomucinous cystadenomas.

### **Arrhenoblastomas**

The term "arrhenoblastoma", signifying a male tumour of ovary, was coined by Meyer (1930, 1931), who described cases of virilization due to ovarian neoplasms. He did emphasize that, on the one hand, granulosa-cell tumours could show tubular differentiation and, on the other, that the tubules he had observed in "arrhenoblastomas" were quite unlike seminal tubules. He and all later investigators were unanimous that virilizing ovarian tumours were of a varying and inconsistent histological pattern. Thus the term "arrhenoblastoma" is merely a synonym for a virilizing ovarian tumour or, as Willis (1960) has put it, it denotes function and not histogenesis.

Teilum (1949, 1951, 1958) has endeavoured to popularize his view of the homology of feminizing and virilizing gonadal tumours in both sexes. Although admitting that 70 per cent of so-called "arrhenoblastomas" display female sex chromatin, he regards all virilizing granulosa-cell tumours and luteomas as "androblastomas", derived from Sertoli cells, and under his influence in every respect typical granulosa-cell tumours, with evidence of oestrogen secretion and originally diagnosed as such, have been relabelled "Sertoli-cell tumours" or "oestrogen-producing androblastomas" (v. Numers and Gylling, 1953). To most workers this concept of "male-directed ovarian cells", which are of female nuclear type and usually secrete oestrogens, appears confusing and ill-founded.

Schiller (1953) maintains that it is possible to differentiate granulosa-cell tumours from trabecular "arrhenoblastomas" by histological minutiae, a view which was rightly rejected by Hughesdon and Fraser (1953).

There have been many recorded examples of virilizing granulosa-cell tumours, thecomas and luteomas, yet virilizing granulosa-cell tumours, in particular, have often been labelled "arrhenoblastomas", especially when tubular differentiation was evident, in spite of the fact that several investigators (Meyer, 1930, 1931; Mackinley, 1957; Novak and Novak, 1958; Willis, 1960) have accepted this feature as an, albeit infrequent, histological variant. Indeed numbers of illustrations, purporting to show typical examples of granulosa-cell tumours and "arrhenoblastomas" are interchangeable (for example Novak and Novak, 1958, figs. 473, 475 and

477 and figs. 495, 501–503). But, quite apart from the morphological dissimilarity of testicular tubules and those of granulosa-cell tumours, the endocrinologically active cell of the testicular tubules is the Sertoli-cell, and this is universally accepted as a source of testicular oestrogen. Virilizing Sertoli-cell tumours are unknown. Although the human Sertoli-cell tumour, the tubular adenoma, is hormonally inactive, canine Sertoli-cell tumours produce marked feminization. Thus the concept of testicular differentiation in virilizing ovarian tumours should be regarded as erroneous.

Willis (1960) has summarized the position regarding virilizing ovarian tumours most succinctly. He distinguishes four different types. The granulosa-theca-luteoma group; the hilus-cell tumours; tumours representing a combination of these two types; and finally the rare tumours arising in an ovarian-mesovarian adrenal cortical rest. Willis also emphasizes that all true ovarian tumours arise from a common parent tissue, the ovarian parenchyma.

Earlier investigators had been unable to explain why the one group of "arrhenoblastomas" which most resembled testicular tubules, the adenoma tubulare testiculare ovarii (Pick), did not produce virilization (for example Javert and Finn, 1951, Case 3). Intensive recent research into the problem of pseudohermaphroditism has shown that many, if not all, of these tumours arise in cases of gonadal dysgenesis in chromosomal males (Willis, 1959), and that hence the tubular type of "arrhenoblastoma" is not an ovarian tumour at all, but a testicular tubular adenoma—a true Sertoli-cell tumour.

It may be briefly mentioned here that ovarian virilization need not be caused by a single tumour mass, but that this syndrome may be due to hilus- or theca-luteal cells scattered as individual cells or lying in small groups throughout the ovarian substance (Simard, 1942; Simard and Simard, 1944; Sternberg, 1949; Siganos, 1961, Case 2; Hawkins and Lawrence, 1965). Similarly, diffuse luteal infiltration of the stroma of a pseudomucinous cystadenoma (Bettinger and Jacobs, 1946), in metastatic ovarian carcinoma (Scully and Richardson, 1961; Ober *et al.*, 1962), and diffuse hilus-cell hyperplasia in a metastatic ovarian carcinoma (Schuldenfrei *et al.*, 1961) have been observed to cause virilization. Conversely, Fox (1965) has shown that luteal cells in the stroma of some serous cystadenomata are the source of secretion of oestrogens.

### **Hormonal activity**

Both Leydig- and hilus-cells, as stated already, are practically absent from the sixth month of foetal life to puberty. This suggests a dependency on gonadotropic pituitary hormones, an assumption which has been shown to be correct.

Intrinsic chorionic gonadotropins secreted during pregnancy and in cases of chorionepitheliomas cause hyperplasia and hypertrophy of hilus-

cells (Brannan, 1927; Sternberg *et al.*, 1953; Schuldenfrei *et al.*, 1961), and their extrinsic administration is followed by Leydig-cell (Maddock and Nelson, 1952) and hilus-cell hyperplasia (Sternberg *et al.*, 1953) (Table I).

In the normal body gonadal oestrogen secretion constitutes a feed-back mechanism whereby secretion of gonadotropic hormones by the pituitary is inhibited. In the absence of gonadal oestrogens there will be continuous secretion of pituitary gonadotropins, resulting in Leydig- or hilus-cell hyperplasia. This mechanism explains the interstitial-cell hyperplasia found in atrophic testes due to cryptorchism and other causes (Dalgaard and Hesselberg, 1957), in the gonadal dysgenesis syndromes (Gordan *et al.*, 1955; Greenblatt *et al.*, 1956; Epps *et al.*, 1958) and in cases of testicular feminization (McMillan, 1966).

TABLE I  
EVIDENCE OF HORMONAL ACTIVITY OF LEYDIG AND HILUS CELLS

	<i>Leydig cells</i>	<i>Hilus cells</i>
Developmental cycle	absent from birth to puberty	absent from birth to puberty
Gonadotrophic stimulation	(a) intrinsic —	hyperplasia in pregnancy and chorionepithelioma
Hyperplasia due to absence of pituitary inhibition by gonadal oestrogen secretion	(b) extrinsic hyperplasia atrophic testis (cryptorchids, etc.) Klinefelter syndrome	hyperplasia Turner's syndrome
Androgenic effects of tumours (or hyperplasia)	precocious puberty	postmenopausal (endometrial carcinoma)
Oestrogenic effects of tumours (or hyperplasia)	gynaecomastia, loss of libido, impotence, aspermia	masculinization of patient masculinization of female foetus postmenopausal endometrial hyperplasia, polypi, carcinoma
	feminization in dogs	cornification of vaginal smears

Sherman and Woolf (1959) observed hilus-cell hyperplasia and a high level of pituitary gonadotropins (the luteinizing hormone in the female) in a high proportion of cases of endometrial carcinomas, and regard this as a consequential chain.

But tumour formation provides the most impressive evidence of the endocrine nature of the gonadal interstitial-cells in both sexes.

Leydig- as well as hilus-cells have long been regarded as a source of gonadal androgens. This view is supported by the observation that Leydig-cell tumours produce precocious puberty in male children, and hilus-cell tumours produce virilization in the female. In Brentnall's (1945) case a virilizing hilus-cell tumour coincided with pregnancy, resulting in masculinization of the female child, a hormonal effect analogous to that which produces freemartins in cattle. Removal of such endocrine neoplasms is followed by complete or, more often, by partial regression of symptoms.

However, certain observations are at variance with such a tidy scheme. Thus Leydig-cell tumours in adult males frequently cause feminization, and gynaecomastia has also been noted in the occasional prepubertal case (Bishop *et al.*, 1960). Marked feminization was noted in a canine Leydig-cell tumour (Kahan, 1955), and a similar case was observed by Laufer and Sulman (1956), who demonstrated high oestrogen levels in urine and tumour.

Similarly, hyperplasia or tumours of hilus-cells have been shown to have caused postmenopausal hyperoestrinism as evidenced by endometrial hyperplasia, polypi and carcinoma, and a high cornification index of vaginal smears (Husslein, 1948, 1951; Scully, 1953*a* and *b*; Plate, 1957; Goodwin *et al.*, 1962). In Plate's case there were high pre-operative levels of urinary oestrogens, which dropped to normal after removal of the growth.

These paradoxical endocrine effects stimulated further hormonal research. The chief source of androgen is the adrenal gland. In hyperplasia or tumour of the adrenal cortex the excretion of 17-ketosteroids is very markedly raised, which can be further increased by the administration of ACTH (Merrill, 1959, Case 2), and may be suppressed by cortisone (Segaloff *et al.*, 1955). Hilus- and Leydig-cell tumours do not respond to these hormones, but a very significant rise in 17-ketosteroid excretion may be obtained in such cases after stimulation with chorionic gonadotropins (Teter *et al.*, 1961). In many cases of hilus-cell tumours urinary 17-ketosteroid values have been within normal limits, although there is frequently a small but definite post-operative decrease, suggesting that gonadal androgens, although contributing but a fraction of the total ketosteroid excretion, are of high potency, a theory which has lately been found to be correct (Finkelstein *et al.*, 1961; Forchielli *et al.*, 1963).

However, there remained the paradoxical oestrogenic effect of gonadal interstitial-cell tumours, some of which have been shown to be associated with greatly raised urinary oestrogen levels (Eisenstadt and Petry, 1957; Herrmann *et al.*, 1958). According to Segal and Nelson (1959) Leydig-cells normally produce both androgens and oestrogens. In ageing men they found a distortion of the ratio of oestrogen and androgen production, with oestrogenic function being retained preferentially. If these observations are correct this would explain why in younger individuals androgenic and in older men oestrogenic effects are more noticeable, and provide a ready explanation for those cases showing symptoms of overproduction of both types of hormone.

In the female this "ambivalent" hormonal phenomenon does not depend on age. As already mentioned, a minority of hilus-cell tumours show evidence of hyperoestrinism (Husslein, 1948/49 and 1951; Klees and Müller, 1950; Scully, 1953*a* and *b*; Goodwin *et al.*, 1962), whilst a minority of the granulosa-theca-luteoma group cause virilization. The explanation of these diametrically opposed hormonal effects of the same tumour must be sought in an intracellular enzyme dysfunction.

Progesterone is the precursor of androgens, and androgens are the precursors of oestrogens. This chain of conversion of one hormone to another may be halted at any given point if the necessary enzyme system is lacking (Thompson and King, 1964). We are ignorant of the factors which induce such enzymatic disturbances in man, but it is interesting to recall that Hill (1937*a* and *b*) succeeded in inducing experimentally transplanted



ovarian tissue to secrete androgens instead of oestrogens by lowering the environmental temperature.

A similar blockage of steroid conversion will transform a tumour of the granulosa group from an oestrogenic into a virilizing neoplasm, and an occasionally observed ancillary progesterone type of reaction (Amati, 1932; Scully and Richardson, 1961; Ober *et al.*, 1962) will have to be ascribed to a partial, still earlier blockage of the chain.

Conversely, an accelerated enzymatic conversion of androgens to oestrogens will result in oestrogen-secreting Leydig- and hilus-cell tumours.

### Conclusions

The six hilus-cell tumours reported illustrate the full range of the potentialities of this tumour. Two of them were of the more common pure type of hilus-cell tumour. They were small, soft, non-encapsulated, brown in colour and histologically of identical appearance. Yet one had caused virilization whereas the second was associated with hyperoestrinism.

TABLE II  
PERCENTAGE OF SEX CHROMATIN IN VARIOUS OVARIAN AND TESTICULAR TUMOURS

Case No.	Age	Histological diagnosis	Symptoms	Hilus cells	Granulosa cells	Others
1	44	Pure hilus cell tumour	Virilization	22	—	—
2	79	Pure hilus cell tumour	Hyperoestrinism	30	—	—
3	48	Mixed granulosa-hilus cell tumour	Virilization	28	38	—
4	about 24	Mixed granulosa-hilus cell tumour	Virilization	45	47	—
5	65	Mixed granulosa-hilus cell tumour	Hyperoestrinism	45	24	—
For comparison	?	Leydig-cell hyperplasia	none (cryptorchid)	—	—	0
For comparison	35	Leydig-cell hyperplasia	none (cryptorchid)	—	—	0
For comparison	12	Canine Leydig-cell tumour	none	—	—	2
For comparison	10	Canine Leydig-cell tumour	none	—	—	0
For comparison	10	Bilateral tubular adenoma	none (prepuberty)	—	—	2
For comparison	40	Multiple tubular adenoma	none (cryptorchid)	—	—	0
For comparison	35	Microscopic tubular adenoma	none (cryptorchid)	—	—	0

One of the three mixed granulosa/hilus-cell tumours was large and yellow in colour. The two others were macroscopically not unlike the tumours of pure type. Two of the three were masculinizing, the third provided evidence of hyperoestrinism.

The single malignant granulosa-cell tumour with hilus-cell differentiation had also caused virilization. Incidentally, its microscopical features are very similar to the "arrhenoblastoma" depicted in Figure 499 by Novak and Novak (1958).

Removal of the virilizing tumour, in the three cases where follow-up information is available, resulted in regression of symptoms. One of these, the malignant growth (Case 6), has now been observed for six years, and the adolescent patient is reported to be developing normally. The two patients with tumours associated with hyperoestrinism had no general subjective complaints, but an early endometrial carcinoma was present in one. The patients' ages ranged from 13 to 79 years. Nuclear sexing demonstrated the presence of female sex chromatin in the five tumours in which this examination was possible (Table II).

The combination of granulosa- and hilus-cells in one tumour is rare. Schiller (1953) has stated that hilus-cells are not present in oestrogen-

## PURE AND MIXED HILUS-CELL TUMOURS OF OVARY

producing granulosa-cell tumours, and this has been confirmed in a personal series of 13 cases. But Schiller's view that mixed granulosa/hilus-cell tumours, which he calls "arrhenoblastomas", are only seen in cases of virilization is certainly incorrect, as evidenced by Case 5 of this paper, which showed definite evidence of hyperoestrinism.

Finally, it should be remembered that hilus-cell tumours, like any other potentially hormone-secreting neoplasm, may be endocrinologically inactive, and may be found only incidentally (Simard, 1942, Case 2; Pope and Yoon, 1958, Case 2; Boivin and Richart, 1965, Case 2).

### SUMMARY

Two pure and three mixed granulosa/hilus-cell tumours, and one malignant tumour of mixed type are reported.

Four cases showed evidence of virilization, and two of hyperoestrinism. An early endometrial carcinoma was present in one of these. Their ages ranged from 13 to 79 years. Postoperative regression of symptoms was noted in three of the virilizing tumours. Nuclear sexing of the five tumours which were suitable for this examination showed the presence of female sex chromatin.

The clinical, morphological and hormonal aspects of hilus-cell tumours are discussed together with those of the Leydig-cell tumour, their male counterpart.

On naked-eye examination hilus-cell tumours are small, brown and non-encapsulated, features which may be helpful in diagnosis. Reinke's crystalloids were demonstrated in only one case, but their presence is not essential for diagnosis. The "ambisexual" hormonal properties of the growths are thought to be due to a disturbance of the normal sequence of steroid conversion, resulting in an overproduction of either androgens or oestrogens.

The cases described provide further evidence that there is no histological entity which can be covered by the term "arrhenoblastoma".

### ACKNOWLEDGEMENTS

I am greatly indebted for clinical information and gift of material to Dr. A. F. Burry (Case 3), Dr. T. K. Owen (Case 2), Mr. P. N. Simons (Cases 1 and 5) and Professor R. A. Willis (Cases 4 and 6). My Chief Technician, Mr. W. M. Seymour, was responsible for the technical and photographic work.

### REFERENCES

- ALEXANDER, W. S., and BERESFORD, O. D. (1953) *J. Obstet. Gynec. Brit. Emp.* **60**, 252.  
AMATI, G. (1932) *Arch. Ist. biochim. ital.* **4**. (Abstract in *Gynec. et Obstét.* (1933) **28**, 634.)  
BELL, W. B. (1915) *Proc. Roy. Soc. Med.* **8**, Obst. and Gynaec. Section p. 77.  
BENECKE, E. (1935) *Virchows Arch.* **294**, 38.  
BERGER, L. (1922) *C.R. Acad. Sci.* **175**, 498.  
——— (1942) *Rev. canad. Biol.* **1**, 539.  
——— (1945) *Tr. Roy. Soc. Can.* (Sect. V, Biol. Sc.) **39**, 23.

- BERGSTRAND, H. (1933/34) *Acta obstet. gynec. scand.* **13**, 336.
- BETTINGER, H. F., and JACOBS, H. (1946) *Med. J. Aust.* **1**, 10.
- BISHOP, P. M. F., VAN MEURS, D. P., WILLCOX, D. R. C., and ARNOLD, D. (1960) *Brit. med. J.* **1**, 238.
- BOIVIN, Y., and RICHART, R. M. (1965) *Cancer* (Philad.) **18**, 231.
- BRANNAN, D. (1927) *Amer. J. Path.* **3**, 343.
- BRENTNALL, C. P. (1945) *J. Obstet. Gynaec. Brit. Emp.* **52**, 235.
- COLLINS, D. H., and PUGH, R. C. B. (1964) *The Pathology of Testicular Tumours*, Edinburgh, Livingstone, pp. 2 and 6-7.
- COTCHIN, E. (1965) Personal communication.
- DALGAARD, J. B., and HESSELBERG, F. (1957) *Acta path. microbiol. scand.* **41**, 219.
- DIXON, F. J., and MOORE, R. A. (1952) Tumors of the male sex organs, in *Atlas of Tumor Pathology*, Armed Forces Institute of Pathology, Washington D.C., fascicle 32, 104-120.
- DOUGHERTY, C. M., THOMPSON, W. B., and MCCALL, M. L. (1958) *Amer. J. Obstet. Gynec.* **76**, 653.
- EISENSTADT, H. B., and PETRY, J. L. (1957) *J. Urol.* **78**, 428.
- EMIG, O. R., HERTIG, A. T., and ROWE, F. J. (1959) *Obstet. and Gynec.* **13**, 135.
- EPDS, D. R., GUERIOS, M. F. M., NETO, A. DA S. C., LEON, N., DE ASSIS, L. M., and CINTRA, A. B. DE W. (1958) *J. clin. Endocrin.* **18**, 892.
- EPSTEIN, JEANNE A., LEVINSON, C. J., and KUPPERMAN, H. S. (1957) *Amer. J. Obstet. Gynec.* **74**, 982.
- FINKELSTEIN, M., FORCHIELLI, E., and DORFMAN, R. I. (1961) *J. clin. Endocrin.* **21**, 98.
- FORCHIELLI, E., SORCINI, G., NIGHTINGALE, M. S., BRUST, N., DORFMAN, R. I., PERLOFF, W. H., and JACOBSON, G. (1963) *Anal. Biochem.* **5**, 416.
- FOX, H. (1965) *Cancer* (Philad.) **18**, 1041.
- GOODWIN, J. W., EHLMANN, R. L., and LEAVITT, T. (1962) *Obstet. and Gynec.* **19**, 467.
- GORDAN, G. S., OVERSTREET, E. W., TRAUT, H. F., and WINCH, G. A. (1955) *J. clin. Endocrin.* **15**, 1.
- GREENBLATT, R. B., CARMONA, N., and HIGDON, L. (1956) *J. clin. Endocrin.* **16**, 235.
- HÄRB, H. (1953) *Frankfurt. Z. Path.* **64**, 491.
- HAWKINS, D. F., and LAWRENCE, D. M. (1965) *J. Obstet. Gynaec. Brit. Com.* **72**, 285.
- HERRMANN, W. L., BUCKNER, F., and BASKIN, A. (1958) *J. clin. Endocrin.* **18**, 834.
- HILL, R. T. (1937a) *Endocrinology*, **21**, 495.
- (1937b) *Endocrinology*, **21**, 633.
- HUGHESDON, P. E., and FRASER, I. F. (1953) *Acta obstet. gynec. scand.* **32**, Suppl. 4.
- HUSSLEIN, H. (1948/49) *Z. Geburtsh. Gynäk.* **130**, 32.
- (1951) *Zbl. Gynäk.* **73**, 1649.
- JAVERT, C. T., and FINN, W. F. (1951) *Cancer* (Philad.) **4**, 60.
- KAHAN, I. H. (1955) *J. Amer. vet. med. Ass.* **122**, 471.
- KLEES, E., and MÜLLER, H. G. (1950) *Geburts. u. Frauenheilk.* **10**, 446.
- KOHN, A. (1928) *Endokrinologie*, **1**, 3.
- KRONE, H. A., and KÜBLER, W. (1961) *Arch. Gynäk.* **196**, 35.
- LAUFER, A., and SULMAN, F. G. (1956) *J. clin. Endocrin.* **16**, 1151.
- LEES, D. H., and PAINE, C. G. (1958) *J. Obstet. Gynaec. Brit. Emp.* **65**, 710.
- LOUBET, R., and LOUBET, A. (1961) *Ann. Anat. path.* (Paris) **6**, 189.
- MACKINLEY, C. J. (1957) *J. Obstet. Gynaec. Brit. Emp.* **64**, 512.
- MCMILLAN, MARY (1966) *J. Path. Bact.* **91**, 417.
- MADDOCK, W. O., and NELSON, W. O. (1952) *J. clin. Endocrin.* **12**, 985.
- MECHLER, E. A., and BLACK, W. C. (1943) *Amer. J. Path.* **19**, 633.
- MERRILL, J. A. (1959) *Amer. J. Obstet. Gynec.* **78**, 1258.
- MEYER, R. (1930) *Zbl. Gynäk.* **54**, 2374.
- (1931) *Amer. J. Obstet. Gynec.* **22**, 697.
- MORRIS, J. M., and SCULLY, R. E. (1958) *Endocrine Pathology of the Ovary*, St. Louis: Mosby, pp. 82-96.
- NOVAK, E., and LONG, J. H. (1933) *J. Amer. med. Ass.* **101**, 1057.
- and NOVAK, E. R. (1958) *Gynecologic and Obstetric Pathology*, 4th edit. Philadelphia, Saunders.
- NOVAK, J., and WALLIS, O. (1937) *Arch. Gynäk.* **164**, 543.
- v. NUMERS, C., and GYLLING, T. (1953) *Ann. Chir. Gynaec. Fenn.* **42**, 161.
- OBER, W. B., POLAK, ANN, GERSTMANN, K. E., and KUPPERMAN, H. S. (1962) *Amer. J. Obstet. Gynec.* **84**, 739.

## PURE AND MIXED HILUS-CELL TUMOURS OF OVARY

- PLATE, W. P. (1957) *Acta Endocrinol.* **26**, 489.
- POPE, R. H., and YOON, D. S. (1958) *Conn. med. J.* **22**, 91.
- ROSS, J. W., WEINBERGER, M. A., and DESBORDES, L. A. (1959) *Amer. J. Obstet. Gynec.* **77**, 188.
- ROTTINO, A., and MCGRATH, J. F. (1939) *Arch. intern. Med.* **63**, 686.
- SCHILLER, W. (1935/36) *Arch. Gynäk.* **160**, 344.
- (1953) in *Pathology*, edited by W. A. D. Anderson, 2nd edit. London, Kimpton, p. 1056.
- SCHULDENFREI, R., JANOVSKI, N. A., and OBER, W. B. (1961) *Amer. J. Obstet. Gynec.* **82**, 1186.
- SCULLY, R. E. (1953a) *J. clin. Endocrin.* **13**, 1254.
- (1953b) *Amer. J. Obstet. Gynec.* **65**, 1248.
- and COHEN, R. B. (1961) *Cancer (Philad.)* **14**, 421.
- and RICHARDSON, G. S. (1961) *Cancer (Philad.)* **14**, 827.
- SEGAL, S. J., and NELSON, W. O. (1959) in *Recent Progress in the Endocrinology of Reproduction*, edited by C. W. Lloyd. New York and London, Academic Press, p. 107.
- SEGALOFF, A., GORDON, D., HORWITT, B. N., and WEED, J. C. (1955) *J. clin. Endocrin.* **15**, 142.
- SHAW, W., and DASTUR, B. (1949) *Brit. med. J.*, **2**, 113.
- SHERMAN, A. I., and WOOLF, R. B. (1959) *Amer. J. Obstet. Gynec.* **77**, 233.
- SIGANOS, E. C. (1961) *J. Obstet. Gynaec. Brit. Com.* **68**, 979.
- SIMARD, L. C. (1942) *Rev. canad. Biol.* **1**, 572.
- and SIMARD, R. (1944) *Rev. canad. Biol.* **3**, 388.
- SOHVAL, A. R., and GAINES, J. A. (1955) *Cancer (Philad.)* **8**, 896.
- SOLOMONS, B., and DOCKERTY, G. C. (1940) *J. Obstet. Gynaec. Brit. Emp.* **47**, 451.
- STERNBERG, W. H. (1949) *Amer. J. Path.* **25**, 493.
- SEGALOFF, A., and GASKILL, C. J. (1953) *J. clin. Endocrin.* **13**, 139.
- STEWART, R. S., and WOODARD, D. E. (1962) *Arch. Path.* **73**, 91.
- TEILUM, G. (1949) *J. clin. Endocrin.* **9**, 301.
- (1951) in *Recent Advances in Clinical Pathology*, edited by S. C. Dyke. London, Churchill, p. 484.
- (1958) *Cancer (Philad.)* **11**, 769.
- TETER, J., NADWORNÝ, J., ZACHWIEJ, E., and BARTOSZEWICZ, W. (1961) *J. Obstet. Gynaec. Brit. Com.* **63**, 451.
- THOMPSON, R. H. S., and KING, E. (1964) *Biochemical Disorders in Human Disease*, 2nd edit. London, Churchill, p. 957.
- WALDEYER, W. (1872) *Arch. path. Anat.* **55**, 133.
- WILLIS, R. A. (1958) *The Borderland of Embryology and Pathology*. London, Butterworth, p. 536.
- (1959) in *Modern Trends in Pathology*, edited by D. H. Collins. London, Butterworth, p. 122.
- (1960) *Pathology of Tumours*, 3rd edit. London, Butterworth, p. 502.
- ZONDEK, LILY H., and ZONDEK, T. (1965) *Biol. Neonat.* **8**, 1.

---

## THE BRITISH CLUB FOR SURGERY OF THE HAND

THE BRITISH CLUB for Surgery of the Hand will hold an Instructional Course in Hand Surgery at the London Hospital on Friday, 17th November 1967, from 9.30 a.m. to 5 p.m.

The Programme will consist of Lectures, Films and Demonstrations in the technical aspects of Examination, Diagnosis and Treatment in Hand Surgery.

Further particulars may be obtained from the Honorary Secretary, Mr. H. Graham Stack, F.R.C.S., Westhay, Mount Avenue, Hutton, Essex.