

G. R. Viviani

Scoliosis Screening and Treatment

SUMMARY

Scoliosis—a spinal curve of 5° or more, with a rotational deformity—may be present in up to 4% of patients aged 12-14. However, only about 0.3% require treatment, for progressive curves of 20° or more. About 70% of all scoliosis in North America is idiopathic. Non-idiopathic varieties include congenital and neuromuscular scoliosis, mesenchymal disorders, non-structural scoliosis, juvenile kyphosis and Scheuermann's disease. A clinical evaluation for early detection of scoliosis need take only a few seconds during an office visit. Treatment can include periodic check-ups and X-rays, exercises, braces, electrical stimulation and surgery. Scoliosis associated with other conditions can be discovered in patients of any age, and recognition early is important for proper treatment. (Can Fam Physician 1985; 31:529-533).

SOMMAIRE

Quatre pourcent des patients âgés de 12-14 ans peuvent présenter une scoliose — courbure lombaire de 5° ou plus, avec une difformité rotatoire. Cependant, seulement environ 0.3% requièrent un traitement, c'est-à-dire les cas de courbures progressives de 20° ou plus. En Amérique du Nord, environ 70% de toutes les scoliose sont idiopathiques. Les variétés non-idiopathiques incluent la scoliose congénitale et neuromusculaire, les désordres mésenchymateux, la scoliose non-structurale, la cyphose juvénile et la maladie de Scheuermann. L'évaluation clinique pour le dépistage précoce de la scoliose ne nécessite que quelques secondes supplémentaires lors d'une visite au bureau. Le traitement peut inclure des examens et des radiographies périodiques, des exercices, des attelles, la stimulation électrique et la chirurgie. La scoliose, associée à d'autres conditions, peut se manifester chez des patients de tout âge, et il est important de l'identifier tôt si on veut la traiter efficacement.

Key words: Scoliosis, screening, spine.

Dr. Viviani is an associate professor of orthopedic surgery at McMaster University. Reprint requests to: Department of Surgery, McMaster University Medical Centre, 1200 Main Street West, Hamilton, ON. L8N 3Z5.

SCOLIOSIS—lateral curvature of the spine—was described by Hippocrates, who recognized that there are many varieties of spinal curvature, even in people who are in good health. Over treatment is a potential problem in our quest to provide the best possible care. Further, Hippocrates' description of many *varieties* of curvature points out the complexity of problems that have been conveniently described by the word 'scoliosis'.

Prevalence

Prevalence studies have been based on chest X-rays taken for tuberculosis

screening, or on data from school scoliosis screening programs. Shands and Eisberg¹ reviewed 40,000 chest mini films, and noticed scoliosis of 10° or more in 1.9% of the patients over 14. Scoliosis over 20° was observed in 0.5%. The ratio was 3.5 females to one male. Data available from school screening programs are often not comparable, because the criteria for the screening process or X-rays were not similar. Rogala et al.'s Montreal study² demonstrated a 4% incidence of scoliosis in students aged 12-14. Scoliosis was defined as a curve of 5° or more, with a rotational deformity. Only about 0.3% required treatment—that is, they had progressive curves of 20° or more. Similar figures have been found throughout North America and Europe. Although mild curves are almost as common in boys as in girls, progression is five times more likely in girls. The most common form of idio-

pathic scoliosis is the adolescent type, which starts after age ten and before adolescence. This type of curvature is most commonly found during school screening programs.

Natural History

The progression of curves coincides with growth spurts. The earlier the age of onset, the more severe is the progression. Some studies have shown an average progression, from the onset of puberty to the end of growth, of as much as 15° per year.³ Studies have now been published to help predict the progression of small curves.⁴

The longterm natural history of this condition after adolescence is not well known. There are not enough longterm data for a rigorous statistical analysis of the several variables involved. Data available from longterm studies are controversial. Especially unpredictable is the progression of curves be-

tween 30°-60° at the end of adolescence. If a curve has already reached 60° by early adulthood, it is very likely to be progressive, causing pulmonary function impairment, high mortality after age 45, disability with back pain and severe cosmetic and psychological problems. Probably the natural history of most curves under 40° is benign, as Moe et al. suggested.⁴

Diagnosis and Evaluation

Idiopathic scoliosis

The majority of all scoliosis seen in North America is idiopathic. Subdivisions, depending on the age of onset, are infantile, beginning before age three, juvenile, age three to ten, and adolescent, age ten until maturity.

By far the most common is the adolescent variety. Most infantile curves are self-resolving, even if not treated. The juvenile variety is an earlier and more severe type of scoliosis than the common adolescent variety. Adolescent scoliosis increases rapidly during growth spurts. Idiopathic scoliosis appears to have a significant genetic component, is more common in certain families and in females.

Non-idiopathic Scoliosis

Congenital scoliosis

This variety is probably not genetic, and includes deformities caused by malformations of the vertebrae. Quite often, these are associated with other congenital malformations in the urinary tract, cardiovascular system or spinal cord. There are many anatomical variations; the 'open type' includes spina bifida. Various types of severe spinal curvatures are associated with myelomeningocele. The 'closed type' of congenital malformations may or may not produce significant spinal deformity. They include wedge vertebrae, hemi-vertebrae, congenital bars and block vertebrae. These malformations are caused by 'failure of formation' of vertebral elements or by 'failure of segmentation'. The prognosis for each malformation is quite often extremely difficult to predict. Each congenital scoliosis patient needs careful, individualized assessment and prolonged follow-up. Congenital curves require aggressive treatment, possibly surgical, as soon as they show a tendency to progress. Fortunately, many congenital spinal malformations are not progressive and quite often

they are only incidental radiological findings.

Neuromuscular scoliosis

Neuromuscular scoliosis can be subdivided into neuropathic and myopathic forms. The neuropathic group includes lower motor neuron diseases such as poliomyelitis and spinal muscular atrophy. The upper motor neuron diseases include cerebral palsy. The myopathic form includes all the progressive disorders related to primary muscle diseases (e.g., muscular dystrophy). For this type of disorder, the present trend is early treatment with extensive spinal fusion to provide a more comfortable sitting position. Most cases of neuromuscular scoliosis are quickly and severely progressive, with significant associated respiratory insufficiency. Recent advances in surgical techniques, particularly Luque segmental spinal instrumentation, provide a more satisfactory procedure to improve the quality of life for these severely disabled patients. Grotesque deformities are no longer inevitable for these patients.

Mesenchymal disorders

This group includes disorders such as Marfan's syndrome, mucopolysaccharidosis, osteogenesis imperfecta and juvenile rheumatoid arthritis. These conditions are frequently associated with severe scoliosis. Neurofibromatosis with typical café-au-lait skin spots warn that a severe curve may occur.

Other causes

These include traumatic spinal injuries, spinal tumors, thoracic surgery, spinal radiation in childhood, senile osteoporosis and vertebral collapse.

Non-structural scoliosis

This term refers to transient curves, usually due to muscle spasm, as seen in sciatic pain or inflammatory conditions affecting the spine or muscles surrounding it. A common cause of mild non-structural scoliosis is leg length discrepancy.

Juvenile kyphosis and Scheuermann's disease

Kyphosis can be a very significant deformity and quite often it is not recognized. Non-structural kyphosis or round back is common in adolescents

and pre-adolescents, due to poor posture. More severe forms are frequently due to structural changes in the vertebrae, associated with Scheuermann's disease. This is a developmental and possibly genetic condition, in which the vertebral discs and end-plates of the vertebral bodies are abnormal during the growth period, producing vertebral anterior collapse with wedge-shaped deformities. Severe kyphosis cannot be corrected later in life without major surgical procedures, which can be considered in severe cases. Treatment with a brace is effective in early adolescence.

Clinical Evaluation

Up to 4% of your patients may have scoliosis!⁴ Evaluation of these patients may seem complex, but need not be so. The same routine that permits a trained school nurse to assess several children in a few minutes can be followed by physicians in their offices. A few seconds for physical examination of the back will permit an early diagnosis. This may not have been taught in medical school!

The examination starts with the physician sitting behind the undressed patient (see Fig. 1). A girl may wear a gown, while a boy should be in his underpants. Note the height of the shoulders, the contour of the flanks, and the prominence of the iliac crests. The waistline and the hanging arms form a triangle that can be compared on both sides.

The line of the spinous processes can be followed visually and by palpation. The patient should bend forward with completely relaxed arms. The profile of the posterior chest wall should be noted for any obvious rib hump or bulge. This 'forward-bending test' is the most significant finding. Repeat this process from the front. Then the child should be examined from the side as he or she bends forward; kyphotic deformities may become more evident in this position. Round back deformities due to posture or associated Scheuermann's disease are not uncommon, and they should be diagnosed in the early stages and treated to prevent permanent deformities. Also, all patients with severe neuromuscular diseases should be watched for spinal deformities.

The height or level of the iliac crest should be observed, because leg length inequalities are not uncommon and

mild scoliotic deviations of the lumbar spine may result from them. Some other musculoskeletal problems are obvious during this examination also.

The patient will not notice a painless spinal deformity until quite late. It is extremely important that physicians examine the back in routine check-ups, especially when this examination will be most likely to detect significant changes. The most common type of scoliosis is the idiopathic adolescent variety, which can usually be detected during the early growth spurt. Typically, this happens in grades seven to nine, between ages ten and 14.

Adult Scoliosis

Scoliosis in adults is frequently associated with complaints of back pain, respiratory restriction or concerns about appearance. Unfortunately, in patients with advanced respiratory impairment it is usually too late to treat the scoliosis itself, although a specialized treatment directed to the respiratory condition may be helpful. The physician must respect patients' concern about their appearance, and encourage them to express any worries. Frequently, a middle-aged patient in whom the curve has gradually become noticeable will not admit that appearance is the most important concern, but rather visit the physician complaining of pain. An appropriate consultation should still be obtained, even if the patient's major concern is appear-

ance, and frequently this can be improved with surgery. When pain is the major problem associated with scoliosis, appropriate treatment usually is available. Treatment for back pain, associated with mild curves, is identical to that for patients without scoliosis. When there are severe curves or specific root compression problems, surgical treatment can be very beneficial.

Role of X-Rays

Special X-rays are necessary to assess spine deformities. To assess a curvature in degrees and compare findings with those in the literature, the X-rays must be taken with the patient standing. A three foot cassette is needed to include the whole spine. This should be taken with minimum radiation, to protect spine, breasts and gonads. Special techniques are available to minimize radiation.⁵ In most instances, only two X-rays are necessary—one in AP and one lateral. If a specific treatment is indicated, more specialized X-rays may be necessary and will be ordered by the orthopedic surgeon. Unfortunately, it is still common for scoliosis patients to be sent for routine views of the thoracic spine and/or the lumbar spine. These films require a significant amount of radiation and do not permit measurement of curvatures. Measurements are commonly taken with the Cobb method, which takes the angle between the two most tilted vertebrae (see Fig. 2). Variations of less than 5° are usually

not significant. An easily detected curve is usually over 20°.

Treatment

Observation

Periodic check-ups and X-rays are indicated for growing adolescents with curvatures below 20°. During the adolescent growth spurt, the curvature can change faster and follow-ups should be done every three to four months. When growth decreases, the follow-ups can be spaced at six month intervals. Length of follow-up after growth ends remains controversial. The rate of further deterioration is rather unpredictable and, in any case, rather slow. Consequently, a biannual check-up is probably ideal until the pattern of the curvature is determined. Radiation should be minimal; usually only one film is necessary.

Exercises

Exercises alone have not been proven to change the natural course of

Fig. 1.
Diagram of back examination.

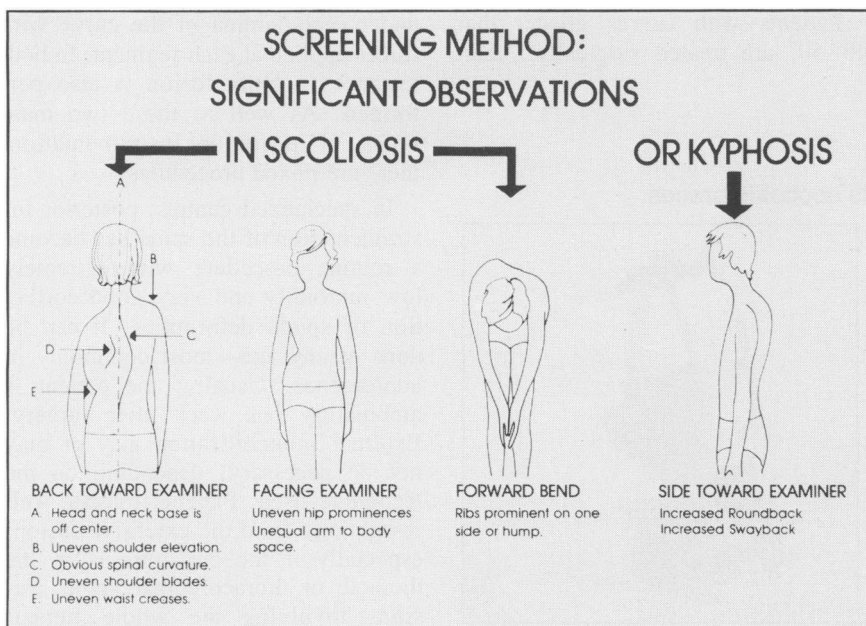
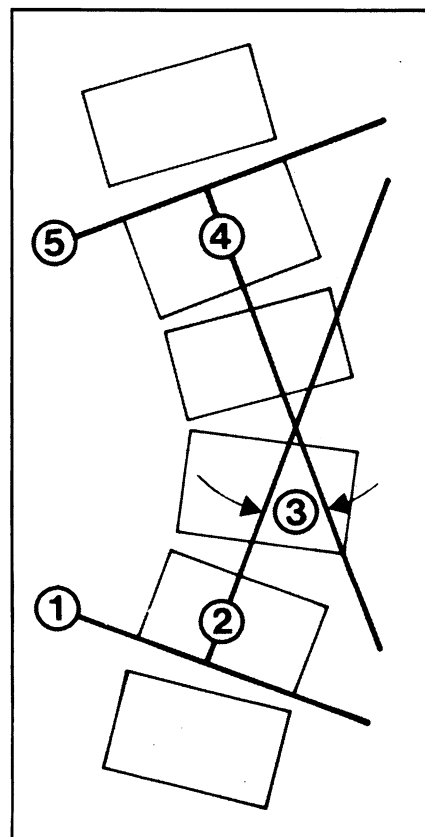


Fig. 2.
Cobb method to measure X-ray scoliosis angle. The Cobb angle is shown in number 3. In this case, the curve is approximately 40°.



scoliosis. Exercise may, however, help to preserve adequate muscle strength when an immobilizing brace is used, or to complement the brace's corrective action. Exercises can be symmetrical, to strengthen all different muscles involved in spinal movements, or asymmetrical to unbend the spine and aid correction. Occasionally traction can be used.

Braces

Since Hippocrates' time, braces have been used to treat spinal deformities. Today, the Blount or Milwaukee brace has been internationally accepted as the standard of treatment (see Fig. 3). This consists of a pelvic structure that has three vertical bars joined to a collar piece, with a small chin and occipital support. Lateral floating pads attached to the vertical bars are applied to the convexity of the curvatures. This brace is custom-made and periodically adjusted for growth and changes in the curves. It requires specialized skills for manufacture and to control its adjustments. The brace is indicated for growing adolescents' progressive curves over 20°. Usually, the treatment goal is to arrest curve progression. Consequently, the brace is generally not indicated when the curve is severe enough to be unsatisfactory in the longterm. The usual, acceptable upper limit is 40° in a curve that is still flexible.

An adolescent may have to wear a brace for one to four years, depending on the growth pattern and curvature response. There are also other types of braces: the thoraco-lumbar-sacral orthosis (TLSO), is a custom built or pre-fabricated modular plastic jacket with

built-in corrective pressure areas on the spine. Its main advantage is cosmetic, as it does not need visible metallic bars or a neck collar. However, it can be used only for curves with an apex below the lower thoracic spine.

Braces are initially worn for 20-22 hours a day, allowing the patient to practice sports or other activities during the remaining hours. The time off the brace is gradually increased at the end of growth. This 'weaning' phase may last one to two years.

Electrical stimulation

Since Dr. Bobechko⁶ at Toronto's Hospital For Sick Children started using implanted electrodes in 1976, electrical stimulation has gradually become more accepted. Recently, the United States Federal Drug Administration approved the use of a cutaneous electrical device for treating scoliosis. A North American multicentre study⁷ showed that the results of the electrical cutaneous device are very similar to bracing. The system consists of two or four electrodes, placed in the back in sites determined by the curvatures. The electrodes have to be placed every night by some one other than the patient. They are connected to an electrical stimulator about the size of a pocket radio, that works with batteries and gives periodic and adjustable electrical impulses, to contract the muscles on the convex side of the curve. Skin tolerance problems are common, and the treatment requires specialized supervision.

Surgical treatment

Patients with curves greater than 40°-50° are treated surgically. There

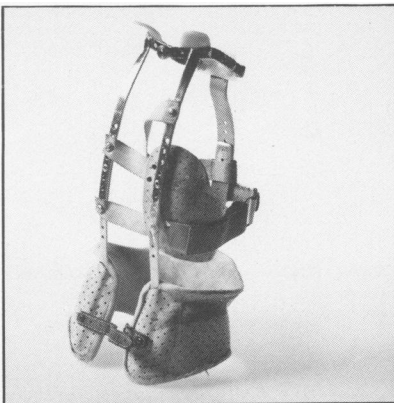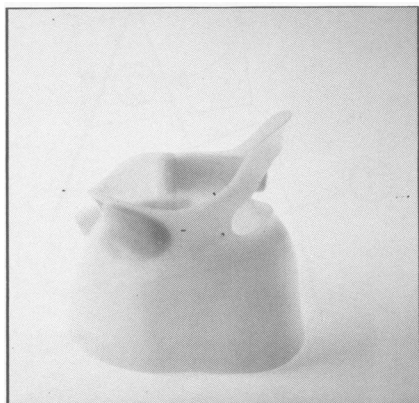
are many surgical treatments for scoliosis. Internal fixation instruments must be used to correct and stabilize the spine. Bone graft is then necessary to fuse the treated area. Consequently, all fusions require a postoperative period of special care and limitations in the patient's activities until the bony fusion is solid. This usually takes about six months. Instrumentation can be divided into anterior spinal and posterior spinal instrumentation. In anterior spinal instrumentation, the surgeon approaches the vertebral bodies through the thorax or abdominal cavity, applying internal fixation devices to the vertebral bodies, and removing several discs in order to fuse the disc spaces with bone graft.

With posterior instrumentation, the surgeon approaches the spine from behind, using the spinous processes, lamina, and transverse processes to fix the instruments. The bone graft is usually taken from the iliac crest. Posterior spinal instrumentation is far more common today.

Posterior instrumentation can be further divided into two types. Dr. Harrington⁸ developed the distraction system about 1960. It consists of a rod with two hooks—one in the most proximal and the other in the most distal vertebra of the curvature. These are hooked onto the lamina, and the rod is built in such a way that the distance between the hooks can be gradually increased until there is adequate tension for correction. The second modality is segmental spinal instrumentation, a recent introduction. Two rods are tied up with multiple wires, which are passed under each lamina of the curve with forces applied at each segment. In both instances a bony fusion is also performed. As well as these two main types of posterior instrumentation, there are mixed procedures.

In specialized centres, posterior instrumentation of the spine has become a routine procedure with extremely low morbidity and very good correction of spinal deformities. It can be done at any age—most commonly in adolescence. Usually, the patient is ambulatory one week after surgery. External immobilization may or may not be necessary, depending on the technique used. Patients tolerate well restrictions from the extensive fusion, especially if the curvature is in the thoracic or thoracolumbar spine. Fusions involving the whole lumbar

Fig. 3.
Examples of Milwaukee and low profile scoliosis braces.



spine are likely to cause functional problems and consequently have a more limited indication. Satisfactory cosmetic corrections can be obtained and pain related to the scoliosis can also be improved. Respiratory restrictions are unlikely to be changed by surgery, and so it should be considered a preventive measure.

Discussion

The etiology of idiopathic scoliosis remains unknown. A recent theory⁹ suggests that the lateral curvature may be initiated by an abnormal alignment in the sagittal plane, with lordosis in an area that usually should have some degree of kyphosis. This could be due to a developmental structural weakness in the disc and related structures, perhaps similar to Scheuermann's condition. Associated rotational changes during growth eventually cause the lateral curvature or scoliosis. Three-dimensional computer analysis of X-rays taken in different planes, combined with computer graphics, are providing new insights into the natural course of scoliosis.⁹ However, we are still unable to predict accurately if a particular patient has a progressive or static deformity.

The varied presentation and slow but significant progression in an adult makes it extremely difficult to obtain reliable information on the natural history and morbidity of idiopathic scoliosis. There are still gaps in the data needed to assess treatment.

The relationship between spinal deformity and pulmonary function remains controversial.¹⁰ Although advances have been made in surgical treatment, braces, and electrical stimulation, treatment modalities remain difficult and not always satisfactory. The ideal would be to obtain normal spinal alignment and mobility. This is not obtained with present treatment techniques. A secondary goal, such as improving impaired pulmonary function in advanced scoliosis, is probably not possible, even though surgical fusion can significantly improve spinal alignment.

Two other important issues associated with scoliosis are pain and deformity. Deformity can usually be significantly improved with braces when the curve is treated in adolescence or with surgery at any age. Unfortunately, this is only an improvement and never a return to normal. Pain associated with scoliosis can be significantly relieved with proper treatment. Physicians often don't realize that this is a benefit of treatment. For example, in middle-aged or older patients, a spinal deformity may contribute to disabling back pain. Surgery can often significantly relieve this pain. Conversely, a common misconception is that scoliosis causes back pain in teenagers or young people; the real source of the pain can be missed.

The school screening programs for early detection of scoliosis remain controversial.¹¹ In Canada, there seems to be a trend away from this type of public health program. In 1981, 24 of Ontario's 43 health care units had screening programs. Approximately 95,000 children were screened per year. Some programs have since been discontinued. Probably a major reason for this is the Canadian Task Force Report on the Periodic Health Examination, which concluded that "there is poor evidence regarding the inclusion of the condition in the periodic health examination and recommendations may be made on other grounds."¹² Also, several authors have questioned the validity and reliability of school screening methods,¹³ believing they may lead to excessive radiation, unnecessary psychological stress, over-treatment and high cost. In spite of this, screening is compulsory in several U.S. states and there is evidence¹⁴ that it may significantly reduce the need for surgery, as many children receive early conservative treatment.

Conclusion

The high risk patient is usually a girl in early adolescence who has a curvature of around 20° and a positive family history of scoliosis.¹⁵ This is a

golden opportunity for favorable, conservative treatment that will prevent a significant spinal deformity in later life.

Scoliosis associated with other conditions can be discovered at any age from early childhood to adulthood. Recognizing this deformity before it is too advanced is extremely important for proper treatment. ●

References

1. Shands AR Jr, Eisberg HB. The incidence of scoliosis in the state of Delaware. A study of 50,000 minifilms of the chest made during a survey for tuberculosis. *J Bone Joint Surg* 1955; 37A:1243-9.
2. Rogala EJ, Drummond DS, Gurr J. Scoliosis: incidence and natural history. *J Bone Joint Surg* 1978; 60A:173-6.
3. Moe JH, Winter RB, Bradford DS, Lonstein JE. *Scoliosis and other spinal deformities*. Philadelphia: W. B. Saunders, 1978: 1-691.
4. Lonstein JE, Carson JM. The prediction of curve progression in untreated idiopathic scoliosis during growth. *J Bone Joint Surg* 1984; 66A:1061-71.
5. Gray JE, Hoffman AD, Peterson HA. Reduction of radiation exposure during scoliosis. *J Bone Joint Surg* 1983; 65A:5-12.
6. Bobechko WP, Herbert MA, Friedman HG. *Electrospinal instrumentation for scoliosis. Current status. Symposium on scoliosis and related spinal disorders*. *Orthop Clin North Am* 1979; 10:927-41.
7. Brown JC, Axelgaard J, Howson DC. Multicenter trial of a noninvasive stimulation method for idiopathic scoliosis. A summary of early treatment results. *Spine* 1984; 9:383-7.
8. Harrington PR. Correction and internal fixation by spine instrumentation. *J Bone Joint Surg* 1962; 42A:591-610.
9. Reuben JD, Brown RH, Nash CL, Jr, Brower EM. In vivo effects of axial loading on double-curve scoliotic spines. *Spine* 1982; 7:440-7.
10. Aaro S, Ohlund C. Scoliosis and pulmonary function. *Spine* 1984; 9:220-2.
11. Morris D. Screening for scoliosis. *Br Med J* 1984; 289:269-72.
12. Canadian Task Force on the Periodic Health Examination. Task force report. *Can Med Assoc J* 1979; 121:1193-1254.
13. Viviani GR, Budgell L, Dok C, Tugwell P. Assessment of accuracy of the scoliosis school screening examination. *Am J Public Health* 1984; 74:497-8.
14. Lonstein JE, Bjorklund S, Wanninger MH, Nelson RP. Voluntary school screening for scoliosis in Minnesota. *J Bone Joint Surg (Am)* 1982; 64A:481-8.
15. Viviani GR. Assessment and treatment of mild adolescent scoliosis. *Mod Med Can* 1981; 36:819-23.