

# THE USE OF THERMOGRAPHY IN SYMPATHETICALLY MAINTAINED PAIN

Morris S. Friedman, M.D.\*

## ABSTRACT

This paper reviews the symptomatology, pathophysiology, and treatment of reflex sympathetic dystrophy and sympathetically maintained pain. It is the author's experience that there exists a group of patients who present with chronic, unexplained pain following trauma, but lack the physical findings and positive investigative tests to confirm the diagnosis of reflex sympathetic dystrophy. For these patients, thermography serves as a useful and sensitive test to diagnosis sympathetically maintained pain. This paper presents six case reports in which thermography was used to diagnosis sympathetic dysfunction as the cause of chronic pain.

## INTRODUCTION

During the Civil War, in 1864, Mitchell, et al. observed that soldiers with battlefield nerve injuries sometimes developed persistent "burning" pain and progressive trophic changes in the injured extremity<sup>16</sup>. Mitchell named this disorder "causalgia," derived from the Greek term for "burning pain"<sup>17</sup>. In 1940, Homans used the term "moderate causalgia," and in 1945, DeTakats used "causalgic states" to describe neurologically mediated pain syndromes<sup>4,11</sup>. Since that time, terms, such as "major causalgia," "minor causalgia," "Sudek's atrophy," "sympathalgia," "post-traumatic dystrophy," and "shoulder-hand syndrome" have been used to describe the pain syndrome and the corresponding pathologic changes that occur in limbs following injuries. Evans was the first to use the term "reflex sympathetic dystrophy"<sup>7</sup>. Currently this is an all-inclusive term for a spectrum of syndromes that result from autonomic dysfunction.

The condition of reflex sympathetic dystrophy (RSD) may follow major or minor trauma. The condition is defined by the International Association for the Study of Pain as "continuous pain in a portion of an extremity after trauma, which may include fracture but does not involve a direct nerve injury, that is associated with sympathetic hyperactivity." The hallmark of RSD is chronic pain and swelling out of proportion to the injury or underlying process. The pain often localizes to the area of injury and with time may progress proximally to involve the entire

limb. The pain varies from a dull sensation to severe burning pain that frequently interferes with all activities including sleep.

Classically RSD presents as a spectrum of signs and symptoms which progresses through three stages. Each stage can last from weeks to months<sup>3,18,20</sup>. The first, or acute stage may begin days, weeks, or months after the injury. In the acute stage, the patient experiences a constant aching or burning pain, hyperalgesia, and hyperhidrosis. Pitting edema, hyperthermia or hypothermia, increased hair and nail growth, and associated color changes may be apparent in the involved extremity. Emotional changes can increase the intensity of the symptoms.

The second, or dystrophic stage begins about three to six months after the injury, and may last up to a year. This stage is characterized by severe continuous burning pain. Generally, the pain is more intense than in the acute stage. The edema becomes brawny and fixed. There is frequently hair loss and the nails develop grooves or ridges. There is wasting of the muscles and progressive stiffness of the joints. Radiographs often show early spotty periarticular osteoporosis which can later become polar or diffuse.

The third, or atrophic stage is characterized by irreversible, marked tissue changes. The hyperpathia may diminish or persist. As the swelling resolves, the skin becomes smooth, cool, tight, glossy, and either pale or cyanotic. There are fibrotic changes of the periarticular soft tissues and fascia which cause joint contractures. The fingers and toes appear fusiform and pointed due to atrophy of the palmar fat and beveling of the nails. The muscles of the extremity show marked wasting. Radiological studies in this stage show severe osteoporosis. Radionuclide scintigraphy demonstrates increased uptake.

## PATHOPHYSIOLOGY OF REFLEX SYMPATHETIC DYSTROPHY

Many theories have been proposed to explain the mechanism responsible for RSD. Livingston in 1943, proposed the theory that painful stimuli initiate "reverberating circuits in the spinal cord"<sup>14</sup>. Doupe, et al., proposed the theory that trauma or nerve injury causes the formation of artificial synapses or "cross stimulation" between sympathetic efferent fibers and somatic sensory afferent fibers, at the site of injury<sup>6,13</sup>. Recent studies in animal models have confirmed the existence of "cross stimulation" (ephapses) in injured nerves<sup>5</sup>. This cross-stimulation

---

\*Dr. Friedman is in private practice as an Orthopaedic Surgeon in South Bend, Indiana. He is a Board Certified Orthopaedic Surgeon, and a Fellow of the American Academy of Orthopaedic Surgery. He is also a member of the Academy of Neuro-Muscular Thermography and the American Academy of Pain Medicine.

between efferent sympathetic fibers and nociceptive afferent fibers is one way that the sympathetic nervous system may play a central role in the pathophysiology of RSD.

Roberts proposed that sympathetically maintained pain is the result of a "high rate of firing in the spinal wide-dynamic-range (WDR) or multi-receptive neurons<sup>19</sup>." Roberts postulated that pain syndromes, such as causalgia and RSD are mediated by activity in low-threshold, myelinated mechanoreceptors. He suggested that the actions of the sympathetic efferent on the afferent fibers evoke activity in the sensitized WDR neurons to produce a painful sensation. Roberts fostered the term "sympathetically maintained pain" to describe a painful condition associated with sympathetic dysfunction.

The majority of evidence in recent literature strongly supports the theory that the sympathetic nervous system plays a central role in the development of RSD and sympathetically maintained pain<sup>18,20,3</sup>.

### TREATMENT

Sympathetic blockade plays a key role in the diagnosis and treatment of RSD and sympathetically maintained pain. A favorable response to sympathetic blockade confirms the diagnosis of RSD<sup>3</sup>. Early diagnosis is essential as the treatment is most effective in the early stages. The results of treatment are less predictable in the later stages when structural changes are present.

Bonica has stated that if the diagnosis is correct, sympathetic blockade combined with vigorous physical therapy relieves the pain in 80% of patients<sup>3</sup>. The number of repeated sympathetic blocks to render effective treatment varies. Intravenous regional guanethidine and reserpine have also been successful in the treatment of patients with RSD. Several authors have reported up to 80% pain relief with intravenous guanethidine<sup>2,8</sup>.

In addition to sympathetic blockade, adjunctive therapy is important in the treatment of RSD and sympathetically maintained pain. Physical therapy, occupational therapy and transcutaneous electrical stimulation (TENS) have been beneficial<sup>20</sup>. Many patients with long-standing RSD and sympathetically maintained pain undergo emotional and psychological disturbances which require intense psychological support. For these patients, psychological support is of equal importance to the other treatment modalities.

### THERMOGRAPHY IN SYMPATHETICALLY MAINTAINED PAIN & REFLEX SYMPATHETIC DYSTROPHY

The diagnosis of RSD is easily made in patients who present with the classic signs and symptoms. However, many patients with chronic pain syndromes do not present in this fashion. In the author's practice, most of the

patients have few or no classic signs of RSD. It is in this group of patients that infrared electronic thermography is most helpful.

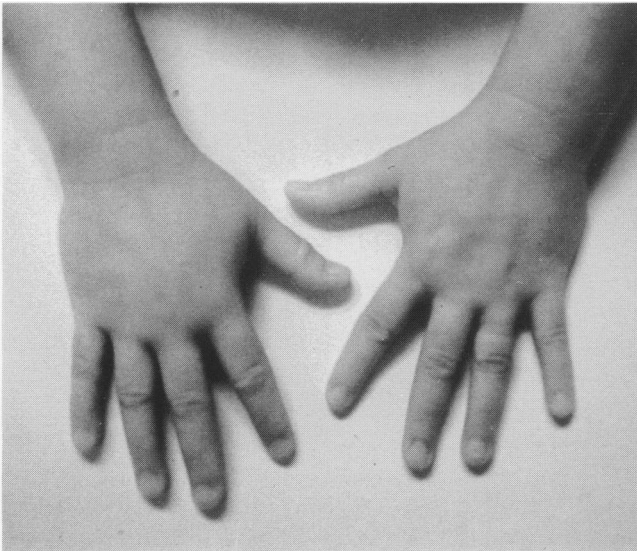
The sympathetic nervous system plays a critical role in the production of RSD and sympathetically maintained pain. The clinical manifestations of these syndromes reflect the dysfunction of the autonomic nervous system, which includes temperature regulation. Hypothermia and hyperthermia of the involved limb, as shown on thermography, provide evidence of sympathetic dysfunction. In a recent study, Bennett and Ochoa obtained infrared thermographic images on rats with experimentally induced nerve injuries<sup>1</sup>. These images were similar to those obtained in patients diagnosed with RSD.

Janig<sup>12</sup> classified reflex sympathetic dystrophy into three subgroups based on their clinical symptoms and physical findings: 1) "Sympathetic Algodystrophy" describes the syndrome in the group of patients who have all the signs and symptoms of RSD. 2) "Sympathetic Dystrophy" describes the syndrome in a group of patients who lack the typical burning pain, but have all the other symptoms of RSD. 3) "Sympathetic Maintained Pain" describes the syndrome in patients who have typical spontaneous pain and allodynia, but present no physical findings of RSD.

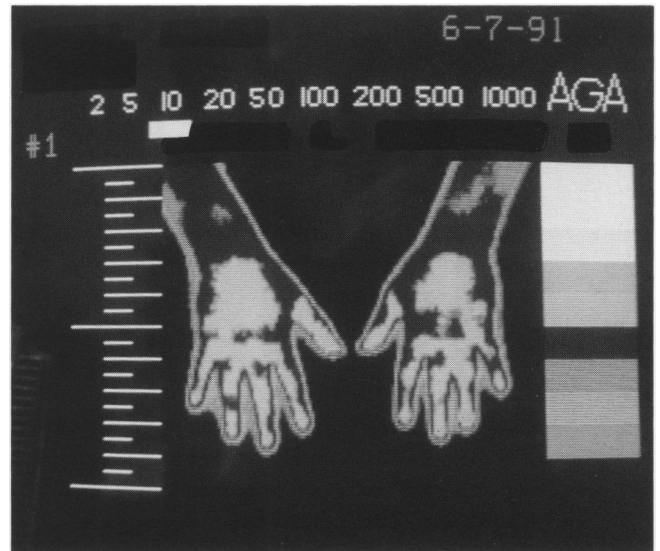
In patients with sympathetically maintained pain, the thermogram may be the only objective way to demonstrate an abnormality. Hendler has stated "at a minimum, diagnostic studies that would facilitate the diagnosis of RSD would be thermography and bone scintigraphy"<sup>10</sup>. I agree with Harden, who proposed that the term sympathetically maintained pain should be reserved for the situations in which autonomic abnormality is detected by thermograms alone, and the term reflex sympathetic dystrophy should be used for those cases with classic physical findings and investigational studies consistent with RSD<sup>9</sup>.

Since electronic thermography reflects sympathetic nerve activity, it is an excellent test for the detection of RSD and sympathetically maintained pain. Electronic thermography measures heat emission from the body surface. Thermography is highly sensitive and can detect sympathetic dysfunction even in the absence of clinical findings.

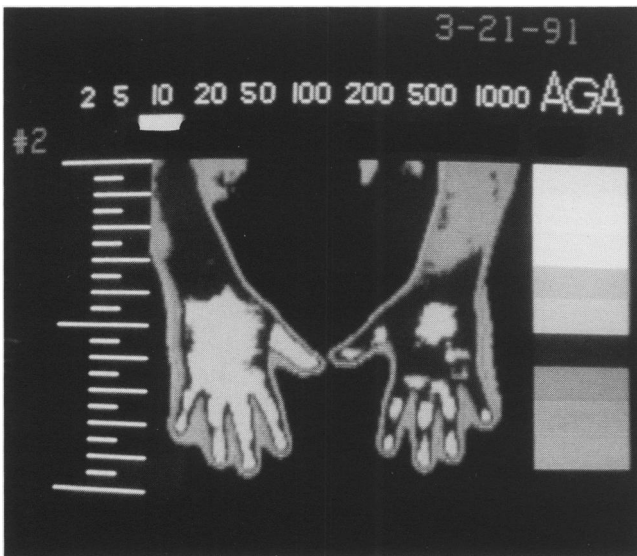
Electronic thermography has led to an increased interest and awareness in sympathetically maintained pain. In my practice, I rarely see patients who manifest all of the classic signs and symptoms of RSD. The majority of my patients who complain of chronic, unexplained pain in an extremity following a major or, more frequently, minor trauma, can be characterized as patients with sympathetically maintained pain, rather than RSD. It is in these patients that thermography has proven itself a sensitive test and useful diagnostic tool.



**Fig. 1-A**  
Photograph of swollen and discolored right hand.



**Fig. 1-C**  
Thermogram shows symmetry of heat emission of the right and left hands.



**Fig. 1-B**  
Thermogram shows relative increase in heat emission (hyperthermia) of the right hand.\*

## CASE PRESENTATIONS

### Case 1

S.T., a 37-year-old woman, injured her right hand while using a wrench to loosen a bolt. She was diagnosed as having acute de Quervain's tenosynovitis of the right wrist, and treated with a steroid injection and immobilization. Shortly after returning to work her right hand became painful, swollen, and discolored (Fig. 1-A). An electronic thermogram showed a relative increase in the heat emission of the right hand compared to the left, suggestive of sympathetically maintained pain (Fig. 1-B). Several weeks after discarding the splint and increasing the use of the hand, most of the pain and swelling had resolved. A follow-up electronic thermogram study showed symmetry of the heat emission between the right and left hands (Fig. 1-C).

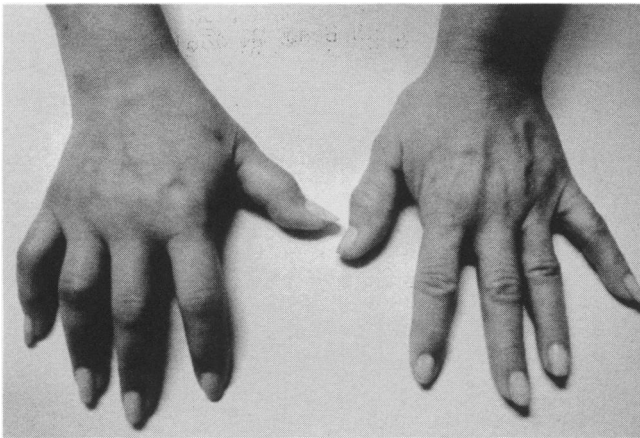


Fig. 2-A

Photograph of swollen and discolored right hand.

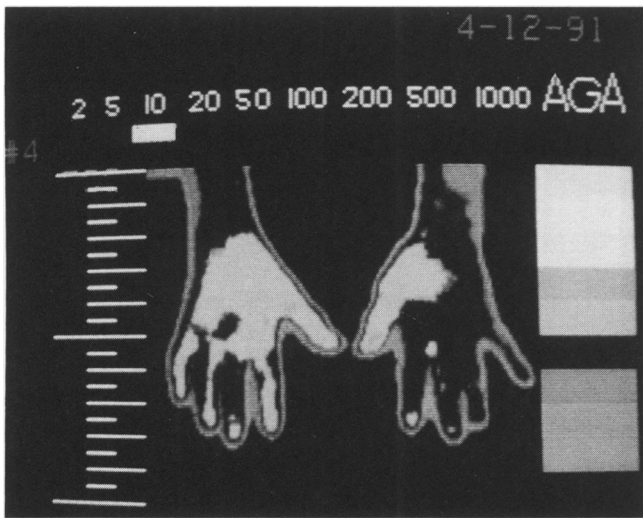


Fig. 2-B

Thermogram shows hyperthermia of dorsum of right wrist and hand.

### Case 2

P.M., a 46-year-old woman, injured her right hand when she slipped on a wet floor. A few days later she complained of pain and swelling of the right hand. The pain persisted despite immobilization and steroid injection. Four months later an EMG study showed evidence of a carpal tunnel syndrome and radiographs demonstrated CMC arthritis of her thumb. Five months after the injury, the patient underwent a carpal tunnel release and a CMC arthroplasty, which failed to relieve her symptoms. Several stellate ganglion blocks did not relieve her hand swelling and pain (Fig. 2-A). An electronic thermogram performed three months after the carpal tunnel release and CMC arthroplasty demonstrated increased heat emission in the right wrist and hand compared to the left, suggestive of sympathetically maintained pain (Fig. 2-B).

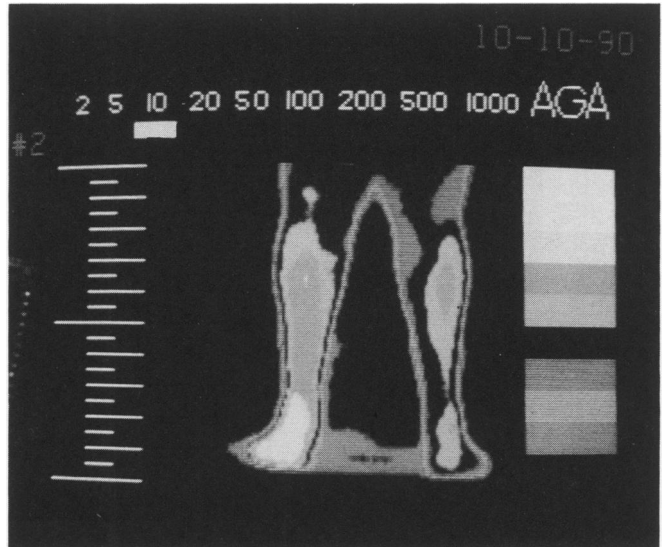


Fig. 3-A

Thermogram demonstrates hyperthermia of right leg.

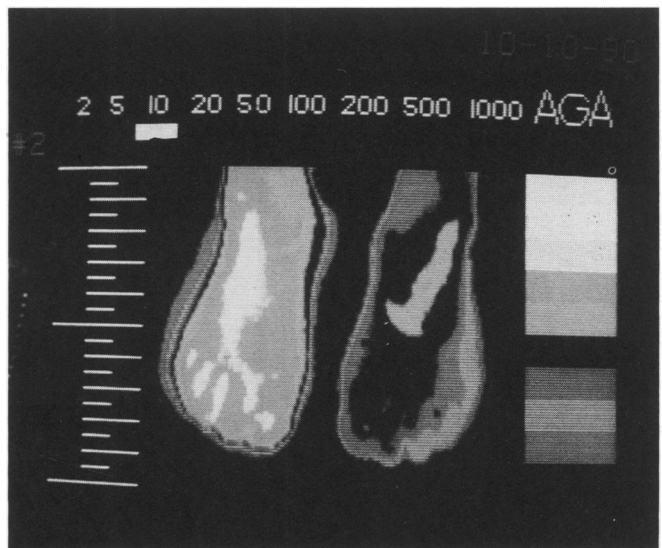
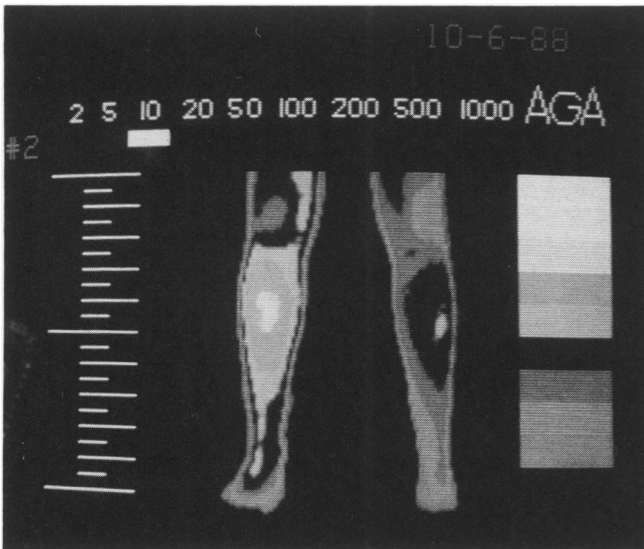


Fig. 3-B

Thermogram shows hyperthermia of right foot.

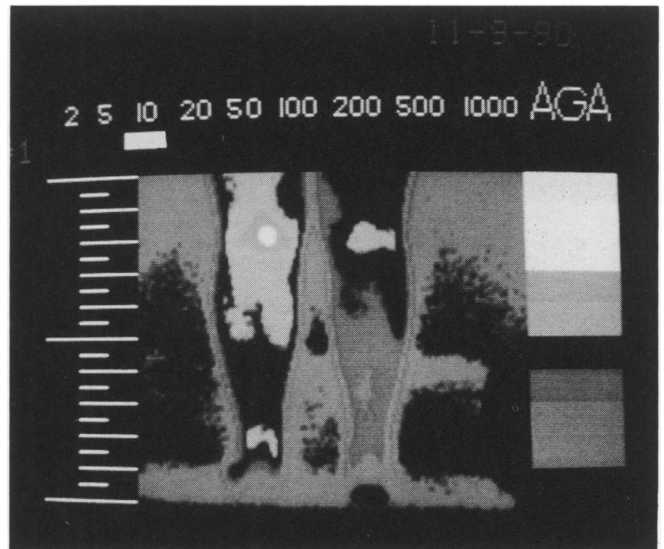
### Case 3

M.M., a 49-year-old woman, had an uncomplicated excision of an accessory tarsal navicular bone from her right foot. This was followed by immobilization of the right foot in a non-weight bearing cast for six weeks. After removal of the cast and progression to full weight bearing, the patient developed burning pain in the right foot and lower leg. An electronic thermogram three months after the surgery on her right foot showed a relative increase in the heat emission of the right leg and foot suggestive of a sympathetically maintained pain syndrome (Fig. 3-A & 3-B).



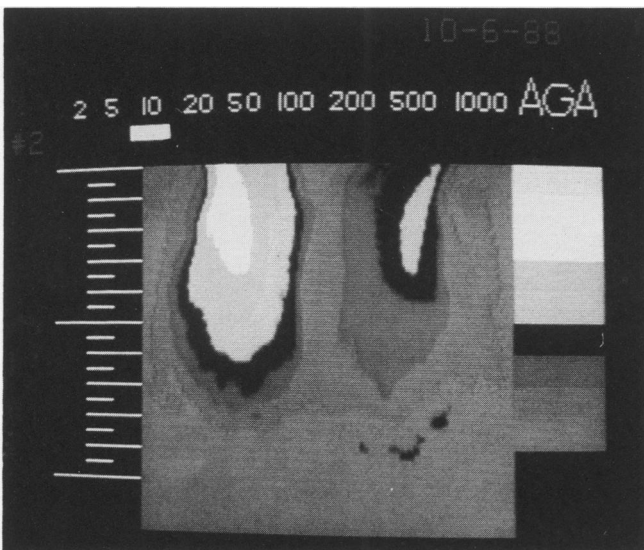
**Fig. 4-A**

Thermogram shows hypothermia of lower left leg.



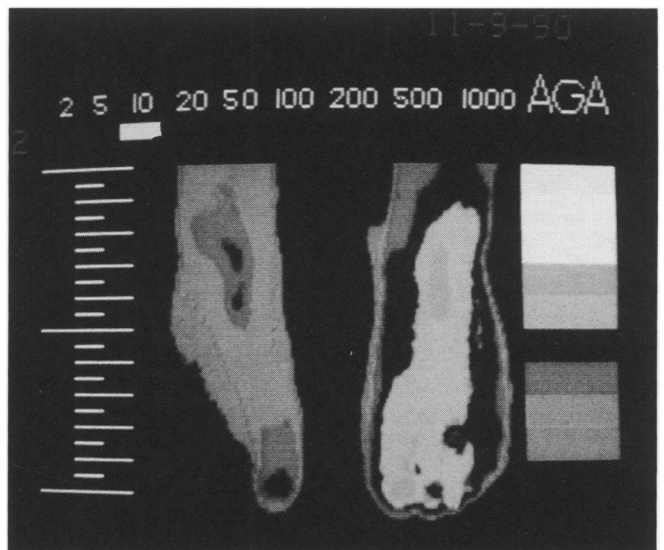
**Fig. 5-A**

Thermogram shows hypothermia of right posterior lower leg.



**Fig. 4-B**

Thermogram shows hypothermia of dorsum of left foot.



**Fig. 5-B**

Thermogram shows hypothermia of right foot.

#### **Case 4**

C.G., a 30-year-old man, twisted his left knee and sustained a nondisplaced fracture of the medial tibial plateau. His injury was treated with a period of non-weight bearing and immobilization. After several weeks, the patient complained of pain and a cold sensation in the left foot and leg. An electronic thermogram two months after the injury showed a global decrease in the heat emission of the left thigh, leg, and dorsal foot (Figs. 4-A and 4-B). This was suggestive of a sympathetically maintained pain syndrome of the left lower extremity.

#### **Case 5**

V.W., a 41-year-old woman, injured her right foot in an automobile accident. Two months after the accident, the patient complained of continued pain in the right ankle and foot. An electronic thermogram performed two months after the injury revealed a decrease in the heat emission of the right lower leg and foot (Figs. 5-A and 5-B). These findings were consistent with a sympathetically maintained pain syndrome of the right lower extremity. After a series of three lumbar sympathetic blocks, the pain in the right ankle and foot resolved. Two months later, the pain recurred. A second series of lumbar sympathetic blocks

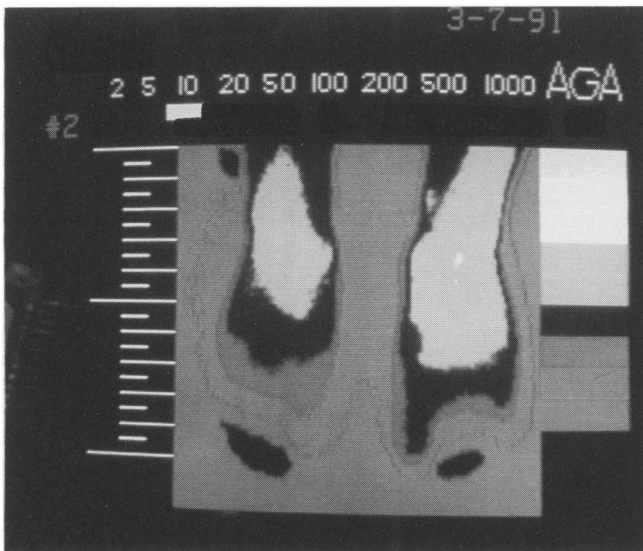


Fig. 5-C

Post-block thermogram show relative symmetry of vascular heat emission of the dorsal aspect of the right and left foot.

resulted in marked relief of the pain. A repeat electronic thermogram one month after the second series of blocks showed an increase in the heat emission of the right ankle and foot (Fig. 5-C). Thus, the repeat thermogram confirmed the clinical improvement following the second series of blocks.

### Case 6

B.G., a 45-year-old woman, complained of a constant burning pain on the dorsal and plantar surfaces of her left foot and over the lateral aspect of her left ankle. Walking one block exacerbated her pain and caused a purple discoloration in her left heel.

The patient reported that her left foot was injured in an automobile accident when her car was struck from the rear by another vehicle. At a local hospital, radiographs of the left ankle and foot showed no fractures. A splint was applied to the left foot and leg, and she was kept non-weight bearing. The splint was removed after four months and her weight bearing was advanced. She was treated with physical therapy for three months, and eventually released to go back to work as a truck driver. She could not resume this job because she was unable to push the clutch with her foot due to pain. An orthopaedic surgeon suspected RSD and requested a thermogram.

The electronic thermogram demonstrated a global decrease in the heat emission pattern of the left lower extremity from the upper posterior thigh to the plantar aspect of the left foot (Figs. 6-A and 6-B), consistent with RSD.

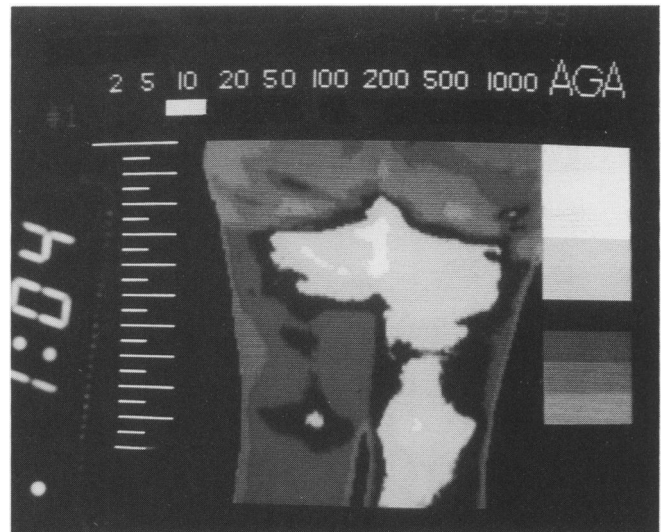


Fig. 6-A

Thermogram shows hypothermia of the posterior left thigh.

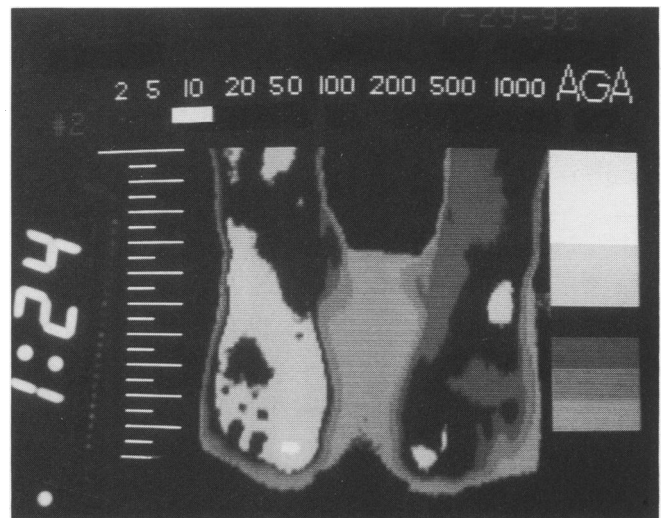


Fig. 6-B

Thermogram shows hypothermia of the dorsum of left ankle and left foot.

### SUMMARY

Reflex sympathetic dystrophy is a pain syndrome that is associated with a broad spectrum of physical findings caused by dysfunction of the sympathetic nervous system. Classic RSD has been divided into, acute, dystrophic, and atrophic stage based on the chronicity of the physical findings. Various theories have been proposed to explain the pathophysiology of RSD. It has been suggested that there are "reverberating circuits" in the spinal cord that are triggered by intense pain<sup>14</sup>. Another theory is the existence of ephapses (artificial synapses) or cross-stimulation between the sympathetic efferent and somatic sensory afferent fibers<sup>6</sup>. It has also been said that RSD is

caused by "a central nervous perturbation, which once established persists despite the subsequent removal of the cause"<sup>22</sup>.

Early diagnosis is crucial for successful treatment of RSD. Sympathetic blockade followed by intensive physical therapy often alleviates the pain and may prevent progression of the syndrome. Sympathetic ganglion blocks have been the cornerstone of the diagnosis and treatment<sup>3,18,20</sup>. The number of blocks necessary for satisfactory outcome varies, and must be individualized for each patient. The pharmacologic interruption of the function of the nerve fibers only lasts a few hours, but the benefit of interfering with the cycle may last for days before the symptoms return. Alternative treatments to ganglionic blockade include regional intravenous infusions (guanethidine, reserpine, and other agents), somatic sensory nerve blocks, sympathectomies, oral agents, and others. Common adjunctive therapy includes physical therapy, TENS, massage, and functional activities such as stress loading. Physical therapy should always accompany treatment with sympathetic blocks. Cognitive psychotherapy and psychological support are also of primary importance in some cases.

The majority of patients in my practice do not present with the classic signs and symptoms of RSD. Their clinical findings are much more subtle. In this group of patients, the condition is described more appropriately as "sympathetically maintained pain". This diagnosis is facilitated by thermography which reflects the activity of the sympathetic nervous system. The thermogram demonstrates temperature changes of the involved extremity. Local or global hypothermia or hyperthermia of an extremity is indicative of autonomic dysfunction when there are no other identifiable causes.

"Sympathetically maintained pain" is a more appropriate term to describe a syndrome which may be more common than the classic syndrome of RSD. The term RSD should be limited to those cases with typical signs and symptoms, while "sympathetically maintained pain" should be used whenever there is only thermographic evidence of sympathetic dysfunction<sup>9</sup>.

## REFERENCES

1. Bennett, G.J.; Ochoa, J.R.: Thermographic Observations on Rats with Experimental Neuropathic Pain. *Pain*, 45:61-67, 1991.
2. Bonelli, S., et al.: Regional Intravenous Guanethidine vs. Stellate Ganglion Block in Reflex Sympathetic Dystrophies: A Randomized Trial. *Pain*, 16:297, 1983.
3. Bonica, J.J.: Causalgia and Other Reflex Sympathetic Dystrophies. In, *The Management of Pain*, Vol. I Second Edition. Philadelphia, Lea & Febiger, pp. 220-243.
4. DeTakats, G.: Causalgic States in War and Peace. *JAMA*, 128:699-704, 1945.
5. Devor, M.: Nerve Pathophysiology and Mechanisms of Pain in Causalgia. *J. Auton Nerve Syst.*, 7:371-384, 1983.
6. Doupe, J.; Cullen, C.H.; Chance, G.Q.: Post-Traumatic Pain and the Causalgia Syndrome. *J. Neurol. Neurosurg. Psychiatry*, 7:33-48, 1944.
7. Evans, J.A.: Reflex Sympathetic Dystrophy: A Report on 57 Cases. *Ann. Intern. Med.*, 26:417-426, 1947.
8. Hannington-Kiff, J.G.: Relief of Causalgia in Limbs by Regional Intravenous Guanethidine. *Brit. Med. J.*, 2:367-368, 1979.
9. Harden, H.: Reflex Sympathetic Dystrophy and Other Sympathetically Maintained Pain. *Issues in Pain*. Pain Central Institute of Georgia. Editor: Brena, S. Vol. 3, No. 1, Fall 1990.
10. Hendler N.: Reflex Sympathetic Dystrophy and Causalgia. *Handbook of Chronic Pain Management*. Editor; C. David Tollison, PhD. Williams & Wilkins, 1989.
11. Homans, J.: Minor Causalgia: A Hyperesthetic Neurovascular Syndrome. *N. England J. of Med.*, 222:870-874, 1940.
12. Janig, W.: Pathobiology of Reflex Sympathetic Dystrophy: Some general conditions. In: M. Stanton Hicks, W. Janig, & R.A. Boas (Eds.) *Reflex Sympathetic Dystrophy*, Kluwer, Boston, 1990; pp. 42-45.
13. Lankford, L.L.; Thompason, J.E.: Reflex Sympathetic Dystrophy. *AAOS International Course Lectures*. St. Louis, C.V. Mosby Co., 26:163-178, 1977.
14. Livingston, W.K.: *Pain Mechanisms*. New York, Mac Millan Publishing Co. Inc., 1943.
15. Merskey, H.: Classifications of chronic pain: Descriptions of Chronic Pain Syndromes & Definitions of Pain Terms. *Pain*, (Suppl. 3)S28, 1986.
16. Mitchell, S.W.; Morehouse, G.R.; Keen, W.W.: *Gunshot Wounds and Other Injuries of Nerves*. New York, J.B. Lippincott, 1864.
17. Mitchell, S.W.: *Injuries of Nerves and Their Consequences*. New York, J.B. Lippincott, 1872.
18. Payne, R.: Neuropathic Pain Syndrome with Special Reference to Causalgia and Reflex Sympathetic Dystrophy. *Clin. J. of Pain*, 2:59-73, 1986.
19. Roberts, W.J.: A Hypothesis on the Physiological Basis for Causalgia and Related Pains. *Pain*, 24:297-311, 1986.
20. Schwartzman, R.J.: Reflex Sympathetic Dystrophy. *Arch. Neurol.*, 44:555-561, 1987.
21. Steinbrocker, O.: The Shoulder-Hand Syndrome. *AJ J. Med.*, 3:402-407, 1947.
22. Wall, P.D.; Melzack, R.: *Textbook of Pain*. Edinburgh, Churchill Livingstone, 1984.