

This comparison is not satisfactory because of the uncertainty as to the true minimal lethal dose in any species. It will be seen that some of the more tolerant animals possess the power of destroying atropine, but that the rat is exceptional since it is very tolerant to atropine, but none of its tissues have any power to destroy the drug.

Both Cloetta and Heffter show that an animal may be tolerant to subcutaneous doses but show no tolerance to intravenous doses, this is only natural because, when given intravenously, the drug exerts its specific action before sufficient time has elapsed for any appreciable destruction to occur. This rule probably holds good for most other drugs in which tolerance is observed, and with the development of intravenous therapy it may become of considerable practical importance.

CONCLUSIONS.

1. The livers of the frog and rabbit possess the power of destroying atropine; this power persists when all living cells are destroyed, and is due to a soluble body, resembling a ferment in its action.

2. In the frog the liver has a marked power, and the heart and kidneys have a slight power, to destroy atropine; no other tissues have any such power.

3. In the rabbit the liver has a marked power, and the blood a less marked power, to destroy atropine; no other tissues have any such power.

4. None of the tissues investigated in the cat, the rat, and the dog have any power to destroy atropine.

REFERENCES.

- ¹ Dixon.—Proc. Roy. Soc. Med., 1911, Vol. 5, Therap. Sect., p. 1.
- ² Buys.—Annales de la Soc. Roy. de Scien. Med. et Nat. de Brux., T. IV., p. 73, 1895.
- ³ Cloetta.—Arch. f. exp. Path. u. Pharm. Suppl., 1908, S. 119.
- ⁴ Cloetta.—Arch. f. exp. Path. u. Pharm., B. 64, S. 427, 1911.
- ⁵ Fleischmann.—Arch. f. exp. Path. u. Pharm., B. 62, S. 518, 1910.
- ⁶ Fleischmann.—Zeitschr. f. Klin. Med., B. 73, S. 174, 1911.
- ⁷ Metzner.—Arch. f. exp. Path. u. Pharm., B. 68, S. 110, 1912.
- ⁸ Cloetta and Fischer.—Arch. f. exp. Path. u. Pharm., B. 54, S. 294, 1906.
- ⁹ Albanese.—Centralbl. f. physiol., B. 23, S. 241, 1909.
- ¹⁰ Fickewirth and Heffter.—Biochem. Zeitschrift, B. 40, S. 36, 1912.

(The expenses of this research were in part defrayed by a grant from the Royal Society.)

STUDY OF EXPERIMENTAL PURPURA.

BY

E. MARSHALL COWELL, M.D., F.R.C.S.

Although it is now easier to interpret the phenomena of purpura on theoretical grounds, yet it is still difficult to explain many cases clinically, and more difficult to produce the condition experimentally. The experiments generally quoted in the large text-books are those of Grenet, carried out in 1904. This author claimed to have produced purpura in a rabbit by introducing three pathological factors:—(1) Hepatic derangement; (2) nervous disturbance; (3) presence of toxin. These are old observations, but, as far as I know, have neither been confirmed nor disproved. My first experiments were therefore repetitions of Grenet's, using, as far as possible, the same technique.

Grenet took rabbits, ligatured the "hepatic pedicle" for twenty minutes, and then in five to seven days injected an alcoholic extract of serum from a hæmophilic patient into the spinal canal. Paraplegia of varying degrees followed, but within a week ecchymoses on the hind legs invariably appeared. Control injections, without preliminary ligature of the pedicle, and also of simple fluids with ligature, always gave negative results.

In the four rabbits in which these proceedings were repeated, apart from some paresis of the hind limbs, no change was produced. No sign of purpura ever appeared. In six other rabbits intraspinal injections were made to investigate the curious tetaniform convulsions which occur when the cord is irritated. Using any fluid, it was found that 1 c.c., the amount employed by Grenet, caused death in a few minutes; with 0.5 c.c. recovery with paresis followed.

Sections of the liver, cut at different dates after ligature of the pedicle, showed no histological changes.

Charrin in 1892 described the easy production of purpura by injecting either organisms and their toxins into animals. *B. pyocaneus* was said to give purpura readily. I found, however, that repeated doses of sterilised twenty-four hours' growth of this organism produced negative results. Animals dying with a *pyocaneus* septicæmia even developed no purpura. Other bacterial toxins, as diphtheria and coli, also injected into guinea-pigs, failed to give a positive result. The mere presence of potent bacterial toxins is not sufficient to produce purpura; some other factor must be present before lysis of the capillary endothelium can occur.

The number of blood platelets is said to be greatly reduced in the hæmorrhagic conditions. Duke has studied the subject, and finds the platelet count is 30,000-80,000 instead of the normal 500,000-600,000 per c.mm. Selling, by injecting benzol subcutaneously into dogs, claims to have been able to reduce the number of platelets. It seemed, therefore, that by diminishing the platelets and then giving the animal toxins, that purpura should follow. Unfortunately I have not been able to confirm Selling's work, using rabbits and guinea-pigs. In counting the platelets Pratt's method was used. Careful microscopic examination of the liver and spleen of these animals failed to show free iron. It is difficult to imagine a drug affecting platelets without at the same time destroying the red corpuscles.

Appended are the tables of blood counts, showing the effect of benzol:—

Date.	Hb%	Reds	Whites	Platelets	Inj. Benzol.
Jan. 22	85	5500000	14000	690000	nil.
" 23	90	6000000	15000	600000	*3cc.
" 24	—	—	—	—	1cc.
" 25	85	5160000	11900	480000	1.5cc.
Feb. 1	60	4200000	11250	450000	1cc.
" 6	90	5060000	15000	500000	1.5cc.
" 9	80	5000000	12000	550000	1.5cc.
" 20	90	6500000	12500	480000	1.5cc.
" 21	95	6800000	19000	540000	nil.
"	Animal killed.				
Jan. 23	99	6500000	12500	400000	*3cc.
24	—	—	—	—	*2cc.
Feb. 1	95	6000000	13000	600000	*2cc.
" 6	95	6500000	14000	620000	*5cc.
" 9	98	6000000	15000	580000	*5cc.
10	animal killed.				

CONCLUSIONS.

Unfortunately, as regards the production of experimental purpura, my results have been negative. It appears that the oft-quoted positive experiments must, at any rate, not be accepted at present.

It is doubtful whether benzol has any effect on the blood platelets.

Although the lytic body at work in purpura is undoubtedly allied to its hæmolysin, yet its action seems to be different, since in two fatal cases of purpura neonatorum I have been able to microscope the organs without finding traces of free iron.

BIBLIOGRAPHY.

- Grenet.—Archiv. Gen. de Med., Paris, 1904, Vol. I., p. 129.
 Charrin.—Compt. Rend. de la Soc. de Biol., Paris, 1902, p. 427.
 Duke.—Journ. Amer. Med. Assoc., 1910, Vol. LV., p. 1,185.
 Selling.—Ibid., quoted by Duke.
 Pratt.—Ibid., 1905, Vol. XLV., p. 1,999.

SOME CLINICAL AND EXPERIMENTAL OBSERVATIONS ON THE OPERATIVE TREATMENT OF FRACTURES,

WITH ESPECIAL REFERENCE TO THE USE OF INTRA-MEDULLARY PEGS.

BY

ERNEST W. HEY GROVES, M.S., F.R.C.S.

The use of intra-medullary pegs for the fractures of the long bones is, of course, no new invention. Various modifications of these, in shape and material, have often been suggested. But for two chief reasons they have not been used very widely, first because of the fear of sepsis being introduced into the marrow cavity, and secondly because of the mechanical difficulty of introducing the peg into the interior of the closely-apposed fractured ends.

Nevertheless I feel quite sure that in certain cases the method of using an intra-medullary peg has great advantages over all others, and I have endeavoured to ascertain, by clinical and experimental observation, the comparative merits of this and other methods of the operative treatment of fractures.

There are two different methods by which the pegs may be introduced into the bone.

1. Pegs with Fixed Crosspiece.

Fig. 1 illustrates the first kind of peg. It is comparatively short—i. e., about 2.4 c.m. in length. It has a fixed crosspiece, transfixing its centre, which keeps the peg from slipping too far into one end or other of the hollow bone. One end of the peg is fitted into one fragment of the broken bone. Then the




Fig. 1.—Short peg with fixed crosspiece. a, The peg. b, Insertion of the peg. One end has been placed and the other bony fragment is about to be placed in apposition.

other fragment is made to engage the projecting end of the peg, and by bringing the bone fragments into line with one another the muscular tension pulls the ends of the bone together over the enclosed peg, which serves thus to keep the fragments in exact apposition. This type of peg can only be used in those cases where the broken bone fragments are easily separated from one another. When it is in position, owing to its shortness, it does not exercise much influence in maintaining the straight axis of the bone.

2. Pegs introduced by Wire Traction.

But in the important class of fractures in which operation is demanded most imperatively; a peg like the one described cannot be employed, simply because in these neglected or mal-united cases it is impossible to separate the broken ends of the bone sufficiently to insert the peg. For these cases I have used pegs (Fig. 2) which are drawn into their place by means of wire traction. Each of these pegs is about 4.7 c.m. long, and is perforated in its centre by a hole transverse to its long axis. Along opposite sides of the peg run grooves in its whole length, and into these grooves the ends of the transverse hole open.

The size of the hole and groove is one which easily takes a fine flexible steel wire, which, when threaded through the transverse hole, lies snugly in the grooves, so that the whole peg can be slipped into one fragment of the bone, the other fragment brought into apposition, and then, by traction on the wire, the peg is pulled up into position, so that one half lies in one fragment and the other in the other.

As regards the thickness of these pegs, I have a set of thirteen sizes, varying from one-eighth to one-half inch, each size differing from the other by one-thirty-second of an inch, and also a set of drills for preparing the bone ends. Each drill makes a hole, into which the corresponding peg will slip easily. The object of drilling the bone should simply be to clear away any rough, outstanding spicules of bone, and not to actually enlarge the natural marrow cavity. It is unnecessary to make the pegs fit very tightly, and the less drilling that is done the better. As regards the method of traction on the wire, in most cases it is quite sufficient to pull on the wire ends, which are rolled round pairs of forceps. But if one has to work at the bottom of a deep wound, which makes it difficult to carry this out, the traction may be made by an instrument (Fig. 3), which winds the wire ends on to two revolving shafts, at considerable mechanical advantage

Experimental Results.

I have carried out a series of experiments on cats and rabbits in order to test the rapidity and efficiency of organic union of the bones when fixed after fracture by various

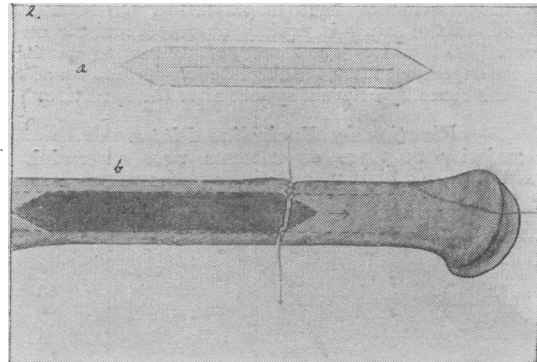


Fig. 2.—Long peg, introduced by wire traction. a is the peg showing the groove and perforation for the wire. b, Bone, with fragments in line; the peg is wholly in the left-hand fragment, and the wire, the ends of which are indicated by arrows, when pulled on will draw the peg up into the other fragment.

appliances. Up to the present these have been 50 in number, and although my full inquiry is not yet complete, I have attained certain results which are of interest. I will merely give a few examples and illustrations of this part of my work.

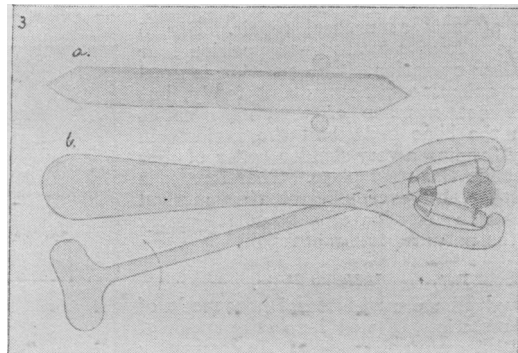


Fig. 3.—Instrument for introduction of the long pegs in difficult cases. a, Shows the peg from the side being pulled up by the turning of the two rollers which pull on the wire. b, The instrument, which consists essentially in two steel rollers which roll the wire ends, and so pull upon the peg which lies between them.

Plates and Screws.

I endeavoured to carry out the method chiefly advocated by Arbuthnot Lane. That is to say, a small steel plate was used, which was screwed into the dense bone on either side of the fracture without perforating the entire thickness of the bone. But owing to the small size of the screws used, and the fact that it is practically impossible to immobilise the limbs of animals by external splints in

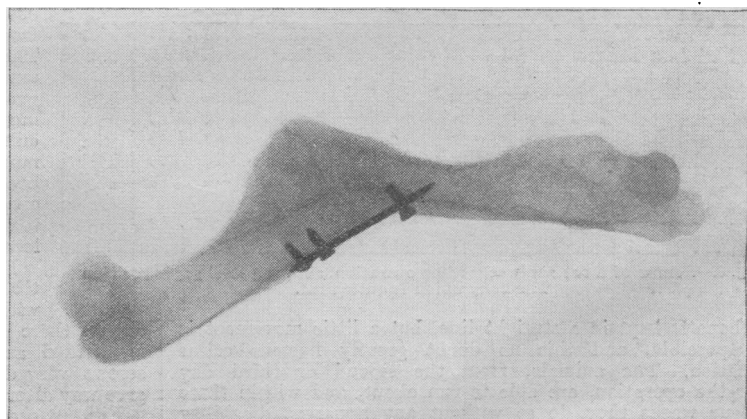


Fig. 4.—Femur of a cat four weeks after a plating operation, showing the way in which the screws from one end have been drawn completely out of place.

the way that it is done in human surgery, none of these experiments gave good results. Invariably within one week

of the operation the screws from one or both ends had been pulled out and complete disunion of the fracture occurred. (Fig. 4.) I think that it is fully proved that no screw which merely penetrates the outer shell can hold a bone in position for long if there still exists a constant considerable force tending to its displacement. In such cases the bone round the screw is rapidly absorbed, and the screw comes out. (See Fig. 10.) The success of any plating operation is therefore dependent upon the absolute fixation and immobilisation of the bones by external splints after the operation.

Fixation by Encircling Plates.

The majority of these experiments were successful. I have used steel, aluminium, and silver plates wrapped round




Fig. 5.—Tibia of a cat five weeks after operation. The fragments are surrounded by an aluminium plate which is almost transparent to the x rays. With the exception of a little periosteal callus at each end of the plate, there is no trace of repair.

the seat of the fracture like a collar and fixed by wire. But in none of these, at the periods during which the animals have been kept alive (four to five weeks), was there any efficient attempt at natural repair. Fig. 5 shows the tibia of a cat in good position four weeks after operation. The position is good and the animal could run about freely, but there is not a trace of reparative callus between the bone ends, and the periosteum is slowly forming a very slender collar of new bone outside the steel plate. Therefore, it is evident that, however efficient that method may be in the fixation of a bone, it greatly retards the natural process of repair.

Intramedullary Pegs.

Although I have used internal pegs made of various materials, I will here only speak of those which are unabsorbable. In comparing the merits of various materials—*e.g.*, bone, steel, and aluminium—the metal pegs are much the best for animal experiments, because those made of bone or ivory are very brittle, and are liable to be broken. It is an interesting fact, as illustrating the very powerful force which tends to displace a fractured bone, that in every case (about ten in number) in which I used a bone or ivory peg for the tibia or femur of an animal, this was snapped in two, and the fragments thus became displaced. Steel is preferable to aluminium, because it throws such a good shadow by the X-Rays. A steel peg is very easy to insert by the method I have described. When it is inserted




Fig. 6.—Femur of a cat six weeks after operation, showing steel peg in position. The bony union is quite firm.

the bone is kept in a straight line, but a little movement is still possible, and this no doubt greatly hastens callus formation. The animals, from the second or third day after the operation, are able to run about, and within three or four weeks they do so without any apparent disability or limping. Fig. 6 is from the tibia of a cat killed six weeks after the operation. The experiments demonstrate that the method is easy, it secures good position, firm and speedy union, and perfect functional result.

Magnesium has a very definite and distinct characteristic

when used for the pegging of bones. It is absorbed within a few weeks, and in the process of its absorption it greatly stimulates the callus production and the ossification of the same. Fig. 7 shows the tibia of a cat eight weeks after the operation, and it will be seen that there is a well-marked spindle-shaped thickening of the bone at the seat of the fracture.

Although this property of magnesium renders it unsuitable for use in ordinary cases, it may be of great value in treatment of old cases of ununited fracture, in which a powerful stimulus to callus formation is the object most desired.

Of the other forms of absorbable bone pegs I have not yet found any which give good results with animal experiments. I have used decalcified bone, horn, catgut, gelatine hardened with formol, and fibrine round an axis of catgut. Of these horn is the best, but in all cases the softening takes place too early—that is to say, before any organic fixation has occurred—and then complete displacement takes place. But it is possible that these pegs might be useful in human surgery in conjunction with external splints.

Some Clinical Results.

I have used the method of intra-medullary pegs for the treatment of bad fractures for the last two years, and I feel sure that it has certain advantages over other methods

of operation. I will here, however, content myself with giving two examples of conditions for which it is specially suitable. Fig. 8 shows the femur of a boy of 13, broken

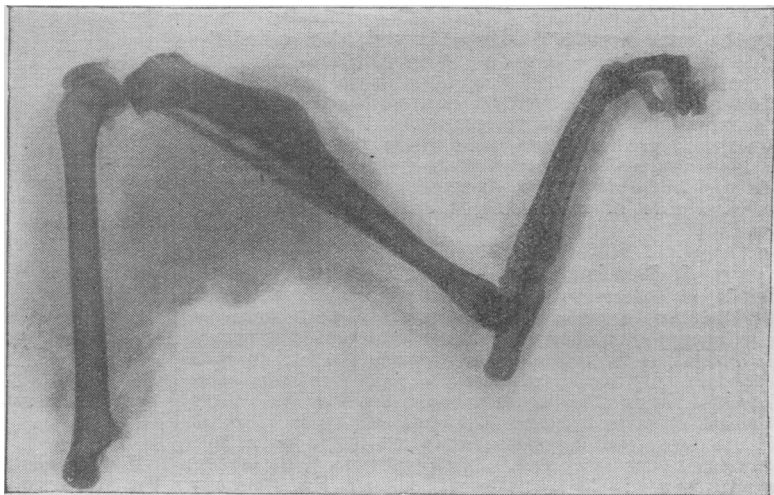


Fig. 7.—Shows the tibia of a cat, eight weeks after operation, with a peg of solid magnesium. There is marked over-production of callus.

in its upper third, with a displacement which neither weight extension nor a double-inclined plane could reduce. Fig. 9 shows how perfect the apposition was after the introduction of an intra-medullary peg. This is the kind of fracture for which the method is especially suitable. The displacement is very difficult to correct by external means; it is still more so to maintain in good position. The bones lie so deeply bedded in muscles that any kind of screwing operation is difficult to carry out efficiently, and, moreover, the muscular tension is so great that a single plate becomes displaced within a short time after the operation. Fig. 10 is from a case of this kind, and it shows the plate and screws, which have become loose within two weeks of the operation.

Fig. 11 illustrates a malunited fracture of the tibia and fibula 18 months after the accident, with much overlapping of the fragments. In such

a case there is very great muscular tension when the bone is divided and replaced. This would make fixation by screws very difficult, and such fixation would be liable to give way after the operation.

Fig. 12 shows the same case four weeks after the operation, the ends of the tibia being replaced over an intra-medullary peg.

Conclusions.

The advantages of the intra-medullary peg method, in operative treatment of fractures may be summarised as

follows:—(1) It can be easily and quickly performed, provided the details I have suggested are observed. (2) It requires a very much smaller incision and less exposure of

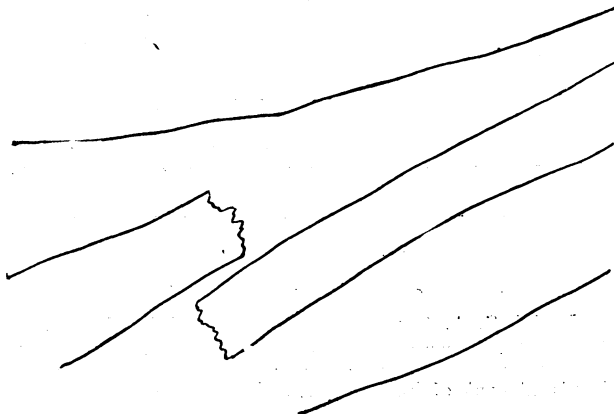

Fig. 8.—Fractured femur of a boy of 13, broken in its upper third, with displacement of its upper fragment in front of the lower.

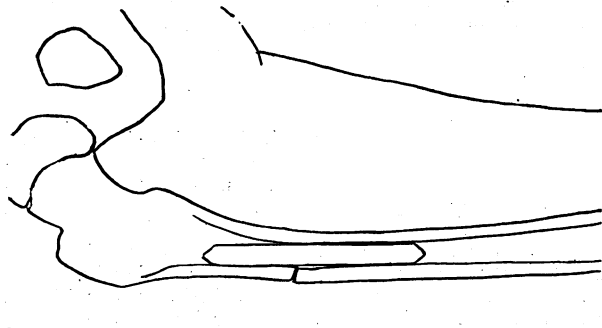


Fig. 9.—The same case shown in Fig. 8, a fortnight after the introduction of a bone peg.

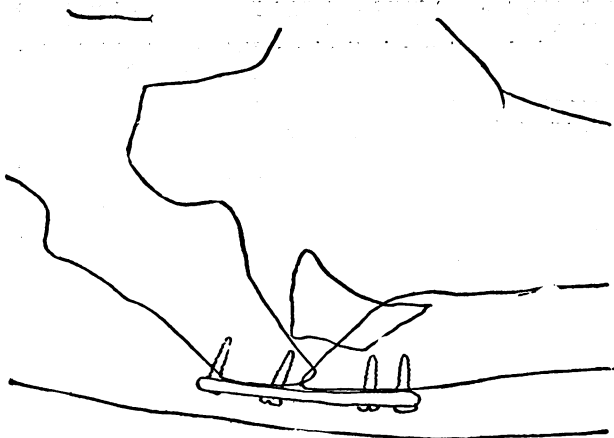


Fig. 10.—Femur of a man, broken in its upper third, showing how a plate and screws failed to maintain the correct position of the bones.

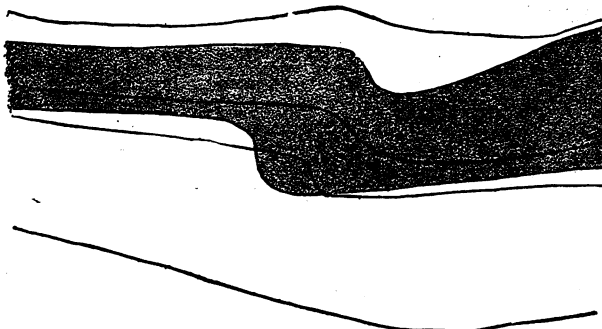


Fig. 11.—Malunited fracture of the leg bones eighteen months after the accident. The tibia is shaded and the fibula only shown in outline.

the soft parts. (3) It involves a minimum of injury to the periosteum. (4) It adjusts the broken bone in the correct position. (5) It allows slight movements between

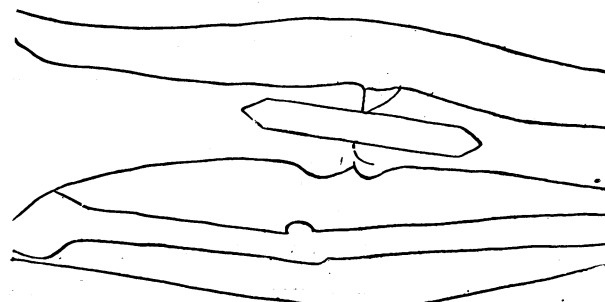


Fig. 12.—The same case as shown in Fig. 11, after the operation, showing the peg in position. A piece of the wire used to draw the peg into position has been left to prevent the peg slipping up or down.

the fragments, which is beneficial for rapid union. (6) It makes the use of external splints unnecessary after the operation, and massage and movements are thus rendered possible as soon as the wound has healed.

[Figures 8, 9, 10, 11 and 12 are accurate outline drawings from the actual skiagrams, reproduced in this form for the sake of clearness.—Ed.]

THE ACUTE AND SUBACUTE LESIONS INDUCED IN THE SPINAL CORD BY INFECTION OF ITS LYMPH SYSTEM.

By DAVID ORR, M.D.,

PATHOLOGIST, LANCASTER COUNTY ASYLUM, PRESTWICH,

AND

R. G. ROWS, M.D.,

PATHOLOGIST, COUNTY ASYLUM, LANCASTER.

The research carried out during the past year has been a continuation of the investigations on the inflammatory phenomena induced in the central nervous system by infection of its lymphatic system. In our last paper we gave in detail the histological evidence which demonstrated that the path of the toxic lymph could be traced, by the presence of inflammatory reaction, along the infected sciatic nerve as far as the posterior root ganglion, and for a considerable distance along the spinal roots. The nerve had been infected by placing a celloidin capsule containing a broth culture of micro-organisms in contact with it.

In our most recent experiments the spinal cord was infected in two ways—either by removing the laminae of the vertebrae and suturing the capsule against the dura mater at the level of the lumbar enlargement, or by separating the muscles from the vertebrae in the dorsal region and placing a capsule against an intervertebral foramen.

All the experiments yielded positive results, but there were marked differences in the degree of the reaction, because in some cases the capsule had burst and a growth of organisms had occurred in the tissues and spread along the dura mater.

In the experiments in which the capsule had burst the changes in the spinal cord were of an acute nature. When there was no growth of organisms outside the capsule the reaction was sub-acute.

SYNOPSIS OF THE PHENOMENA IN THE ACUTE SERIES.

1. In the epidural tissue there were micro-organisms, polymorphonuclear leucocytes, and large lymphocytes.

2. Inflammatory reaction of the cells of the dura mater and pia mater, with the formation of polyblasts.

3. Within the spinal cord were found:—Proliferation of the adventitial and endothelial cells, with the formation of polyblasts, and here and there of compound granular corpuscles; dilatation of the blood vessels, and the formation of thrombi within them; neuroglia proliferation; nerve cell degeneration and neuronophagy.

SYNOPSIS OF THE PHENOMENA IN THE SUB-ACUTE SERIES.

1. In the epidural tissue there were polymorphonuclear leucocytes, plasma cells, and polyblasts.

2. Plasma cells were present also in the dura mater and in the capsule of the posterior root ganglia; in the substance of the posterior root ganglia, and collected into a prominent group at the proximal pole; in the perineurium of the spinal roots and in the adventitial sheath of the vessels in it; in the