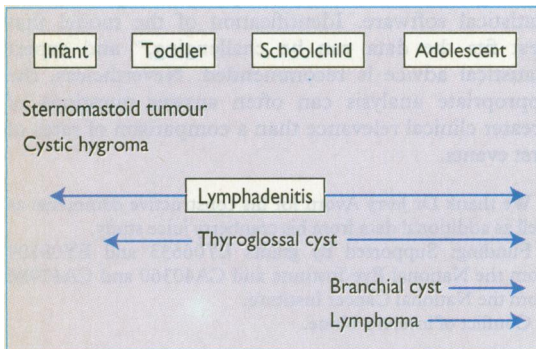


## LUMPS AND SWELLINGS OF THE HEAD AND NECK

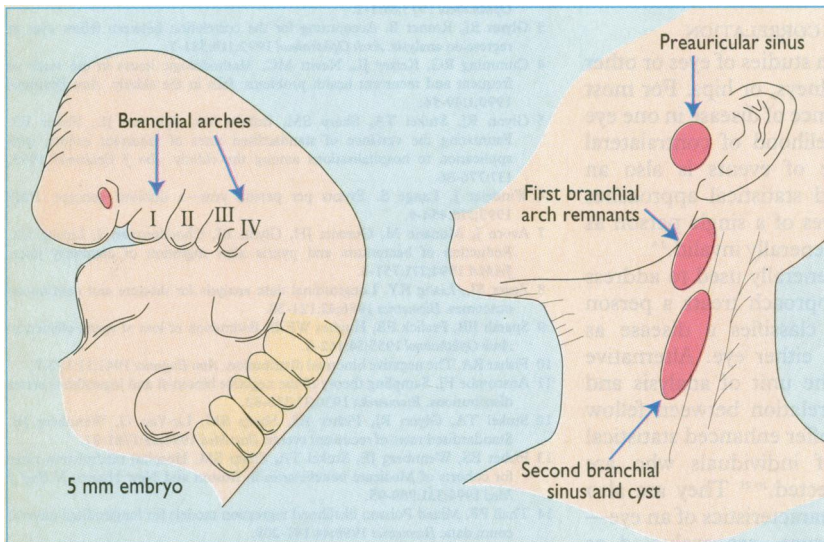
Mark Davenport



Commonest causes of neck lumps in children by age.

Lumps arising in the head and neck constitute an important diagnostic category in children. As neoplasia is such a rare cause of head and neck swellings in this age group, lumps can be broadly divided into those having a congenital origin and those due to inflammatory or infective causes. Some knowledge of the embryological development of the neck is important in understanding how a substantial proportion of these lumps arise. It becomes even more important if these are to be surgically excised—the usual treatment.

### Branchial cleft apparatus and its derivatives

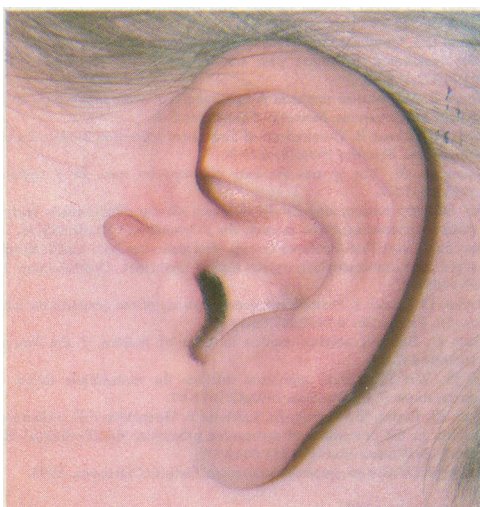


Branchial arches in human embryo (left) and usual sites of branchial remnants in child (right).

The branchial arches are well developed ridges that are visible in the cervical region of the embryo from the fourth to the eighth week of gestation. Each consists of a mesodermal cartilaginous centre, an intervening ectodermal cleft, an internal pouch, and a parent nerve. They are believed to recapitulate gill-like structures (Greek, *branchia*—gills). Although comparative anatomists can identify six such structures, only the first four are distinct in humans. The mandible, eustachian tube, and some bones of the middle ear are derived from the first branchial arch, while the second arch and its internal pouch form the hyoid bone and the tonsillar fossa respectively.

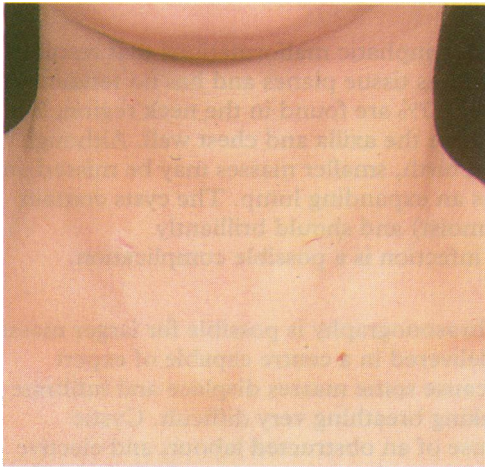
#### Branchial derivatives

These may take the form of cysts, sinuses, or cartilaginous remnants, and it is possible to identify the relevant branchial arch from the anatomical position. Strangely, although most remnants have usually been present since birth, branchial cysts most commonly present in adolescence or adulthood.



Preauricular cartilaginous remnant.

**Preauricular and first branchial remnants**—Small sinuses and cartilage remnants just in front of the ear are the commonest finding but are probably not of branchial origin. Such preauricular pits may be blind but occasionally lead to a racemose collection of small cysts or to the cartilage of the helix. Otherwise inconspicuous pits may present as an infection or abscess in front of the ear. A true sinus or fistula from the first branchial arch is rare and has an opening just below the angle of the jaw along the uppermost border of the sternomastoid. A communication with the external meatus may be identified during dissection.



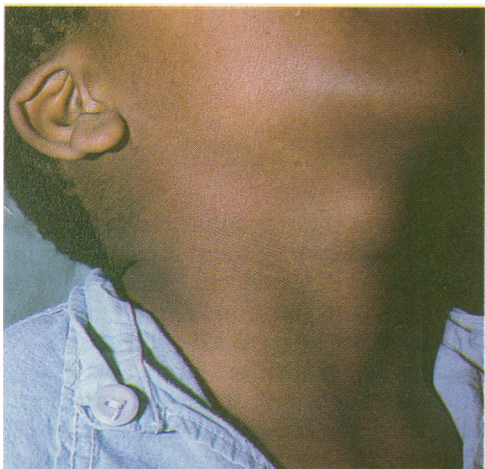Bilateral branchial sinuses, related to anterior border of sternomastoid.

*Second branchial remnants*—The external opening of a branchial sinus or fistula is almost always related to the anterior border of the sternomastoid. Such sinuses may be bilateral and extend deeper and higher into the neck than is apparent from a superficial examination, occasionally opening near the tonsillar fossa itself. A thin, glairy mucoid fluid can be secreted from a sinus, although secondary infection is the usual reason for referral.

*Branchial cysts* are palpable anterior to the middle third of the sternomastoid and may become more prominent after an upper respiratory tract infection. They are not usually apparent during childhood. Some authors have used this and the obvious lymphoid tissue in the wall as evidence against these being branchial remnants at all and have suggested that they are derived from cystic degeneration in lymph nodes.

*Treatment*—Uninfected derivatives should be treated by formal surgical excision, with a careful attempt made to identify any deeper components. A counter incision is often needed to gain access to the deeper aspects of the tract. Infected cysts or sinuses should be treated with antibiotics and, if necessary, aspirated or surgically drained. A more formal excision can be performed when the infection is quiescent.

## Thyroglossal derivatives



Thyroglossal cyst—exaggerated by neck extension.

The thyroid gland develops from tissue originally derived from the posterior third of the tongue, which descends during fetal life to its final position anterior to the tracheal rings. Several anomalies may follow from this complex migration. Rarely, no migration occurs, and the thyroid develops entirely at the back of the tongue—a lingual thyroid. More common are thyroglossal cysts, ectodermal remnants that develop along the line of descent of the thyroid gland.

### *Thyroglossal cysts*

The key diagnostic features of these neck lumps are their midline position and movement on tongue protrusion and swallowing. They present most commonly in toddlers and older children as a painless neck lump. Most are intimately related to the hyoid bone, which explains their relation to the tongue and muscles of swallowing. About 10% arise under the chin as submental swellings and may be confused with midline dermoid cysts. Secondary infection of thyroglossal cysts may occur, and their congenital origin is only suspected when recurrence or persistent drainage follows surgical incision.

Although clinical examination is often sufficient for diagnosis, some surgeons obtain a radioisotope thyroid scan before excision to ensure that a normal thyroid gland is present. Excision of the middle third of the hyoid bone in continuity with the cyst (Sistrunk's operation) should be performed to reduce the possibility of recurrence.

## Cervicofacial dermoids

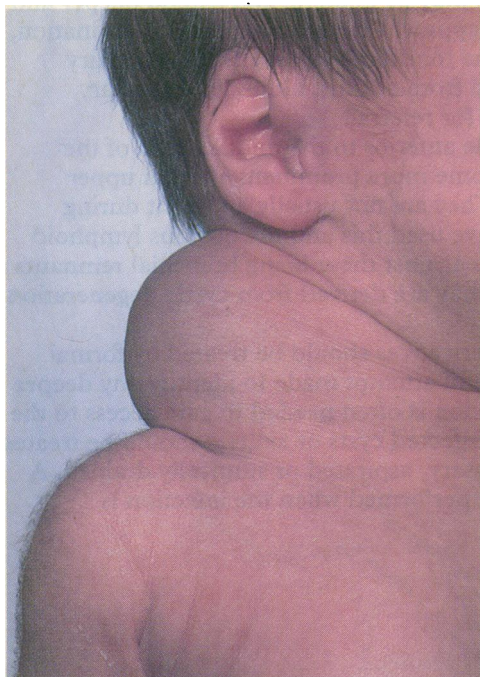
### **Common sites of cervicofacial dermoids**

- Between outer border of eye and hair line (external angular dermoid)
- Nasal bridge
- Under chin (sub-mental)
- Superficial to sternum

The soft tissues of the face are formed by the convergence of three facial processes (frontal, maxillary, and mandibular). As a consequence, there are lines of fusion where islands of ectodermal tissue may become submerged, later to secrete sebaceous material and present as obvious cystic swellings known as dermoids. The commonest site for this phenomenon is at the upper lateral part of the forehead (an external angular dermoid), but other sites include the upper medial part of the eye or along the midline of the face and neck. Rarely, there may be a communication through the calvarium and two dermoid elements occurring on either side of the bone to resemble a dumb-bell tumour. Any suspicion that a dermoid may be fixed to the bone should prompt an x ray examination or even computed tomography to test this possibility. Dermoids should be treated by excision.



## Cystic hygroma



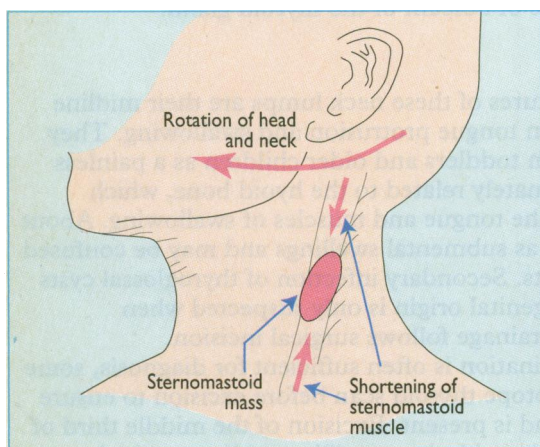
Cystic hygroma arising from posterior triangle of neck.

These are hamartomatous, lymphatic malformations that result in a multicystic mass which infiltrates tissue planes and has no tendency to spontaneous resolution. Over 60% are found in the neck region, but other sites of origin may include the axilla and chest wall. Although they are invariably present at birth, smaller masses may be missed and present later in childhood as an expanding lump. The cysts contain clear fluid (Greek, *hygros*—moist) and should brilliantly transilluminate. Secondary infection is a possible complication.

Antenatal diagnosis by ultrasonography is possible for larger masses; affected infants should be delivered in a centre capable of expert endotracheal intubation because some masses displace and infiltrate the pharynx and larynx, making breathing very difficult. Cystic hygromas are also a rare cause of an obstructed labour, and elective caesarian section may be necessary for a proportion of affected infants.

Treatment of these often cosmetically disabling masses can be difficult. Surgical excision of all the affected tissue is the ideal, but this can be difficult because of infiltration of vital neck structures, and recurrence is therefore all too common. A variety of sclerosing agents that can be injected directly have been used over the years. The latest is a solution made of inactivated streptococcal organisms (FK 432); this is obtainable for named patients from Japan and has been remarkably effective for recurrent lesions.

## Sternomastoid tumour



Mechanism of torticollis.

This is a mass in the middle third of the sternomastoid muscle. It is probably caused by overstretching of the muscle and myolysis during a difficult delivery. Such lumps are often detected some weeks after birth and may be associated with shortening of the muscle and, hence, a wry neck or torticollis looking away from the affected side. Treatment should be directed at the torticollis rather than the lump, and physiotherapy and manipulation are important. If it is left untreated the soft tissues of the face may rarely become asymmetric and, even with straightening, may appear very abnormal. Surgical lengthening can be achieved with a small incision over the sternoclavicular insertion of the muscle.

## Cervical lymphadenopathy, lymphadenitis, and abscess

### *Cervical lymphadenopathy*

This is common during the middle years of childhood but is seldom pathological. The usual scenario is of an indolent, non-tender, dominant node in the jugular chain which persists over several months. Lymphadenopathy is usually recognised in other cervical nodes, and any other systemic symptoms are few. Such children have a normal full blood count and normal chest radiograph, and if the node is excised it shows reactive hyperplasia.

### **Characteristic features of lymphadenopathy**

- Found along jugular vein
- Mostly benign
- Related to respiratory and throat infections
- Histological appearance of reactive hyperplasia

*Cat scratch fever* is a specific cause of childhood lymphadenopathy caused by a small bacillus, *Rochalimaea henselae*. There is often a small papule at the inoculation site, and tender lymphadenopathy occurs about two weeks after the scratch (usually from a kitten). The diagnosis can be established either by aspiration and use of a special (Warthin-Starry) silver stain or by node excision.

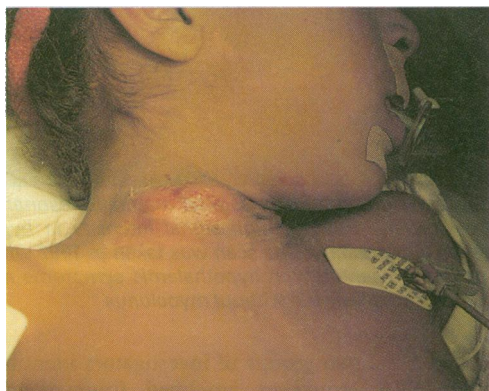
### Characteristic features of lymphadenitis

- Acute tenderness
- Pain
- Swelling
- Erythema of overlying skin
- If pus is formed it requires surgical drainage

### Lymphadenitis

Acute lymphadenitis is most often bacterial (streptococcal or staphylococcal) in origin, with the presumed point of entry being the throat. The swelling is acutely tender with overlying skin erythema, and, if it is allowed to progress to actual formation of pus, fluctuance can be elicited. It is possible to attenuate the natural course of bacterial lymphadenitis by using antibiotics (such as co-amoxiclav or erythromycin), but if the condition does not resolve within about 48 hours an abscess must be suspected and surgical drainage should be considered.

*Mycobacterial lymphadenitis*—If the history of the condition is longer (perhaps over a period of weeks), less acutely tender, and responds only partially or not at all to an appropriate antibiotic then lymphadenitis due to mycobacterial organisms should be considered. In Britain the causative organism is usually an atypical mycobacterium (such as *Mycobacterium avium-intracellulare*). This is not associated with the systemic symptoms, abnormality on a chest radiograph, or even a positive Mantoux test that would occur with, for instance, human tuberculosis. The treatment is surgical excision of all affected lymph nodes together with any associated chronic sinus and affected skin. Standard antituberculous chemotherapy is often started but is seldom effective because of drug resistance, although newer macrolide antibiotics (such as azithromycin) may have a role in some cases.



Chronic lymphadenitis due to atypical mycobacterial infection.

Professor Lewis Spitz, Institute of Child Health, London, provided some of the clinical illustrations.

The ABC of General Surgery in Children is edited by Mark Davenport, consultant paediatric surgeon, department of paediatric surgery, King's College Hospital, London.

## Grand Rounds—Hammersmith Hospital

### Cerebral Whipple's disease

#### Relapse presenting with spinal myoclonus

Whipple's disease is a rare disease caused by infection with the newly identified organism *Tropheryma whippelii*. Relapses of the disease most commonly occur in the central nervous system and are often resistant to antibiotics. We present the case of a man with recurring ophthalmoplegia, myoclonus, and hypothalamic symptoms while on treatment with co-trimoxazole for a previous relapse of Whipple's disease in the central nervous system. The patient had the clinical and electromyographic features of spinal myoclonus, a movement disorder not previously described in isolation in Whipple's disease. We then discuss the clinical features and pharmacological treatment of cerebral Whipple's disease.

#### Case history

A 28 year old right handed man was admitted to the neurology ward of his local hospital for further investigations. The patient was Italian and worked as a bank clerk in Pisa.

He gave an 18 month history of gradually worsening involuntary movements of both arms and the upper trunk. He also had impaired eye movements and a six month history of ejaculatory and erectile difficulties, weight gain, somnolence, and depression. He also complained of poor memory and difficulty with concentration.

His medical history was that in 1986 he had presented with nausea, anorexia, abdominal pain, and weight loss. Endoscopy was performed, and duodenal

mucosal biopsies showed macrophages that yielded a positive result when stained with the periodic acid Schiff reagent. Intestinal Whipple's disease was diagnosed, and he was treated for six months with oral amoxicillin.

In 1992 he had presented with increased skin pigmentation, lethargy, weight gain, and decreased libido. He had paralysed vertical ocular movements. Staining with periodic acid Schiff reagent did not yield a positive result in duodenal biopsies but did in 15 mononuclear cells from the cerebrospinal fluid.

Magnetic resonance imaging of the brain showed multiple focal lesions in the hypothalamus, striatum, and midbrain (fig 1). Relapse of Whipple's disease in the central nervous system was diagnosed. He was treated for two weeks with intravenous streptomycin and penicillin and then with oral co-trimoxazole. He made a gradual and complete recovery.

In 1993, however, he presented with involuntary twitching of the right arm and limitation of voluntary eye movements. At this stage he was referred to this hospital. His serum co-trimoxazole concentrations were below the optimal treatment range. The patient admitted poor compliance with taking his antibiotics.

Cerebrospinal fluid showed 10 mononuclear cells, which gave a weakly positive result when stained with periodic acid Schiff reagent. Polymerase chain reaction amplification of the cerebrospinal fluid was performed and contained a DNA sequence specific for *T whippelii*. Magnetic resonance imaging of the brain and cervical spine was performed; the images were suboptimal



Hammersmith Hospital,  
London W12 0NN

Case presented by:  
R A Weeks, *neurology registrar*

Chairman:  
J Scott, *professor of medicine*

Discussion group:  
D J Brooks, *Hartnett professor of neurology*  
H Hodgson, *professor of gastroenterology*  
J Cohen, *professor of infectious disease*

Series edited by:  
Dr W A Lynn.

BMJ 1996;312:371-3