

## Fortnightly Review

### Callosities, corns, and calluses

Dishan Singh, George Bentley, Saul G Trevino

Callosities can be painful, and the symptoms may be so intense as to seriously affect a person's gait, choice of footwear, and activities. While many patients seek symptomatic relief from a chiropodist or pharmacist, doctors should be familiar with the diagnosis and management of these common disorders.

#### Nomenclature

Many medical textbooks fail to clearly differentiate between the various types of keratotic lesions. Furthermore, the terminology used by British surgeons, American surgeons, rheumatologists, dermatologists, and podiatrists is different and sometimes confusing.<sup>1-9</sup> The definitions below reflect the most widely accepted use of the terms (fig 1).

#### CALLOSITY

A callosity occurs when the process of keratinisation, which maintains the stratum corneum of the skin as a horny protective cover, becomes overactive due to shearing or compressive forces. This is a normal protective response—as seen in the hands of manual labourers and the feet of those who walk barefoot—and a callosity becomes pathological only when it is so large as to cause symptoms.

#### CORN

A corn represents a circumscribed, sharply demarcated area of traumatic hyperkeratosis. It has a visible translucent central core which presses deeply into the dermis, causing pain and sometimes inflammation. The term *heloma* (Greek *helus*, a stone wedge) is often used by podiatrists to denote a corn (Latin *cornu*, horn).

The hard corn (*heloma durum*) represents the classic corn—a dry horny mass most commonly found on the dorsolateral aspect of the fifth toe or the dorsum of the interphalangeal joints of the lesser toes (fig 2). It is often termed the digital corn.

The soft corn (*heloma molle*) is an extremely painful lesion that occurs only interdigitally and is probably best termed an interdigital corn. It is essentially a corn that has absorbed a considerable amount of moisture from sweat, leading to characteristic maceration (fig 3) and sometimes secondary fungal or bacterial infection. It is most common in the fourth interdigital space. Sometimes two opposing lesions can be found and are termed “kissing lesions.”

Institute of Orthopaedics,  
Royal National  
Orthopaedic Hospital,  
Stanmore, Middlesex  
HA7 4LP

Dishan Singh, senior lecturer  
George Bentley, professor

Baylor College of  
Medicine, Houston, Texas,  
USA

Saul G Trevino, associate  
professor

Correspondence to:  
Mr Singh.

BMJ 1996;312:1403-6

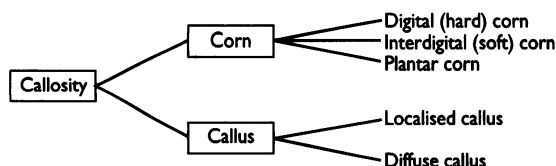


Fig 1—Classification of callosities in the foot

#### Summary points

- Corns and calluses arise from hyperkeratosis, a normal physiological response to chronic excessive pressure or friction on the skin
- They may be caused by excessive irritation from poorly fitting shoes or by abnormal pressure if there is a deformity of the foot
- Treatment should therefore not only provide symptomatic relief (such as by regular paring or using keratolytic agents) but should also alleviate the underlying mechanical cause
- Most lesions can be managed conservatively by use of sensible footwear (properly fitting shoes with low heels, soft upper, and roomy toebox) and orthoses to redistribute mechanical forces
- Surgery is rarely indicated and should be specifically aimed at correcting the abnormal mechanical stresses

#### CALLUS

A callus is a broad based, diffuse area of hyperkeratosis of relatively even thickness, most commonly found under the metatarsal heads. A callus is less circumscribed than a corn, is usually larger, does not have a central core, and may or may not be painful. The terms *tyloma* or *clavus* are sometimes used to denote a callus.

While there is some agreement about labelling large diffuse areas of traumatic plantar hyperkeratosis simply as diffuse plantar callus, there is much confusion in the naming of more discrete localised areas of traumatic hyperkeratosis that occur on the sole of the foot (fig 4).

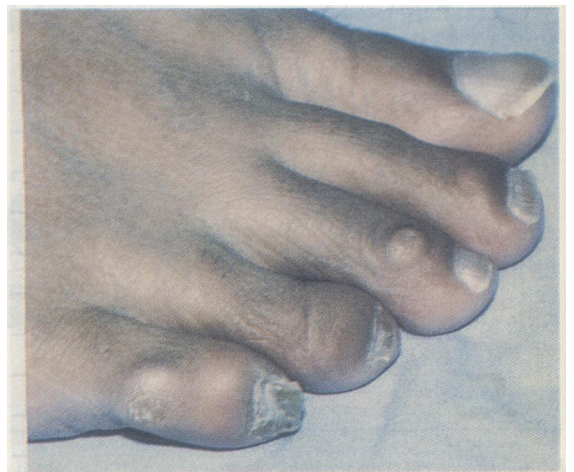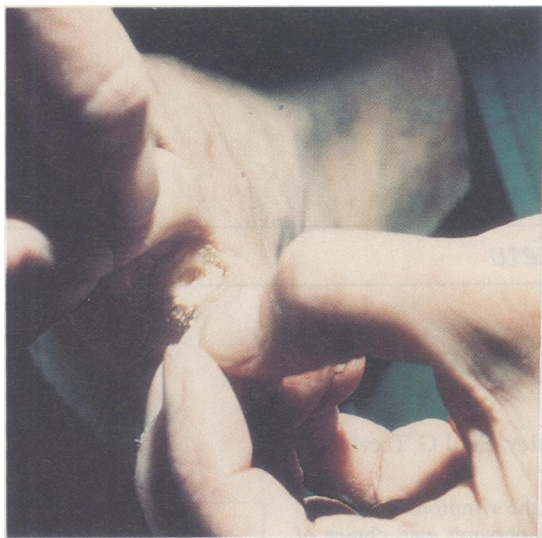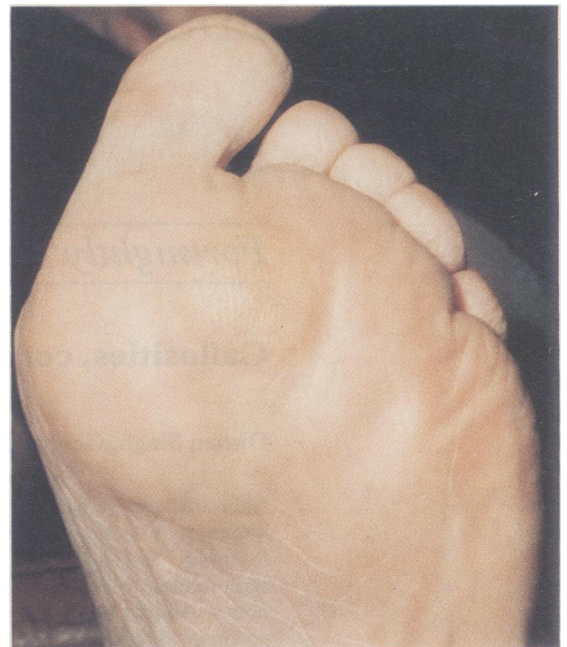


Fig 2—Hard (digital) corns on dorsolateral aspect of fifth toe and dorsum of third toe



**Fig 3**—Soft (interdigital) corn between fourth and fifth toes

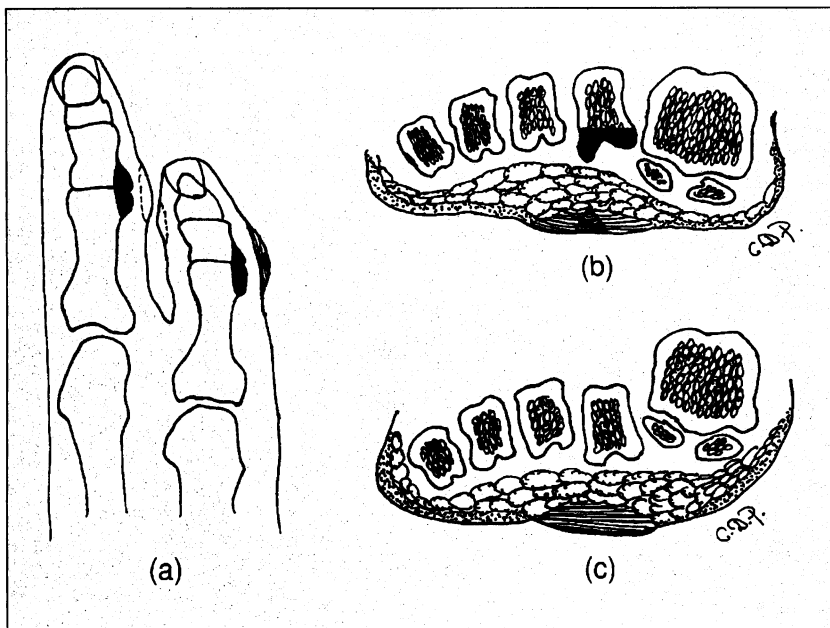
In a classic paper in 1954, Giannestras pointed out that many of these localised lesions had previously been thought to be plantar warts (see below) and coined the term plantar keratosis.<sup>10</sup> Mann and DuVries introduced the term intractable plantar keratosis to denote a symptomatic plantar callosity that does not resolve.<sup>11</sup> This term is popular in North America and is often abbreviated to IPK. These same localised areas are sometimes referred to as plantar callus,<sup>5</sup> tyloma,<sup>5</sup> callosity,<sup>2</sup> plantar corn,<sup>3, 8</sup> plantar heloma,<sup>4</sup> and keratoma.<sup>9</sup> We prefer to use the term plantar corn to denote the small, well localised and painful lesions (found beneath either the tibial sesamoid or a sharp projection of the fibular condyle of a metatarsal head) that contain a central keratin plug. These lesions are usually called focal intractable plantar keratosis in American literature.<sup>12</sup> We use the term localised callus to denote larger lesions usually measuring over 1 cm across, not containing a keratin plug, and caused by misalignment of a metatarsal head. American authors prefer the term diffuse intractable plantar keratosis.<sup>12</sup>



**Fig 4**—Localised callosity under second metatarsal head. Superficial layers should be pared with a scalpel to distinguish between a plantar corn (translucent central core), wart (end arteries), and localised plantar callus (homogeneous appearance)

#### Pathogenesis

Bones of the foot have many projections, especially over the condyles of the heads and bases of the metatarsals and phalanges. Pressure is applied to the skin underlying those bony projections either by a tight shoe or during walking (fig 5). The body attempts to protect the irritated skin by accumulation of the horny layer of the epithelium (callosity), but this accumulation itself causes a prominence that increases the pressure in a tight shoe. Thus, a vicious cycle is generated that may ultimately lead to the keratin plug pressing into the dermis and causing pain. Abnormal mechanical stresses may be extrinsic (from without) or intrinsic (from within). Intrinsic and extrinsic factors are often combined, as in the claw toe—the intrinsic factor is the toe deformity, and the extrinsic factor is the toebox of the shoe.



**Fig 5**—Diagrams showing bony prominences that lead to (a) digital and interdigital corns, (b) plantar corns, and (c) localised plantar callus. Areas shaded black represent the bony resection that may be necessary

#### Factors that may lead to development of callosities

##### Extrinsic factors

- Poor footwear
  - Tight shoe
  - Irregularities in shoe
  - Open shoes
- Activity level
  - Athletes

##### Intrinsic factors

- Bony prominences
  - Prominent condylar projection
  - Malunion of a fracture
- Faulty foot mechanics
  - Cavovarus foot
  - Toe deformity (claw, hammer, mallet)
  - Short first metatarsal
  - Hallux rigidus
  - Transfer lesion from osteotomy or removal of adjacent metatarsal head

**Table 1—Treatments for different callosities**

Callosity	Symptomatic treatment	Shoes	Orthoses	Surgery
Hard digital corn on deformed toe	Remove central core Regular trimming	Soft upper Extra depth Low heeled Stretching	Silicone sleeve	Correct toe deformity
Hard digital corn on fifth toe	Remove central core Regular trimming	Soft upper Wide Stretching	Silicone sleeve	Trim condyles or excision arthroplasty
Interdigital soft corn	Lamb's wool or deflective padding	Soft upper Wide Stretching	Toe spacer	Trim condyles
Plantar corn	Removal central core Regular trimming	Wide Low heeled	Metatarsal pad Insole with metatarsal relief	Condylar arthroplasty
Localised plantar callus	Regular trimming	Extra depth Wide Low heeled	Metatarsal pad Insole with metatarsal relief	Poor results
Diffuse plantar callus	Regular trimming	Cushioning	Cushioning insole	Not indicated

**Diagnosis**

Patients should be asked about their footwear and previous treatments (such as osteotomies, orthoses, etc). Patients' gait should be observed, and the alignment of their feet should be examined for faulty mechanics (cavovarus foot, etc). The location and characteristics of the keratotic lesions should be noted, and they should be palpated to assess which bony prominence is involved. Radiographs of weightbearing feet are useful for identifying bony prominences. Pressure studies (pedobarographs) may help to define the exact location of increased plantar pressure and to differentiate between transfer lesions and lesions caused by direct pressure.

Verrucas and plantar corns are best distinguished by careful paring of the thickened stratum corneum with a sharp scalpel blade. As the cornified layer of skin over a verruca is removed, the end arteries appear—there may be punctate bleeding, or black dots may be visible if the end arteries are thrombosed.

**Treatment**

It should always be remembered that callosities are signs of increased mechanical stress rather than an actual disease. The principles of treatment should therefore be to (a) provide symptomatic relief, (b) determine the mechanical aetiology, (c) formulate a conservative management plan by advising on footwear and prescribing orthoses, and (d) consider surgery if conservative measures fail (table 1).

**SYMPTOMATIC RELIEF**

Callosities may be acutely painful because of pressure of the central keratin plug on underlying nerves in the papillary layer. Paring the lesion with a sharp number

22 scalpel and removing the central keratin plug—with a local anaesthetic if necessary—provides almost complete pain relief. Recurrence can be prevented by weekly gentle trimming with a pumice stone or emery board after soaking the lesion in warm water for 20 minutes. Some patients prefer to use a motorised sandpaper disc if there are several lesions or a large lesion, while others benefit from regular paring by a podiatrist or chiropodist. An emollient cream can be useful for softening the skin. Patients who present with a plantar callus (localised or diffuse) that is not painful or tender and whose only complaint is of the cosmetic appearance of the callus need only to be advised to use a pumice stone regularly after soaking the foot in warm water.

Silicone sleeves (fig 6) provide good pain relief by cushioning and by slow release of mineral oil to soften the keratotic lesion. Careful application of dilute solutions of keratolytic agents (such as 10-15% salicylic acid) or pads containing keratolytic agents are sometimes beneficial, but overzealous applications of concentrated solutions (such as 40% salicylic acid) may cause chemical burns. For a painful soft interdigital corn, padding the web space with lamb's wool or deflective padding will often provide relief and will usually induce healing of the maceration.

We do not recommend the subcutaneous injection of bovine collagen<sup>4</sup> or fluid silicone<sup>5</sup> advocated by some podiatrists as it fails to address the primary problem and may induce an immune reaction. The intralesional use of triamcinolone<sup>3</sup> or chymotrypsin<sup>5</sup> may even increase the mechanical pressure by thinning the skin. It seems unnecessary to prescribe high doses of oral vitamin A as


**Distinguishing features of warts and plantar corns**

*Wart*

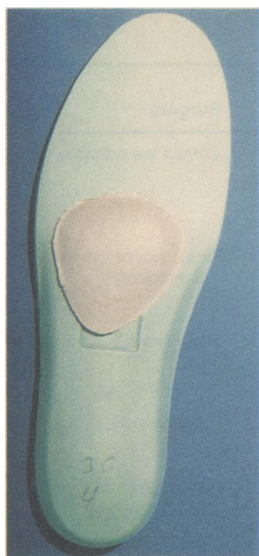
- Relatively rapid onset
- May or may not be under bony prominences
- Skin lines pass around lesion
- Maximum pain with squeezing side to side
- End arteries visible on paring
- Rapid recurrence after shaving and padding

*Plantar corn*

- Develops over months or years
- Localised under bony prominences
- Skin lines pass through lesion
- Maximum pain with direct pressure
- No end arteries visible on paring
- Slower recurrences at least a week after shaving



**Fig 6—Silicone sleeve for symptomatic relief from hard digital corn**



**Fig 7**—Metatarsal pad to provide relief from painful callosities under metatarsal heads

an antikeratotic drug<sup>3</sup> as it may lead to a raised intracranial pressure.<sup>3</sup> Similarly, local excision of the corn without simultaneous removal of the protuberant bone has a high risk of recurrence as well as a risk of sinus formation and osteomyelitis.

#### FOOTWEAR

Tight shoes are the main cause of most callosities—corns are merely the symptoms of “shoe disease” and do not occur in people who walk barefoot. Patients must be advised to wear low heeled shoes with a soft upper and a roomy toebox is imperative. Extra depth is needed to accommodate corns on deformed toes (such as hammer or claw toes), and extra width is needed for corns on the lateral aspect of the fifth toe and interdigital soft corns. Shoes may also be stretched by a cobbler to relieve mechanical pressure on a lesion. Irregularities in a shoe such as a poorly positioned seam or stitching may be responsible for mechanical irritation on a fifth toe. Sometimes a shoe modification by an orthotist may be necessary—such as a medial wedge for a cavovarus foot.

Conversely, shoes that are too loose (such as unlaced trainers and open backed sandals) may induce shearing forces on the edges of the weight bearing area of the sole of the foot to produce the so called “marginal callus” or “heel fissures.”

#### ORTHOSSES

As a hyperkeratotic lesion will always recur unless the mechanical stress is removed, orthoses are useful in redistributing forces to allow the lesion to heal. Doughnut shaped corn pads, heloma shields, and silicone toe splints are available to relieve pressure from the tender central core in corns. An interdigital wedge made of plastazote or a silicone orthodigital splint will promote healing of an interdigital soft corn.

In the case of a localised plantar callus a metatarsal pad placed proximal to a prominent metatarsal head will reduce the pressure of the metatarsal head on the underlying skin (fig 7). Placement of the adhesive metatarsal pad in the shoe can be helped by applying lipstick to the callus as a guide. It is best to start with a thin pad and to build it up gradually. A ready made full length shoe inlay of padded leather or plastazote may sometimes provide better relief and can be moved from shoe to shoe. A customised shoe inlay of vacuum moulded plastazote with added metatarsal relief is best at relieving pressure but can only be worn in extra depth shoes and cannot be worn in most dress shoes.

#### SURGICAL PROCEDURES

Surgery to remove bony prominences or change the mechanics of the foot is indicated only if all conservative measures have failed. Surgical correction of a claw toe, hammer toe, or mallet toe will heal a corn on the deformed toe.<sup>6</sup> Hard corns on the fifth toe and soft interdigital corns can be treated by resection of the prominent condyles<sup>6</sup> or excision arthroplasty of the proximal interphalangeal joint of the fifth toe (fig 5). Syndactylisation of the web space between the fourth and fifth toes is rarely indicated.

Localised painful plantar keratoses on the ball of the foot (a common cause of metatarsalgia) require careful study of radiographs and pedobarographs to allow identification of bony prominences and transfer lesions. Many patients have been harmed by failure to diagnose a transfer lesion so that operation on one metatarsal then leads to problems with the next metatarsal head and so forth. A modified DuVries metatarsal condylectomy<sup>7</sup> is preferable to excision of the metatarsal head for a plantar corn. Patients with multiple callosities under the metatarsal heads are best managed conservatively as surgery “to level the tread” is contraindicated: metatarsal shortening and excision of the metatarsal head or the floating osteotomies have unpredictable results and may lead to the development of transfer lesions.<sup>2</sup>

#### Summary

Inappropriate shoes, abnormal foot mechanics, and high levels of activity produce pressure and friction that lead to corns and calluses. Most lesions can be managed conservatively by proper footwear, orthoses, and, if necessary, regular paring. The lesions usually disappear when the causative mechanical forces are removed. Surgery is rarely indicated and should be specifically aimed at correcting the abnormal mechanical stresses.

We thank Mr John Michael, podiatrist at the Royal National Orthopaedic Hospital, for providing some of the photographs, and Mrs Colleen Power for the drawings.

- 1 Baker H. Common skin disorders. In: Klenerman L, ed. *The foot and its disorders*. 3rd ed. Oxford: Blackwell Scientific Publications, 1991: 113-22.
- 2 Klenerman L, Nissen KI. Common causes of pain. In: Klenerman L, ed. *The foot and its disorders*. 3rd ed. Oxford: Blackwell Scientific Publications, 1991: 93-111.
- 3 Arnold HL, Odom RB, James WD. *Andrews' diseases of the skin: clinical dermatology*. Philadelphia, PA: WB Saunders, 1990: 44-6.
- 4 Whiting MF. Skin and subcutaneous tissues. In: Lorimer DL, ed. *Neale's common foot disorders: diagnosis and management: a general clinical guide*. 4th ed. Edinburgh: Churchill Livingstone, 1993: 93-121.
- 5 Yale JF. *Yale's podiatric medicine*. 3rd ed. Baltimore, MD: Williams and Wilkins, 1987.
- 6 Coughlin MJ, Mann RA. Lesser toe deformities. In: Mann RA, Coughlin MJ, eds. *Surgery of the foot and ankle*. 6th ed. St Louis, MO: CV Mosby, 1993: 341-411.
- 7 Mann RA, Coughlin MJ. Keratotic disorders of the plantar skin. In: Mann RA, Coughlin MJ, eds. *Surgery of the foot and ankle*. 6th ed. St Louis, MO: CV Mosby, 1993: 413-65.
- 8 Richardson GE. Lesser toe abnormalities. In: Crenshaw AH, ed. *Campbell's operative orthopaedics*. St Louis, MO: CV Mosby, 1992: 2729-56.
- 9 Regnauld B. *The foot: pathology, aetiology, semiology, clinical investigation and therapy*. Berlin: Springer-Verlag, 1986.
- 10 Giannestras NJ. Shortening of the metatarsal shaft for the correction of plantar keratosis. *Clin Orthop* 1954;4:225-31.
- 11 Mann RA, DuVries HL. Intractable plantar keratosis. *Orthop Clin North Am* 1973;4:67-73.
- 12 Mann RA. Intractable plantar keratoses. *Instructional course lectures of the AAOS*. St Louis, MO: CV Mosby, 1984: 287-301.

#### Correction

##### Recent advances in medical genetics

A typesetters' error occurred in this article by John R W Yates (20 April, pp 1021-5). The first point of the summary box should read “over 60 disease genes were isolated in 1995” [not 1955].