

Clinically significant pulmonary barotrauma after inflation of party balloons

Andrew D Mumford, Keyoumars Ashkan, Stuart Elborn

Although pneumothorax is the commonest presentation of pulmonary barotrauma unrelated to mechanical ventilation, systemic air embolism and emphysema within the pulmonary interstitium, mediastinum, retroperitoneum, pericardium, and subcutaneous tissues have all been described.¹ We report a case of pulmonary barotrauma after inflation of party balloons.

Case report

A 24 year old previously healthy, non-smoker presented with a 48 hour history of a sensation of crackling under the skin. His symptoms were initially confined to the neck but within 24 hours had affected his chest wall, trunk, and legs. The next day he developed retrosternal pleuritic chest pain and attended the accident and emergency department. He reported that 24 hours before the onset of symptoms he had inflated about 20 party balloons over one hour. He had not experienced chest pain or shortness of breath at the time or immediately afterwards.

On presentation his temperature was 38°C, his heart rate was 140 beats/minute, he was normotensive, and his arterial oxygen saturation was 98% while breathing room air. Subcutaneous emphysema was present over his shoulders, chest, abdominal wall, and in the neck to the angle of the jaw, and it extended anteriorly into his legs and the arms. Subcutaneous air was palpable over his whole back and buttocks. There was good air entry into both lungs and a loud crunching sound audible over the precordium synchronous with the heart sounds (Hamman's sign). Plain chest radiographs showed extensive subcutaneous emphysema in the neck and chest wall pneumomediastinum and pneumopericardium (fig 1). Computed tomography also showed large collections of air in the retroperitoneum and superior mediastinum. Lung texture was normal, and there were no bullae. There was no leakage of ingested contrast medium from the oesophagus during barium swallow examination. He was given intravenous antibiotics, fluids, and analgesics, and radiographs showed complete resolution of his emphysema after 10 days. Four weeks after admission respiratory symptoms had resolved and lung function tests showed no underlying lung abnormalities.

Six balloons identical with those he had inflated were analysed in the lung function laboratory. A mean pressure of 64 (SE 0.73) cm H₂O was required to initiate inflation, but thereafter a pressure of 40 cm H₂O was required. Each balloon comfortably held 6 litres of air before rupturing. In a demonstration of his technique the patient inhaled to maximum inspiratory capacity and then rapidly exhaled into the balloons to maximum expiratory capacity, inflating a balloon in two or three such manoeuvres.

Comment

Extra-alveolar air in subcutaneous tissues and mediastinum may accumulate after damage to alveoli. Increases in intra-alveolar pressure or decreases in perivascular interstitial pressure may rupture alveoli and result in interstitial emphysema in the lung periphery. As mean interstitial pressure in the mediastinum is usually lower than in the lung periphery air may dissect proximally along the bronchovascular sheath to the mediastinum.²

Increased alveolar pressure caused by straining against a closed glottis is associated with alveolar

rupture when a strong expiratory effort is applied at the maximum inspiratory capacity, as occurs in the Valsalva manoeuvre.³ This may explain the apparent ease with which extra-alveolar air may develop after voluntary Valsalva manoeuvres during smoking of marijuana or cocaine.⁴

Similar pathophysiological mechanisms may underly pulmonary barotrauma during mechanical ventilation. Subcutaneous emphysema and pneumothorax occur in 5-15% of such patients.⁵ Predisposing factors include high peak inflation pressure, high tidal volume, and pre-existing lung disease. Maximum inflation pressures of 30-80 cm H₂O carry considerable risk of alveolar rupture.³ To initiate balloon inflation our patient generated airway pressures of 64 cm H₂O on each occasion. He probably sustained alveolar rupture during expiration early in the course of inflation, with large quantities of extra-alveolar air being forced into the pulmonary interstitium during subsequent inflations. This later became clinically apparent as extensive subcutaneous, mediastinal, and retroperitoneal emphysema. This case shows that significant pulmonary barotrauma can occur after seemingly innocuous respiratory manoeuvres and is not confined to patients with pre-existing lung disease.

We thank Mr Michael Saunders, Pulmonary Function Unit, Llandough Hospital, for his analysis of the balloons, and Professor L K Borysiewicz for permission to report this case.

Funding: None.

Conflict of interest: None.

- 1 Janz MA, Pierson DJ. Pneumothorax and barotrauma. *Clinics in Chest Medicine* 1994;15:75-91.
- 2 Maunder RJ, Pierson DJ, Hudson LD. Subcutaneous and mediastinal emphysema. *Arch Intern Med* 1984;144:1447-53.
- 3 Varkey B, Kory RC. Mediastinal and subcutaneous emphysema following pulmonary function tests. *Am Rev Respir Dis* 1973;108:1396.
- 4 Goldberg RE, Lipuma JP, Cohen AM. Pneumomediastinum associated with cocaine abuse: a review of the literature. *J Thorac Med* 1987;2:88-9.
- 5 Parker JC, Hernandez LA, Peevy KJ. Mechanisms of ventilator-induced lung injury. *Crit Care Med* 1993;21:131-43.

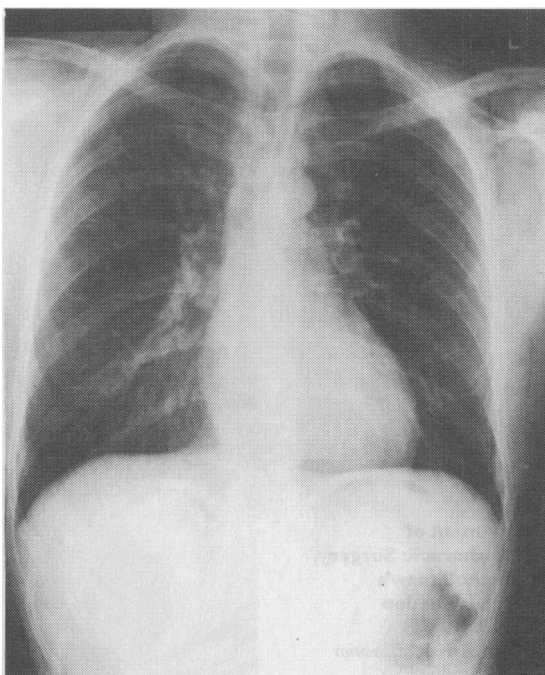


Fig 1—Plain chest radiograph showing widespread subcutaneous and mediastinal emphysema

Department of Medicine,
University Hospital of
Wales, Cardiff CF4 4XN
Andrew D Mumford, senior
house officer
Keyoumars Ashkan, house
officer

Respiratory Investigation,
Level 11, Belfast City
Hospital, Belfast BT9 7AB
Stuart Elborn, consultant
physician

Correspondence to:
Dr Elborn.

BMJ 1996;313:1619