

New techniques in medicine

Unravelling the helix – a physician's guide to spiral computed tomography

S E Kearney, C J Garvey

Summary

The introduction of spiral technology to computed tomography (CT) scanners in the late 1980s has revolutionised the field of CT. Spiral CT offers definite practical benefits over conventional scanners and has expanded the role of CT through the development of new scanning techniques. CT scanning now rivals magnetic resonance imaging in many areas of investigation, and for some situations is the clear investigation of choice. This review is aimed at those clinicians who have access to spiral scanning services but wish to have a greater understanding of the technique and its clinical applications. The concept of spiral CT, and the differences between spiral and conventional scanning are discussed. The various clinical applications of the technique are illustrated.

Keywords: computed tomography

Applications where spiral CT offers major practical benefits

Thoracic

- pulmonary embolism
- assessment of hilar disease
- tracheobronchial abnormalities
- assessment of small pulmonary nodules
- diaphragmatic lesions
- aortic disease

Abdominal

- assessment of liver metastases
- staging of aortic aneurysm
- renal artery stenosis

Miscellaneous

- assessment of complex bone/face trauma
- extracranial carotid disease

Box 1

Department of Radiology,
Royal Liverpool University Hospital,
Prescot Street, Liverpool L7 8XP, UK
S E Kearney
C J Garvey

Correspondence to Dr Garvey

Accepted 27 June 1997

In many clinical situations, the capabilities of magnetic resonance imaging (MRI) clearly surpass those of computed tomography (CT). Previously this led to a widely held belief that MRI would rapidly replace CT in most of its applications. A major advance in CT technology occurred in the late 1980s, namely, the development of spiral scanners. Spiral CT scanners offer definite practical benefits over conventional scanners and, in certain areas, are able to surpass MRI (table). As a result spiral CT is now recognised to be the most appropriate investigation in a range of existing applications. Moreover, spiral technology has allowed CT to be applied to new areas of investigation that were not previously possible (box 1).

Before discussing the benefits of spiral CT however, it is first important to understand certain limitations of conventional scanners.

Conventional CT – problems and limitations

In all CT scanners, X-ray tubes and/or detectors are mounted on a rotating gantry. By rotating this tube/detector array around the patient, the scanner is able to acquire transverse (axial) images. The mechanics of the electrical cables in conventional scanners limits the number of rotations that are possible in any cycle. Thus, after a limited number of clockwise or anti-clockwise rotations, the scanner must stop and rotate in the opposite direction. It is not possible therefore, for a standard CT scanner to rotate continuously. Instead, a series of intermittent scans are made, between which the patient is advanced a fixed distance through the scanner (figure 1A). In standard CT therefore, images are obtained precisely as they appear on the X-ray film, ie, as a series of axial 'slices', commonly 1 cm thick, taken at fixed intervals.

Since it is necessary to advance the patient through the scanner between each stationary slice, the total time required to complete the scan is much greater than would be needed if scanning were continuous. Furthermore, the position of the transverse sections is determined in advance and small lesions can therefore 'fall between' two adjacent slices. Although neither aspect may at first seem to be of major importance, in fact both these factors impose significant limitations on the use of CT (summarised in box 2).

Spiral CT – a 'simple' solution

In spiral CT scanners the standard cable connections are replaced by slip-ring electrical contacts which allow the X-ray tubes and detectors to be rotated continuously for the entire duration of the scan. This 'simple' advance forms the basis of spiral CT. The ability of spiral CT scanners to rotate continuously, means a patient can be advanced continuously through the rotating scanner. As a result, image data is acquired not in the form of a series of transverse slices, but instead as a continuous spiral (or more accurately a helix) (figure 1B). This helical data is then reformatted so that images are displayed as axial slices that are indistinguishable in practical terms from those of conventional CT.

Despite the apparent similarity of the final image, both the speed with which scans can be performed, and the manner in which a spiral scanner acquires data, offer major practical benefits.

ADVANTAGES OF SPIRAL CT – BENEFITS ARISING FROM INCREASED SPEED

Since the patient moves continuously through the scanner, the 'inter-scan time' required to re-position the patient between slices is eliminated and scan times are considerably shortened. The benefits of this shorter total scan time are considerable.

Limitations of standard CT technology
<ul style="list-style-type: none"> ● interscan time: overall scanning is slowed by the requirement to re-position the patient between each successive slice ● misrepresentation: respiratory movement may cause areas to be scanned twice or missed completely ● contrast dispersal: prolonged scan times mean that it is difficult to maintain high levels of contrast agents in the vessels ● partial volume: small lesions lying between slices rather than within a single slice may be difficult to detect

Box 2

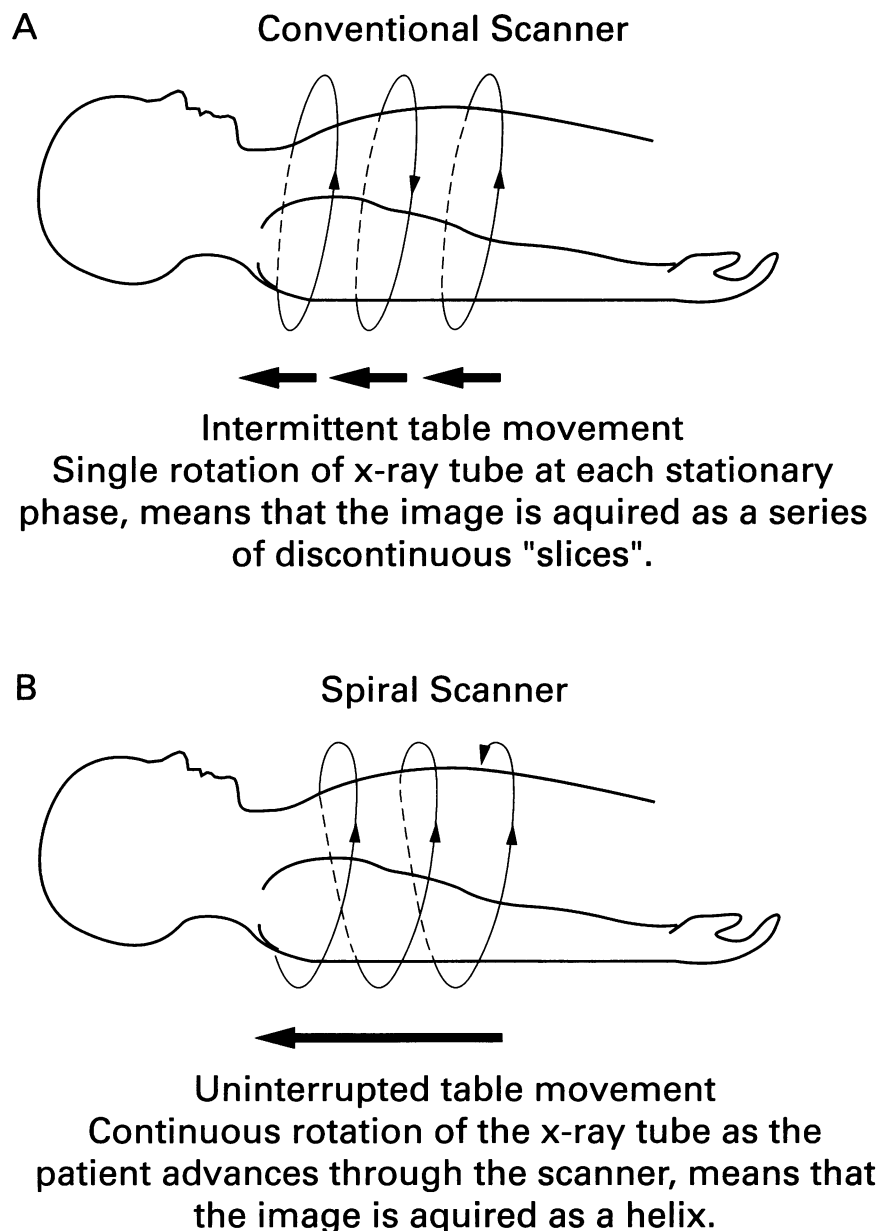


Figure 1 Differences between conventional and serial CT scanners

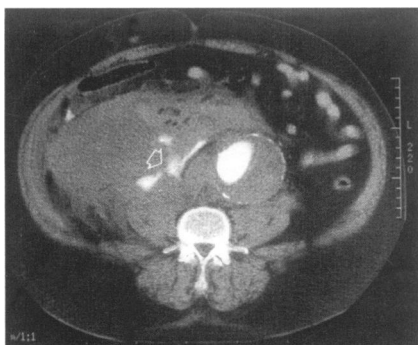


Figure 2 Actively bleeding abdominal aortic aneurysm. The aortic aneurysm is clearly seen to contain freshly injected contrast (white). Most of the surrounding soft tissue (grey) represents haematoma. Within the haematoma there is a 'spurt' of recently injected intravenous contrast (arrow) indicating acute bleeding. The ability of the scanner to capture such a 'spurt' is a clear indication of the speed with which images can be acquired

Reduced dispersal of contrast due to shortened scan times – enhanced vascular contrast
The rapid scanning speed offered by spiral CT allows a high intensity of vascular contrast to be achieved from a single intravenous bolus injection. Moreover, this high contrast can be maintained throughout the entire duration of the scan. As a result, spiral CT not only achieves superior vascular opacification, it also requires significantly less contrast to do so. This ability to detect and rapidly follow injected contrast is well illustrated by figure 2. In this scan of an acutely bleeding aortic aneurysm, the speed with which the scanner was able to trace the injected contrast is clearly demonstrated by the 'spurt' of fresh contrast, caught as it was ejected through the ruptured arterial wall into an existing haematoma (arrow).

Examples like the one above are fortunately rare. In more standard radiological practice, specific vascular contrast is employed for two purposes: firstly, to improve delineation of normal anatomy and its relationship to any abnormal structures; secondly, to identify specific vessels in order to distinguish them from surrounding or adjacent structures of similar radiodensity.

An example of how the clear delineation of normal anatomy can highlight abnormal appearances is given in figure 3. In this spiral scan of liver, contrast is used to illustrate the hepatic vasculature, and allows the abnormal dilated bile ducts to be clearly visualised. The second example demonstrates the importance

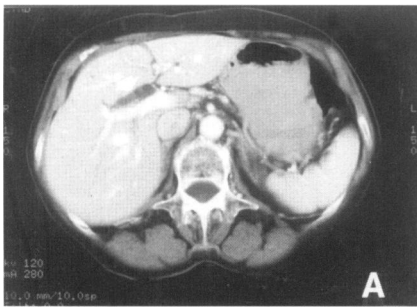


Figure 3 Bile duct dilatation. The dilated proximal common duct (arrow) is well demonstrated. The duct is clearly differentiated from the adjacent portal vein which appears white due to the injected contrast

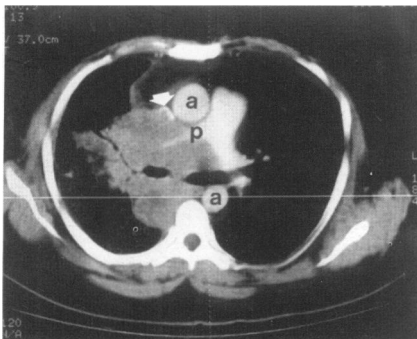


Figure 4 Involvement of local structures by malignant tumour. The mediastinal mass appears dark grey and clearly extends into the right lung. The injected contrast has rendered three vascular structure clearly visible. The two parts of the aorta (a) are not involved by tumour. The right pulmonary artery (p) is markedly compressed while the superior vena cava (arrow) is almost obliterated

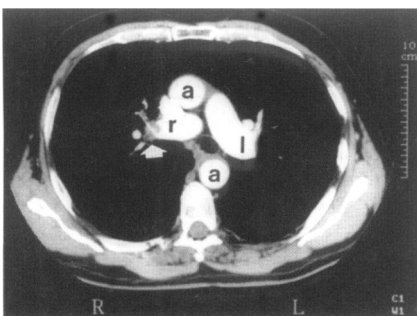


Figure 5 Pulmonary embolus. Injected contrast is present in the ascending and descending aorta (a). Contrast also delineates the right and left pulmonary trunks (r and l, respectively). In the right pulmonary artery and lobar vessel there is unenhanced soft tissue (arrow). This grey tissue represents thrombus

Table A comparison of the relative practical merits of CT and MR

	CT	MRI
Soft-tissue definition	moderate	excellent
Spatial resolution	very good	good
Total scan time	short	long*
Movement artifact	little problem	may degrade image in some areas
Radiation exposure	may be high	nil

* There are now sequences available which can image an organ such as the liver in less than a minute. However a complete MR examination requires a series of sequences and as such the total scan time is much greater than CT.

of accurately distinguishing vessels from other tissues. In figure 4, a vessel is seen to be encased by a mass of tumour; in this case the high levels of contrast achieved within the vessel allow it to be distinguished from the surrounding tumour mass, and allow encasement to be readily detected.

Improved confidence in detecting small lesions in lung/liver – avoidance of misrepresentation

In spiral scanners, areas such as lung or liver can be scanned within a single breath hold. This effectively eliminates the respiration-induced 'misrepresentation' (explained in box 2). For this reason, diagnostic confidence for small lesions is greatly increased.¹

Visualising thrombus within the vascular tree – detection of pulmonary emboli

One new area of investigation made possible by the advent of spiral scanners is the detection of pulmonary embolus. The rapidity with which a spiral scanner can image the pulmonary vascular tree means that high levels of intravenous contrast can be maintained in the pulmonary vessels for the entire duration of the scan. Pulmonary emboli are diagnosed as non-opacified filling defects within the vessel (figure 5). Studies have shown that the technique has a high sensitivity and specificity for the diagnosis of pulmonary embolus involving second to fourth order arteries.² It is likely that CT will be increasingly used in this particular application.

ADVANTAGES OF SPIRAL CT – BENEFITS ARISING FROM ACQUIRING DATA AS A SPIRAL

The acquisition of data as a spiral offers an additional advantage. While conventional CT holds data only for a series of redefined axial slices, a spiral scanner acquires data for the entire 3-D volume encompassed by the spiral.

Constructing new images to improve the visibility of lesions – avoidance of partial volume

Since a spiral scanner holds data for the entire volume encompassed by the spiral, the radiologist can retrospectively reconstruct slices at any point within that spiral. One advantage of this ability to reconstruct 'new' slices is that the problem of 'partial volume' can be effectively overcome. The term 'partial volume' refers to a major problem whereby a small lesion may not lie precisely within a single axial slice, instead it may feature partly on two adjacent slices. Since CT scanners average the data within each slice, partially sampled lesions are often poorly visible. In spiral scanners, if a partially sampled lesion is suspected the stored spiral data can be used to construct a 'new' slice positioned precisely at the centre of any suspected lesion, this will often greatly enhance the visibility of such a lesion (figure 6).

Reformatting images to provide optimal visibility – the use of multiplanar and 3-D reconstruction

The most instantly impressive aspect of spiral scanners is their superior ability to re-format images. Computer software is used to reprocess axial image data into high quality coronal, sagittal, oblique, or 3-D formats. Although such formats impart no information that is not already present on standard axial views, by presenting images in a clearer manner the information can often be better appreciated.

The practical value of such reconstructions is currently being assessed in a range of applications.³⁻⁶ However, multiplanar and 3-D formats are already finding increasing use in applications where it is important to appreciate clearly the relationship of a lesion to its surrounding anatomical structures.

The following examples help illustrate the areas in which multiplanar and 3D reformats can be of benefit. Figure 7 shows a multiplanar reconstruction of liver involved by metastatic disease; spiral CT provides appropriate oblique

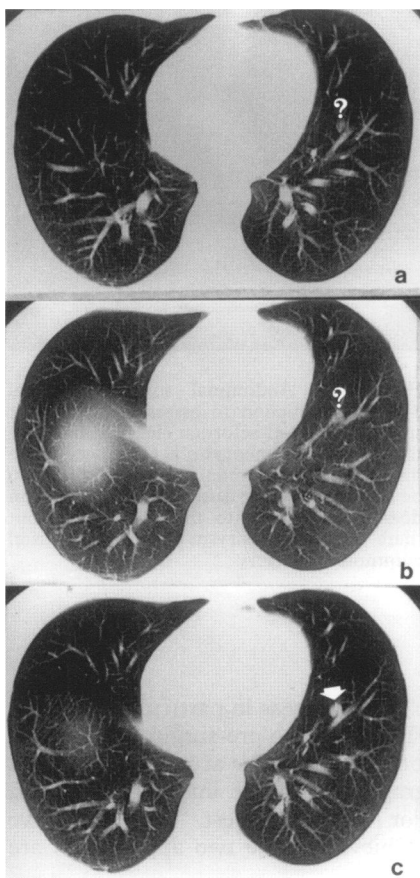


Figure 6 Axial reconstructions improve the visibility of small lung nodules. When a lesion is small (<1 cm) it may fall between two adjacent scans and as a result may not be clearly demonstrated. Two successive slices (a and b) suggested the presence of a small lung nodule. A retrospective axial reconstruction was made of the area between a and b. This confirmed that a nodule was present (c)

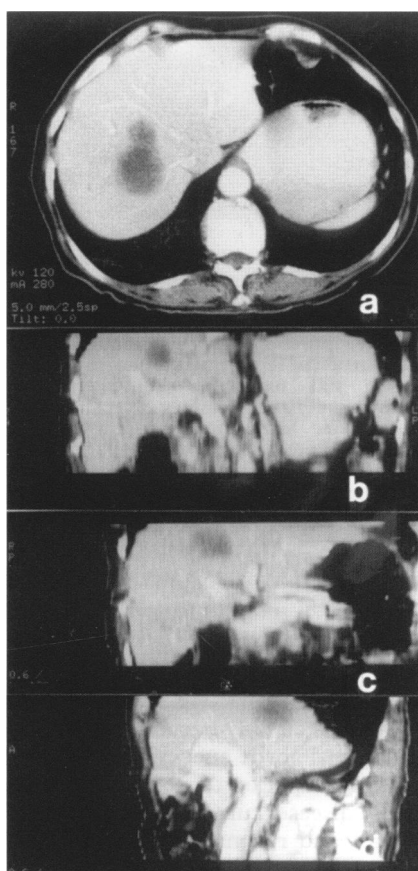


Figure 7 Multi-planar reconstructions (MPRs) demonstrate the anatomical relationships prior to possible surgical resection. A lobulated low attenuation metastasis is present on the axial scan a. MPR (b,c,d) show the anatomical relationships of the lesion and in particular its relationship to the portal and hepatic veins which are important surgical landmarks

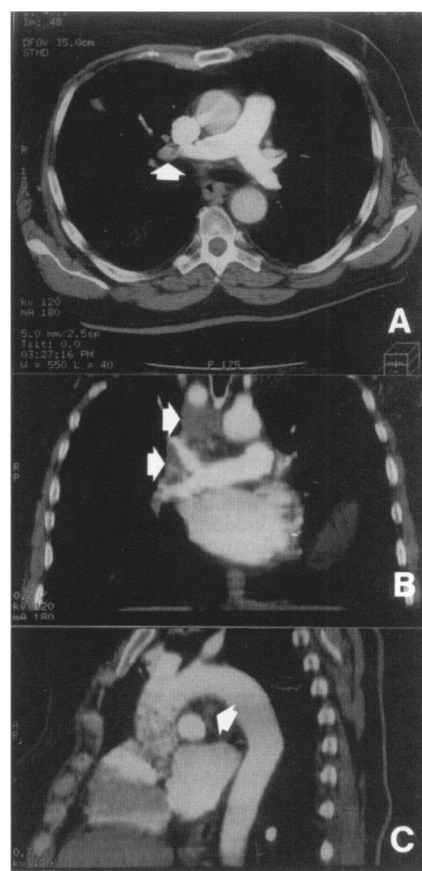


Figure 8 MPR demonstrate hilar and mediastinal lymphadenopathy clearly. The subtle right hilar abnormality seen on the axial scan A (arrow), is more easily appreciated on the coronal reformat B, as abnormal soft tissue between the right upper and lower pulmonary arteries. Lymphadenopathy is also demonstrated in the right paratracheal area, (scan B) and within the aortopulmonary window (scan C)

reconstructions that allow the position of the deposit and its relation to portal and hepatic veins to be appreciated. Such information has clear value to a surgeon considering limited resection.

Multiplanar reformats have a number of applications within the thorax.⁷ Hilar disease can be more easily appreciated, as demonstrated in figure 8.⁸ The technique is capable of revealing detailed bronchial anatomy and as a result is effective in diagnosing diseases of the airways. Figure 9 demonstrates an endobronchial tumour in the left upper lobe bronchus which was confirmed by bronchoscopy. Diseases of the vessels, such as aortic dissection, are well demonstrated.⁹ Figure 10 shows the multiplanar and 3-D reconstruction of a dissection. Such reconstructions are very valuable when assessing the type, extent and therefore operability of such lesions.

Combining need and reformatting – CT angiography

It has been emphasised in previous sections that the speed, and hence improved contrast handling, of spiral CT allows vessels to be clearly visualised. This means that, in addition to the previously discussed advantages of vessel delineation, angiography by CT becomes possible. There are two reasons why the ability to perform angiography by CT should be considered a very major advance. First, images of vessels can be reconstructed into different planes or into 3-D; this greatly enhances the ability to visualise vessel disease with obvious advantages for the surgeon. Second, CT angiography can often avoid the need for arterial catheterisation; as a result the possible complications of cannulating diseased vessels are considerably lessened.

CT angiography may potentially be applied to many different existing angiographic applications and comparisons with conventional studies are

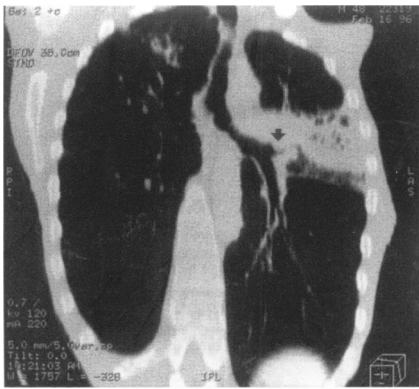

Figure 9 Coronal reconstruction of the left bronchus showing an endobronchial lesion. There is consolidation of the anterior segment of the left upper lobe with cavitation. This consolidation results from the growth of an endobronchial lesion which is clearly seen obstructing the upper lobe bronchus just beyond its origin (arrow)

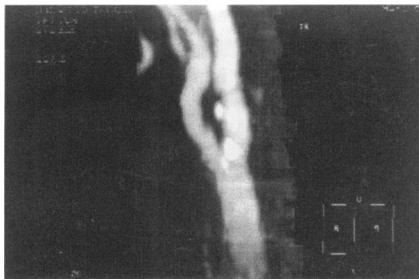


Figure 12 Reconstruction of carotid artery to assess extracranial internal carotid disease. In this scan a reconstruction has been made of the carotid vessels at the level of bifurcation. Several calcified plaques are seen within the proximal internal carotid, and there is some irregularity of the vessel wall, however the examination demonstrates that there is no significant stenosis

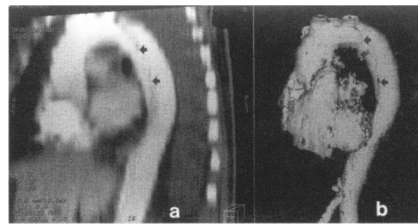


Figure 10 Aortic dissection, coronal and 3-D reconstructions. On the coronal reconstruction (a) the dissection (arrow) can be seen extending from the left subclavian origin to just above the diaphragm. The 3-D reconstruction represents the contents of the vessel, and has been constructed by removing all tissue elements except the high attenuation intravenous contrast. The resulting image therefore reveals contours within the vessel, and the position and extent of the dissection is clearly shown

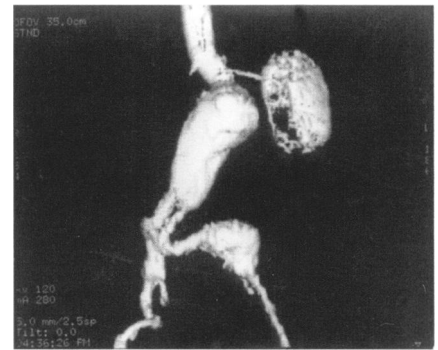


Figure 11 Abdominal aortic aneurysm, 3-D reconstruction to assess suitability for surgery. The 3-D reformat clearly shows that the neck of the aneurysm is at an acceptable distance below the renal artery, allowing it to be clamped during surgery. The aneurysm does not extend into the iliac vessels but there is a focal aneurysm of the left distal common iliac artery

actively taking place in a number of areas.¹⁰ In two areas in particular CT angiography is already becoming established. These are the pre-surgical imaging of abdominal aortic aneurysm, where it has been shown to be at least as good and possibly superior to conventional angiography,¹¹ and the imaging of carotid artery disease, currently the subject of major research interest.¹² The impressive images and reconstructions that can be achieved in the two applications are illustrated by figures 11 and 12.

The future

Spiral CT has clearly revived the flagging fortunes of CT. For the present therefore, CT is not only holding its own against MRI in a number of areas, its role is being extended into new areas. Will this be maintained?

In the long-term the answer to this question is uncertain and it depends largely on how rapidly MRI technology develops and becomes integrated into radiology departments. There is no doubt that fast MRI is possible. Breath-hold techniques, dynamic contrast-enhanced MRI sequences and, more recently echoplanar imaging, which allows images to be acquired in less than a second, are becoming available. Unfortunately, such technology is presently very expensive.

In the short-term therefore, it seems likely that spiral CT is likely to assume an increasing importance. This is particularly true with regard to its angiographic applications, where CT will probably replace standard angiography in many areas. It is also true of 3-D reconstruction. Such reconstructions seem likely to assume an increasing importance in medicine, both in the imaging of disease and potentially in practical areas involving 'virtual reality'. The ability of spiral scanners to provide rapid and detailed reconstructions mean they are increasingly likely to be used in this manner.

1 Buckley JA, Scott WW Jr, Siegelman SS, *et al*. Pulmonary nodules: effect of increased data sampling on detection with spiral CT and confidence in diagnosis. *Radiology* 1995;196:395-400.
2 Remi-Jordan M, Remy J, Wattinne L. Central pulmonary thromboembolism: diagnosis with spiral volumetric CT with the single breath hold technique. Comparison with pulmonary angiography. *Radiology* 1992;185:381-7.
3 Lacrosse M, Trigaux JP, Van-Beers BE, Weynants P. 3D spiral CT of the tracheobronchial tree. *J Comput Assist Tomogr* 1995;19:341-7.
4 Brink JA, Heiken JP, Semenkovich J, Teefey SA, McClennan BL, Sagel SS. Abnormalities of the

diaphragm and adjacent structures: findings on multiplanar spiral CT scans. *AJR* 1994;163:307-10.

5 Bluemke DA, Urban B, Fishman EK. Spiral CT of the liver: current applications. *Semin Ultrasound CT MR* 1994;15:107-21.

6 Luka B, Brechtelsbauer D, Gellrich NC, Konig M. 2D and 3D CT reconstructions of the facial skeleton: an unnecessary option or a diagnostic pearl? *Int J Oral Maxillofac Surg* 1995;24:76-83.

7 Costello P. Spiral CT of the thorax. *Semin Ultrasound CT MR* 1994;15:90-106.

8 Remy-Jardin M, Duyck P, Remy J, *et al*. Hilar lymph nodes: identification with spiral CT and

histologic correlation. *Radiology* 1995;196:387-94.

9 Costello P, Ecker CP, Tello R, Hartnello GG. Assessment of the thoracic aorta by spiral CT. *AJR* 1992;158:1127-30.

10 Rubin GD, Dake MD, Semba CP. Current status of three-dimensional spiral CT scanning for imaging the vasculature. *Radiol Clin North Am* 1995;33:51-70.

11 Costello P, Gaa J. Spiral CT angiography of abdominal aortic aneurysms. *Radiographics* 1995;15:397-406.

12 Schwartz RB. Neuroradiological applications of spiral CT. *Semin Ultrasound CT MR* 1994;15:139-47.