

## Short reports

# Lymphogranuloma venereum as a cause of rectal strictures

Savvas Papagrigoriadis, John A Rennie

### Summary

**Rectal strictures are uncommon in young patients without a history of malignancy, inflammatory bowel disease or previous surgery. Lymphogranuloma venereum of the rectum has been described as a rare cause of rectal strictures in the western world, mainly in homosexual men and in blacks. It presents with nonspecific symptoms, rectal ulcer, proctitis, anal fissures, abscesses and rectal strictures. Clinical and endoscopic findings as well as histology resemble Crohn's disease, which may be misdiagnosed. Serology is often positive for *Chlamydia trachomatis* but negative serology is not uncommon. We present two young black women who suffered from chronic diarrhoea, abdominal pain and weight loss. There was no previous history and investigations showed in both cases a long rectal stricture. Serology was positive in one patient. They were treated with erythromycin and azithromycin and they both underwent an anterior resection of the rectum. Postoperative histology confirmed the presence of lymphogranuloma venereum of the rectum. We conclude that rectal lymphogranuloma venereum is a rare cause of rectal strictures but surgeons should be aware of its existence and include it in the differential diagnosis of unexplained strictures in high-risk patients.**

**Keywords:** lymphogranuloma venereum; rectal strictures; rectal tumours

Lymphogranuloma venereum is a rare disease in the Western world. It is estimated that approximately 400 cases occur in the US annually.<sup>1</sup> It is a venereal disease caused by *Chlamydia trachomatis* and it has been reported to be associated more frequently with black or homosexual patients.<sup>2</sup> The condition is more common in Southeast Asia, Africa, Central America and the Caribbean. In its rectal manifestation it can be associated with fistulae,<sup>3</sup> abscesses, and rectal strictures.<sup>4</sup>

We present two cases of rectal strictures in young women associated with lymphogranuloma venereum and adenocarcinoma of the rectum.

### Case reports

#### Case 1

A 30-year-old black woman from Jamaica had been suffering from intermittent bloody diarrhoea (six or seven times a day) for six years. Diarrhoea was accompanied by abdominal cramps which were relieved by defecation. Her symptoms had become more frequent and severe in the last year during which she had also lost approximately 7 kg of weight. There was no previous medical or family history. She was married with children and there was no risk factor associated with the sexual history. She was HIV negative.

Clinical examination was unremarkable. A colonoscopy revealed a narrowing with ulceration of the rectosigmoid junction (figure 1). Multiple biopsies revealed granulomatous changes and abscesses compatible with lymphogranuloma venereum. There was also an area with adenocarcinoma *in situ*. She had positive titres to Serovar 2, IgG 4096, IgM 64. All tests for other sexually transmitted diseases were negative.

She was treated with erythromycin for three months (azithromycin was not used because she was pregnant at the time). She also underwent a low anterior resection of the rectum with a defunctioning ileostomy. Operative findings included a very long stricture occupying the entire rectum and lower sigmoid. The diseased segment of the bowel was very thickened and chronically inflamed. These changes extended to the anal margin and there was no healthy margin for anastomosis. Predictably she suffered a leak of the anastomosis which was treated conservatively. Closure of the ileostomy was delayed and six months postoperatively she complained of constipation. A repeat colonoscopy revealed a low stricture of the anastomosis which was treated with dilatation.

Histology confirmed the diagnosis of lymphogranuloma venereum with multiple granulomas and stellate abscesses (figure 2). There was also adenocarcinoma Dukes A.

#### Case 2

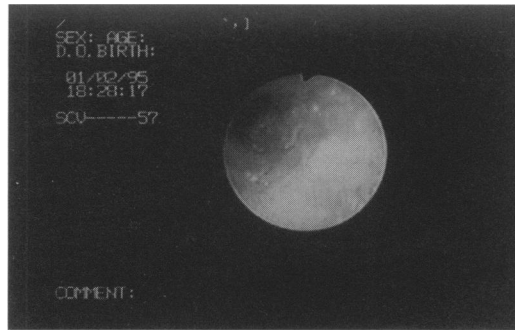
A 33-year-old Nigerian woman had suffered from diarrhoea with mucous four months post-partum. Three months later bleeding per rectum and left iliac fossa discomfort were superimposed. There was no previous medical history and no family history. She was married with children and there was no risk factor associated with the sexual history. This patient

Academic Department  
of Surgery, King's  
College Hospital,  
Denmark Hill, London  
SE5 9RS, UK  
S Papagrigoriadis  
J A Rennie

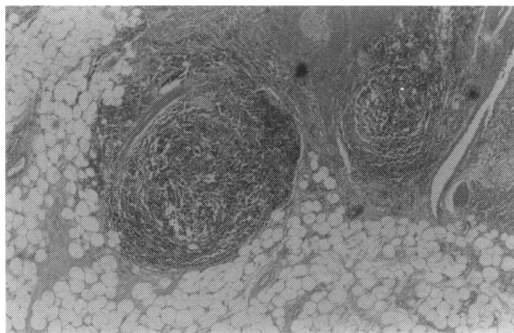
Correspondence to  
Mr JA Rennie

Accepted 20 August 1997

**Figure 1** Endoscopic appearance of a rectal stricture caused by lymphogranuloma venereum



**Figure 2** Histological appearance of lymphogranuloma venereum with granuloma formation



refused to be tested for HIV, but there was no clinical suspicion of immunosuppression.

The only abnormal investigations were a mild anaemia, haemoglobin 11.2 g/dl, mean corpuscular volume 77 fl and erythrocyte sedimentation rate 22. A barium enema showed extensive ulceration and stricturing of the upper rectum and a rectal biopsy showed normal mucosa. A colonoscopy revealed a recto-sigmoid stricture with inflamed mucosa with multiple inflammatory polyps. Biopsy revealed a chronic ulcer without specific features. A low anterior resection of the rectum with a functioning ileostomy was performed. The postoperative course was uneventful. Postoperative histology revealed suppurative granulomas with stellate abscesses, features compatible with chronic lymphogranuloma venereum. Serology and rectal swabs were negative for *Chlamydia*.

## Discussion

Non-neoplastic rectal strictures occur as a result of a number of conditions, the commonest being diverticular disease, ischaemic colitis, postoperative anastomotic strictures, and Crohn's disease. The small number caused by lymphogranuloma venereum may be misdiagnosed, as this is a rare disease in the Western world, although more common in Africa, South East Asia and the Caribbean.

## Summary points

- rectal lymphogranuloma venereum is caused by *Chlamydia trachomatis*
- high-risk groups include patients from Africa, the Caribbean and South East Asia and homosexuals
- rectal symptoms are nonspecific and include diarrhoea, proctitis and rectal ulcer
- histology may be misdiagnosed as Crohn's disease
- in the case of unexplained rectal stricture, serology and rectal swabs for *C trachomatis* should be performed
- surgical resection of the stricture should be combined with antibiotics to avoid chronic infection and the risk of malignancy

Rectal lymphogranuloma venereum is transmitted sexually and this is believed to be the reason it occurs mainly in women and homosexual men. The disease takes the form of proctitis, rectal ulcer, peri-anal or rectovaginal fistulas, and in late cases strictures. Inguinal lymphadenopathy is often absent. Isolated cases have also been reported in association with anal tumours. Histologically, colorectal lymphogranuloma venereum is almost indistinguishable from Crohn's disease. The commonest feature is an infectious granuloma with the formation of stellate abscesses. The distribution of the disease may help to distinguish between them.<sup>5</sup> When the diagnosis is suspected on clinical grounds it may be confirmed serologically, but this may be difficult because of cross reactivity and failure of cultures. In difficult cases a technique of identifying the intracellular organisms in tissue sections using monoclonal antibodies has been described.<sup>6</sup>

Treatment includes tetracycline, erythromycin, trimethoprim-sulphamethoxazole, etc. In cases of rectal stricture resection is necessary, increasing the overall morbidity of the disease. Association with adenocarcinoma has been reported<sup>7</sup> but is rare and chronicity of the infection is an important factor. In our case 1, the symptoms had been present for six years but even 20 years duration has been reported.<sup>8</sup>

Diagnosis was rapidly established in one case because of the positive serology. However if serology and cultures prove negative but histology is compatible with lymphogranuloma venereum, in the absence of any other diagnosis lymphogranuloma venereum is the most likely diagnosis. Lymphogranuloma venereum is a rare disease but still frequent enough for surgeons to be aware of its modes of presentation that may resemble other surgical conditions and may also require surgical treatment.

1 Fiumara NJ. *Pictorial guide to sexually transmitted diseases* Secausus: NJ, Hospital Publications Inc, 1987.  
 2 Ruther U, Rupp W, Muller HA, et al Rectal pseudotumour due to *Chlamydia trachomatis* in a male homosexual. *Endoscopy* 1990;22:237-8  
 3 Ghatak DP A study of urinary fistulae in Sokoto, Nigeria. *J Indian Med Assoc* 1992;90:285-7.  
 4 Mostafavi H, O'Donnel KF, Chong FK. Supralelevator abscess due to chronic rectal lymphogranuloma venereum. *Am J Gastroenterol* 1990;85:602-6.  
 5 de la Monte SM, Hutchins GM. Follicular proctocolitis and neuromatous hyperplasia with lymphogranuloma venereum. *Hum Pathol* 1985;16:1025-32.

6 Klotz SA, Drutz DJ, Tam MR, Reed KH. Hemorrhagic proctitis due to lymphogranuloma venereum serogroup L2. diagnosis by fluorescent monoclonal antibody. *N Engl J Med* 1983;30:1563-5.  
 7 Chopda NM, Desai DC, Sawant PD, et al. Rectal lymphogranuloma venereum in association with rectal adenocarcinoma. *Indian J Gastroenterol* 1994;13: 103-4.  
 8 Dan M, Rotmensch HH, Eylan E, et al. A case of lymphogranuloma venereum of 20 years' duration: isolation of *Chlamydia trachomatis* from perianal lesions. *Br J Vener Dis* 1980;56:344-6.