

Age-related macular degeneration

John G O'Shea

Summary

Macular degeneration is now responsible for approximately 95% of blindness and partial sighted registrations in the UK. This review has been written specifically to make the general medical community of the UK aware of the prevalence and clinical manifestations of age-related macular degeneration. The review encompasses the risk factors, the disabilities and problems experienced by sufferers of the condition and current therapeutic options. Age related macular degeneration increases in prevalence in our community from 0% among people under 55 years old to 18.5% among those 85 years or older. There is a marked female preponderance. The exudative form of the disorder is commoner. Treatment remains supportive for most patients with macular degeneration although a minority will benefit from macular laser photocoagulation.

Keywords: ageing; macular degeneration

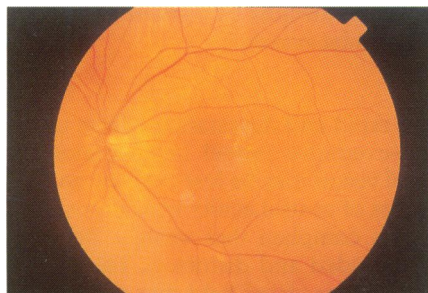


Figure 1 Discrete drusen supratemporal to the fovea. Photograph courtesy of Mr DA Infeld

Department of Ophthalmology,
University of Birmingham,
Birmingham, UK
J G O'Shea

Correspondence to Mr JG O'Shea, Birmingham and Midland Eye Centre, Dudley Road, Birmingham B18 7QU, UK

Accepted 25 June 1997

Age-related macular degeneration is now the commonest cause of blindness amongst most Western communities, currently accounting for approximately 95% of blindness and partial sight registrations in the UK.¹ Major epidemiological studies have centred on preventive aspects of the condition. These studies indicate, however, that the condition may not be as responsive to lifestyle modification as are other diseases of the elderly, for example, ischaemic heart disease. It is imperative, however, that any relationship between age-related macular degeneration and treatable or preventable pathology be fully explored.

Degeneration is the change of a tissue to a less functionally active form.² Until recently, the syndrome was referred to as senile macular degeneration, a name given to the condition by Haab as early as 1885, the terminological change reflecting contemporary sensibility regarding diseases in ageing populations.^{1 3}

Age-related macular degeneration has recently been comprehensively morphologically classified by Bird and co-workers who formed the International ARM Epidemiological Study Group.³ The disorder is either referred to as age-related maculopathy (ARM) or age-related macular degeneration (AMD). ARM is further divided into two groups—the exudative or neovascular type and the non-exudative or dry type, the severest form of which is called central areolar sclerosis.³

The macula

The macula subserves high resolution central and colour vision. It is horizontally oval, 5 mm in diameter. The foveola forms the central floor. It has a diameter of 0.35 mm. It is the thinnest part of the retina. Its entire thickness consists only of cone photoreceptors and it subserves the most acute vision.^{3 4}

The retinal pigment epithelium is a single layer of hexagonally shaped cells. They reach out to the photoreceptor layer of the inner retina. Bruch's membrane separates the retinal pigment epithelium from the vascular choroid. Ultrastructurally it is composed of five elements and throughout life can accumulate metabolic debris related to the build up of lipofuscin from the retinal pigment epithelium.¹ The functions of the retinal pigment epithelium include the maintenance of the photoreceptors, absorption of stray light, formation of the outer blood retinal barrier, phagocytosis and regeneration of visual pigment.^{3 4}

The macula has the highest concentration of photoreceptors and is the area where the retinal pigment epithelium is most metabolically active and as a consequence most likely to suffer the consequence of enzymatic failure over time with the accumulation of metabolic debris and lipofuscin.

Prevalence of ARM

The first major epidemiologic study was the Framingham eye study.⁵ The Framingham study, it will be recalled, had investigated a study population in the town of Framingham, Massachusetts, for the risk factors of coronary artery disease since 1948. In 1977, 2675 of the 3977 still living members of the initial study were given an eye examination. The results showed a prevalence of ARM of 11% for those aged 65–74 years and 28% for those aged 75–85 years.⁴ The total prevalence in the population aged between 52–85 years was 8.8%. By contrast, the prevalence of age-related cataract was 15.5% and that of open angle glaucoma 3.3%. Other studies also show the disease to be extremely common in the elderly.^{6-9 10}

The more recent Blue Mountains Eye Study,¹¹ which was conducted by Professor Paul Mitchell using differing diagnostic criteria (similar to those proposed by the International ARM Study Group³) provides an accurate estimate of the age-specific prevalence of ARM. End-stage macular degeneration was present in 1.9% of the elderly population studied and was bilateral in 56% of this group. It was more frequently of the neovascular type (ratio neovascular: atrophic, 2:1).

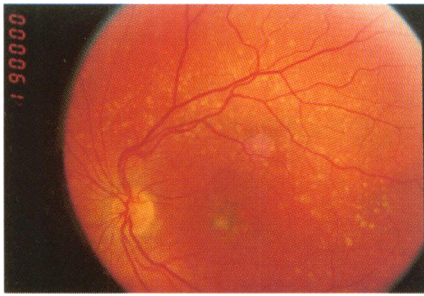


Figure 2 Extensive drusen at the macula. Photograph courtesy of Mr DA Infeld

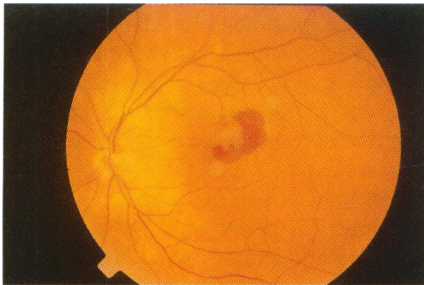


Figure 3 Recent haemorrhage from subretinal new vessels. Photograph courtesy of Mr DA Infeld

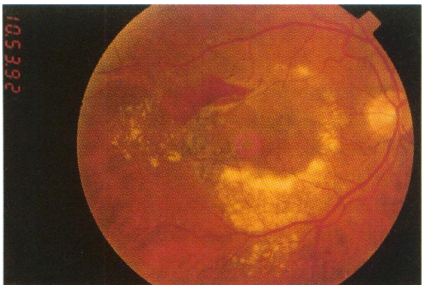


Figure 4 More extensive haemorrhage from new vessels, a ring of lipid exudates (hard exudates) has been dispersed beneath the macula. Photograph courtesy of Mr DA Infeld

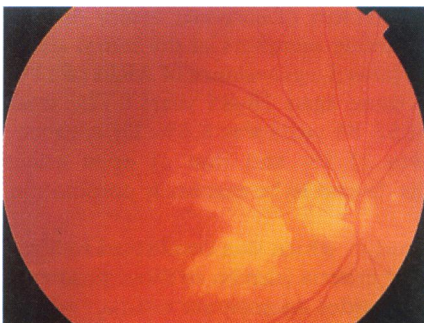


Figure 5 Geographic atrophy, the severest form of non-exudative ARM. Photograph courtesy of Mr DA Infeld

Common manifestations of macular degeneration

- drusen: the key lesion of ARM is the druse (pleural drusen) an aggregation of hyaline material located between Bruch's membrane and the retinal pigment epithelium. It is associated with atrophy and depigmentation of the overlying retinal pigment epithelium
- non-exudative macular degeneration: dry or non-exudative ARM is due to a slow and progressive degeneration of the photoreceptors and the retinal pigment epithelium with gradual failure of central vision
- exudative macular degeneration: this type of macular degeneration may have rapid and devastating effects upon vision. In contrast with patients with non-exudative retinal degeneration, in whom impairment of vision is gradual, central vision may be lost over the course of a few days

Box 1

ARM rose in prevalence from 0% among people under 55 years old to 18.5% among those 85 years or older. Soft drusen were found in 13.3% of the surveyed population and retinal pigment abnormalities in 12.6%. The sex ratio was 1.34, indicating a marked female preponderance.

Pathology and clinical manifestations

Recent publications provide detailed descriptive and photographic studies of the characteristic microscopic and ultrastructural changes associated with ARM.¹²⁻¹⁴

DRUSEN

The key lesion of ARM is the druse (pleural drusen), an aggregation of hyaline material located between Bruch's membrane and the retinal pigment epithelium. It is associated with atrophy and depigmentation of the overlying retinal pigment epithelium. Certain types of drusen are associated with sight-threatening pathology.^{14 16} Small, hard drusen are referred to simply as drusen; soft drusen over 63 μm in diameter are statistically associated with visual pathology and are termed early ARM.³ Hyper- or hypo-pigmentation of the retinal pigment epithelium also constitutes part of the description of ARM.³ Most people over the age of 40 years have at least one druse.^{15 16}

NON-EXUDATIVE MACULAR DEGENERATION

Dry or non-exudative ARM is due to a slow and progressive degeneration of the photoreceptors and the retinal pigment epithelium, with gradual failure of central vision. It is also known as atrophic ARM. Retinal pigment epithelium changes, as manifested by hypo- or hyper-pigmentation may be present, and there may be thinning of the overlying retina.³ Geographic atrophy consists of one or more areas of retinal pigment epithelium hypopigmentation with clearly visible choroidal vessels. It is the severest form of non-exudative ARM, representing a zone of retinal pigment epithelium atrophy 175 μm or greater in diameter with exposure of the underlying choroidal vessels.³

EXUDATIVE MACULAR DEGENERATION

This type of macular degeneration may have rapid and devastating effects upon vision. In contrast with patients with non-exudative retinal degeneration in whom impairment of vision is gradual, central vision may be lost over the course of a few days.^{1 3} The cardinal symptoms are loss of central acuity with a 'positive' scotoma and metamorphopsia. Often patients complain that straight lines no longer seem straight and central vision is obtunded and distorted. There may also be showers of floaters or clouding of the entire visual field due to vitreous haemorrhage.¹

The pathology of neovascular ARM is choroidal neovascularisation with the formation of a subretinal neovascular membrane, which leads to haemorrhage and disciform scarring.¹ Age-related Bruch's membrane changes may be especially important in exudative macular degeneration; these changes include thickening of Bruch's membrane, drusen and other metabolic acuminata such as lipids, and loss of basal connections with the retinal pigment epithelium.^{1 15-17}

Risk factors

SMOKING

The Beaver Dam study disclosed a relationship between the development of exudative lesions and a history of current cigarette smoking.¹⁷ The relative odds for exudative macular degeneration in female smokers was 2.5 times greater

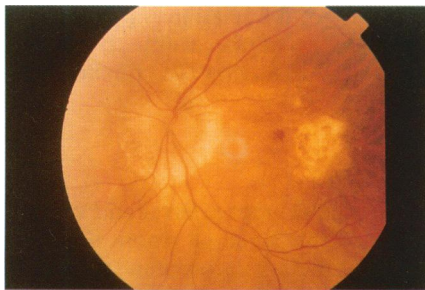


Figure 6 A disciform scar in an elderly patient who is also myopic. Photograph courtesy of Mr DA Infeld

Good practice points

- best practice for the general physician involves the prompt referral and specialist assessment of elderly patients who have any sudden disturbance of vision
- smoking cessation should be encouraged and the current dietary recommendation is to encourage food groups such as dark green, leafy vegetables rich in carotenoids
- good control of hypertension may favourably influence the surgical treatment of neovascular membranes

Box 3

The BD8 Form (1948 National Assistance Act)

Definitions

- blindness: cannot do any work for which eyesight is essential
- partial sight: substantially and permanently handicapped by defective vision

(The WHO definition of blindness is vision less than 3/60 in the better eye with best available spectacle correction)

Box 4

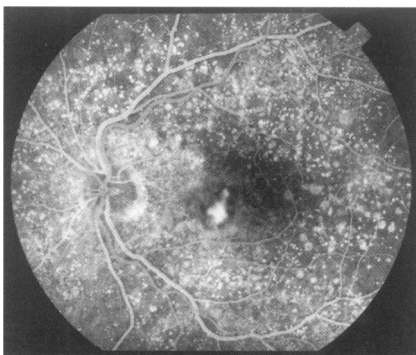


Figure 7 Fluorescein angiogram demonstrating exudative macula degeneration. Note also extensive drusen outlined by angiography. Photograph courtesy of Mr D A Infeld

Postulated risk factors for macular degeneration

- smoking: the Beaver Dam Study disclosed a relationship between the development of exudative lesions and a history of current cigarette smoking; smoking cessation lowers the relative risk of ARM
- nutrition: several studies have described the beneficial effects of dietary carotenoids in slowing the course of the disease. Dietary supplementation with vitamin A, C or E or zinc did not have any beneficial effect and the use of dietary vitamin supplements was not identified as a strategy likely to prevent ARM
- exogenous post-menopausal oestrogen: the use of exogenous supplements in post-menopausal women lowered the risk of ARM in a study by the Eye Case Control Study Group
- ethnic origin: no statistical differences were observed in the prevalence of macular degeneration between Asian and European patients living in Leicester; neovascular ARM is, by contrast, uncommon amongst Afro-Americans and Afro-Caribbeans
- there was no statistically significant relationship between hypertension, or history of cardiovascular disease, and ARM
- the recent Blue Mountains Eye Study disclosed no relationship between light and ARM

Box 2

(95% confidence interval (CI) 1.01–6.20) than in female ex-smokers or never-smokers. For males, this figure was 3.2 (CI 1.03–10.50)

The Eye Disease Case Control study group⁸ also found that smoking increased the risk of the exudative type of ARM 2.8 times above those who are current smokers. Smoking cessation lowers the relative risk of ARM.^{8 17}

NUTRITION

Several studies have described the beneficial effects of dietary carotenoids in slowing the course of the disease.¹⁸ However, dietary zinc or vitamin supplements have not been shown to have any demonstrable beneficial effect on the risk of developing or prevention of ARM in those who have good general nutrition.^{8 18} The current recommendation is the consumption of foods rich in dietary carotenoids, namely, spinach and collard greens.

EXOGENOUS POST-MENOPAUSAL OESTROGEN

The use of exogenous supplements in post-menopausal women was associated with a lower risk of ARM in a study performed by the Eye Case Control Study Group. The risk factor for current oestrogen users was 0.3 (CI 0.1–0.8). Prior use of oral contraceptive pills had no association with ARM.⁸

GENOTYPE AND ETHNIC ORIGIN

Studies in siblings and probands support the belief that genetic factors influence age-related changes in Bruch's membrane more than do environmental factors.^{19 20} Professor Alan Bird studied the eyes of 50 spouse and 53 sibling pairs and a trend toward concordance was noted only in the sibling pairs.¹⁹

No statistical differences were observed in the prevalence of macular degeneration between Asian patients (ie, those whose ethnic origin is from the Indian Subcontinent) and European patients living in Leicester.²¹ Neovascular ARM is, by contrast, uncommon amongst Afro-Americans.^{22 23} The Beaver Dam Study also noted the prevalence of ARM was higher in non-Hispanic whites than blacks.²⁴

CARDIOVASCULAR RISK FACTORS

There was no statistically significant relationship between hypertension, or history of cardiovascular disease and ARM.^{8 25} There was a correlation between hyperlipidaemia and early macular degeneration; this may be due to a genetic linkage association but the mechanism was not elucidated in the cited studies.^{8 25}

LIGHT

It has been postulated that light plays a role in the development of ARM, the proposed mechanism being that of oxidative stress to the macula.^{26 27} The existence of a relationship between light and ARM is controversial and is still being evaluated. The recent Blue Mountains Eye Study, for example, revealed no such relationship.¹¹ This investigation of the role of sunlight exposure involved the collection of detailed histories of ocular exposure of 838 watermen who worked on the Chesapeake Bay. The study discussed the possible role of visible light potentiating ARM and excluded any role of ultraviolet radiation; it suggested that further case control studies were needed to clarify the issue. The Blue

Support for the visually disabled

Royal National Institute for the Blind
224 Great Portland Street,
London W1N 6AA
Telephone 0171 388 1266
Handout on facilities available 0345-023153

Partially Sighted Society
PO Box 322, Queens Rd,
Doncaster DN1 2NX
Telephone 01302 323132 or 0171 372 1551

Box 5

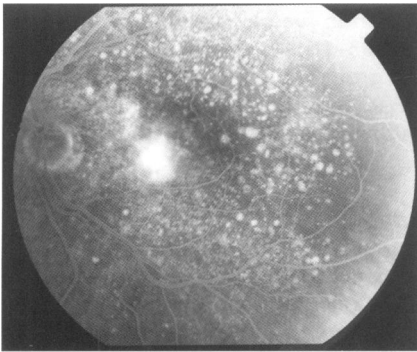


Figure 8 Diffuse leakage of fluorescein at the macula of a patient with exudative macular degeneration. Photograph courtesy of Mr DA Infeld

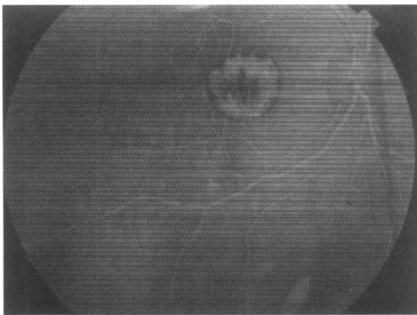


Figure 9 Fluorescein angiogram demonstrating subretinal neovascular membrane; the 'cartwheel' appearance is typical. Photograph courtesy of Mr DA Infeld

Summary points

- 95% of blindness and partial sightedness registrations in the UK are due to ARM
- treatment remains supportive for most patients with macular degeneration although a minority will benefit from macular laser photocoagulation

Box 6

Mountains Study further outlined the complexity of the relationship, for example, those with fair skin tended to avoid sunlight. At the moment, no firm evidence links ARM with exposure to visible or UV light, however, further studies are ongoing.^{11 26-28}

The treatment of patients with ARM

Best practice for the general physician involves the prompt referral and specialist assessment of those who have any sudden disturbance of vision. Smoking cessation should be encouraged and the current dietary recommendation is to encourage food groups such as dark green, leafy vegetables rich in carotenoids.^{8 18} Good control of hypertension may favourably influence the surgical treatment of neovascular membranes.²⁹

Patients should be counselled to the effect that the condition principally affects central vision and therefore they will maintain a degree of peripheral vision necessary for independent living. Areas of particular social and psychological concern include driving and reading. Elderly people often have intercurrent health problems such as deafness or poor mobility while financial difficulties and living alone may compound disability.

PATIENT SUPPORT

Supportive treatment may include registration as blind or partially sighted (BD8 form; box 4) by an ophthalmologist. The benefits of registration include financial emburment and support services such as talking books. Various agencies such as the Royal National Institute for The Blind provide support (box 5). There are many household devices which may help a patient maintain an independent lifestyle, while good illumination in the home increases contrast and aids vision.³⁰

LOW VISUAL AIDS

Low visual aids compensate for lost central vision by magnifying the object of regard. The most simple include the use of a convex lens as magnifying loupe or a convex cylindrical lens as a reading aid.³² The Galilean telescope is composed of a convex objective and a concave eye piece lens separated by the difference in their focal lengths. The problems are that high magnification results in a reduced field of view, making rapid scanning of a line or page difficult and the object viewed has to be held close to the eye. The ability to continue reading, even on a limited basis, is extremely important to patients afflicted with ARM and with these types of ancillary devices many of them do so.^{31 32}

DRIVING

Fitness to drive is based on both retention of central acuity and of sufficient peripheral field. The computerised Esterman Binocular programme is designed to assess visual field in accordance with current DVLA criteria. Because ARM affects central vision, those who fail to achieve driving vision usually do so due to failure to meet the former. An acuity of 6/10 in mesopic illumination, or better, with spectacle correction being the approximate minimum level required (ie, number plate at 25 yards). It is legal to drive a private motor vehicle if one has good vision only in one eye, although commercial driving licences have more stringent requirements.

SURGICAL TREATMENT OF NEOVASCULAR LESIONS

Developing a disciform scar in one eye carries an approximate risk of 10–12% per annum of second eye involvement.^{1 29 32 33} Neovascular ARM is sometimes amenable to treatment by argon, krypton or diode laser photocoagulation; 10–26% of cases of subretinal neovascular membrane are treatable but there is a recurrence rate of about 50%. Factors which correlate with good visual outcome include retention of 6/18 acuity or better, short duration of symptoms and a lesion located outside the foveal avascular zone.^{1 29 32 33}

Clearly, only a minority of patients with end-stage ARM are effectively treatable with present modalities. The Macular Photocoagulation Study, on-going since 1982, is a large randomised, prospective trial which has accurately defined the role of macular photocoagulation in ARM.^{29 32 33} Other forms of treatment include vitrectomy for large, sudden sub-macular haemorrhages, using tissue plasminogen activator to lyse the clot. Early studies have shown this to be effective in highly selected cases. Radiotherapy is being evaluated by Archer and co-workers in Belfast.³⁴

The author would like to acknowledge the help and assistance of Professor Gerard Crock FRCS FRACP of the University of Melbourne.

- 1 Kanski JJ. *Clinical ophthalmology*, 2nd edn. London: Butterworth Heinemann, 1989; pp 339-69.
- 2 Freil JP, ed. *Dorland's illustrated medical dictionary*, 25th edn. Philadelphia, 1974; pp 414-5.
- 3 Bird AC, Bressler NM, Bressler SB, et al. An international classification and grading system for age-related maculopathy and age related macular degeneration. *Surv Ophthalmol* 1995;39:367-74.
- 4 Klein R, Davis MD, Magli YL, Segal P, Klein BEK, Hubbard L. The Wisconsin age related maculopathy grading system. *Ophthalmology* 1991;98:1128-34.
- 5 Kahn HA. The Framingham eye study - outline of major prevalence findings. *Am J Epidemiol* 1977;106:17-32.
- 6 Klein R, Klein BE, Linton KL. Prevalence of age-related maculopathy. The Beaver Dam Eye Study. *Ophthalmology*. 1992;6:933-43.
- 7 Bressler NM. The grading and prevalence of macular degeneration in Chesapeake Bay Watermen. *Arch Ophthalmol* 1989;107:847-52.
- 8 Seddon JM, Ajani UA, Sperduto RD, et al. Risk factors for age related macular degeneration. The eye disease case control study group. *Arch Ophthalmol* 1992;110:1701-8.
- 9 Vinding T. Age related macular degeneration, macular changes prevalence and sex ratio. *Acta Ophthalmol* 1989;67:609-16.
- 10 Mitchell RA. Prevalence of age related macular degeneration in persons aged 50 years and over in Australia. *J Epidemiol Commun Health* 1993; 47:42-5.
- 11 Mitchell P, Smith W, Attebo K, Wang JJ. Prevalence of age related maculopathy in Australia, the Blue Mountains Eye Study. *Ophthalmology* 1995;102:1450-60.
- 12 Green WR, Enger C. Age-related macular degeneration histopathologic studies. The 1992 Lorenz E Zimmerman Lecture. *Ophthalmology* 1993;100:1519-35.
- 13 Spencer WH. *Ophthalmic pathology*. Philadelphia: WB Saunders, 1985; pp 924-1034.
- 14 Sarks SH. Drusen and their relationship to senile macular degeneration. *Aust J Ophthalmol* 1980;8:117-30.
- 15 Pauleikhoff D, Barondes MJ, Minassian D, Chisholm IH, Bird AC. Drusen as risk factors in age-related macular disease. *Am J Ophthalmol* 1990;109:38-43.
- 16 Maguire MG, Bressler NM, Fine SL. The Macular Photocoagulation Study Group. Relationship of drusen and abnormalities of the retinal pigment epithelium to the prognosis of neovascular macular degeneration. *Arch Ophthalmol* 1990;108:1442.
- 17 Klein R, Klein BE, Linton KL, De Mets DL. The Beaver Dam Eye Study: the relation of age related maculopathy to smoking. *Am J Epidemiol* 1993;137:190-200.
- 18 Seddon JM, Ajani UA, Sperduto RD, et al (Eye Disease Case-Control Study Group). Dietary carotenoids, vitamins A, C and E and advanced age-related macular degeneration. *JAMA* 1994; 272:1413-20.
- 19 Piguet B, Wells JA, Palmvang IB, Wormald R, Chisholm IH, Bird AC. Age-related Bruch's membrane change: a clinical study of the relative role of heredity and environment. *Br J Ophthalmol* 1993;77:400-3.
- 20 Heiba IM, Elston RC, Klein BE, Klein R. Sibling correlations and segregation analysis of age-related maculopathy: the Beaver Dam Eye Study. *Genet Epidemiol* 1994;11:51-67.
- 21 Das BN, Thompson JR, Patel R, Rosenthal AR. The prevalence of eye disease in Leicester: a comparison of adults of Asian and European descent. *J R Soc Med* 1994;87:219-22.
- 22 Jampol LM, Teilsch J. Race, macular degeneration and the macular photocoagulation study. *Arch Ophthalmol* 1992;110:1699-701.
- 23 Schact AP, Hyman L, Leske MC, Connell A, Ogden N, and the Barbados Eye Study Group. Features of age related macular degeneration in a black population. *Arch Ophthalmol* 1995;113: 728-35.
- 24 Klein R, Rowland M, Harris M. Age related maculopathy. Third national health and nutrition examination survey. *Ophthalmology* 1995; 102:371-82.
- 25 Klein R. The Beaver Dam Eye Study. *Ophthalmology* 1993;100:406-14.
- 26 Taylor HR, West S, Munoz B, Rosenthal FS, Bressler SB, Bressler NM. The long-term effects of visible light on the eye. *Arch Ophthalmol* 1992;110:99-104.
- 27 Taylor HR, Munoz B, West S, Bressler NM, Bressler SB, Rosenthal FS. Visible light and risk of age-related macular degeneration. *Trans Am Ophthalmol Soc* 1990;88:163-73.
- 28 Cruikshanks KJ, Klein R, Klein BE. Sunlight and age related macular degeneration. The Beaver Dam Eye Study. *Arch Ophthalmol* 1993;111: 514-8.
- 29 Jampol LM. Hypertension and visual outcome in the macular photocoagulation study. *Arch Ophthalmol* 1991;109:789-90.
- 30 Abrams D. *Duke-Elder's Practice of refraction*. London: Churchill Livingstone, 1978; pp 188-92.
- 31 Elkington AR, Frank HJ. *Clinical optics*. London: Blackwell, 1988; pp 116-21.
- 32 Macular Photocoagulation Study Group. Argon laser for senile macular degeneration. *Arch Ophthalmol* 1982;100:912-8.
- 33 Moissev J, Alhalel A, Masuri R, Treister G. The impact of the macular photocoagulation study results on the treatment of exudative age related macular degeneration. *Arch Ophthalmol* 1995;113:185-9.
- 34 Chakavarthy U, Houston RF, Archer DB. Treatment of age related subfoveal neovascular membranes by teletherapy; a pilot study. *Br J Ophthalmol* 1993;77:265-73.
- 35 Evans J, Wormald R. Is the incidence of registerable age related macula degeneration increasing? *Br J Ophthalmol* 1996;80:9-14.