

Classic diseases revisited

Abdominal tuberculosis

V K Kapoor

Summary

Tuberculosis has staged a global comeback and forms a dangerous combination with AIDS. The abdomen is one of the common sites of extrapulmonary involvement. Patients with abdominal tuberculosis have a wide range and spectrum of symptoms and signs; the disease is therefore a great mimic. Diagnosis, mainly radiological and supported by endoscopy, is difficult to make and laparotomy is required in a large number of patient. Management involves judicious combination of antitubercular therapy and surgery which may be required to treat complications such as intestinal obstruction and perforation. The disease, though potentially curable, carries a significant morbidity and mortality.

Keywords: tuberculosis

"The captain of all these men of death that came against him to take him away was the consumption; for it was that that brought him down to grave." John Bunyan, 1628-88¹

Tuberculosis causes 3 million deaths every year, accounting for 6% of all deaths. It is among the 10 leading causes of death and is one of the commonest causes of death in the young.²

Incidence

Tuberculosis is the most important communicable disease world-wide. Despite expectations such as "tuberculosis should be virtually eradicated from most developing countries within 50 years"³ it has come back with a vengeance and has recently been declared a global emergency by the World Health Organisation. It continues to be prevalent in the underdeveloped and developing Third world, and although it was on the verge of eradication in the developed world, its prevalence is increasing there too, due to factors such as transglobal immigration, ageing populations, alcoholism, socio-economic deprivation, and more recently, acquired immunodeficiency syndrome (AIDS). It is estimated that half of the world's population is infected and about 10 million new cases occur every year.

The abdomen is involved in 11% of patients with extra-pulmonary tuberculosis.⁴ In a recent series of 820 patients with tuberculosis reported from Saudi Arabia,⁵ 16% had abdominal involvement. Abdominal tuberculosis continues to be common in various parts of the world with large series being reported from Chile,⁶ Egypt,⁷ India,⁸⁻¹³ Iraq,¹⁴ Kuwait,¹⁵ Nigeria,¹⁶ Saudi Arabia¹⁷ and Sudan.¹⁸

In the UK, pulmonary tuberculosis has declined in incidence but non-pulmonary tuberculosis continues to be common.¹⁹ In 1985, abdominal tuberculosis accounted for 5% of all cases of tuberculosis notified in a district in the UK.²⁰ The disease was largely under control in the 1950s but revived in the 1960s and 70s²¹ and its renaissance in the 1980s and 90s²² is disturbing. In a District General Hospital in London, Palmer *et al*²³ reported having seen 90 patients with abdominal tuberculosis during the 10-year period up to 1984; over the same period Crohn's disease was diagnosed in 102 patients. This may not be typical of all of the country but may reflect experience in areas with a large Asian population.²⁴ Other large series of abdominal tuberculosis have been reported from areas in the UK with large immigrant populations.²⁵⁻²⁸ Abdominal tuberculosis has also reappeared in the US²⁹⁻³⁴ and is likely to become more common because of AIDS.³⁵

Aetiopathogenesis

Abdominal tuberculosis probably occurs due to reactivation of a dormant focus. This primary gastrointestinal focus is established as a result of haematogenous spread from a pulmonary focus acquired during primary infection in childhood. It may also be caused by swallowed bacilli which pass through the Peyer's patches of the intestinal mucosa and are transported by macrophages through the lymphatics to the mesenteric lymph nodes, where they remain dormant. Suppression of host defences by conditions such as malnutrition, weight loss, alcoholism, diabetes, chronic renal failure, immunosuppression, AIDS, etc, increases the risk of such reactivation. Ingestion of bacilli from an active pulmonary focus, haematogenous spread from active tuberculosis in other organs, and direct extension from adjacent organs are other possible mechanisms of involvement of the abdomen. Ingestion of infected milk is rarely a cause because of disappearance of bovine tuberculosis and pasteurisation of milk in the West and the practice of boiling milk before consumption in the developing countries. Most bacilli isolated in patients with abdominal tuberculosis are *Mycobacterium tuberculosis* and not *Mycobacterium bovis*.^{12 28 36}

Department of Surgical
Gastroenterology, Sanjay Gandhi
Postgraduate Institute of Medical
Sciences, Lucknow 226014, India
V K Kapoor

Accepted 10 March 1998

Extrapulmonary disease is more common in patients with AIDS; 50% of AIDS patients with tuberculosis have extrapulmonary involvement, compared to only 10–15% of non-HIV tuberculosis patients.³⁷ The diagnosis of tuberculosis may precede the diagnosis of AIDS by several months; tuberculosis frequently disseminates in AIDS patients, progresses rapidly and is associated with a high mortality.³⁸ Treatment of tuberculosis in AIDS patients is the same as in non-HIV infected patients³⁹ but multi-drug-resistant tuberculosis is more common in patients with AIDS.⁴⁰

Pathology

Abdominal tuberculosis denotes involvement of the gastrointestinal tract, peritoneum, lymph nodes, and solid viscera, eg, liver, spleen, pancreas, etc. The gastrointestinal tract is involved in 65%⁹ to 78%¹² of patients; associated peritoneal and lymph node involvement is common in these patients. The common sites of involvement in the gastrointestinal tract are the ileum^{9 11} and the ileocaecal region,^{23 41} followed by the colon and the jejunum. In 196 patients with gastrointestinal tuberculosis,⁹ the ileum was involved in 102 and caecum in 100 patients. In another series of 300 patients,¹⁰ however, the ileocaecal region was involved in 162 and the ileum in only 89 patients. Three types of intestinal lesions are commonly seen – ulcerative, stricturous, and hypertrophic, cicatricial healing of the ulcerative lesions resulting in strictures. Occlusive arterial changes may produce ischaemia and contribute to development of strictures.⁴² These morphological types can coexist, eg, ulcero-constrictive and ulcero-hypertrophic lesions. Small intestinal lesions are usually ulcerative or stricturous and large intestinal lesions are ulcero-hypertrophic. Colonic lesions are usually associated with ileocaecal or ileal involvement but isolated segmental colonic tuberculosis does occur.^{43 44} Some patients have involvement of peritoneum and lymph nodes alone without involvement of the gastrointestinal tract. Peritoneal involvement may be of either an ascitic or adhesive (plastic) type. The lymph nodes in the small bowel mesentery and the retroperitoneum are commonly involved, and these may caseate and calcify. Disseminated abdominal tuberculosis involving the gastrointestinal tract, peritoneum, lymph nodes and solid viscera has also been described. Chen *et al*⁴⁵ reported disseminated involvement of the abdomen in 21 out of 60 patients with large bowel tuberculosis, while most of the 96 patients with tuberculous hepatitis reported by Essop *et al*⁴⁶ had disseminated disease. Multiple lesions are common. Bhansali⁹ reported that small intestinal strictures were multiple in 71 out of 119 patients; as many as 12,⁴⁷ 16,⁴¹ and 19⁴⁸ strictures have been reported in a single patient.

Clinical features

Abdominal tuberculosis can occur at any age but is predominantly a disease of young adults; two-thirds of patients are 21–40 years old^{9 11 23 49} and the mean age of patients is 30–40 years.^{12 17 23 41} The mean age of white patients is higher – 56 years.²⁰ Although some reports mention a higher incidence in females,^{10 12 41} it seems that the disease affects both sexes equally.^{9 23 28} Abdominal tuberculosis is also seen in children, where the spectrum of disease is different from that in adults; 90% of child patients have peritoneal and lymph node involvement, intestinal lesions being present in less than 10% of cases.⁵⁰

Abdominal tuberculosis is characterised by different modes of presentation, *viz*, chronic, acute and acute-on-chronic, or it may be an incidental finding at laparotomy for other diseases; incidental abdominal tuberculosis is usually peritoneal and lymph nodal.¹⁵ The clinical presentation depends upon the site and type of involvement (table 1). Bhansali⁹ observed frank malabsorption in 21% of patients, while Tandon *et al*¹ reported biochemical evidence of malabsorption in 75% of patients with intestinal obstruction and 40% of those without it. The lump in patients with abdominal tuberculosis is firm, mobile and only slightly tender. Rectal bleeding has been reported in 4%⁴⁹ to 6%¹¹ of patients; massive lower gastrointestinal bleeding is rare.⁵² Subacute intestinal obstruction is described as colicky abdominal pain, distension, vomiting, gurgling, feeling of a ball of wind moving in the abdomen, and visible loops and peristalsis; these symptoms are relieved spontaneously after passage of flatus. Ano-rectal tuberculosis presents as stricture,⁵³ fistula-in-ano,^{54 55} or fissure-in-ano.⁵⁶ Tubercular fistulae are usually multiple; as many as 12 out of 15 multiple fistulae but only four out of 61 single peri-anal fistulae were tubercular.⁵⁷

Gastroduodenal tuberculosis may present as peptic ulcer with or without gastric outlet obstruction^{58 59} or perforation²⁰ and may mimic carcinoma.⁶⁰ Short duration of history, early onset of obstruction, bizarre endoscopic findings, and non-response to H₂-receptor antagonists in a patient with a diagnosis of peptic

Acute tubercular abdomen

- intestinal obstruction: acute or acute-on-chronic
- peritonitis: with or without perforation
- acute mesenteric lymphadenitis
- acute tubercular appendicitis

Box 1**Table 1** Clinical features

Site	Type	Clinical features
Small intestine	Ulcerative* Strictureous	Diarrhoea, malabsorption Obstruction
Large intestine	Ulcerative Hypertrophic	Rectal bleeding Lump, obstruction
Peritoneal	Ascitic* Adhesive	Pain, distension Obstruction
Lymph nodes		Lump, obstruction

*Systemic symptoms of tuberculous infection also present

ulcer should arouse the suspicion of gastroduodenal tuberculosis.⁶¹ Microscopic involvement of the liver is common in patients with abdominal tuberculosis but isolated focal lesions (tuberculoma) are rare.⁴⁶ Tuberculosis at unusual sites mimics more common diseases in those organs, eg, oesophagus – carcinoma,⁶² pancreas – carcinoma,⁶³ pancreatitis,⁶⁴ and abscess.⁶⁵

Varying grades of tenderness and guarding may be present in patients with ascitic peritoneal tuberculosis but board-like rigidity or rebound tenderness as seen in pyogenic peritonitis is absent.⁶⁶ Loculation of the ascitic fluid may result in a soft cystic lump. Involvement of the mesenteric lymph nodes produces a lump in the central abdomen. Enlarged lymph nodes at the root of the mesentery may cause obstruction to the third part of the duodenum.^{58, 61} Portal hypertension due to portal vein compression⁶⁷ and obstructive jaundice due to compression of the common bile duct due to tuberculous nodes, have been reported.⁶⁸

Systemic manifestations of tuberculous infection include low-grade fever with evening rise, lethargy, malaise, night sweats, anorexia and weight loss (failure to thrive in children). These are present in about one-third of patients with abdominal tuberculosis¹¹ and are more frequent in those with ulcerative intestinal lesions and ascitic peritoneal tuberculosis. Some patients, particularly those with miliary tuberculosis, may have tubercular toxæmia,¹⁰ with high fever, tachycardia, anaemia, and leucocytosis. Tuberculous involvement of other organs or systems has been reported in as many as one-third of patients.¹² The commonest sites of involvement are pulmonary and pleural. Genital tract involvement has been reported in 10% of women with abdominal tuberculosis.^{9, 21} Peripheral lymph nodes (cervical or axillary) may be involved in 3–10%^{11, 12, 49, 50} of patients. A family history of tuberculosis, reported in about one-third of patients in the UK,^{20, 28} is rarely revealed by patients in India because of the social stigma still attached to the disease.

Tuberculosis is regarded as a disease with insidious onset and chronic presentation, most patients having symptoms for a few weeks to months, sometimes years; Lambrianides *et al*²⁷ even stated that tuberculosis is rarely an emergency. Between 15 and 40% of patients^{10, 23, 49} may, however, present with an acute abdomen⁶⁹ (box 1). Intestinal obstruction in tuberculosis is usually chronic/subacute but may be acute-on-chronic (episode of acute obstruction with history of subacute obstruction) or acute (no previous history of obstruction). Perforation has been reported in 8%⁹ to 12%^{70, 71} of patients; while 19 out of 123 bowel perforations in children were tubercular.⁷² Tuberculous perforations are usually single and proximal to a stricture; a previous history of subacute intestinal obstruction and evidence of tuberculosis on chest X-ray suggest the diagnosis.⁷³

Differential diagnosis

Because of its varied clinical presentations, abdominal tuberculosis is a great mimic and figures in the list of differential diagnoses of a large number of medical and surgical conditions (box 2).¹ It should be included in the differential diagnosis of pyrexia of unknown origin,²³ unexplained weight loss,⁷⁷ and hepatosplenomegaly.⁴⁶ Abdominal tuberculosis should be considered in any patient with unexplained and chronic abdominal symptoms⁷⁸ and should be thought of whenever a diagnosis of Crohn's disease or gastrointestinal malignancy is being entertained.⁷⁹

It is important to distinguish Crohn's disease from tuberculosis; while steroids are the mainstay of treatment in the former they may be disastrous in the latter.⁷⁹ This can be done in the majority of patients on the basis of clinical features and radiological investigations but the distinction may not be clear in some cases without laparotomy and histological examination.⁸⁰ Colonic tuberculosis may rarely present as diffuse pancolitis and mimic ulcerative colitis.⁸¹ Ascites due to peritoneal tuberculosis should be differentiated from that due to cirrhosis, as

Differential diagnosis*Intestinal lesions*

- ulcerative: coeliac disease, tropical sprue, immunoproliferative small intestinal disease, giardial infestation⁷⁴
- strictures: Crohn's disease, malignancy (adenocarcinoma and lymphoma), ischaemic³⁶
- hypertrophic: carcinoma caecum, appendicular lump, amoeboma, actinomycosis
- perforations: typhoid⁷⁵

Peritoneal

- ascites: cardiac failure, malnutrition, nephrotic syndrome, cirrhosis
- tubercles: carcinomatosis⁷⁶

Box 2

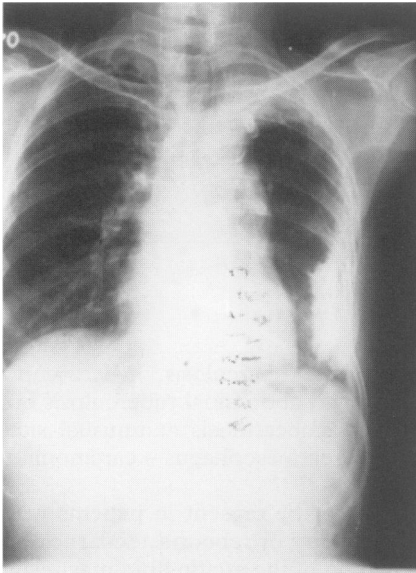


Figure 1 Chest X-ray showing fibro-calcific pleural plaque left lower lobe (healed tuberculosis)

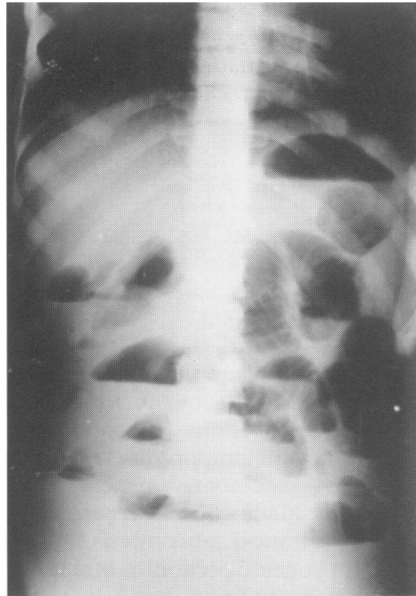


Figure 2 Abdomen X-ray (erect film) showing multiple air fluid levels in subacute intestinal obstruction

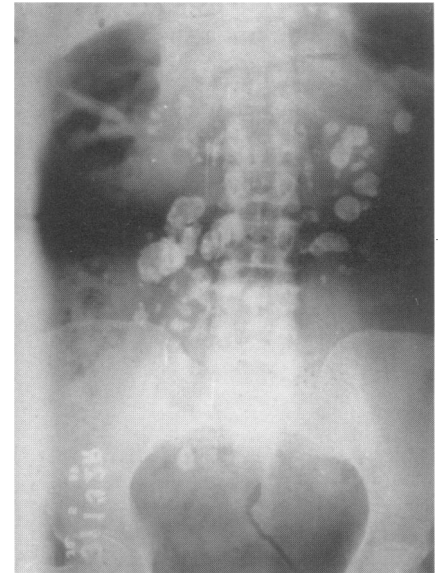


Figure 3 Abdominal X-ray showing calcified mesenteric lymph nodes

antitubercular drugs are hepatotoxic and may precipitate hepatic failure in the presence of cirrhosis; sometimes the two conditions may coexist, thus complicating the diagnosis and management.⁸²

Investigations

Haematological tests reveal anaemia, leucocytosis with relative lymphocytosis and raised erythrocyte sedimentation rate (ESR). All the children⁵⁰ and between 50%^{10 11} and 80%⁴⁹ of the adults with abdominal tuberculosis have been found to be anaemic, while ESR was found to be raised in 50%,⁴⁹ 66%,¹⁰ and 80%^{11 23 43} of patients. Hypoalbuminaemia is frequent.²⁰ Serological tests, such as soluble antigen fluorescent antibody and enzyme-linked immunosorbent assay, are prone to give both false-negative (due to immune non-response) and false-positive (due to latent tuberculous infection) results, and can only suggest the probable diagnosis of tuberculosis.^{83 84} Anti-cord factor antibodies have been found to be of use in rapid diagnosis of intestinal tuberculosis and its differentiation from Crohn's disease.⁸⁵ Tuberculin test (Mantoux or Heaf) was positive in a majority of patients²⁰ but is of limited value as a diagnostic tool because it does not differentiate between active disease and previous sensitisation by contact or vaccination.

Radiological investigations are the mainstay of diagnosis of abdominal tuberculosis.⁸⁶ Homan *et al*⁸⁰ observed that a normal chest X-ray excludes a diagnosis of abdominal tuberculosis but chest X-ray is positive in only 25% of patients.^{11 49} While findings of tuberculosis (active or healed) on chest X-ray (figure 1) support the diagnosis of abdominal tuberculosis, a normal chest X-ray does not rule it out. In Prakash's¹⁰ series of 300 patients, no patient had active pulmonary tuberculosis but 39% had evidence of healed tuberculosis on X-ray. Chest X-ray is more likely to be positive for tuberculosis in patients with ulcerative intestinal and ascitic peritoneal types and those with acute complications.

Abdominal X-rays may show dilated intestinal loops and air fluid levels (figure 2), even in the absence of clinical intestinal obstruction,^{10 11 50} calcified lymph nodes (figure 3), enteroliths and ascites. The radiological findings on small bowel enema are mucosal irregularity and rapid emptying (ulcerative), flocculation and fragmentation (malabsorption), dilated loops and stricture (figures 4 and 5), displaced loops (enlarged lymph nodes) and adherent fixed loops (adhesive peritoneal disease).

Double-contrast barium enema in ileocaecal tuberculosis shows a shortened ascending colon, deformed (irregular, shortened, narrowed) caecum, deformed and incompetent ileocaecal valve, dilated ileum, and a distorted ileocaecal junction with increased (obtuse) ileocaecal angle (figure 6).⁸⁷ Barium studies are sensitive for ileocaecal and colonic lesions⁴⁹ (figure 7) but small bowel strictures may be missed and extra-intestinal lesions (peritoneal and lymph nodes) may be

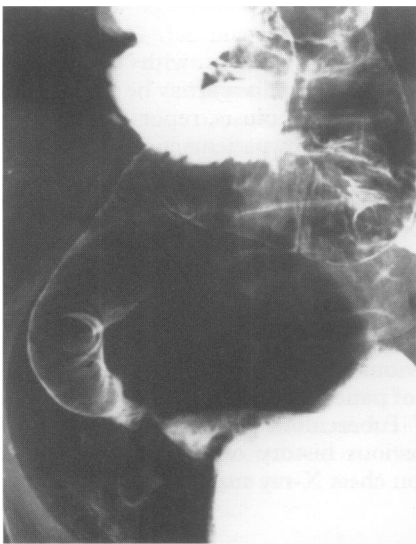


Figure 4 Barium meal follow-through showing distal ileal stricture

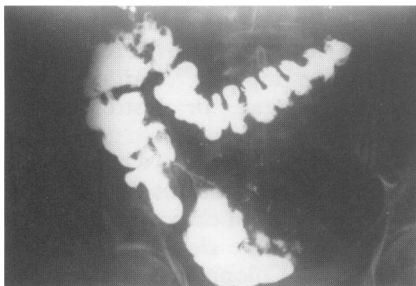


Figure 5 Barium enema showing terminal ileal stricture with proximal dilatation

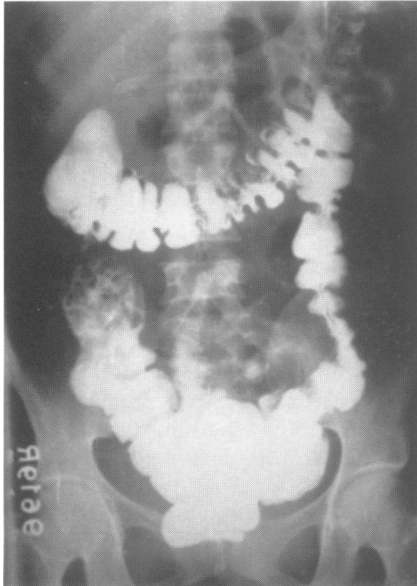


Figure 6 Barium enema showing absent (shortened, contracted) ascending colon and caecum with dilated ileum entering the hepatic flexure

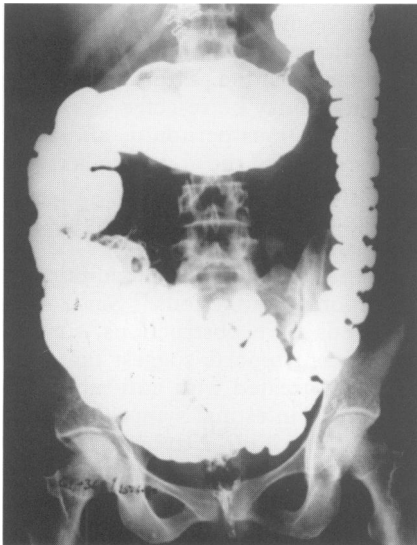


Figure 7 Barium enema showing stricture in the transverse colon with proximal dilatation

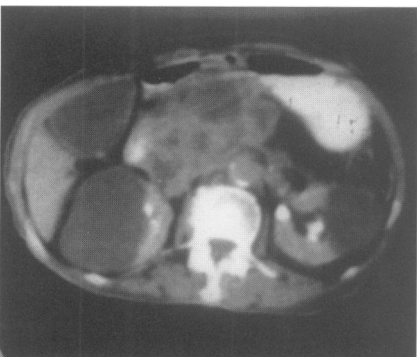

Figure 8 CT scan showing large lymph node mass in the region of the head of the pancreas (FNAC showed caseating granulomas)

misinterpreted as intestinal strictures or *vice versa*.^{66 88} Tandon *et al*¹¹ reported false-negative barium studies in 25% of patients. Radiological studies may not always differentiate tuberculosis from Crohn's disease and malignancy.^{20 23}

Imaging has recently been used in the diagnosis of abdominal tuberculosis.⁸⁹ Ultrasonography shows ascites, enlarged lymph nodes and hypertrophic intestinal lesions.⁹⁰ Ultrasound-guided ascitic tap or fine needle aspiration cytology (FNAC) from the lymph nodes or the hypertrophic lesion may be performed.⁹¹ Computed tomography (CT) shows adherent bowel loops, thickened omentum with irregular soft tissue densities, caseated lymph nodes (low-density centre with high-density rim) (figure 8)⁹² and has been found to be of use both in the diagnosis of tuberculous peritonitis⁹³ and in differentiating it from peritoneal carcinomatosis.^{94 95}

Endoscopic appearances in tuberculosis include hyperaemic nodular friable mucosa, irregular ulcers with sharply defined margins and undermined edges, pseudopolyps and cobblestoning, and may mimic Crohn's disease and malignancy.⁴³ Endoscopic biopsy may not reveal granulomas in all cases, as the lesions are submucosal⁴⁴; biopsies from the edges and the base of the ulcer, multiple biopsies at the same site,^{12 43} and endoscopic FNAC⁹⁶ may increase the yield. Although acid-fast bacilli were not seen in any case, Vij *et al*¹² reported positive cultures in more than 40% of endoscopic biopsy specimens. Endoscopic biopsy specimens may be subjected to polymerase chain reaction for detection of acid-fast bacilli.⁹⁷ In patients with ascites, peritoneal tap reveals straw-coloured fluid with proteins > 30 g/l, cells more than 1000/ μ l (predominantly lymphocytes), ascitic/ blood glucose ratio of less than 0.96,⁹⁸ and adenosine deaminase levels > 33 U/l.⁹⁹ Acid-fast bacilli are rarely seen on smear but may be cultured from the ascitic fluid; yield may be increased to more than 80% by culturing a litre of fluid concentrated by centrifugation.⁸⁸ Blind percutaneous needle biopsy,¹⁰⁰ laparoscopic biopsy,¹⁰¹ or small incision open peritoneal biopsy under local anaesthesia¹⁰² may be helpful in the ascitic type but should be avoided in the adhesive type of peritoneal tuberculosis. Ultrasound and CT may be helpful in selecting cases suitable for needle biopsy/ laparoscopy by showing presence of ascites and absence of parietal adhesions. Liver biopsy may be useful in patients with systemic symptoms.⁴⁶ Stool and gastric aspirate are rarely positive for acid-fast bacilli in patients with abdominal tuberculosis.^{10 50}

Microbiological diagnosis of abdominal tuberculosis is difficult; the yield of organisms from abdominal lesions is low because extrapulmonary disease is paucibacillary. Acid-fast bacilli were seen on histological examination by Ziehl Nielsen staining in only 6–8% of patients.^{10 23 43} The diagnosis of abdominal tuberculosis is therefore mainly histological – epithelioid cell granulomas with Langhan's giant cells, peripheral rim of lymphocytes and plasma cells, and central caseation necrosis.¹⁰³ Non-caseating granulomas, as seen in Crohn's disease, may be present in tuberculosis due to low virulence of organisms and increased host resistance. Mycobacterial culture should be performed in all cases (although results take 6 weeks) because it may be positive even in the absence of a characteristic histological picture.¹²

Pre-operative diagnosis is difficult even in areas where tuberculosis is common and was obtained in only 40%⁴⁹ to 50%⁸ of patients in India, 33% in Kuwait¹⁵ and 25% in the UK.²⁰ Many reports describe a significant number of patients in whom tuberculosis could not be diagnosed during the life of the patient but was revealed at necropsy.^{20 23} This happens more frequently in the presence of small intestinal strictures which are not amenable to endoscopic or percutaneous biopsy and FNAC, and adhesive peritoneal lesions where ascitic tap or laparoscopic biopsy can not be performed. Therapeutic trial – starting the patient on anti-tubercular therapy empirically without a definite diagnosis of tuberculosis, is advocated by many authors^{23 28 45 74 104} in such circumstances but we do not recommend it as it may delay the diagnosis and treatment of diseases such as malignancy, lymphoma, and Crohn's disease, which can mimic tuberculosis clinically and even radiologically. Also, anti-tubercular therapy can alter the histological picture in tuberculosis so that the diagnosis cannot be confirmed or refuted at a later date,¹⁰³ and it may precipitate intestinal obstruction due to healing by fibrosis and cicatrization,¹⁰⁵ or result in intestinal perforation.¹⁰⁶ Tandon and Prakash¹⁰³ observed recrudescence of obstructing symptoms requiring operation in one-third of patients who were put on anti-tubercular therapy. In such circumstances, where clinical suspicion is strong but results of investigations are equivocal, a diagnostic laparotomy may be a safer option as it may allow treatment of intestinal lesions concurrently. Laparotomy is definitely indicated when malignancy cannot be ruled out with certainty.

Operative findings in abdominal tuberculosis include ascites, small white-to-yellow nodules over the visceral and parietal peritoneum (tubercles), adhesions between intestinal loops and to the parietes, calcified or enlarged mesenteric

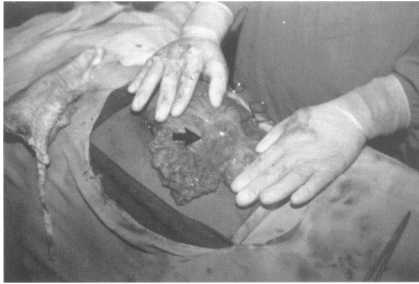

Figure 9 Enlarged mesenteric lymph nodes (arrow)

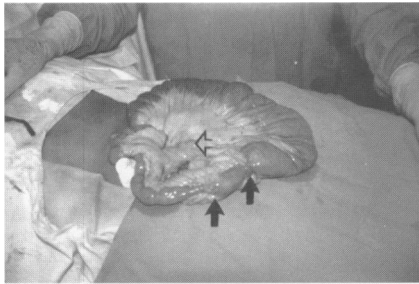

Figure 10 Ileal strictures (arrows) with proximal dilatation and enlarged mesenteric lymph nodes (arrowhead)

lymph nodes (figures 9 and 10) which may show caseation on bisection, infiltrated thickened and rolled up omentum, increased mesenteric fat wrapping the bowel, short and fibrotic strictures (figure 10), and soft to firm hypertrophic lesions (figure 11). The opened specimen shows thickened folds, nodularity, ulceration and fibrosis (figures 12 and 13). In many patients it may not be possible to differentiate tuberculosis from malignancy and Crohn's disease, even at laparotomy. A frozen section examination may help to confirm or exclude malignancy. A mesenteric lymph node should always be removed for biopsy because granulomas and caseation are more likely to be found in the lymph nodes than in the intestinal lesions.^{9 103}

Management

All patients with abdominal tuberculosis should receive a full course of anti-tubercular therapy. Conventional regimens include anti-tubercular therapy for 12 to 18 months.¹⁰⁷ Short-course regimens including ethambutol, rifampicin and isoniazid for 3 months followed by rifampicin and isoniazid for 6 months or pyrazinamide, ethambutol, rifampicin and isoniazid for 2 months followed by rifampicin and isoniazid for 4 months, are effective for abdominal tuberculosis.¹⁰⁸ It is important to administer a correct and complete course, as inadequate drugs, dose or duration is the most important cause of emergence of multi-drug-resistant tuberculosis.

As many as 20%¹⁰⁹ to 40%⁴⁹ of patients with abdominal tuberculosis who present with acute abdomen require emergency surgical intervention.⁶⁹ Acute-on-chronic intestinal obstruction usually responds to conservative management; these patients can then be electively investigated and managed accordingly.⁹

Tubercular perforations are usually ileal and are associated with distal strictures; if the two are close to each other the segment should be resected.⁷³ Parikh¹¹⁰ described strictureplasty in such situations – the incision through the stricture encircling the perforation. If they are far apart the perforation may be closed after freshening the edges and the stricture may be resected or treated with strictureplasty.⁷³ In patients with acute tuberculous peritonitis and acute mesenteric lymphadenitis, biopsy alone is performed and the abdomen is closed without drainage.¹¹¹ Peritoneal toilet should be performed.

Patients with ulcerative intestinal disease and those with peritoneal and lymph node involvement may be treated with anti-tubercular therapy if no complications are present. In patients with peritoneal disease, the addition of steroids may reduce the subsequent complications of adhesions.⁸⁸ Since most patients with strictures and hypertrophic lesions have obstructions, surgical treatment is recommended.¹¹² However, two recent reports suggest that even obstructing intestinal lesions may be successfully treated with anti-tubercular therapy.^{104 108} The mean time required for relief of intestinal symptoms was 6 months, although systemic symptoms improved within 2 months. A pre-operative 6-week course of anti-tubercular therapy has been recommended in patients who are planned for elective surgery¹¹³ but we feel this should be avoided, except in patients with active pulmonary tuberculosis or tubercular toxemia,¹⁰ as it can alter the histological picture, making the diagnosis of tuberculosis difficult.¹⁰³

Initially, by-pass procedures like entero-enterostomy and ileo-transverse colostomy were performed in patients with abdominal tuberculosis, as any

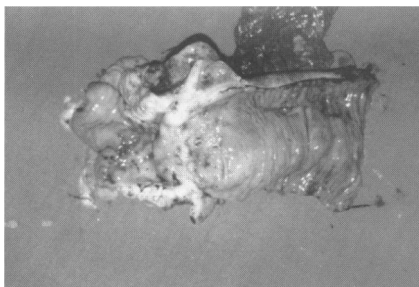

Figure 11 Hypertrophic ileocaecal lesion

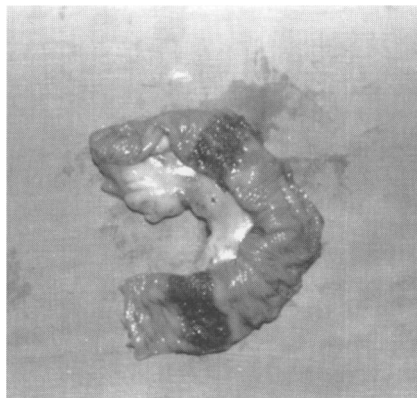


Figure 12 Two ulcerated lesions in ileum

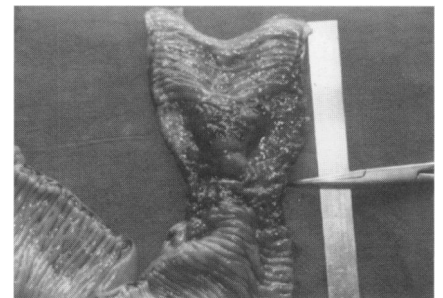


Figure 13 Ulcero-stricturous ileal lesion

Table 2 Diagnostic algorithm

Predominant clinical presentation	Possible lesions		Suggested investigations
	Site	Type	
Intestinal obstruction	Small intestine Peritoneum	Strictureous Adhesive	Small bowel enema CT
Lump	Ileocaecal region, colon Lymph nodes	Hypertrophic	DCBE, colonoscopy + biopsy US, CT, FNAC
Diarrhoea	Small intestine	Ulcerative	Small bowel enema, retrograde ileoscopy + biopsy UGIE + biopsy
Rectal bleeding	Large intestine	Ulcerative	Colonoscopy + biopsy
Ascites	Peritoneum	Ascitic	US, CT, ascitic tap, laparoscopy + biopsy

CT - computed tomography; DCBE - double contrast barium enema; FNAC - fine needle aspiration cytology; UGIE - upper gastrointestinal endoscopy; US - ultrasonography

resectional surgery was considered hazardous in the presence of active disease. When adequate anti-tubercular drugs became available, various reports recommended the use of radical procedures, such as right hemicolectomy, in an attempt to eradicate the disease. The recommended surgical procedures for tuberculosis today are conservative; tuberculosis is a systemic disease and cannot be eradicated by surgery alone. Prakash's¹⁰ series of 300 patients managed between 1959 and 1977 shows the transition from right hemicolectomy, performed in the initial 107 patients, to limited ileocaecal resection, performed in 88 later patients. Resection in tuberculosis is segmental with 5 cm margins; wide excision of the mesentery as is performed in malignant disease is not necessary.⁴¹⁻⁴⁸ However, if malignancy cannot be ruled out, radical resection should be performed. Strictures are best treated with strictureplasty; long tubular strictures, those with complete obliteration of the lumen, or multiple strictures in a small segment may need resection, while early strictures which are not very tight may be left alone⁴⁸ or dilated through an enterotomy.⁴⁷ Strictureplasty involves opening the bowel by a longitudinal 5–6 cm incision along the anti-mesenteric border centred on the stricture. Edges are trimmed for biopsy⁴⁸⁻¹¹⁰ and the incision is closed transversely in two layers. Katariya *et al*⁷⁷ reported strictureplasty in pyloroduodenal and ileocaecal lesions. A U-anastomosis, such as in the Finney pyloroplasty for intestinal strictures has also been described.⁴¹ Multiple procedures are often necessary because of the frequency of multiple lesions; Bhansali⁹ reported the need for more than one resection in 19% of patients. By-pass procedures are not preferred to resections as residual disease may cause complications like obstruction, fistulae, and malabsorption due to blind loops. These patients may require re-operation and resection during follow-up.⁹⁻²⁰ Prakash¹⁰ reported on seven patients requiring second stage resection after by-pass procedures. Gastro-jejunostomy⁴⁸ or duodeno-jejunostomy,⁹⁻⁵⁸ however, may be performed for duodenal obstruction. In some patients with peritoneal tuberculosis, the adhesions are so dense and fibrotic that attempts to lyse them carry a high risk of enterotomy into one of the adherent loops and such attempts should be resisted. Bhansali⁹ reported that in 35 out of 300 patients with abdominal tuberculosis laparotomy alone could be performed. Chen *et al*⁴⁵ reported nine patients with large bowel tuberculosis in whom only biopsy could be performed.

Postoperative complications include anastomotic leak resulting in a faecal fistula, peritonitis and intra-abdominal sepsis, persistent obstruction, wound infection, and dehiscence.⁹⁻⁴¹ Re-operation may be required during the follow-up for recurrent obstruction due to strictures or adhesions²⁰⁻⁵⁰; the incidence of recurrent disease is, however, less than in Crohn's disease.

Table 3 Management

Site	Type	Suggested treatment
Any site	Acute abdomen	Emergency surgery
Intestinal	Ulcerative	ATT
	Strictureous	Strictureplasty, resection
	Hypertrophic	Resection
	Ascitic, adhesive	ATT + ? steroids
Peritoneal		ATT
Lymph nodes		ATT

ATT - antitubercular therapy

Prognosis

Delayed diagnosis and injudicious treatment due either to limited experience or poor understanding of the disease are principally responsible for the mortality rate of 4–12%.^{10 17 45 49 50} The high mortality is partly due to the associated malnutrition, anaemia and hypoalbuminaemia; mortality is even higher (12–25%) in the presence of acute complications.^{9 49 114} Timely diagnosis based on a high index of suspicion in areas and in populations in which tuberculosis is common, an algorithmic diagnostic approach using radiology, imaging and endoscopy (table 2), and management with a judicious combination of anti-tubercular therapy and conservative surgery (table 3), can reduce the mortality of this 'easily curable yet potentially lethal' disease.¹¹⁵

"The first country to eliminate tuberculosis will be that which regards it as a serious problem right to the end." Prof Etienne Bernard, Paris³

Tuberculosis unfortunately still remains the world's most neglected health crisis.

The author reviewed the subject during a Visiting Professorship to the Academic Department of Surgery at the King's College Hospital, London on a Commonwealth Fellowship.

Acknowledgements are due to Ms Dymna Kelly, Lecturer, Academic Department of Surgery, King's College Hospital, London for her comments on the manuscript.

- Cook GC. Tuberculosis - certainly not a disease of the past! *Q J Med* 1985;56:519–21.
- Anonymous. The challenge of tuberculosis. *Lancet* 1994;34:277–9.
- Horne NW. Problems of tuberculosis in decline. *BMJ* 1984;288:1249–51.
- Anonymous. Management of non-respiratory tuberculosis. *Lancet* 1986;1:1423–4.
- Al-Karawi MA, Mohamed AE, Yasawy MI, et al. Protean manifestations of gastrointestinal tuberculosis. *J Clin Gastroenterol* 1995;20:225–32.
- Fica A, Belletti J, Cruzat C, Rojas D, Montalva M. Intestinal tuberculosis: analysis of clinical cases and autopsy. *Rev Med Chile* 1991;119:1153–9.
- Hibbs RG, Kamal M, Farid Z. Abdominal tuberculosis in Cairo, Egypt. *Trans R Soc Trop Med Hyg* 1994;88:317–8.
- Das P, Shukla HS. Clinical diagnosis of abdominal tuberculosis. *Br J Surg* 1976;63:941–6.
- Bhansali SK. Abdominal tuberculosis. Experiences with 300 cases. *Am J Gastroenterol* 1977;67:324–37.
- Prakash A. Ulcero-constrictive tuberculosis of the bowel. *Int Surg* 1978;63:23–9.
- Tandon RK, Sarin SK, Bose SL, Berry M, Tandon BN. A clinico-radiological reappraisal of intestinal tuberculosis - changing profile? *Gastroenterol Jpn* 1986;21:17–22.
- Vij JC, Malhotra V, Choudhary V, et al. A clinicopathological study of abdominal tuberculosis. *Indian J Tubercul* 1992;39:213–20.
- Singh V, Jain AK, Agrawal AK, et al. Clinicopathological profile of abdominal tuberculosis. *Br J Clin Pract* 1995;49:22–4.
- Al-Bahrani ZR, Al-Saleem T. Intestinal tuberculosis in Iraq: a study of 50 cases. *Int Surg* 1982;67:483–5.
- Al-Hadeedi S, Walia HS, Al-Sayer HM. Abdominal tuberculosis. *Can J Surg* 1990;33:233–7.
- Lewis EA, Kolawole TM. Tuberculosis ileocolitis in Ibadan: a clinico-radiological review. *Gut* 1972;13:646–53.
- Al-Quorain A, Satti MB, Al-Freihy HM, Al-Gindan YM, Al-Awad N. Abdominal tuberculosis in Saudi Arabia: a clinico-pathological study of 65 cases. *Am J Gastroenterol* 1993;88:75–9.
- El Masri SH, Boulos P, Malick MOA. Abdominal tuberculosis in Sudanese patients. *East Afr Med J* 1977;54:319–26.
- Innes JA. Non-respiratory tuberculosis. *J R Coll Physicians Lond* 1981;15:227–31.
- Klimach OE, Ormerod LP. Gastrointestinal tuberculosis: a retrospective review of 109 cases in a district general hospital. *Q J Med* 1985;56:569–78.
- Addison NV. Abdominal tuberculosis - a disease revived. *Ann R Coll Surg Engl* 1983;65:105–11.
- Jayanthi V, Probert CS, Sher KS, Wicks AC, Mayberry JF. The renaissance of tuberculosis. *Dig Dis* 1993;11:36–44.
- Palmer KR, Patil DH, Basran S, Riordan JF, Silk DBA. Abdominal tuberculosis in urban Britain: a common disease. *Gut* 1985;26:1296–305.
- Probert CS, Jayanthi V, Wicks AC, Carr Locke D, Garner P, Mayberry JF. Epidemiological study of abdominal tuberculosis among Indian migrants and the indigenous population of Leicester, 1972–89. *Gut* 1992;33:1085–9.
- Mandal BK, Schofield PF. Abdominal tuberculosis in Britain. *Practitioner* 1976;216:683–9.
- Findlay JM, Addison NV, Stevenson DK, Mirza ZA. Tuberculosis of the gastrointestinal tract in Bradford, 1967–77. *J R Soc Med* 1979;72:587–90.
- Lambrianides AL, Ackroyd N, Shorey BA. Abdominal tuberculosis. *Br J Surg* 1980;67:887–9.
- Sharp JF, Goldman M. Abdominal tuberculosis in East Birmingham: a 16 year study. *Postgrad Med J* 1987;63:539–42.
- Dineen P, Homan WP, Grafe WR. Tuberculous peritonitis: 43 years experience in diagnosis and treatment. *Ann Surg* 1976;184:717–22.
- Homan WP, Grafe WR, Dineen P. A 44-year experience with tuberculous enterocolitis. *World J Surg* 1977;1:245–50.
- Sherman S, Rohwedder JJ, Ravikrishnan KP, et al. Tuberculous enteritis and peritonitis: Report of 36 general hospital cases. *Arch Intern Med* 1980;140:506–8.
- McGee GS, Williams LF, Potts J, Barnwell S, Sawyers JL. Gastrointestinal tuberculosis: resurgence of an old pathogen. *Am Surg* 1989;55:16–20.
- Guth AA, Kim U. The reappearance of abdominal tuberculosis. *Surg Gynecol Obstet* 1991;172:432–6.
- Ko CY, Schmit PJ, Petrie B, Thompson JE. Abdominal tuberculosis: the surgical perspective. *Am Surg* 1996;62:865–8.
- Rosengart TK, Coppa GF. Abdominal mycobacterial infections in immunocompromised patients. *Am J Surg* 1990;159:125–31.
- Tandon HD. The pathology of intestinal tuberculosis and distinction from other diseases causing stricture. *Trop Gastroenterol* 1981;2:77–93.
- Goldman KP. AIDS and tuberculosis. *Tubercle* 1988; 69: 71–2.
- Fee MJ, Oo MM, Gabayan AE, Radin DR, Barnes PF. Abdominal tuberculosis in patients infected with the human immunodeficiency virus. *Clin Infect Dis* 1995;20:938–44.
- Watters DAK. Surgery for tuberculosis before and after HIV infection: a tropical perspective. *Br J Surg* 1997;84:8–14.
- Iseman MD. Treatment of multidrug resistant tuberculosis. *N Engl J Med* 1993;329:784–91.
- Joshi MJ. The surgical management of intestinal tuberculosis - a conservative approach. *Indian J Surg* 1978;40:79–83.
- Shah P, Ramakantan R. Role of vasculitis in the natural history of abdominal tuberculosis - evaluation by mesenteric angiography. *Indian J Gastroenterol* 1991;10:127–30.
- Shah S, Thomas V, Mathan M, et al. Colonoscopic study of 50 patients with colonic tuberculosis. *Gut* 1992;33:347–51.
- Singh V, Kumar P, Kamal J, Prakash V, Vaiphei K, Singh K. Clinico-colonoscopy profile of colonic tuberculosis. *Am J Gastroenterol* 1996; 91:565–8.
- Chen WS, Leu SY, Lin JK, Lin TC. Trend of large bowel tuberculosis and relation with pulmonary tuberculosis. *Dis Colon Rectum* 1992; 35:189–92.
- Essop AR, Posen JA, Hodgkinson JH, Segal I. Tuberculous hepatitis: a clinical review of 96 cases. *Q J Med* 1984;212:465–77.
- Katariya RN, Sood S, Rao PG, Rao PLNG. Strictureplasty for tubercular strictures of the gastrointestinal tract. *Br J Surg* 1977;64:496–8.
- Pujari BD. Modified surgical procedures in intestinal tuberculosis. *Br J Surg* 1979;66:180–1.
- Dandapat MC, Mohan Rao V. Management of abdominal tuberculosis. *Indian J Tubercul* 1985; 32:126–9.
- Sharma AK, Aggarwal LD, Sharma CS, Sarin YK. Abdominal tuberculosis in children: experience over a decade. *Indian Paediatr* 1993; 30:1149–53.
- Tandon RK, Bansal R, Kapur BML, Shrinivas. A study of malabsorption in intestinal tuberculosis: stagnant loop syndrome. *Am J Clin Nutr* 1980;33:244–50.
- Monkemuller KE, Lewis JB Jr. Massive rectal bleeding from colonic tuberculosis. *Am J Gastroenterol* 1996;91:1439–41.
- Puri AS, Vij JC, Chaudhary A, et al. Diagnosis and outcome of isolated rectal tuberculosis. *Dis Colon Rectum* 1996;39:1126–9.
- Shukla HS, Gupta SC, Singh G, Singh PA. Tubercular fistula in ano. *Br J Surg* 1988;75:38–9.
- Alyoune M, Nadir S, Merzouk M, et al. Tuberculous anal fistulas. *Ann Gastroenterol Hepatol* 1994;30:9–11.
- Myers SR. Tuberculous fissure-in-ano. *J R Soc Med* 1994;87:46.
- Dandapat MC, Mukherjee LM, Behera AN. Fistula-in-ano. *Indian J Surg* 1990;52:265–8.
- Khanna AK, Kumar K, Mishra MK, Jain AK, Gupta JP. Duodenal tuberculosis: presentation in a surgical unit. *Ann Natl Acad Med Sci (India)* 1994;30:282–4.
- DiPlacido R, Pietroletti R, Leardi S, Simi M. Primary gastroduodenal tuberculous infection presenting as pyloric outlet obstruction. *Am J Gastroenterol* 1996;91:807–8.
- Wells AD, Northover JMA, Howard ER. Abdominal tuberculosis: still a problem today. *J R Soc Med* 1986;79:149–53.
- Ali W, Sikora SS, Bannerjee D, et al. Gastroduodenal tuberculosis. *Aust NZ J Surg* 1993;63:466–7.
- Monge E, Lozano R, Salazar S. Esophageal tuberculosis. *Am J Gastroenterol* 1992;87:156.
- Hashimoto M, Koyama H, Noie T, Shibayama K, Kitamura N. Abdominal tuberculosis mimicking a pancreatic neoplasm. *Surg Today* 1995; 25:365–8.
- Mokoena J, Bairagi N. Acute tuberculous pancreatitis associated with HIV infection. *Trop Doct* 1994;24:172–3.
- Sozbilen M, Erhan Y, Koyuncu A. Tuberculosis of the pancreas. *Br J Surg* 1992;79:802.
- Bastani B, Shariatzadeh MR, Dehdashti F. Tuberculous peritonitis: report of 30 cases and review of the literature. *Q J Med* 1985;56:549–57.
- Diab S, Nema TA, Zidan FA. Portal hypertension complicating abdominal tuberculosis. *Acta Chirug Scand* 1990;156:495–7.
- Murphy TF, Gray GF. Biliary tract obstruction due to tuberculous adenitis. *Am J Med* 1980; 68: 452–4.

- 69 Kapoor VK, Gupta S, Sikora SS, Chattopadhyay TK, Sharma LK. Acute tubercular abdomen. *Indian J Surg* 1991; 53: 71-5.
- 70 Eggleston FC, Deodhar MC, Kumar A. Tuberculous perforation of the bowel - results in 21 cases. *Trop Gastroenterol* 1983; 4: 164-7.
- 71 Kakkar A, Aranya RC, Nair SK. Acute perforation of small intestine due to tuberculosis. *Aust NZ J Surg* 1983; 55: 381-3.
- 72 Dhar A, Bagga D, Taneja SB. Perforated tubercular enteritis of childhood: a ten year study. *Indian J Pediatr* 1990; 57: 713-6.
- 73 Kapoor VK, Kriplani AK, Chattopadhyay TK, Sharma LK. Tuberculous perforations of the small intestine. *Indian J Tubercul* 1986; 33: 188-9.
- 74 Yachha SK, Misra S, Malik AK, Nai B, Mehta S. Spectrum of malabsorption syndrome in north Indian children. *Indian J Gastroenterol* 1993; 12: 120-5.
- 75 Sharma LK, Gupta S, Soin AS, Sikora SS, Kapoor VK. Generalised peritonitis - the tropical spectrum. *Jpn J Surg* 1991; 21: 72-7.
- 76 Nistal de Paz F, Herrero Fernandez B, Perez Simon R, et al. Pelvic peritoneal tuberculosis simulating ovarian carcinoma. *Am J Gastroenterol* 1996; 91: 1660-1.
- 77 Underwood MJ, Thompson MM, Sayers RD, Hall AW. Presentation of abdominal tuberculosis to general surgeons. *Br J Surg* 1992; 79: 1077-9.
- 78 Walia HS, Khafagy AR, al Sayer HM, et al. Unusual presentations of abdominal tuberculosis. *Can J Surg* 1994; 37: 300-6.
- 79 Anonymous. Abdominal tuberculosis in Britain. *BMJ* 1977; 1: 1557.
- 80 Kapoor VK. Koch's or Crohn's? *Int J Clin Pract* 1997; 51: 246-7.
- 81 Misra A, Khanduri A, Jain M, Gupta RK, Choudhuri G. Colonic tuberculosis presenting as diffuse pancolitis. *Indian J Gastroenterol* 1996; 15: 105.
- 82 Aguado JM, Pons F, Casafont F, et al. Tuberculous peritonitis: a study comparing cirrhotic and non-cirrhotic patients. *J Clin Gastroenterol* 1990; 12: 550-4.
- 83 Chawla TC, Sharma A, Kiran U, Bhargava DK, Shrinivas, Tandon BN. Serodiagnosis of intestinal tuberculosis by enzyme immunoassay and soluble antigen fluorescent antibody tests using a saline extracted antigen. *Tubercle* 1986; 67: 55-60.
- 84 Bhargava DK, Dasarathy S, Shrinivas, Kushwaha AKS, Duphare H, Kapur BML. Evaluation of enzyme-linked immunosorbent assay using mycobacterial saline-extracted antigen for the serodiagnosis of abdominal tuberculosis. *Am J Gastroenterol* 1992; 87: 105-8.
- 85 Kashima K, Oka S, Tabata A, et al. Detection of anti-cord factor antibodies in intestinal tuberculosis for its differential diagnosis from Crohn's disease and ulcerative colitis. *Dig Dis Sci* 1995; 40: 2630-4.
- 86 Lundstedt C, Nyman R, Brismar J, Hugosson C, Kagevi I. Imaging of tuberculosis. II. Abdominal manifestations in 112 patients. *Acta Radiol* 1996; 37: 489-95.
- 87 Kapoor VK, Chattopadhyay TK, Sharma LK. Radiology of abdominal tuberculosis. *Australas Radiol* 1988; 32: 365-7.
- 88 Singh MM, Bhargava AN, Jain KP. Tuberculous peritonitis. An evaluation of pathogenetic mechanisms, diagnostic procedures and therapeutic measures. *N Engl J Med* 1969; 281: 1091-4.
- 89 Sheikh M, Abu Zidan F, Al Hilaly M, Behbehani A. Abdominal tuberculosis: comparison of sonography and computed tomography. *J Clin Ultrasound* 1995; 23: 413-7.
- 90 Kedar RP, Shah PP, Shirde RS, Malde HM. Sonographic findings in gastrointestinal and peritoneal tuberculosis. *Clin Radiol* 1994; 49: 24-9.
- 91 Liu KW, Chan YL, Tseng R. Childhood abdominal tuberculosis. The role of echo-guided fine needle aspiration in its management. *Surg Endosc* 1994; 8: 326-8.
- 92 Bankier AA, Fleischmann D, Wiesmayr MN, et al. Update: abdominal tuberculosis - unusual findings on CT. *Clin Radiol* 1995; 50: 223-8.
- 93 Lisehora GB, Peters CC, Lee YT, Barcia PJ. Tuberculous peritonitis - do not miss it. *Dis Colon Rectum* 1996; 39: 394-9.
- 94 Ha HK, Jung JI, Lee MS, et al. CT differentiation of tuberculous peritonitis and peritoneal carcinomatosis. *AJR* 1996; 167: 743-8.
- 95 Rodriguez E, Pombo F. Peritoneal tuberculosis versus peritoneal carcinomatosis: distinction based on CT findings. *J Comput Assist Tomogr* 1996; 20: 269-72.
- 96 Kochhar R, Rajwanshi A, Goenka MK, et al. Colonoscopic fine needle aspiration cytology in the diagnosis of ileocaecal tuberculosis. *Am J Gastroenterol* 1991; 86: 102-4.
- 97 Anand BS, Schneider FE, El-Zaatari FA, Shawar RM, Clarridge JE, Graham DY. Diagnosis of intestinal tuberculosis by polymerase chain reaction on endoscopic biopsy specimens. *Am J Gastroenterol* 1994; 89: 2248-9.
- 98 Wilkins EGL. Tuberculous peritonitis: diagnostic value of the ascitic/ blood glucose ratio. *Tubercle* 1984; 65: 47-52.
- 99 Dwivedi M, Misra SP, Misra V, Kumar R. Value of adenosine deaminase estimation in the diagnosis of tuberculous ascites. *Am J Gastroenterol* 1990; 85: 1123-5.
- 100 Levine H. Needle biopsy diagnosis of tuberculous peritonitis. *Am Rev Respir Dis* 1968; 97: 889-94.
- 101 Bhargava DK, Shrinivas, Chopra P, et al. Peritoneal tuberculosis: laparoscopic patterns and its diagnostic accuracy. *Am J Gastroenterol* 1992; 87: 109-11.
- 102 Shukla HS, Bhatia S, Naithani YP, Das P, Gupta SC. Peritoneal biopsy for diagnosis of abdominal tuberculosis. *Postgrad Med J* 1982; 58: 226-8.
- 103 Tandon HD, Prakash A. Pathology of intestinal tuberculosis and its distinction from Crohn's disease. *Gut* 1972; 13: 260-9.
- 104 Anand BS, Nanda R, Sachdev K. Response of tuberculous strictures to antituberculous treatment. *Gut* 1988; 29: 62-9.
- 105 Schoffield PF. Abdominal tuberculosis. *Gut* 1985; 26: 1275-8.
- 106 Jayaswal R, Jena PK, Gopinathan VP, Chauhan MS. Recurrent acute tuberculous perforations of the small intestine associated with military tuberculosis of lung. *J Assoc Physicians India* 1986; 34: 817-8.
- 107 Cooke NJ. Treatment of tuberculosis. *BMJ* 1985; 291: 497-8.
- 108 Balasubramanian R, Ramachandran R, Joseph P, et al. Interim results of a clinical study of abdominal tuberculosis. *Indian J Tubercul* 1989; 36: 117-21.
- 109 Haddad FS, Ghossain A, Sawaya E, Nelson AR. Abdominal tuberculosis. *Dis Colon Rectum* 1987; 30: 724-35.
- 110 Parikh AJ. Conservative approach in management of intestinal tuberculosis. *Indian J Surg* 1978; 40: 85-90.
- 111 Arunabh, Kapoor VK, Chattopadhyay TK, Sharma LK. Tuberculous peritonitis presenting as acute abdomen. *Indian J Tubercul* 1986; 33: 190-1.
- 112 Kapoor VK, Sharma LK. Abdominal tuberculosis. *Br J Surg* 1988; 75: 2-3.
- 113 Vanderpool DM, O'Leary JP. Primary tuberculous enteritis. *Surg Gynecol Obstet* 1988; 167: 167-73.
- 114 Jain SK. Tubercular abdomen with acute manifestation. *Indian Med J* 1993; 87: 76-7.
- 115 Lingenfelter T, Zak J, Marks IN, Steyn E, Halkett J, Price SK. Abdominal tuberculosis: still a potentially lethal disease. *Am J Gastroenterol* 1993; 88: 744-50.