

THE RECONSTRUCTION OF THE HAND IN LEPROSY

Hunterian Lecture delivered at the Royal College of Surgeons of England

on

24th October, 1952

by

P. W. Brand, F.R.C.S.

Surgeon, Christian Medical College, Vellore, South India.

LEPROSY IS A disease which affects chiefly two tissues ; skin and peripheral nerves. Through most of his life the patient with leprosy should be a relatively healthy person. His vital organs are not affected, his mind is clear, and his digestion sound. There may be bouts of fever in the acute stages, and distressing complications such as iritis, but these are now readily controllable by the new drugs which the physician has at his disposal.

The fact is, however, that a large proportion of leprosy patients do not live an active life, and depend entirely upon charity for their maintenance, both during the active phase of their disease and after it has become burnt-out or cured.

There are two main reasons for this. One is the social stigma of leprosy, which makes employment a problem, and the other is the paralysis and deformity of the hands and feet which often make any skilled trade out of the question, and which may make it difficult for the patient even to feed or to dress himself.

Physicians have long worked to find a cure for the disease, and now, with the help of the research chemists, are able to offer the patient the prospect of the arrest of his symptoms and the probable eradication of the infection. Welfare organisations and missions are working to dispel the fear and superstition that surround the word "leper," and now it remains the obvious duty of the surgeon to see whether the crippling effects of paralysis can be overcome, and the patient thereby allowed to take his place as an active wage earner and independent citizen.

The reason that a serious attempt to reconstruct the hands of leprosy patients has not been made a long time ago is due, probably, to two popular misconceptions about the effects of this disease. One is that its paralysis is haphazardly progressive and has no well-defined limits ; and therefore healthy muscles used for transplantation might themselves later become paralysed and make the operation useless. The other is that leprosy causes fingers to fall off or become absorbed ; it is not worth trying to mobilise fingers that may not long remain with the patient.

We need not discuss whether these would be valid reasons for withholding surgery, because we shall try to show that they do not represent the full facts.

The paralysis of leprosy certainly appears to be haphazard in some respects. It may be completely asymmetrical, and it may show periods of rapid progress and of complete arrest which are difficult to explain or to

predict, and which seem to bear no relation to the activity of the disease. The paralysis may progress after clinical cure of the disease, and during periods of treatment with the most effective drugs.

However, we have been able to show that in one important respect the paralysis is predictable. It affects only certain nerves and these nerves only at certain anatomical levels. Therefore, when a hand is assessed at any stage in the disease, one may say with some confidence that though certain muscles may become paralysed later, certain others will almost certainly never become paralysed, however far the infection progresses.

We shall not attempt, at this time, to explain the reason for this, but simply append a list of the muscles affecting the hand which, in our experience, are commonly paralysed, and a list of the muscles which we have rarely or never seen paralysed in a series of over a thousand cases of leprosy.

Commonly Paralysed

All the small muscles of the hand, lumbricales, interossei, and muscles of the thenar and hypothenar eminences.

Flexor carpi ulnaris.

Flexor profundus to little finger. (Less commonly.)

Flexor profundus to ring finger. (Rarely.)

Rarely Paralysed (less than 1 per cent.)

All the extensors of the wrist.

The long extensors of the fingers and thumb.

Abductor pollicis longus.

Unparalysed Muscles

Flexor digitorum sublimis, all fingers.

Flexor profundus, index and long fingers.

Flexor pollicis longus.

Flexor carpi radialis.

Palmaris longus.

All upper arm and shoulder muscles.

With regard to absorption, we need only say that we have become convinced from a careful observation of a number of cases, and questioning of many others, that injuries and burns are responsible for almost all of the loss of fingers in leprosy.

The loss of the sensations of pain and temperature make the patients liable to frequent injury, and allow gross carelessness and misuse of wounded and infected fingers. This leads to osteo-myelitis and gangrene and loss of digits. Fig. 1.

It would be going beyond our evidence to state definitely that in the absence of injury leprosy never causes absorption of fingers, but there can be no doubt that the main causes of absorption are preventable, and that, if the patients can be trained to anticipate and avoid the commoner causes of injury and treat their slight wounds with respect and care, there is no reason why they should not keep their fingers intact.

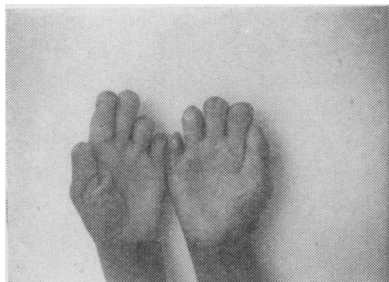


Fig. 1. The hands of an active manual worker, a coolie. These hands have loss of sensation but no paralysis, and have been exposed to repeated trauma and burns. These are still strong and useful hands.

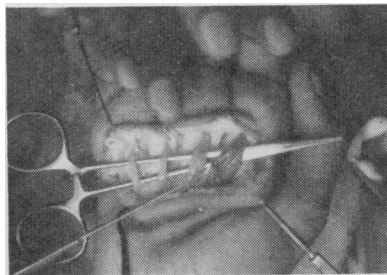


Fig. 2. The lumbrical muscles exposed at operation. The little and ring finger muscles have long been paralysed, the index finger only recently.

Hand disability in leprosy begins usually with some anaesthesia to light touch and temperature sensation at or near the ulnar border of the hand. This spreads to involve the ulnar nerve area of the skin and then the median and radial nerve areas, producing an irregular glove anaesthesia extending proximally up to the elbow and beyond. This anaesthesia deepens to include loss of pin-prick and skin pain, and later some deeper sensations, but even in advanced cases patients retain some position sense in their fingers, and are able to appreciate deep pressure and deep pain.

Paralysis commonly first shows itself in the small muscles of the hand, in the ulnar nerve group. The patient becomes unable to adduct the little finger, and then loses power of abduction and adduction in all fingers, and gets clawing of the little, ring and perhaps long fingers. The pinch becomes a little unstable from loss of the first dorsal interosseus and adductor pollicis and flexor pollicis brevis. When the median nerve becomes affected, the clawing becomes complete in all fingers. The thumb falls back as the thenar muscles are paralysed, and it becomes impossible to oppose the thumb to the fingers in grasp or pinch.

Ultimately there are only three useful functions left to the hand. The first is the closed hook. If some object such as a bucket has to be carried, its handle can be pushed into the curve of the clawed fingers, and the strong flexors will easily maintain the hook position and carry the object. The second is the interdigital squeeze. Small objects like pencils are pushed into interdigital clefts, usually the index-long cleft, and when the fist is clenched, the pencil is held firmly by the adduction that accompanies flexion. The third useful movement is a sideways pinch between the proximal segment of the thumb and the second (index) metacarpal. This is powered by the simultaneous contraction of the flexor pollicis longus and the extensor pollicis longus, and is the most useful movement left to the patient.

The chief disability is thus the loss of the grasp, due to the inability to extend the interphalangeal joints, and the loss of pinch owing to the loss of abduction and opposition of the thumb.

Following paralysis, in the absence of treatment, there develops an increasing stiffness of interphalangeal joints, due to disuse. Chronic sores also develop due to misuse and burns, and to wear and tear of dorsal and interdigital skin which has had to take strains normal to palmar skin.

Once the natural history and pathology of the deformity of leprosy is understood, its surgical treatment may follow the well defined lines that have been worked out by the pioneers of modern hand surgery, such as Sterling Bunnell.

First the superficial sores and ulcers must be soundly healed.

Then the hand must be mobilised as far as possible by a programme of active exercise and physiotherapy, designed to limber up the joints.

Next an operation must be performed for the restoration of lumbrical action, using transplanted long flexors or long extensors; and then an operation for the restoration of opposition to the thumb.

Finally a programme of rehabilitation is necessary.

At the Christian Medical College, Vellore, we have operated upon over 250 clawed fingers, and on 45 thumbs that have lost the power of opposition. Our first cases were done in 1948, and have been followed for four years. As a result of this experience we have reached a few conclusions about the best technique for these leprosy cases.

Preliminary Mobilisation of Joints.

Metacarpophalangeal joints are nearly always mobile and active already. It is only the interphalangeal joints that give trouble as a rule, and these are often stiff in flexion and may be very obstinate. Active exercise is most valuable, and is best done with the metacarpophalangeal joints stabilised in flexion, using the other hand for this purpose or a knuckleduster type of splint. Passive stretching is especially dangerous in leprosy, because violence may easily be used, even by the patient himself, since pain is not a restraining factor. Elastic traction may be used, provided care is taken that too much pressure is not placed on the pulps of the fingers. We have found it useful to apply a light plaster splint (two layers of Gypsona) to each finger in maximum gentle extension. This is removed in one or two days, the finger exercised, and a new splint applied in what will probably be a few degrees more extension. This may be repeated every two days for a few weeks, as long as improvement is being maintained, and regular exercise continued.

Wax baths and oil rubbed into the fingers at exercise times are probably of value.

Preparation for operation

Skin preparation is important, as cracks, sores, and scabies are common when the hands are first seen. These must all be soundly healed before surgery is attempted. We have sometimes operated on the hands of a patient who still has unhealed ulceration on the soles of his feet, provided that the latter are clean and healing. In these cases the feet are covered

with occlusive dressings, and not exposed during the days of hand preparation, and penicillin is given to cover the operation and post-operative period.

We have not found that operations cause any flare-up of leprosy, except in a few cases where there has been prolonged general anaesthesia, and even in these cases the reaction has not been severe. It is probably wise to continue the routine sulphone or other therapy throughout the operative period. We have operated on lepromatous as well as on neural cases, but have avoided operations during acute phases of the disease.

A pre- and post-operative vitamin supplement, at least of B complex and ascorbic acid has been given.

Anaesthesia

Brachial plexus block anaesthesia has been used in nearly all cases. The partial loss of pain sensation that most patients already have has probably contributed to the uniform success which we have had with this method. The only complaint that patients make is of tourniquet discomfort, and if this becomes severe a gas and oxygen or pentothal supplement has to be given.

General Surgical Technique

A bloodless field is, of course, essential, and a pneumatic tourniquet should be used. It is probably wise to keep the pressure below 225 mm. and to release it at the end of an hour or hour and a quarter, as the nerves in leprosy are harmed by prolonged ischaemia. The tourniquet may be reapplied for a second period if necessary. The importance of fine instruments and an atraumatic technique has often been stressed by hand surgeons, and is not less important in leprosy cases. It is also important that all parts of the operation should be carefully planned and that a fairly speedy technique be developed, because the average leprosy hand requires five tendon transfers, and often an arthrodesis as well. The only alternatives are a rather prolonged operation or else repeated operations on the same hand, with increased scarring and long hospitalisation. For any but an experienced hand surgeon it would be wise to operate on two fingers at a time, and on the thumb at a separate session. With increasing experience all five digits can conveniently be operated at one session.

Healing is probably rather slower in leprosy cases and skin stitches may be left in for 14 days. If Bunnell's pull-out wire technique is used the wires should be left in for longer than is advised for healthy patients. Most of our patients are mal-nourished, and part of the delay in healing may be due to this.

Great care should be taken in applying any sort of pressure bandage after operation. Superficial skin necrosis has occurred in some of our cases, under ace bandages that would not have been considered too tightly applied for healthy orthopaedic cases. We have now given up pressure dressings, and use only light plaster splints over gauze dressings, and depend on continuous high elevation of the limb to prevent oedema.

Plaster and other splints must be moulded with extra care because of the patient's inability to appreciate pain or discomfort on excessive pressure. For this reason we prefer light plaster splinting even to the most malleable of metal splints, as only the former can be moulded with finger tip gentleness and precision.

Choice of Operation

1. *For clawed fingers.* We have used two operations for these fingers; Bunnell's sublimis transplantation is the operation of choice for suitable cases, and interphalangeal arthrodesis for the fingers with stiff joints.

Patients are usually offered operation as soon as they themselves feel the need for it, that is when they find that their fingers will not open far enough to grasp the objects which they commonly use. Nothing is lost by waiting and exercising, but there is always the fear that exercises will be discontinued, and then stiffness may begin and soon become irreversible.

There is a simple test that decides whether Bunnell's operation will benefit a finger. The metacarpophalangeal joint is passively flexed by pressing the proximal phalanx forwards from the dorsal surface and then the patient is instructed to extend the interphalangeal joints. The extent to which he then succeeds in straightening his finger is about the extent to which Bunnell's operation will enable him to do it without help. If he makes a strong attempt, but does not get very far, it is worth sending him back for further exercises and physiotherapy, and then a second test may be made. It is very important to keep records of the range of joint movement at each stage of progress, measured with a protractor which has a swinging arm. Even very good guesswork on angles can be quite a long way out, especially if a different surgeon makes the second assessment.

Bunnell's operation is well worth doing even if the best that a patient can do is well short of a straight finger, because the chief disability of clawing is not so much the failure of the finger to become straight, but that it begins its flexion movement by closing its interphalangeal joints before its metacarpophalangeals, *i.e.*, it curls up into the palm already clenched. This feature of the clawed finger is completely cured by Bunnell's operation even when absolute straightness is not achieved.

We have found, however, that, if the patient is not able to extend his finger beyond 90 degrees at the proximal interphalangeal joint, even when his metacarpophalangeal joint is stabilised, then Bunnell's operation is usually a failure. It is in these cases that we advise inter-phalangeal arthrodesis.

In a few cases the impression may be gained that the skin is the chief obstacle to extension, and then a Z-plasty may give a better extension, or a flap of dorsal skin may be turned volarwards, but our results in these cases have been disappointing. Arthrodesis gives a strong useful hand, so is really the operation of choice for flexion contractures.

The angle for arthrodesis depends upon the trade which the patient is to follow, but for carpenters and most manual workers we like an angle of 90 degrees for the long, ring, and little fingers to give a grasp against the palm, and a wider angle for the index finger to meet the pulp of the thumb in a pinch. This angle should be decided after the thumb has been reconstructed and may be about 130 degrees.

The proximal interphalangeal joint is the only one that usually needs to be arthrodesed, but if the terminal joint is too sharply flexed that may be fused as well.

In Bunnell's operation a midlateral incision is made on each side of each finger, from the web down to the proximal interphalangeal joint and the edge of the extensor expansion is defined. The lumbrical tendon is exposed and its canal identified. The flexor sheath is then opened near the interphalangeal joint and the flexor sublimis tendon divided near its insertion. It is split back to where it surrounds the profundus tendon, and released.

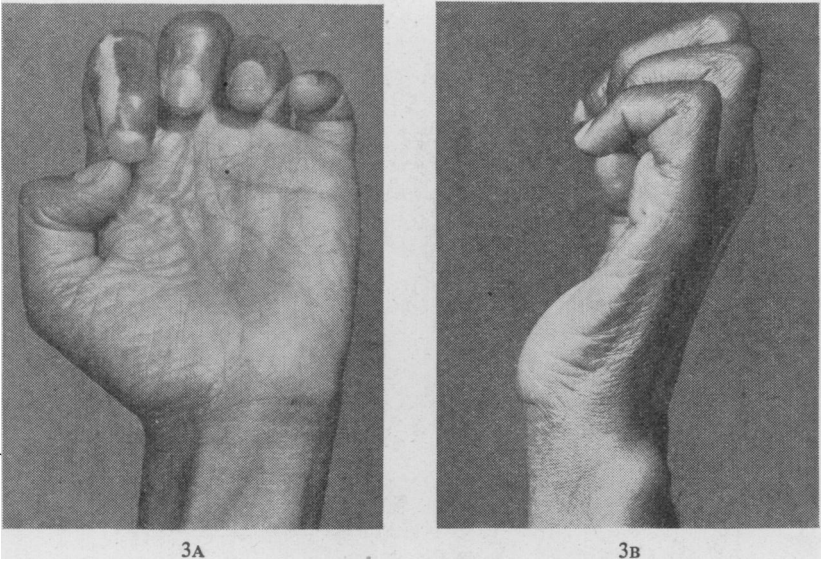
The palm is opened by a transverse incision just proximal to the distal crease, and the sublimis tendons withdrawn into the palm, and the two halves split back for about $2\frac{1}{2}$ inches. The lumbrical canals are opened up from the palmar end and each strand of sublimis tendon is passed down a canal to one side of a finger. Each half is pulled into the finger incision, passed through a slit in the lumbrical tendon and sutured to the dorsum and edge of the extensor expansion, just proximal to the joint.

Bunnell advises that each half of each tendon should be inserted into the same side of two adjacent fingers, that is, the index finger sublimis should go to the lateral side of the index and to the lateral side of the long, while the sublimis from the long finger might go to the medial side of the index and the medial side of the long. This is so that a certain amount of side to side movement may be obtained.

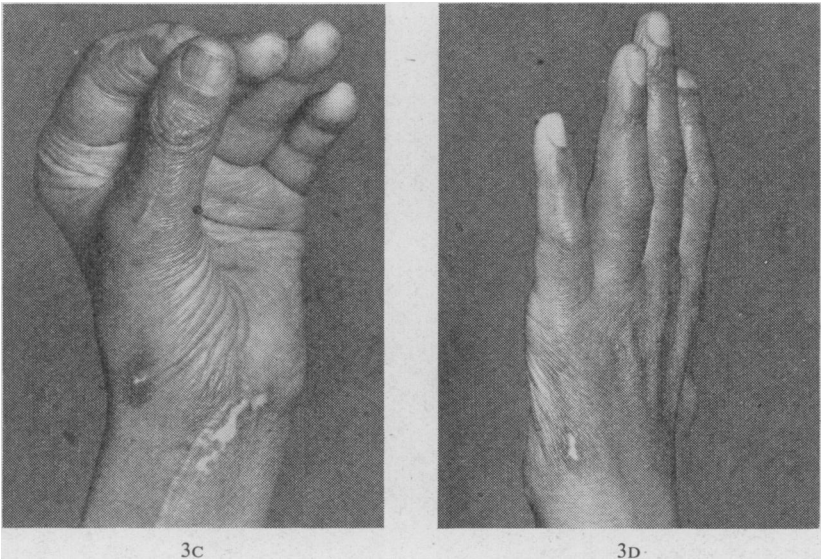
Details of anatomy and operative technique are fully described in Bunnell's "Surgery of the Hand" and it is not our purpose here to discuss any operative procedures in detail, but simply to establish the principle that such procedures are applicable to patients with leprosy.

We have introduced a few minor modifications of technique into this operation, the most useful of which was suggested to us by Dr. William White when he visited us. We now operate on only one side of each finger and attach the tendon transplants only to the radial side of each finger. We find that it gives us the following advantages: (1) A saving of tendons for transplantation. We use the index finger tendon for the radial side of the index finger, the long finger tendon is split and used half for the long finger and half for the ring finger, and the little finger tendon is used only for the little finger. This leaves the ring finger sublimis for use on the thumb for the restoration of opposition. (2) A great saving of time. Four incisions are eliminated. (3) A better stabilisation of the index finger against adduction strains in pinching. The loss of side to side

THE RECONSTRUCTION OF THE HAND IN LEPROSY



Figs. 3A and 3B. Neural leprosy with complete paralysis of all small muscles of hand. Median and ulnar nerves affected. Typical attempt at pinch.



Figs. 3c and 3D. The same patient three months later, following Bunnell's operation on all fingers, and transplantation of flexor sublimis from ring finger to thumb, passing through pulley at pisiform bone.

(This operation was performed at the Hillingdon Hospital, Middlesex. We are grateful for the cooperation of the staff, and for these photographs.)

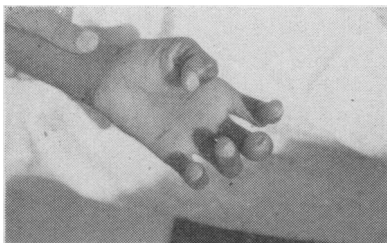


Fig. 4A. Claw hand with thenar paralysis. Attempt to extend fingers and oppose thumb.

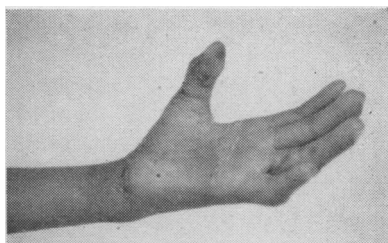


Fig. 4B. Same hand one month later after Bunnell's operation and flexor sublimis transplantation from ring finger to thumb.

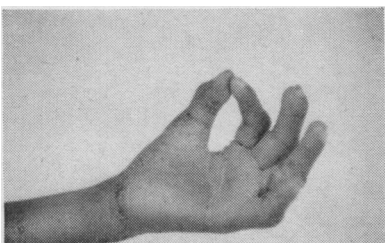


Fig. 4C. Same hand, showing post-operative pinch.

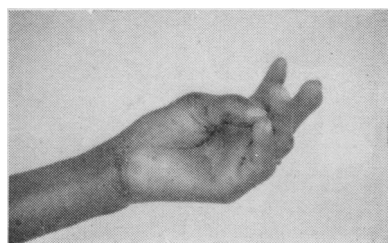


Fig. 4D. Same hand showing post-operative range of opposition.

NEURAL LEPROSY

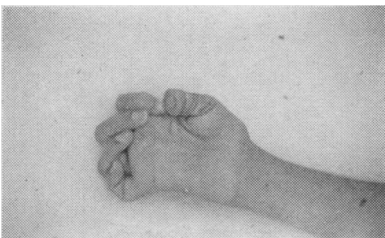


Fig. 5A. Complete claw hand and thenar paralysis of many years' standing. Attempt to extend fingers and oppose thumb.

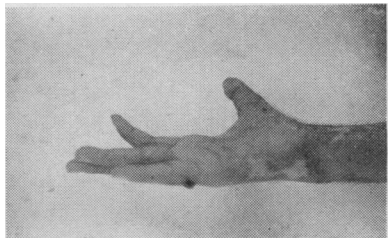


Fig. 5B. Same hand after Bunnell's operation to all fingers and flexor sublimis transplantation from ring finger to thumb.

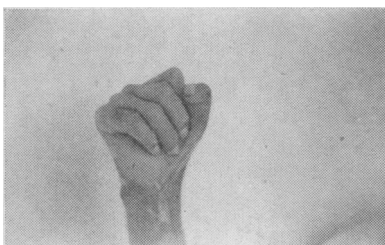

Fig. 5C. Same hand in grasp position, post-operative.

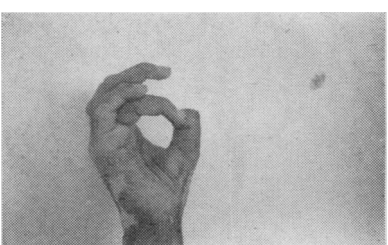


Fig. 5D. Same hand showing pinch, post-operative. Note the interphalangeal joint of the thumb has not been arthrodesed.

movement does not seem to be important, as we had not been very successful in educating our patients in lateral movements of the fingers even with the original technique. The loss of fine movements is in any case not so serious when there is loss of sensation in the hands, because the patients are unable to use fine varied movements in their trades owing to the clumsiness that comes from loss of touch. They do most of their work through the medium of tools, and therefore we concentrate on the production of a strong simple grasp and pinch. The radial deviation that might be expected to result from this one-sided operation has not, in fact, been observed, whereas there were one or two cases of ulnar deviation seen among the earlier cases that had the original procedure.

2. *For restoration of opposition to thumb.* In the operation to restore opposition to the thumb it is important that the following of Bunnell's rules should be followed. The new tendon should run from the base of the proximal phalanx towards the pisiform bone or to a point about half an inch to its radial side. The new tendon should run in a subcutaneous tunnel. It should cross the summit of the metacarpophalangeal joint, or at least a point dorsal to the fulcrum of the joint (the tendon of insertion of the abductor pollicis brevis is a good landmark of this fulcrum). With regard to the choice of tendon and the point of its insertion, and other matters, Littler has given a fine exposition. We are in full agreement with him that the flexor sublimis to the ring finger gives a far better result than any wrist flexor, or palmaris longus, both because of its better range of excursion and because a tendon suture at the wrist level is avoided. The point of insertion may be into the bone on the ulnar side of the base of the phalanx, or into the extensor longus tendon just distal to the joint. It is probably an advantage to suture this tendon under somewhat greater tension than normal.

We have no new contribution to make on the subject of the shrinkage of the thumb web in long-standing cases, and the transposition of the extensor longus pollicis tendon when it restricts opposition. These matters are dealt with fully in the literature.

It is well known that in complete small muscle paralysis of the hand the power of extending the terminal joint of the thumb becomes lost, following the loss of the stabilizers of the proximal joint. We do not think it has been sufficiently emphasised how disabling this can be. The position of function of the thumb is usually pictured as making an O between thumb and index finger. In actual fact the O position is rarely used except in picking up small objects off a flat surface. The normal position of function of the thumb is with the terminal joint in extension for pinch and very slight flexion for grasp. The pinch with the terminal joint flexed is not strong, and is particularly unstable when sensation is imperfect. It is a finger-tip pinch instead of a pulp pinch.

In early cases some power of extension seems to return to the terminal joint after an operation for opponens replacement, but in later cases it does not return, even if the new tendon is inserted into the

extensor longus tendon. In these cases we find the thumb is much more useful if the terminal joint is arthrodesed in extension.

In the exceptional cases in which the extensors of the wrist and fingers are paralysed, the radiocarpal joint should certainly be arthrodesed and wrist flexors used for finger extension.

Partial loss of digits from previous injuries need not deter the surgeon from reconstruction of the rest of the hand. In fact hands that have suffered some absorption will often be found to belong to the most keen and active patients, with fairly good forearm muscles. It is their strength and activity that has exposed them to the hazards of injury. The grossly paralysed hand often has intact digits, because the paralysis has prevented any active use and exposure to trauma.

It is quite exceptional to find a hand so damaged or paralysed by leprosy that it is not possible to restore some useful grasp and pinch, and it has been encouraging to find that, in cases in which attempts have been made to reconstruct very bad hands, subsequent use has resulted in still further improvement, and has well justified the intervention.

Rehabilitation

When all tendon transfers are completed a leprosy patient is left with a fairly mobile, active hand, with fair strength in grasp and pinch, and with position sense, but without cutaneous sensation.

Such a hand is clumsy in fine movements, and easily damaged, especially by burns.

Patients on discharge are liable to get quickly discouraged finding that they cannot even now compete with healthy workers, and soon return to their old occupation of begging.

It is of great importance that in the post-operative phase the patients should be shown how to make the best use of their hands and be taught trades in which their skill and dexterity may compete on equal terms with others with normal hands.

We have studied this matter with some care, and our experience is that these patients do well in a trade or craft in which all the work is done with tools and handles, and none or very little with direct finger manipulation. Basket making, at which blind people excel, is an example of a completely unsuitable trade, as so much of the weaving depends upon touch reflexes.

Simple carpentry is quite within the power of most patients, provided some care is taken to see that the handles of all tools are adjusted where necessary to fit the strongest part of the grasp. Handles of a diameter of one to one and a half inches are usually good for chisels and screw-drivers. Pliers and forceps should be fitted with springs to keep the handles open about three inches apart, and be about an inch or an inch and a half apart when closed. Scissors, similarly, should have the ring handles removed and simple spring-open grasp handles fitted. All tools should be kept on a rack above the bench with the handles projecting, so that time is not lost in fumbling to pick up tools from a flat surface.

THE RECONSTRUCTION OF THE HAND IN LEPROSY

Nails and screws should be kept in racks, and handled with forceps rather than fingers. If small machines such as jig-saws can also be supplied to do tedious parts of the work, then these men are well able to produce good work at a speed which will enable them to earn their living.

There are many other trades which may be similarly studied and adjusted to become suitable for hands without sensation.

At the same time that the trade is being taught, the patient must also be helped to understand the need for care of his hands.

Every day his hands should be inspected for small cuts or abrasions. If any are found, their cause must be sought, and explained, and their recurrence avoided. A simple first aid dressing box, preferably using ready cut adhesive dressings should be kept in the homes and workshops of all patients, and the danger of continuing to use an infected finger emphasised.

If the rehabilitation team enters with sympathy and enthusiasm into this matter of care of the hands, and regards with real horror and distress the small injuries that the patients tend to ignore, then it will be found that the patients themselves will soon develop a new respect for their hands. They will begin to take a pride in the fingers which they had previously tried to hide, and will take trouble to avoid the trauma which previously had not bothered them because it did not hurt.

REFERENCES

- BRAND, P. W. (1950) The Orthopaedic care of leprosy patients. *J. C Med. Assn. India.*
- BUNNELL, S. (1938) Opposition of the thumb. *J. Bone Jt. Surg.* **20**, 269-284.
- _____ (1942) Surgery of the intrinsic muscles of the hand other than those producing opposition of the thumb. *J. Bone Jt. Surg.* **24**, 1-31.
- _____ (1948) *Surgery of the hand.* 2nd edit. Philadelphia, Lippincott.
- GOLDNER, J. L. and IRWIN, C. E. (1950) Analysis of paralytic thumb deformities. *J. Bone Jt. Surg.* **32A**, 627.
- IRWIN, C. E. and EYLER, D. L. (1951) Surgical rehabilitation of the hand and fore-arm disabled by polio. *J. Bone Jt. Surg.* **33A**, 825.
- LITTLER, J. W. (1949) Tendon transfers and arthrodeses in combined median and ulnar nerve paralysis. *J. Bone Jt. Surg.* **31A**, 225.
- LUCKEY, C. A. and MCPHERSON, S. R. (1947) Tendinous reconstruction of the hand following irreparable injury to the peripheral nerves. *J. Bone Jt. Surg.* **29**, 560.
- MAYER, LEO (1916) The physiological method of tendon transplantation. *Surg. Gynec. Obstet.* **22**, 182-197, 298-306, 472-481.
- NEY, K. W. (1921) Tendon transplant for intrinsic hand muscle paralysis. *Surg. Gynec. Obstet.* **33**, 342.
- SLOCUM, D. B. and PRATT, D. R. (1926) Disability evaluation for the hand. *J. Bone Jt. Surg.* **28**, 491.
- STEINDLER, A. and MARXER, J. L. (1946) *The traumatic deformities and disabilities of the upper extremity.* Springfield, Thomas, p. 422.