

Radiology for the surgeon

Musculoskeletal case 38

Presentation

A 31-year-old previously healthy man presented with swelling in his left foot, with a blue discolouration for 4

years. On examination, he had marked swelling over the medial aspect of the first metatarsal bone of his left foot. Plain films were normal (not shown). On the basis of the soft tissue swelling, we performed magnetic resonance imaging.

Figure 1 is a representative axial T_1 -weighted image, and Figure 2 is a representative coronal fat saturated proton density sequence.

From these imaging characteristics, what is your diagnosis?

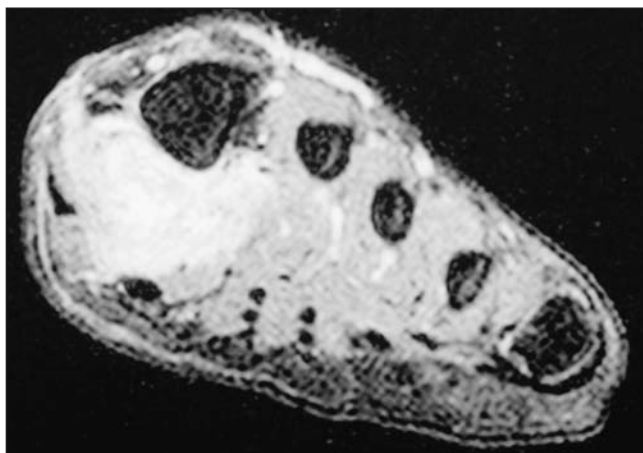


FIG. 1. Axial T_1 -weighted magnetic resonance image of the foot.

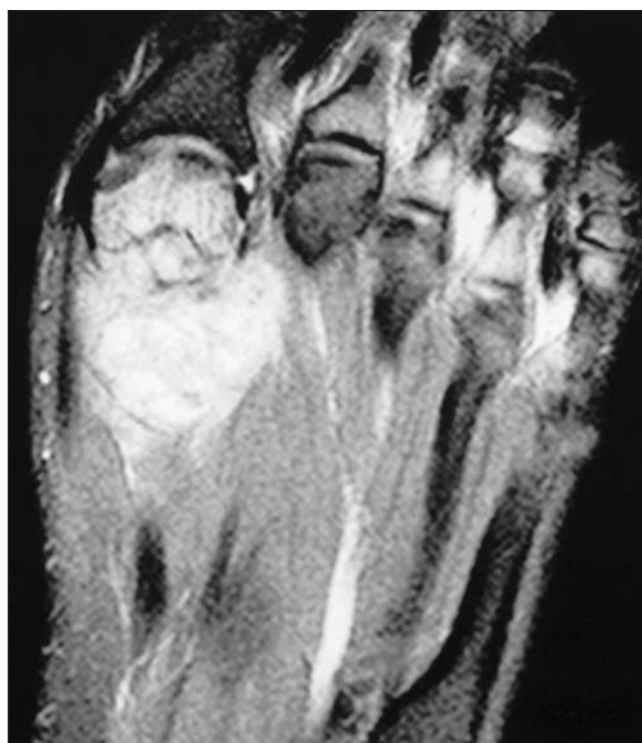


FIG. 2. Coronal fat saturated proton density sequence magnetic resonance image of the foot.

Submitted by Nizar A. Al-Nakshabandi, MD, and Peter L. Munk, MD, Department of Radiology, Vancouver General Hospital, Vancouver BC.

Correspondence to: Dr. Peter L. Munk, Professor, Department of Radiology, Vancouver General Hospital and Health Sciences Centre, 855 West 12th Ave., Vancouver BC V5Z 1M9; fax 604 875-4723; peter.munk@vch.ca

Inquiries about this section should be directed to the section editor: Dr. Peter L. Munk, Professor, Department of Radiology, Vancouver General Hospital and Health Sciences Centre, 855 West 12th Ave., Vancouver BC V5Z 1M9; fax 604 875-4723; peter.munk@vch.ca

Diagnosis

Clear cell sarcoma of the foot

The axial T_1 (Fig. 1) and proton density coronal images (Fig. 2) demonstrate a somewhat lobulated, well-defined soft tissue mass, plantar and medial to the distal shaft and metadiaphysis of the first metatarsal bone. The mass is probably arising from the flexor hallucis brevis and displaces abductor hallucis. Focal bone marrow changes are demonstrated as high-signal intensity on the coronal proton density and sagittal STIR weighted images (Fig. 2 and Fig. 3, respectively).

Clear cell sarcoma is a rare malignant soft tissue neoplasm, accounting for less than 1% of soft tissue neoplasms.¹ It was first described by Enzinger in 1965.² Patients are usually in their second to fourth decade of life, with a slight female predominance.¹ A painless mass is the most common presenting symptom,³ although Luca and colleagues⁴ showed pain and tenderness to be present in one-third to one-half of their patients. Clear cell sarcoma has a predilection for the lower extremities; in particular, the foot and ankle are the most common primary sites, accounting for 33%–43% of cases.² The next most common sites are the knee, thigh, hand, forearm, elbow and shoulder.²

Conventional radiographs are usually normal. CT and magnetic resonance imaging (MRI) are required to detect and characterize clear cell sarcoma.¹ MRI shows a homogeneous mass of T_1 and T_2 -weighted images. Sixty-seven percent of lesions were well-defined, with bone destruction seen in 10% of the cases.⁵ Histologically, the mass reveals a cluster of

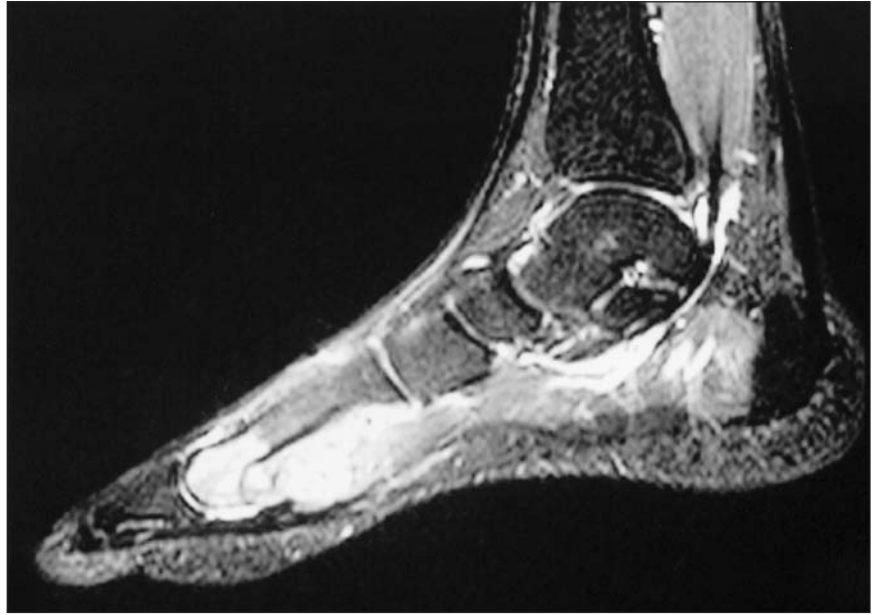

FIG. 3. Sagittal STIR weighted magnetic resonance image showing focal bone marrow changes.

polygonal cells and fibrovascular septae between tumour cells. Clusters are often contiguous with fibres of involved tendons. Both malignant melanoma and clear cell sarcoma have similarities in their immunohistochemical profile, suggesting that these neoplasms are closely related.¹ Therapy consists of radical excision or amputation combined with radiation therapy and chemotherapy. The metastases are mostly found in skeleton and in lungs.⁵

Competing interests: None declared.

References

1. Gelczer RK, Wenger DE, Wold LE. Primary clear cells sarcoma of bone: a unique site of origin. *Skeletal Radiol* 1999;28:240-3.
2. Weiss SW, Goldblum JR. *Soft tissue tumors*. St. Louis: CV Mosby; 1995. In: Chapter 32. Primitive Neuroectodermal Tumors and Related lesions. p. 1265-332.
3. Chung EB, Enzinger FM. Malignant melanoma of soft parts: a reassessment of clear cell sarcoma. *Am J Surg Pathol* 1983;7:405-13.
4. Lucas DR, Nascimento AG, Sim FH. Clear cell sarcoma of soft tissue: Mayo clinic experience with 35 cases. *Am J Surg Pathol* 1992;16:1197-204.
5. Beuckeleer LH, De Schepper AM, Vandevenne JE, et al. MR imaging of clear cell sarcoma (malignant melanoma of the soft parts) a multicenter correlative MRI-pathology study of 21 cases and literature review. *Skeletal Radiol* 2000;29:187-95.