

Review Article

Human pythiosis in Thailand

P. Imwidthaya

Department of Microbiology, Siriraj Hospital, Mahidol University, Bangkok 10700, Thailand

Summary: *Pythium insidiosum* is a protoctista and causes diseases in plants and animals. In Thailand it can cause a unique human infection of three types.

The first type is a subcutaneous lesion in thalassaemic patients, with the pathological findings of a granulomatous reaction, diffuse infiltration, and oedema of the vessel walls. The patients responded to a saturated solution of potassium iodide. The second type is chronic inflammation and occlusion of blood vessels mainly in the lower extremities which results in gangrene or aneurysm formation. This type of infection is only found in thalassaemic patients and leads to amputation of the affected extremities or resection of the involved arteries. The third type is keratitis. This type of infection may or may not be associated with thalassaemia. The clinical signs and symptoms do not differentiate it from other types of mycotic keratitis. The patients end up with keratoplasty, evisceration or enucleation.

Thailand is an agricultural country, and there are plenty of swampy areas and several plants to support the life cycle of *Pythium*. Moreover, many people suffer from thalassaemia, and there is no drug available for *Pythium*. Pythiosis plays an important role in medicine in Thailand.

Introduction

Pythium species are well known as aquatic fungi causing serious economic losses on a wide variety of crops and causing granulomatous disease in horses and cattle.¹ Previous names of the disease include bursatte,² hyphomycosis destruens,³ phycomycosis^{4,5} and swamp cancer.⁶ In 1980, Chandler *et al.* called the disease caused by *Pythium* pythiosis,⁷ although the species was not identified. However, infection in humans had not been described even in areas endemic for animals. It seemed to be a unique human infection endemic in Thailand.

Subcutaneous infection

The first occurrence of the disease presented as subcutaneous lesions at Siriraj Hospital, Mahidol University in 1985.⁸ Two thalassaemic males aged 23 and 26 years from rural areas developed granulomatous ulcers, one on the right arm and the other on the left leg. They were painful and there was a discharge. Swabs from the lesion mounted with potassium hydroxide revealed non-septate hyphae. Histopathology revealed a granulomatous reaction, diffuse infiltration and oedema of the vessels walls. Haematoxylin and eosin staining

showed evidence of the Splendore–Hoeppli phenomenon. Biopsies from the lesions were cultured on Sabouraud dextrose agar. White colonies appeared within 3 days and later turned cream. Lactophenol cotton blue solution revealed broad (4–10 µm in diameter) hyaline hyphae with granular cytoplasm. The organism was able to grow at room temperature (37°C and 40°C). Because the organism was non-sporulating, the culture could not be identified and was sent to the Center for Disease Control (CDC), Atlanta, Georgia, USA. Although the patients had no definite diagnosis, the lesions improved when treated with a saturated solution of potassium iodide.

Systemic infection

The second occurrence of the disease presenting as systemic infection was reported from Ramathibodi Hospital, Mahidol University. This involved five patients, aged 19–46 years, both males and females, seen during 1987–1988.⁹ All were thalassaemic and farmers from rural areas of Thailand. The patients were suffering from pain and swelling of the extremities because of chronic arterial inflammation and occlusion by invasion of the organism, which resulted in gangrene, aneurysm formation and resection of affected arteries or amputation of the affected extremities. Two patients died because of aortic leakage.

Correspondence: P. Imwidthaya, M.D.

Accepted: 17 March 1994

After these two occurrences, there were further sporadic reports. The report from Siriraj Hospital of patients seen from 1983 to 1989¹⁰ contained six thalassaemic patients suffering from necrotizing arteritis with thrombosis predominantly in the main arteries of the lower extremities. Histopathological examination showed that the infection was ascending along the infected arteries. Autopsy findings in some patients showed invasion of the organism in the spleen, kidneys and lungs. The finding corresponded with the report that *P. insidiosum* could be cultured from the blood of patients and that patients died.¹¹ This type of disease occurred only in thalassaemic patients.

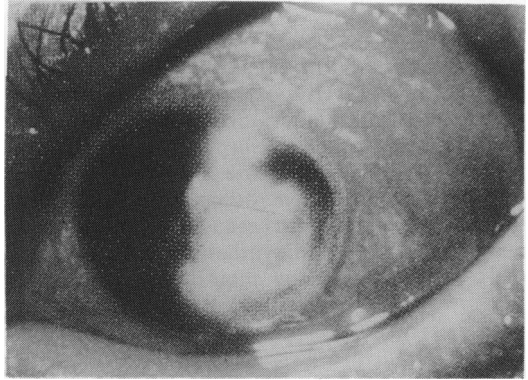


Figure 1 Keratitis from *Pythium insidiosum* on the first admission day.

Keratitis

The third occurrence of the disease presented as keratitis reported first in 1988.¹² After that there were also sporadic reports of keratitis from *P. insidiosum*.¹³⁻¹⁵ (Fig. 1). All patients lived in rural areas and most were farmers, and had a history of abrasion or injury. Clinical signs and symptoms could not be differentiated from those of other mycotic keratitis. The patients end up with keratoplasty, evisceration or enucleation. In contrast to the first and second occurrences, a history of haemoglobinopathy was not important as underlying disease of the patients.

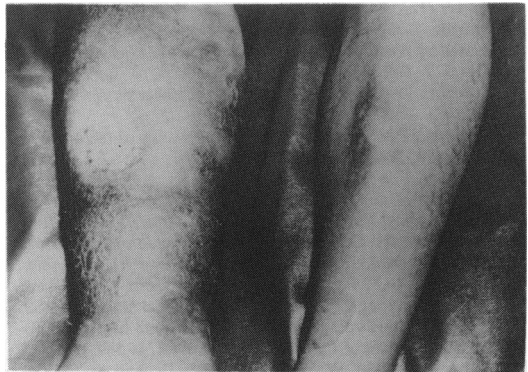

Figure 2 Chronic ulcer of right leg from *Pythium insidiosum*.

Taxonomy

Finally, the organism causing diseases in animals and humans was identified as *Pythium insidiosum* in 1987.¹⁶ The organism was classified in kingdom Protoctista, phylum Oomycota and order Peronosporales.

Immunodiffusion test

An immunodiffusion test for diagnosing and monitoring human pythiosis was developed in the Department of Microbiology, Siriraj Hospital, Mahidol University in 1988.¹¹ When cultured filtrated antigen from *P. insidiosum* was reacted against patients and rabbit antisera, 1-5 precipitin bands occurred, and a line of identity also occurred between patient and rabbit sera. This test is still available in the laboratory.

Pathogenicity and epidemiology

Study of the life cycle of *Pythium insidiosum*¹⁷ shows that it may use more than one species of aquatic plants to complete its life cycle in nature. The authors hypothesized that for pathogenicity,

biflagellated motile zoospores will be attracted by injured tissue. There they lose their flagella, attach to tissue by using a sticky substance, encyst and then germinate by producing germ tubes and later abundant hyphal filaments, which invade the host tissue.

As Thailand is an agricultural country and an aquatic environment, it allows several plants such as rice and corn to survive and support the life cycle of *Pythium*. Furthermore α - and β -thalassaemia are prevalent in South-east Asia, and iron overload in these patients may have participated in the mechanism of infection in subcutaneous and systemic infection.¹⁰

From a retrospective study of the record in the Department of Microbiology, Siriraj Hospital during 1989-1993, there were seven cases of arteritis (Fig. 2) and four cases of keratitis from *P. insidiosum*. The diseases were not correlated with an increased incidence of human immunodeficiency virus infected persons.

Treatment

With awareness of the disease, there is no problem in diagnosis and even zoospores production can be performed in many laboratories.^{14,18} It may play an important role in medicine in Thailand because the people can get the disease from the swampy environment and their occupation. Moreover, there is no drug of choice because *Pythium* does not need sterols for cell wall synthesis as do other fungi. Only early detection by clinical recognition and

microbiological findings as soon as possible, and radical surgical removal of infected lesion and surrounding tissues, followed by irrigation seem to be effective treatment. Also potassium iodide is a chemotherapeutic agent worth trying as an adjunct to aggressive surgical treatment.⁹

Acknowledgement

The author would like to thank Dr Ruengpung Sutthent for reviewing the manuscript.

References

- Mendoza, L. & Alfaro, A.A. Equine pythiosis in Costa Rica: report of 39 cases. *Mycopathologia* 1986, **94**: 123–129.
- Smith, F. The pathology of bursattee. *Vet J* 1884, **19**: 16–17.
- Haan, J. & Hoogkamer, L.J. *Hyphomycosis destruens* equine. *Archiv Wiss Prak Tierheilk* 1903, **29**: 395–410.
- Bridges, C.H. & Emmons, C.W. A phycomycosis of horse caused by *Hyphomyces destruens*. *J. Am Vet Med Assoc* 1968, **138**: 579–589.
- Hutchins, D.R. & Johnston, K.G. Phycomycosis in the horse. *Aust Vet J* 1972, **48**: 269–278.
- Austwick, P.K.C. & Copland, J.W. Swamp cancer. *Nature* 1974, **250**: 284.
- Chandler, F.W., Kaplan, W. & Ajello, L. *A Color Atlas and Textbook of the Histopathology of Mycotic Diseases*. Year Book Medical Publishers Inc., Chicago, 1980, pp. 104–105.
- Thianprasit, M. Cutaneous pythiosis in human-being. *Siriraj 100th Academic Meeting, Mahidol University, Bangkok, Thailand*, 18–22 April, 1988, p. 94 (abstract).
- Sathapatayavongs, B., Leelachaikul, P., Prachaktam, R. *et al.* Human pythiosis associated with thalassemia hemoglobinopathy syndrome. *J Infect Dis* 1989, **159**: 274–280.
- Wanachiwanawin, W., Thianprasit, M., Fucharoen, S. *et al.* Fatal arteritis due to *Pythium insidiosum* infection in patients with thalassemia. *Trans Roy Soc Trop Med Hyg* 1993, **87**: 296–298.
- Imwidththaya, P. & Srimuang, S. Immunodiffusion test for diagnosing human pythiosis. *Mycopathologia* 1989, **106**: 109–112.
- Kunavisarut, S., Prawinwongwuth, K., Lerdvitayasakul, R. & Sathapatayavongs, B. *Pythium* corneal ulcer: cases report. *Thai J Ophthalmol* 1988, **2**: 70–73.
- Imwidththaya, P. & Methitraitur, A. *Pythium insidiosum* keratitis. *The 33rd Siriraj Scientific Annual Meeting*, March 9–13, 1990, pp. 537–542.
- Tantisarasart, T., Patchimkul, P., Wongbuntern, S. & Rangsipanuratn, W. Keratic pythiosis in Songklanagarind Hospital. *Thai J Ophthalmol* 1993, **7**: 39–45.
- Tanphaichitra, D. Tropical disease in the immunocompromised host: melioidosis and pythiosis. *Rev Inf Dis* 1989, **11**: S1629–1643.
- de Cock, A.W.A.M., Mendoza, L., Padhye, A.A., Ajello, L. & Kaufman, L. *Pythium insidiosum* sp. nov., the etiologic agent of pythiosis. *J Clin Microbiol* 1987, **25**: 344–349.
- Mendoza, L., Hernandez, F. & Ajello, L. Life cycle of the human and animal oomycete pathogen *Pythium insidiosum*. *J Clin Microbiol* 1993, **31**: 2967–2973.
- Chaiprasert, A., Samerpitak, K., Wanachiwanawin, W. & Thasnakorn, P. Induction of zoospore formation in Thai isolates of *Pythium insidiosum*. *Mycoses* 1990, **33**: 317–323.