

## Clinical Reports

# Hashimoto's thyroiditis, Sjogren's syndrome and orbital lymphoma

G.T.C. Ko, C.C. Chow, V.T.F. Yeung, H. Chan and C.S. Cockram

*Department of Medicine, Chinese University of Hong Kong, Shatin, NT, Hong Kong*

**Summary:** A 69 year old Chinese housewife presented with periorbital puffiness, and dry eyes and mouth. Subsequent investigations confirmed the presence of Hashimoto's thyroiditis, Sjogren's syndrome and orbital lymphoma. This unusual combination is discussed with reference to previous publications.

### Introduction

Hashimoto's thyroiditis as a risk factor of thyroid lymphoma is well recognized.<sup>1,2</sup> However, primary malignant lymphoma in an extranodal location other than the thyroid gland, in association with Hashimoto's thyroiditis is very uncommon.

Sjogren's syndrome, an autoimmune disease, is associated with many other autoimmune disorders including myasthenia gravis, primary biliary cirrhosis and thyroid diseases.<sup>3</sup> Patients with Sjogren's syndrome have an increased risk of developing malignant lymphoma mainly involving the salivary glands and cervical lymph nodes.<sup>4</sup>

We now report a case with Hashimoto's thyroiditis, Sjogren's syndrome and orbital lymphoma. This patient is interesting in the sense that her lymphoma occurs in an unusual site and there is coexistence of two autoimmune diseases, involving the thyroid and salivary glands.

### History

A 69 year old Chinese housewife had a 2 year history of periorbital puffiness and a 9 month history of dry eyes and mouth. She was admitted because of a recent increase in periorbital swelling.

Physical examination showed a non-tender, firm, diffuse goitre, and enlarged submandibular and parotid glands. She was clinically euthyroid, but she had evidence of severe infiltrative ophthalmopathy with bilateral exophthalmos and impaired eyeball movement especially in the vertical direction, marked periorbital oedema and chemo-

sis. The fundal examination and intraocular pressure were normal.

Initial investigations showed sensitive thyroid stimulating hormone (sTSH) 0.54 mIU/l (0.3–4.0), free thyroxine (fT4) 17.2 pmol/l (7.0–21.8) and positive thyroid anti-microsomal antibody at a titre 1:1,600. Anti-thyroglobulin antibody, anti-nuclear antibody, anti-Ro/anti-La antibody and rheumatoid factor were all negative. ESR was 26 mm in 1 hour. Complete blood picture, renal and liver function tests were all normal.

Computerized tomographic (CT) scan of the orbits showed bilateral exophthalmos, enlargement of both lacrimal glands, enlarged extraocular muscles and periorbital soft tissue infiltration and oedema (Figures 1 and 2). Thyroid ultrasound showed a diffusely enlarged thyroid with multiple haloed hypo/hyperechoic nodules. Also, the submandibular and parotid glands were diffusely enlarged.

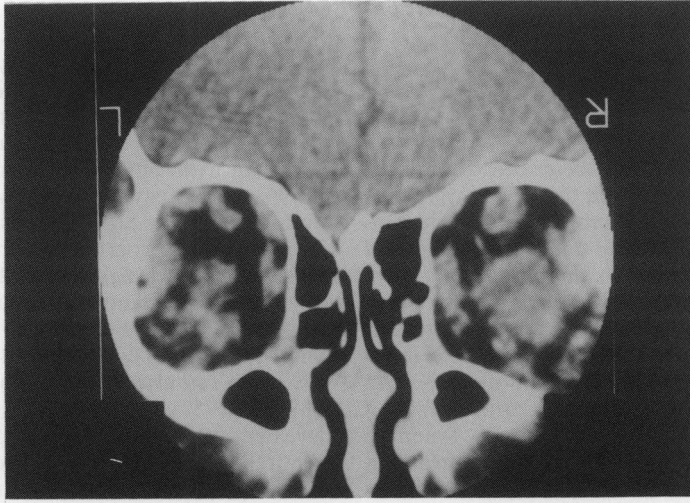
Fine-needle aspiration of the thyroid showed features consistent with Hashimoto's thyroiditis. Sublabial minor salivary gland biopsy showed histology consistent with Sjogren's syndrome.

Pulsed steroid therapy was given using methylprednisolone 500 mg per day for 3 days. This was followed by oral prednisolone 25 mg daily tailing down to 7.5 mg daily. Four weeks after the methylprednisolone, the patient's periorbital oedema improved markedly together with some regression of exophthalmos. The dry mouth and dry eyes remained unchanged.

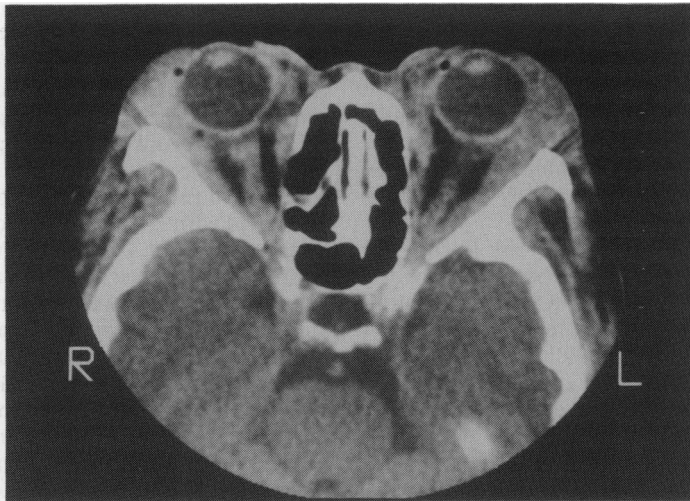One month later, the ophthalmopathy deteriorated again with reduction in eye movement, marked periorbital oedema and chemosis. A second course of pulsed methylprednisolone 500 mg was given. Again, only a transient improvement for a few weeks was achieved.

CT scan of the orbits was repeated and showed

Correspondence: Gary T.C. Ko, M.R.C.P.I., 9/F, Department of Medicine, Prince of Wales Hospital, Shatin, NT, Hong Kong.  
Accepted: 4 October 1993



**Figure 1**



**Figure 2**

**Figures 1 and 2** Coronal and cross-sectional images of CT scan orbits. There are bilateral exophthalmos, swelling of extraocular muscles and periorbital soft tissue oedema

only minimal reduction of extraocular muscle swelling while the bilateral periorbital tissue swelling and infiltrates persisted. At this juncture, because of the unusual background of Hashimoto's thyroiditis and Sjogren's syndrome, we decided to perform a biopsy of the intra-orbital lesion to rule out lymphoma. Biopsy of the periorbital tissue of the right eye confirmed non-Hodgkin's malignant B-cell lymphoma. According to the updated Keil classification, this was a lymphocytic lymphoma, chronic lymphocytic lymphoma (CLL) type and low grade. By Rapport

classification, it was a diffuse, lymphocytic well-differentiated lymphoma.

Therapy was commenced using prednisolone 40 mg daily and chlorambucil 6 mg daily. Prednisolone therapy was tailed off at 3 months while chlorambucil was given for 5 months. There was significant clinical improvement a few weeks after commencement of chemotherapy. The periorbital puffiness, chemosis and conjunctival congestion were much reduced. The size of the submandibular and parotid glands also decreased significantly. Up to September 1993, 8 months after commencement

of chemotherapy, the beneficial effects were maintained.

### Discussion

In 1912, Hashimoto first described an inflammatory thyroid disease with diffuse infiltration of lymphoid cells into the thyroid gland which commonly affected middle aged and elderly women as in our patient. Hashimoto's thyroiditis, infiltrative ophthalmopathy and Graves' disease can occur alone or in association with one or both of the other conditions. These disorders are considered as inter-related organ-specific autoimmune diseases with disturbances of immunological surveillance. Infiltrative ophthalmopathy is commonly found in Graves' disease but is unusual in classical Hashimoto's thyroiditis.

In infiltrative ophthalmopathy, there is acute inflammation with infiltration of extraocular muscles by lymphocytes. This causes extraocular muscle enlargement, periorbital tissue swelling, exophthalmos and chemosis.

Our patient had a firm diffuse goitre, positive thyroid anti-microsomal antibody and biopsy-proven Hashimoto's thyroiditis. Clinically the ocular problem suggested infiltrative ophthalmopathy and this was supported by the CT scan findings.

Hashimoto's thyroiditis is a risk factor for thyroid lymphoma as suggested by various reports and epidemiological studies.<sup>1</sup> Up to 23% of thyroid lymphoma occurs in patients previously diagnosed as having Hashimoto's thyroiditis.<sup>2</sup>

Patients with chronic lymphocytic thyroiditis are also at higher risk of other myeloproliferative and lymphoproliferative neoplasms with a relative risk of 4.0. The relative risk of non-Hodgkin's lymphoma in chronic lymphocytic thyroiditis has been reported to be 6.0.<sup>5</sup> Usually the lymphoma develops in the thyroid gland, other cases usually being abdominal lymphomas. Development of extranodal lymphomas in patients with Hashimoto's thyroiditis occurs mainly in organs with lymphoid tissue or in organs susceptible to lymphocytic infiltration.<sup>6</sup> Thus theoretically, periorbital tissue is another potential site for primary malignant lymphoma to develop in autoimmune thyroiditis besides the thyroid itself. The rarity of lymphoma occurring in periorbital tissue may be due to the relatively small number of patients, the

usually mild severity of infiltrative ophthalmopathy, or possibly underdiagnosis and failure to recognize this possible association.

Sjogren's syndrome is characterized by progressive destruction of the salivary and lacrimal glands that causes mucosal and conjunctival dryness.<sup>3</sup> Coexistence of Sjogren's syndrome and Hashimoto's thyroiditis is uncommon, although numerous case reports have been published.<sup>7,8</sup>

Patients with Sjogren's syndrome have predisposition to non-Hodgkin's B-cell lymphoma involving the salivary glands and cervical lymph nodes.<sup>4</sup> There also appears to be an increased risk of lymphoma in sites distant from the affected glands in Sjogren's syndrome.<sup>9</sup> In one study, eight of 120 patients (6.7%) with primary Sjogren's syndrome developed non-Hodgkin's lymphoma within a 7-year follow-up period.<sup>10</sup> None, however, developed orbital lymphoma. A proportion of patients with non-Hodgkin's lymphoma also develop Sjogren's syndrome at some stage of their illness. One study showed that 14 of 113 patients (12.4%) with untreated non-Hodgkin's lymphoma had Sjogren's syndrome at first presentation.<sup>11</sup>

Most autoimmune disorders are associated with specific human leucocyte antigens (HLA) alleles. The reason is unknown. Atrophic Hashimoto's thyroiditis is associated with HLA-DR3 and DR5 while goitrous Hashimoto's thyroiditis is probably associated with HLA-DR4.<sup>12</sup> Sjogren's syndrome, on the other hand, is associated with HLA-B8 and DR3.<sup>13</sup> Close linkage between certain HLA alleles may provide an explanation for the relationships seen between some autoimmune disorders.

Recent evidence shows that autoantibodies exist with high frequency in the normal B-cell repertoire. The autoreactive B-cell repertoire may undergo malignant transformation as a result of continuous challenge by autoantigens.<sup>14</sup> Organotropic autoimmune diseases such as Hashimoto's thyroiditis and Sjogren's syndrome provide a specific pool of autoantigens to which the autoreactive B-cell is continuously exposed. Malignant change of the B-cell may then follow and produce an association of lymphoma with certain autoimmune disorders.

In conclusion, our patient illustrates well the possibility of an association between Hashimoto's thyroiditis, Sjogren's syndrome and extranodal malignant lymphoma. Extraocular muscle lymphoma should be suspected in patients with Hashimoto's thyroiditis and infiltrative eye disease.

### References

1. Aozasa, K. Hashimoto's thyroiditis as a risk factor of thyroid lymphoma. *Acta Pathol Jpn* 1990, **40**: 459-468.
2. Scholefield, J.H., Quayle, A.R., Harris, S.C. *et al.* Primary lymphoma of the thyroid, the association with Hashimoto's thyroiditis. *Eur J Surg Oncol (Engl)* 1992, **18**: 89-92.
3. Moutsopoulos, H.M. & Manoussakis, M.N. Immunopathogenesis of Sjogren's syndrome: 'facts and fancy'. *Autoimmunity (Switzerland)* 1989, **5**: 17-24.
4. Fox, R.I. & Kang, H.I. Pathogenesis of Sjogren's syndrome. *Rheum Dis Clin North Am* 1992, **18**: 517-538.

5. Holm, L.E., Blomgren, H. & Lowhagen, T. Cancer risks in patients with chronic lymphocytic thyroiditis. *N Engl J Med* 1985, **312**: 601–604.
6. Hadzic, B., Budakor, P. & Stajnic, S. Evolution of chronic lymphocytic thyroiditis in primary malignant lymphoma in an extranodal location. *Med Pregl* 1989, **42**: 355–357.
7. Nogita, T., Aramoto, Y., Terajima, S. *et al.* The coexistence of psoriasis vulgaris, Sjogren's syndrome, and Hashimoto's thyroiditis. *J Dermatol (Japan)* 1992, **19**: 302–305.
8. Horita, M., Takahashi, N., Seike, M. *et al.* A case of primary biliary cirrhosis associated with Hashimoto's thyroiditis, scleroderma and Sjogren's syndrome. *Intern Med (Japan)* 1992, **31**: 418–421.
9. Talal, N. & Bunim, T.J. The development of malignant lymphoma in the course of Sjogren's syndrome. *Am J Med* 1964, **36**: 529–540.
10. Pavlidis, N.A., Drosos, A.A. & Papadimitriou, C. Lymphoma in Sjogren's syndrome. *Med Pediatr Oncol* 1992, **20**: 279–283.
11. Janin, A., Morel, P., Quiquandon, I. *et al.* Non-Hodgkin's lymphoma and Sjogren's syndrome. An immunopathological study of 113 patients. *Clin Exp Rheumatol (Italy)* 1992, **10**: 565–570.
12. Weissel, M., Hofer, R., Zasmata, H. *et al.* HLA-DR and Hashimoto's thyroiditis. *Tissue Antigens* 1980, **16**: 256–257.
13. Moutsopoulos, H.M., Chused, T.M., Mann, D.L. *et al.* Sjogren's syndrome (Sicca syndrome): current issues. *Ann Intern Med* 1980, **92**: 212–226.
14. Muller-Hermelink, H.K. & Greiner, A. Autoimmune diseases and malignant lymphoma. *Verh Dtsch Ges Pathol* 1992, **76**: 96–109.