

Short reports

Congestive cardiomyopathy and endobronchial granulomas as manifestations of Churg–Strauss syndrome

R Alvarez-Sala, C Prados, E Armada, A Del Arco, J Villamor

Summary

Churg–Strauss syndrome is a systemic vasculitis. Its most frequent complications are heart diseases and asthma. Usually, cardiologic manifestations are pericarditis, cardiac failure and myocardial infarction. Endobronchial granulomas identified by bronchoscopy are unusual. We present the case of a man with congestive cardiomyopathy and endobronchial granulomas macroscopically visible at bronchoscopy. After a review of medical literature, we found one case of congestive cardiomyopathy and no cases of endobronchial granulomas observed by bronchoscopy associated with Churg–Strauss syndrome.

Keywords: Churg–Strauss syndrome, congestive cardiomyopathy, endobronchial granulomas

Churg–Strauss vasculitis is a clinical syndrome characterised by systemic vasculitis associated with peripheral and extravascular eosinophilia which appears almost exclusively in asthmatic and allergic rhinitis patients.^{1–4} The most frequent complications of this pathological entity appear when lungs, heart, and peripheral nerves are involved.^{1,4,5} Granuloma formation in the airways is a common feature, but these are usually small.⁶ Very occasionally, they join to give rise to nodules identifiable on thorax radiology and bronchoscopy.⁶ Sometimes, cardiac disease may progress from an early eosinophilic necrotic phase to fibrosis, producing a picture resembling endomyocardial fibrosis.^{7,8} We present the case of a man diagnosed with Churg–Strauss syndrome with congestive cardiomyopathy and the presence of macroscopically visible granulomas on bronchoscopy which were confirmed by biopsy. These endobronchial granulomas are considered very unusual in Churg–Strauss syndrome.⁶

Case report

A 28-year-old man was sent to our Service from the Intensive Care Unit. He had been a heavy smoker (280 packets/year) until he was diagnosed as suffering from bronchial asthma and bilateral maxillary sinusitis a year earlier. He was treated with inhaled bronchodilators and corticoids. Fifteen days before admission, he presented a productive cough and occasional haemoptysis. He was also febrile and suffered fatigue, weakness, weight loss and generalised pleuritic pain. Later, he presented progressive dyspnea, wheezing, and paroxysmal nocturnal dyspnea. He was taken to the emergency room of our hospital where he suffered a cardio-respiratory arrest. He was admitted to the intensive care unit. On thoracic X-ray and computed tomography (CT), a peripheral patched alveolar pattern and cardiomegaly with pericardial effusion were observed. Fiber-optic bronchoscopy and bronchoalveolar lavage were performed. Macroscopic findings on bronchoscopy revealed whitish granulomas on the bronchi of the middle and lower right lobes. The histology of the granulomas showed epithelioid cells, lymphocytes, plasma cells, and some eosinophils. On bronchoalveolar lavage, 15% eosinophils was the most emphasised feature. Congestive cardiomyopathy, severe systolic failure of the left ventricle and pericardial effusion (6 mm) were seen on echocardiography (figure). On electrocardiogram, atrial fibrillation with controlled ventricular rate was noted. He was treated with furosemide, digoxin, antibiotics and a high dose of steroids.

La Paz Hospital,
Universidad
Autonoma, Madrid,
Spain
Department of
Pneumology
R Alvarez-Sala
C Prados
J Villamor
Department of
Cardiology
E Armada
Department of
Internal Medicine
A Del Arco

Correspondence to
Dr Rodolfo Alvarez-Sala,
c/ Alcalá 119, 28009 Madrid,
Spain

Accepted 16 November 1994

Cardiac involvement in Churg–Strauss syndrome

- acute and constrictive pericarditis
- cardiac failure
- myocardial infarction

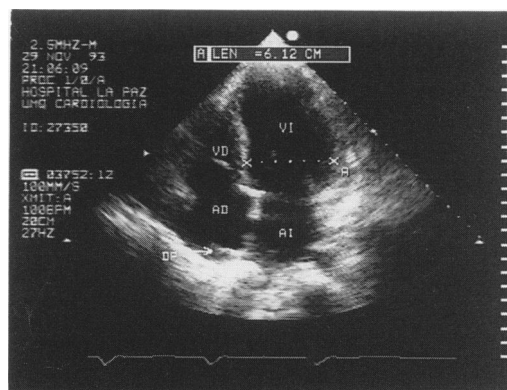


Figure Echocardiogram: dilated myocardial pathology

Twelve hours later he improved and was passed to our unit. On physical examination, wheezing was heard. Three days later he presented a lacerating pain in the left leg. Neurological exploration showed a decrease in sensitivity of the medial side of this leg. An electromyogram was performed and sensitive and motor alterations in the zones of sural and tibial nerves were observed. A skin-muscle-nerve biopsy in this zone was performed and revealed fibrinoid necrosis, vasculitis, and extravascular granulomas formed by lymphocytes, eosinophils, plasma and epithelioid cells. Serological studies for different bacteria and viruses, including hepatitis A, B, and C, were negative. Otolaryngeal studies were normal. Renal function was normal. Antinuclear, antineutrophil cytoplasmic and antibasal membrane antibodies, rheumatic factor and immunoglobulins were normal, except for an increased IgE. The patient was diagnosed as having Churg-Strauss syndrome.

Discussion

Endobronchial granuloma visible on fiberoptic bronchoscopy in Churg-Strauss vasculitis is exceptional.⁶ The most frequent finding is the presence of vasculitis, necrotising capillaritis, alveolar infiltration by eosinophils and granulomatous process involving the interstitium.^{1,4,5} Our patient showed endobronchial lesions which, when biopsied, revealed eosinophilic granulomas and necrotising vasculitis.

Cardiac disorders have been considered the primary cause of death in Churg-Strauss syndrome.^{1,3,5,8} Eosinophilic myocardial infiltration is not as usual in this vasculitis as in other diseases with peripheral eosinophilia, such as hypereosinophilia syndromes.⁷⁻⁹ If it occurs,

Learning points

- dilated cardiomyopathy may occur in patients with Churg-Strauss syndrome
- endobronchial granulomas may be visible on bronchoscopy

endomyocardial fibrosis may progress to constrictive cardiomyopathy.^{7,8} Our patient presented signs of cardiac failure, a typical complication of Churg-Strauss vasculitis.^{1,5,8} On echocardiography (figure), congestive cardiomyopathy was observed. This finding has been reported once before in the literature.⁸

The aetiology of this complication does not seem to be explainable by the previous mechanisms suggested for endomyocardial fibrosis due to the role of eosinophils.^{1,5,8} The results of Pérez Blanco *et al*⁸ are probably due to granuloma formation in the ventricular wall and tendinous chordae visible with echocardiography. Unlike that report, the congestive myocardiopathy of our patient, persists in the echocardiogram, in spite of treatment with steroids and cyclophosphamide. We think that the myocarditis in our patient may represent an inflammatory process, as seen in other muscles (eg, legs, arms, etc) in the Churg-Strauss syndrome. This would then explain our patient's myocardiopathy. Nevertheless, eosinophils may also play a role in the pathogenesis of this condition.

We consider that the presence of endobronchial granulomas visible to fiber-optic bronchoscopy and congestive cardiomyopathy should be considered as possible complications of Churg-Strauss syndrome.

- 1 Chumbley LC, Harrison EG, DeRemee RA. Allergic granulomatosis and angiitis (Churg-Strauss syndrome). Report and analysis of 30 cases. *Mayo Clin Proc* 1977; 52: 477-84.
- 2 Masi AT, Hunder GG, Lie JT, *et al*. The American College of Rheumatology 1990 criteria for the classification of Churg-Strauss syndrome (allergic granulomatosis and angiitis). *Arthritis Rheum* 1990; 33: 1094-100.
- 3 Churg J, Strauss L. Allergic granulomatosis, allergic angiitis, and periarteritis nodosa. *Am J Pathol* 1951; 27: 277-301.
- 4 Hueto Pérez de Heredia JJ, Domínguez del Valle FJ, García E, Gómez ML, Gallego F. Chronic eosinophilic pneumonia as a presenting feature of Churg-Strauss syndrome. *Eur J Respir* 1994; 7: 1006-8.
- 5 Lanham JG, Elkon KB, Pusey CD, Hughes GR. Systemic vasculitis with asthma and eosinophilia: a clinical approach to the Churg-Strauss syndrome. *Medicine (Baltimore)* 1984; 63: 65-81.
- 6 Clutterbuck EJ, Pusey CD. Severe alveolar hemorrhage in Churg-Strauss syndrome. *Eur J Respir Dis* 1987; 71: 158-63.
- 7 Lanham JG, Cooke S, Davies J, Hughes GRV. Endomyocardial complications of the Churg-Strauss syndrome. *Postgrad Med J* 1985; 61: 341-4.
- 8 Pérez-Blanco FJ, Cano Pérez M, Moreno Torribas G, Manzanares Olivares L. Miocardiopatía congestiva en el síndrome de Churg-Strauss. *An Med Intern* 1993; 10: 466-7.
- 9 Davidson AG, Thompson PJ, Davies J, Corrin B, Turner-Warwick M. Prominent pericardial and myocardial lesions in the Churg-Strauss syndrome (allergic granulomatosis and angiitis). *Thorax* 1983; 38: 793-5.