

Eponyms in medicine revisited

Klippel–Trenaunay syndrome

OMP Jolobe

Summary

The Klippel–Trenaunay syndrome, typically characterised by the triad of cutaneous haemangioma, venous varicosities, and limb hypertrophy, may also have a formes frustes presentation, with absence of the cutaneous naevus. A case is reported in a 75-year-old woman with a presumptive diagnosis of renovascular hypertension.

Keywords: Klippel–Trenaunay syndrome

Klippel–Trenaunay syndrome: diagnostic criteria

- cutaneous haemangioma, varicose veins, and limb hypertrophy
- cutaneous haemangioma absent in 4%–68% of cases
- lower limbs preferentially affected

Box 1

Klippel–Trenaunay syndrome: complications

Local

- pain
- cellulitis
- ulceration
- thrombophlebitis
- gangrene

Involvement of internal organs

- neurovascular anomalies
- pulmonary vein varicosities
- pleuro-pericardial effusions
- pulmonary embolism
- colorectal and urinary tract haemorrhage

Systemic

- consumptive coagulopathy
- high-output cardiac failure

Box 2

Tameside General Hospital, Fountain Street, Ashton-under-Lyne, Lancashire OL6 9RW, UK
OMP Jolobe

Originally described in 1900, the Klippel–Trenaunay triad is a congenital angiomatous disorder (box 1).^{1–3} Formes frustes may, however, occur, with absence of cutaneous naevus in 4% to 68% of cases.^{3,4} The eponymous transformation to the Klippel–Trenaunay–Weber syndrome is reserved for patients with co-existing arterio-venous fistulae in the hypertrophic limb.⁵ Occasionally, there may be similarities and an overlap with the Proteus syndrome, the latter being characterised by limb hypertrophy, and sometimes also by epidermal naevi.⁶

Aetiology

The presumed pathogenetic pathway is that of mesodermal developmental derangement, leading to the maintenance of microscopic arteriovenous communications in the limb bud, with consequent development of the triad of naevus, superficial varices, and limb hypertrophy.⁷ A genetic basis is suggested by the occurrence of two other cases in the families of two of the 86 Klippel–Trenaunay syndrome patients participating in an extensive search for a genetic pattern in this syndrome.⁸

Age range and prevalence

The resurgence of interest in this syndrome, exemplified by its categorisation, since 1991, as a separate entity in Index Medicus, has led to its recognition even *in utero*, thanks to the documentation, by antenatal ultrasonography, of stigmata such as asymmetric limb growth,⁹ 19 weeks gestation being the earliest documented diagnosis.⁹ The rarity of this condition is reflected by the existence of only 94 subjects in the Dutch Klippel–Trenaunay syndrome register.⁸ The oldest patient in the series reported by Aelvoet *et al* was 73 years old⁸; the case reported here extends the age range to 75.

Complications

Local and systemic complications are summarised in box 2.¹⁰ Coexisting ipsilateral angiomatosis may be exemplified by neurovascular anomalies such as cerebral arteriovenous fistulae,¹¹ and spinal cord arteriovenous malformations,¹² with corresponding symptomatology. Intrathoracic manifestations include pulmonary vein varicosities,¹³ lymphangiectatic sclerosis giving rise to pleural and pericardial effusions,¹⁴ and an increased liability to pulmonary embolism.⁴ Abdominal viscera affected by ipsilateral angiomatosis include the colon,¹⁵ and the urinary tract,¹⁶ with consequent rectal bleeding and haematuria, respectively, and, as in the case presented here, the possibility of renovascular hypertension (box 3).¹⁰

Case report

A 75-year-old woman presented with a blood pressure of 245/130 mmHg; at age 59 her blood pressure had been recorded as 170/110 mmHg. She bore Klippel–Trenaunay syndrome stigmata on her left upper limb without cutaneous naevus (figure 1). Varicosities were also noted on the trunk. An isotope renogram (figure 2) showed ipsilateral renal atrophy and ipsilateral superficial 'blush', suggesting superficial shunting of blood supply away from the affected kidney

Box 3

Klippel-Trenaunay syndrome: treatment

Local

- conservative measures may suffice
- surgery indicated for cosmetic reasons, for complications of venous insufficiency, and for bone overgrowth with non-healing ulcers

Complications involving internal organs

- surgery usually indicated

Systemic complications

- surgery indicated for consumptive coagulopathy and for high-output cardiac failure

Box 4

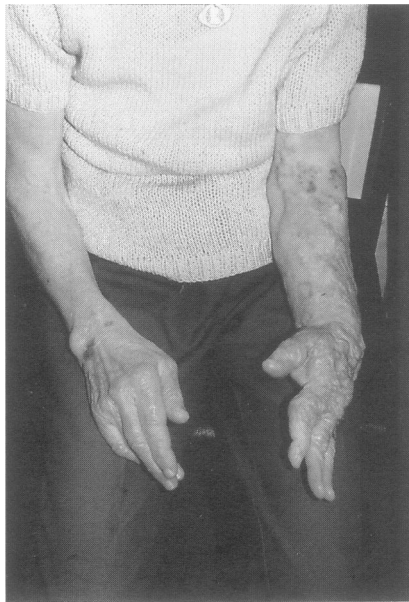

Figure 1 Hypertrophied left arm showing superficial varicosities

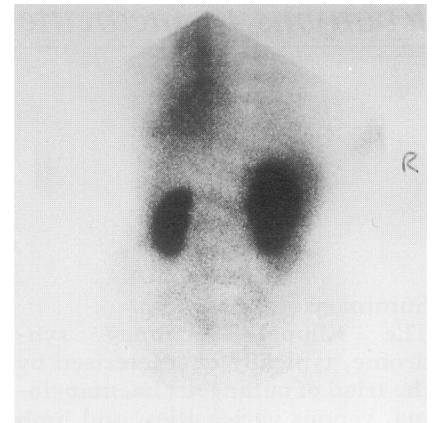


Figure 2 Isotope renogram showing atrophy of the left kidney and ipsilateral superficial 'blush'

Treatment

Most patients do well without treatment, or with elastic compression only.¹⁷ Patients with severe chronic venous insufficiency, disturbing cosmetic appearance, and complications of haemangioma, may benefit from surgical treatment, including epiphyseal stapling, stripping or resection of superficial varicose veins, or resection of a large lateral vein. Amputation may be required for bone overgrowth with non-healing decubitus ulcers, or for recurrent bleeding from haemangiomas. Detailed pre-operative imaging significantly improves the outcome of surgery, and the risk/benefit profile of each patient needs careful evaluation,¹⁷ as in those presenting with visceral complications.

Conclusion

Klippel-Trenaunay syndrome should not be regarded as just another case of varicose veins.¹⁸

I am indebted to Mr R Biggs, medical photographer, Tameside General Hospital, for the photographs of the patient, and to the X-ray department (Nuclear Medicine) for the isotope renogram.

1 Klippel M, Trenaunay P. Du naevus variqueux osteo-hypertrophique. *Arch Gen Med (Paris)* 1900; 185: 641-72.
 2 Kramer W. Klippel-Trenaunay syndrome. In: Vinken PJ, Bruyn AW, eds. *Handbook of Clinical Neurology* 1972; Vol 14: pp 390-404.
 3 Serville M. Klippel and Trenaunay's syndrome: 768 operated cases. *Ann Surg* 1985; 201: 365-73.
 4 Baskerville PA, Ackroyd JS, Lea Thomas M, Browse NL. The Klippel-Trenaunay syndrome: clinical, radiological, and haemodynamic features and management. *Br J Surg* 1985; 72: 232-6.
 5 Parkes-Weber F. Angioma formation in connection with hypertrophy of limbs and hemihypertrophy. *Br J Dermatol* 1907; 19: 231-5.
 6 Sanson JE, Jardine P, Lunt PW, Schutt WH, Kennedy CTC. A case illustrating Proteus and Klippel-Trenaunay syndrome overlap. *J R Soc Med* 1993; 202: 624-7.

7 Baskerville PA, Ackroyd JS, Browse NL. The etiology of Klippel-Trenaunay syndrome. *Ann Surg* 1985; 202: 624-7.
 8 Aelvoet GE, Jorens PG, Roelen LM. Genetic aspects of the Klippel-Trenaunay syndrome. *Br J Dermatol* 1992; 126: 602-3.
 9 Jorgenson RJ, Darby B, Patterson R, Trimmer KJ. Prenatal diagnosis of the Klippel-Trenaunay-Weber syndrome. *Prenatal Diagn* 1994; 14: 989-92.
 10 Samuel M, Spitz L. Klippel-Trenaunay syndrome: clinical features, complications, and management in children. *Br J Surg* 1995; 82: 757-62.
 11 Oyesiku NM, Gahn NH, Goldman RL. Cerebral arteriovenous fistula in the Klippel-Trenaunay-Weber syndrome. *Dev Med Child Neurol* 1988; 30: 245-51.
 12 Djidjian M, Djidjian R, Hurth M, Rey A, Houdart R. Spinal cord arteriovenous malformations and the Klippel-Trenaunay-Weber syndrome. *Surg Neurol* 1977; 8: 229-37.

13 Owens DW, Garcia E, Pierce RR, Castro FF. Klippel-Trenaunay syndrome with pulmonary vein varicosity. *Arch Dermatol* 1973; 108: 111-3.
 14 Joshi M, Cole S, Knibbs D, Diana D. Pulmonary abnormalities in Klippel-Trenaunay syndrome: a histologic, ultrasound, and immunocytochemical study. *Chest* 1992; 102: 1274-7.
 15 Ghahremani GG, Kangaroo H, Volberg F, Meyers MA. Diffuse cavernous haemangioma of the colon in Klippel-Trenaunay syndrome. *Pediatr Radiol* 1976; 118: 673-8.
 16 Fligelstone LJ, Campbell F, Ray DK, Rees RWM. The Klippel-Trenaunay syndrome: a rare cause of hematuria requiring nephrectomy. *J Urol* 1994; 151: 404-5.
 17 Gloviczki P, Stanson AW, Stickler GB et al. Klippel-Trenaunay syndrome: the risks and benefits of vascular interventions. *Surgery* 1991; 110: 469-79.
 18 Travis RC, Rowan DM, Miller J. Case of the month: just another case of varicose veins? *Br J Radiol* 1990; 63: 581-2.