

Short reports

Deep cerebral venous thrombosis presenting as an encephalitic illness

PA Silburn, PA Sandstrom, C Staples, P Mowat, RS Boyle

Summary

Three cases of deep cerebral vein thrombosis presenting as encephalitic illnesses are described. Thyrotoxicosis was present in one case, ulcerative colitis in one case and an anticardiolipin antibody was detected in two cases. All three patients were on oestrogen and progesterone. Magnetic resonance imaging and angiography allowed rapid confirmation of the diagnosis and permitted non-invasive follow up of this condition. The first two patients made complete clinical recoveries despite having thalamic infarction, in one case bilaterally, demonstrable radiologically.

Keywords: deep cerebral vein thrombosis, magnetic resonance angiography

Deep cerebral vein thrombosis is uncommon. The clinical presentation may be confusing and not suggestive of a vascular event. Until recently, invasive neurological procedures were required to establish the diagnosis. The use of magnetic resonance imaging (MRI) and magnetic resonance angiography (MRA) has led to accurate, rapid and non-invasive diagnosis of this condition. The clinical syndrome is thus being better defined.

Although a variety of conditions has been associated with cerebral vein thrombosis, its association with thyrotoxicosis has rarely been reported. We describe the clinical and radiological features of three patients with deep cerebral vein thrombosis and lateral sinus thrombosis. In one case, severe thyrotoxicosis was present. In another case the patient was suffering an exacerbation of ulcerative colitis at the time of presentation. In two cases an anticardiolipin antibody was detected. All three patients were on oestrogen and progesterone therapy.

Case reports

Case 1

A previously well 18-year-old woman on the low-dose oral contraceptive pill presented with a 10-day history of fever, intermittent vomiting, increasing headache and confusion. On presentation, her temperature was 38°C and she had a fluctuating Glasgow Coma Scale score of 10 to 12/15. She had a mixed dysphasia, left-sided visual neglect and a left hemiparesis. She had a resting tachycardia of 110.

A computed tomography (CT) scan on day 7 of her illness demonstrated a haemorrhagic lesion in the left temporoparietal area and an ill-defined area of low attenuation in the right basal ganglia and thalamus. A lumbar puncture revealed: polymorphonuclear cells 6×10^6 g/l, erythrocytes 1.1×10^6 g/l, protein 2700 mg/l (reference range 150–450 mg/l) and glucose 3.2 mmol/l (2.1–3.7 mmol/l). Cultures for bacteria, fungi and viruses were negative. An MRI scan on day 9 showed, on T2-weighted images, a wedge-shaped area of increased signal intensity involving the cortical surface of the left temporal lobe and adjacent white matter extending medially but sparing the thalamus (figure 1). A similar area of increased T2 signal was seen in the right basal ganglia and thalamus, sparing the external capsule. The left lateral sinus showed increased signal intensity on T1-weighted images. The signal void normally seen in sagittal views of the straight sinus was not present.

MRA scanning adjusted to show venous flow showed no signal in the deep cerebral veins, inferior sagittal sinus or straight sinus (figure 2). The antero-posterior view showed minimal flow in the left lateral sinus.

The patient was found to be thyrotoxic with a free thyroxine of 130 pmol/l (9–23 pmol/l), free triiodothyronine of 16 pmol/l (3.4–7.2 pmol/l) and undetectable thyroid-stimulating hormone <0.05 mU/l (0.3–5.5 mU/l). Positive thyroid receptor antibodies at 23 units (normal <15) were detected and generalised increased uptake on technetium thyroid scanning was consistent with Grave's disease. Normal investigations included electrolyte and renal profile, liver function tests, haemoglobin and full blood count, coagulation profile, lupus anticoagulant, anticardiolipin antibody, protein C, protein S, antithrombin III, sucrose lysis test, autoantibody screen, antinuclear antibody (ANA) screen, and HIV serology.

The patient was anticoagulated. Three months after presentation, she was neurologically intact. Follow-up MRI showed small areas of infarction and old haemorrhage in the right thalamus and left temporoparietal region. A repeat MRA examination revealed recanalization in all the venous systems originally involved.

Case 2

A 50-year-old woman presented with a five-day history of increasing headache, vomiting, confusion and obtundation six weeks after com-

Department of
Neurosciences,
Princess Alexandra
Hospital, Brisbane,
Queensland, Australia
PA Silburn
PA Sandstrom
C Staples
RS Boyle

Department of
Radiology, Royal
Brisbane Hospital,
Brisbane, Queensland,
Australia
P Mowat

Correspondence to
Dr RS Boyle, Director of
Neurology, Department of
Neurosciences, Princess
Alexandra Hospital, Ipswich
Road, Woolloongabba,
Brisbane, Queensland,
Australia

Accepted 15 September 1995

mencing a low-dose oral contraceptive pill for post-menopausal hormone replacement. There were no localising physical findings. She had a past history of leg deep venous thrombosis and pulmonary thrombo-embolism, occurring 15 years previously when she was taking a higher dose of contraceptive agent.

A CT scan performed five days into the illness was normal. A lumbar puncture demonstrated an opening pressure of 21 cm with polymorphs 7×10^6 g/l, red blood cells 286×10^6 g/l, protein content 2300 mg/l and glucose 3.5 mmol/l. Cultures for bacteria, viruses and fungi were negative.

An MRI scan on day 7 revealed symmetrical basal ganglia and thalamic low attenuation changes on T1-weighted images with increased signal on T2-weighted images. MRA scanning revealed an absence of flow symmetrically in the deep cerebral veins, inferior sagittal sinus, straight sinus and left lateral sinus. An elevated anticardiolipin antibody titre was detected at 28 units (normal <23). Normal investigations included all those referred to in Case 1. The patient was anticoagulated. Three weeks after the onset of the illness, the patient was well apart from the presence of a severe amnesic defect. Three months following presentation, the patient's memory had returned to normal.

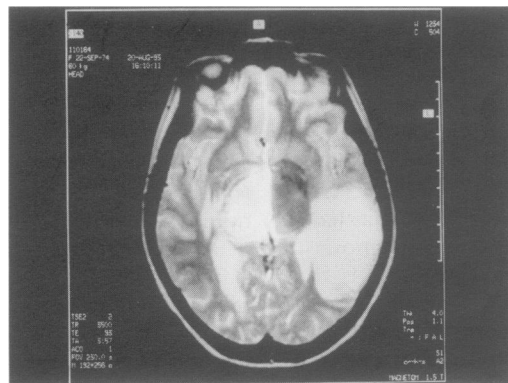

Figure 1 T2-weighted axial image from Case 1 showing areas of increased T2 signal on the cortical surface of the left posterior temporal lobe and the right thalamus

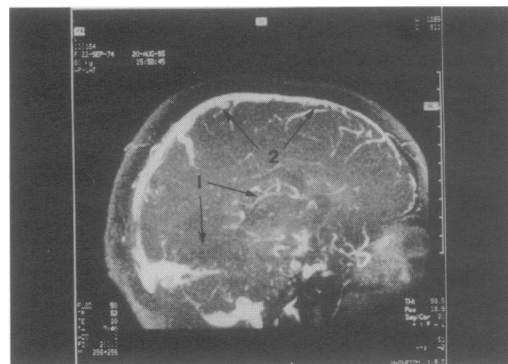


Figure 2 Corresponding MRA scan showing a lack of signal in the deep venous system (1) with normal signal in the superior sagittal sinus (2). Anterior and posterior views demonstrated a lack of signal in the left lateral sinus

An MRI scan at this time showed small areas of infarction in both thalami and in the left corona radiata. An MRA scan revealed return of flow symmetrically in the deep cerebral veins, inferior sagittal and straight sinuses with persistent lack of flow in the left lateral sinus.

Case 3

A 26-year-old woman on progesterone and oestrogen for control of endometriosis presented with a three-day history of increasing headache, confusion, dysphasia and obtundation, culminating in a generalised tonic/clonic seizure. At the time she was suffering an exacerbation of her ulcerative colitis.

On examination she had a Glasgow Coma Scale score of 10/15, was aphasic, had right-sided neglect and bilateral extensor plantar responses. A CT scan three days into her illness was normal. A lumbar puncture demonstrated a mononuclear cell count of 2×10^6 g/l cells, red blood cell count 600×10^6 g/l, protein 400 mg/l and glucose 4 mmol/l. Cultures for bacteria, fungi and viruses were negative.

An MRI scan on day 4 revealed bilaterally symmetrical increased signal changes on T2-weighted images in the basal ganglia and asymmetrical thalamic changes, more prominent on the left, with minor involvement in the medial right thalamus. MRA scanning on day 5 revealed an absence of flow symmetrically in the deep cerebral veins, inferior sagittal sinus, straight sinus and both lateral sinuses. In addition, mild hydrocephalus was present.

An elevated anticardiolipin antibody was detected at 32 units. Normal investigations included all of those referred to in Cases 1 and 2. The patient was anticoagulated.

On day 5 she deteriorated with clinical and radiological evidence of transtentorial herniation and required assisted ventilation. By day 7 a marked improvement in her clinical status had occurred. On day 20, she was noted to have mild right-sided weakness and moderate amnesia with confabulation as the only neurological deficits. A mild amnesic deficit was the only abnormality detected six months after initial presentation. Follow-up scanning has not been performed.

Discussion

Because the presentation of thrombosis of the deep cerebral venous system is variable and often not suggestive of a vascular event, the diagnosis may not be immediately recognised. All three of these cases presented with the relatively slow development of headache, confusion, obtundation and vomiting with, in one case, the subsequent development of focal neurological signs. The initial diagnosis in all three cases was viral encephalitis. This encephalitic presentation has become part of the recognised clinical spectrum of deep cerebral vein thrombosis.¹ This is in contrast with the more acute and devastating presentation previously thought to be more typical of this condition.

The temporoparietal haemorrhagic infarction observed in the first case occurred

probably as a result of spread of thrombus from the left lateral sinus into the vein of Labbé. The unilateral distribution of deep grey matter changes must have reflected the presence of collateral venous drainage from the deep grey matter to more superficial venous systems. Cases 2 and 3 demonstrated the more typical deep bilateral grey matter changes associated with deep cerebral vein thrombosis. These changes are best seen on MRI scanning, CT scanning being often quite insensitive in detecting these changes.

In all cases, MRA adjusted to highlight venous flow demonstrated clearly the pathological circulatory disturbances.

In cases 1 and 2 no residual neurological deficit was observed three months after the onset of symptoms. In case 3, recovery was slower but by six months after the onset of symptoms only a very mild amnesic deficit was detectable. This is in line with recent reports indicating there may be a more benign outcome for patients with deep cerebral vein thrombosis than previously thought.¹ MRA scanning showed partial recanalization of the venous system in case 1 and near complete recanalization in case 2. The corresponding MRI scans also showed considerable resolution of the changes seen on the initial films. Follow up MR studies in case 3 are not available.

The syndrome of simultaneous bilateral thalamic infarction has been attributed to occlusion of perforating arteries arising from a common stem, although arteriographic evidence has been lacking. Our case 2 indicates that deep cerebral vein thrombosis should be included in the differential diagnosis as a cause for this syndrome.

The association of cerebral vein thrombosis with thyrotoxicosis was first reported in 1913 by Kaliebe, with a further report by Doyle in 1927.² Cerebral vein thrombosis has also been described during an episode of thyrotoxicosis in a patient with congenital plasminogen deficiency.³ A case in which bilateral deep grey matter hypodensities seen on CT scan, similar to the changes in case 2, occurring in the clinical setting of progressive confusion, obtundation and subsequent quadriplegia, probably represents a further case of deep cerebral vein thrombosis related to thyrotoxicosis.⁴ Siegert *et al*⁵ recently reported two further cases of cerebral vein thrombosis occurring in association with thyrotoxicosis. Thus, it seems that thyrotoxicosis may predispose to cerebral

Deep cerebral vein thrombosis: clinical features

- the deep cerebral venous system is consistently present and well visualised angiographically
- occlusion produces a spectrum of clinical presentations from acute coma with decerebrate posturing to a subacutely evolving confusional state with no localising physical signs
- outcome is variable and may include death, akinetic mutism, extrapyramidal syndromes, dementia or no residual deficit

Learning points

- deep cerebral vein thrombosis may present with a subacute encephalitic picture with or without focal physical abnormalities
- MRI is far more sensitive than CT in detecting the radiological changes of deep cerebral vein thrombosis
- MRA non-invasively defines the vascular occlusion
- recanalization of the thrombosed venous system often occurs
- the outcome of deep cerebral vein thrombosis may be very good
- thyrotoxicosis may be a risk factor for cerebral vein thrombosis
- deep cerebral vein thrombosis is a cause of bilateral simultaneous thalamic infarction

venous thrombosis, although the mechanism for this is unclear.

Cases 2 and 3 both had persisting elevated titres of anticardiolipin antibodies, a known risk factor for venous and arterial thrombosis. Ulcerative colitis, present in case 3, is also a recognised risk factor for cerebral vein thrombosis. All three cases were being treated with combined oestrogen and progesterone therapy at the time of their thromboses, this again being a known risk factor for venous and arterial thrombosis.

These three cases demonstrate that the presentation of deep cerebral vein thrombosis may not be suggestive of a vascular event and the outcome may be better than previously thought. Case 3 supports the hypothesis that the association of thyrotoxicosis and cerebral vein thrombosis may be more than one of chance.

1 Bousser MG, Barnett HJM. Cerebral venous thrombosis. In: Mohr JP, Stein B, Yatsu IM, eds. *Stroke. Pathophysiology, diagnosis and management*. Churchill Livingstone, 1992; pp 517–37.

2 Doyle JB. Obstruction of the longitudinal sinus. *Arch Neurol Psychiatry* 1927; **29**: 374–82.

3 Schutta HS, Williams EL, Baranski BG, Sitia TP. Cerebral venous thrombosis with plasminogen deficiency. *Stroke* 1991; **22**: 401–5.

4 Page SR, Scott AR. Thyroid storm in a young woman resulting in bilateral basal ganglia infarction. *Postgrad Med J* 1993; **69**: 813–5.

5 Siegert CEH, Smelt AHM, de Bruin TWA. Superior sagittal sinus thrombosis and thyrotoxicosis. *Stroke* 1995; **26**: 496–7.