

# Papillary thyroid carcinoma associated with ulcerative colitis

N Evgenikos, JG Stephen

## Summary

**A case is reported of papillary thyroid adenocarcinoma with cervical lymph node metastases in a young man who had presented earlier with severe total ulcerative colitis. The aetiological factors in the pathogenesis of papillary thyroid carcinoma are briefly reviewed and an association between this neoplasm and ulcerative colitis is suggested**

**Keywords:** papillary thyroid carcinoma, ulcerative colitis

The presentation of papillary thyroid adenocarcinoma in a young man three months after proctocolectomy for ulcerative colitis with pericholangitis prompted a consideration of possible aetiological factors which might link the two diseases. The literature contains an account of another patient with primary sclerosing cholangitis and ulcerative colitis who developed papillary carcinoma of the thyroid.<sup>1</sup>

## Case report

A 27-year-old man with a three-year history of intractable ulcerative colitis was referred for surgery. He had been treated with mesalazine as well as intermittent courses of prednisolone since the onset of his symptoms and had undergone continuous therapy with azathioprine for the previous two years. He complained of mild abdominal discomfort and profuse bloody diarrhoea despite therapy with prednisolone 20 mg daily, azathioprine 150 mg daily and mesalazine 800 mg tid. On examination, he was thin and anaemic. The abdomen was normal but rectal examination showed irregular, oedematous and haemorrhagic mucosa. Sigmoidoscopy and biopsies showed the typical features of ulcerative colitis.

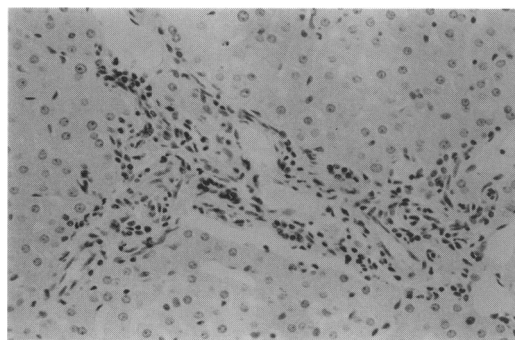
Results of investigations included: haemoglobin 9.1 g/dl, white cell count  $9.2 \times 10^9/l$ , platelets  $348 \times 10^9/l$ . Liver function tests were normal apart from an alkaline phosphatase of 80 IU/l (normal range, 25–70 IU/l). A barium enema showed extensive superficial ulceration in the rectum, sigmoid and descending colon. However, the colon proximal to the splenic flexure appeared normal and small bowel enema showed no abnormality.

Proctocolectomy was performed with construction of a terminal ileostomy. At laparotomy the left colon and rectum appeared inflamed but the transverse and ascending

colon appeared normal on inspection. However, examination of the gross specimen and histology showed a total ulcerative colitis, the left colon being more severely involved than the right. There was ulceration with pseudopolypoid and crypt abscesses. The terminal ileum was normal. The liver appeared macroscopically normal but needle biopsies demonstrated minor focal pericholangitis and some periductal fibrosis, features consistent with those of liver disease in ulcerative colitis (figure 1).

He made a good recovery, his steroid therapy was gradually withdrawn and he returned to work. At review three months after surgery he was well generally but was noted to have a lymph node mass in the right side of the neck. Computed tomography and ultrasound scans showed a mass of enlarged lymph nodes extending from the suprasternal notch to the parotid gland and situated antero-lateral to the right internal jugular and carotid vessels and deep to the sternomastoid muscle. On thyroid isotope scan there was a defect in the upper pole of the right lateral lobe. Serum thyroxine and thyroid-stimulating hormone concentrations were normal. The serum thyroglobulin concentration was 158  $\mu g/l$  (adult basal reference range: 93% of normals less than 25  $\mu g/l$ ). A lymph node biopsy revealed metastatic papillary carcinoma of the thyroid (figure 2).

He was submitted to a near-total thyroidectomy and right radical neck dissection. There was a hard tumour (2 cm in diameter) in the upper pole of the right thyroid lobe and a mass of enlarged lymph nodes lateral and deep to the internal jugular vein. He made a satisfactory recovery and postoperative serum calcium concentrations were within normal limits. He was started on thyroxine therapy (150  $\mu g/day$ ). Laryngoscopy showed both vocal cords to be



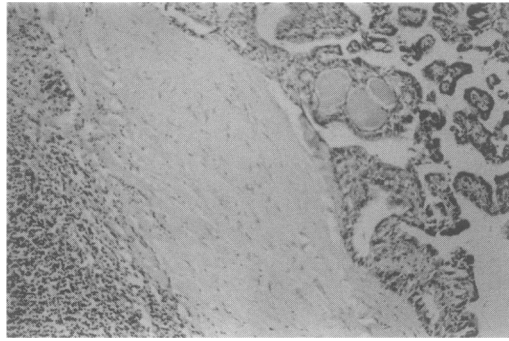
**Figure 1** Photomicrograph of liver biopsy revealing minor focal pericholangitis and mild periductal fibrosis

Department of  
Surgery, Bishop  
Auckland Hospitals  
NHS Trust, County  
Durham DL14 6AD,  
UK

N Evgenikos  
JG Stephen

Correspondence to  
Mr JG Stephen

Accepted 12 January 1996



**Figure 2** Photomicrograph showing lymph node with metastatic papillary carcinoma of the thyroid

mobile. He received an ablation dose of radioactive iodine. An isotope scan three months later showed significant uptake in the neck indicating metastatic disease. Therefore he had further therapy with radioactive iodine. One year after thyroid surgery he remains well and is euthyroid while treated with thyroxine 200  $\mu\text{g}$  daily. The chest radiograph is normal, his serum thyroid-stimulating hormone concentration remains suppressed and his serum thyroglobulin concentration (2.4  $\mu\text{g}/\text{l}$ ) is satisfactory.

### Discussion

The main factors which have been considered in the pathogenesis of carcinoma of the thyroid follicular epithelium are ionizing radiation, prolonged thyroid-stimulating hormone stimulation and genetic mechanisms. Of these, only radiation exposure has been shown unequivocally to cause thyroid cancer.<sup>2,3</sup> There was no history of irradiation in our patient and no evidence of pre-existing thyroid disease or raised serum thyroid-stimulating hormone concentration.

Familial occurrence of papillary thyroid carcinoma has been reported.<sup>4,5</sup> Familial polyposis of the colon and Cowden's disease (multiple hamartoma syndrome) are both hereditary conditions recognised to be associated with thyroid carcinoma.<sup>6,7</sup> However, this patient had no family history of any of these disorders. Furthermore, his HLA status (A1, Aw19, B8, B15) was different from those previously reported to be associated with thyroid carcinoma (DR1, DR3 and DR7).<sup>8</sup>

Our patient had undergone immunosuppression with prednisolone and azathioprine for two years. Since patients receiving chronic

### Aetiological factors for thyroid cancer

- ionizing radiation
- prolonged thyroid-stimulating hormone stimulation
- genetic mechanisms, eg, familial papillary thyroid carcinoma, familial polyposis of colon, Cowden's disease (multiple hamartoma syndrome), HLA status (DR1, DR3 & DR7)
- immunosuppression

immunosuppressive treatment have an increased frequency of many malignant tumours, the possibility that this therapy could have had a carcinogenic role requires consideration. However, a study of kidney graft recipients on prolonged immunosuppression showed that the most frequently occurring tumours were skin carcinomas, non-Hodgkin's lymphomas, Kaposi's sarcomas, carcinomas of the cervix, perineum and vulva and hepatobiliary carcinomas.<sup>9</sup> The mean interval between allograft transplantation and development of malignancy was 60 months. Penn *et al* reported a thyroid tumour in a renal transplantation patient after immunosuppressive drug therapy.<sup>10</sup> However, this was a malignant lymphoma which involved many organs, including the thyroid, rather than a papillary carcinoma.

A similar case of papillary thyroid carcinoma occurring in a patient with primary sclerosing cholangitis and ulcerative colitis has been described.<sup>1</sup> A young man presented with cholestatic liver disease and a lateral neck mass which proved to be a lymph node metastases from papillary carcinoma of the thyroid. Further investigation with liver biopsy and endoscopic retrograde cholangiopancreatography (ERCP) showed the features of primary sclerosing cholangitis and at colonoscopy ulcerative colitis was diagnosed. Our patient's liver showed histological changes associated with ulcerative colitis and it may be that this pericholangitis is related to the macroscopic strictures seen on ERCP in primary sclerosing cholangitis.

Thus, liver disease complicating ulcerative colitis may be a factor reflecting the severity of the disease or the disease subtype and associated with a genetic predisposition to thyroid carcinoma. It is possible that the occurrence of these two diseases in our patient was fortuitous but this is the second case to be reported and an association seems likely.

1 Ginsberg GG, Goodman ZD, Lewis JH. A 22-year old man with thyroid cancer and cholestatic liver disease. *Semin Liver Dis* 1991; 11: 64-71.

2 Shore RE, Woodward E, Hildreth N, Dvoretzky P, Hemplemann L, Pasternack B. Thyroid tumours following thymus irradiation. *J Natl Cancer Inst* 1985; 74: 1177-84.

3 Schneider AB. Carcinoma of follicular epithelium: pathogenesis. In: Braverman LE, Utiger RD, eds. *Werner and Ingbar's The thyroid: a fundamental and clinical text*, 6th edn. Philadelphia: JB Lippincott Company, 1991; pp 1121-9.

4 Lote K, Anderson K, Nordal E, Brennhovd IO. Familial occurrence of papillary thyroid carcinoma. *Cancer* 1980; 46: 1291-7.

5 Olah E, Balogh E, Bojan F, Juhasz F, Stenszky V, Farid NR. Cytogenetic analyses of three papillary carcinomas and a follicular adenoma of the thyroid. *Cancer Genet Cytogenet* 1990; 44: 119-29.

6 Delamarre J, Capron JP, Armand A, Dupas JL, Deschepper B, Davion T. Thyroid carcinoma in two sisters with familial polyposis of the colon: case reports and review of the literature. *J Clin Gastroenterol* 1988; 10: 659-62.

7 Thyresson HN, Doyle JA. Cowden's disease (multiple hamartoma syndrome). *Mayo Clin Proc* 1981; 56: 179-84.

8 Farid NR. Genetic factors in thyroid disease. In: Braverman LE, Utiger RD, eds. *Werner and Ingbar's The thyroid: a fundamental and clinical text*, 6th edn. Philadelphia: JB Lippincott Company, 1991; pp 588-602.

9 Boitard C, Bach JF. Long-term complications of conventional immunosuppressive treatment. *Adv Nephrol Necker Hosp* 1989; 18: 335-54.

10 Penn I, Hammond W, Brettschneider L, Starzl TE. Malignant lymphomas in transplantation patients. *Transplant Proc* 1969; 1: 106-12.