

Clinical guidelines

Summary

The presence of intracardiac thrombus has been associated with many diseases and clinical states, although cardiac impairment is commonly also present. Despite this, there continues to be a lack of consensus on which patients with cardiac impairment should have anticoagulant therapy. This review discusses the relationship between thromboembolism and cardiac impairment secondary to ischaemic heart disease, and suggests possible mechanisms, methods of diagnosis and therapeutic strategies for anticoagulation in such patients. In particular, warfarin has been established as thromboprophylaxis in certain subgroups of patients with cardiac impairment secondary to ischaemic heart disease. A large-scale randomised controlled trial in ambulant patients with cardiac impairment to evaluate the effectiveness of anticoagulant therapy and antiplatelet therapy is, however, long overdue.

Keywords: thrombus formation, cardiac impairment, anticoagulant therapy

Causes of thrombus formation in the left ventricle

Common

- acute myocardial infarction
- left ventricular aneurysm
- dilated/congestive cardiomyopathy

Uncommon

- blunt chest trauma
- systemic lupus erythematosus
- carcinoid heart disease
- postpartum heart disease
- Chagas' disease
- beri-beri
- amyloidosis
- infectious myocarditis
- endomyocardial fibrosis
- sarcoidosis
- endomyocardial biopsy
- diverticulum of the left ventricle
- Löffler's endocarditis

In many instances, especially in the common causes of intracardiac thrombus formation, significant cardiac impairment is also present

Box 1

University Department of Medicine and Department of Cardiology, City Hospital, Birmingham B18 7QH, UK
GYH Lip

Accepted 7 February 1996

Intracardiac thrombus formation in cardiac impairment: the role of anticoagulant therapy

Gregory YH Lip

As intracardiac thrombus is often associated with diseases involving the endocardium and/or myocardium of the left ventricle, the precise prevalence of left ventricular thrombus is difficult to ascertain. For example, the presence of intracardiac thrombus has been associated with many diseases and clinical states (box 1), although cardiac impairment is also commonly present and associated with stroke and thromboembolic risk.¹

The commonest cause of cardiac impairment in clinical practice remains ischaemic heart disease. However, there continues to be a lack of consensus on which patients with cardiac impairment should have anticoagulant therapy. This is due to the perceived lack of evidence, the uncertainty of diagnosis (especially of intracardiac thrombus) and the inconvenience and safety aspects of using warfarin. The diagnosis of intracardiac thrombus is further influenced by changes in imaging techniques and management strategies for different cardiac problems.

Mechanisms and factors contributing to thromboembolism

It has long been recognised that thromboembolism is a frequent cause of death in patients with congestive heart failure, occurring in up to 30% of patients.² Despite the high incidence in some series, anticoagulant therapy has not been widely used as an adjuvant to routine therapy in patients with cardiac impairment. This may be due to the fact that there has not been a controlled trial assessing the efficacy of anticoagulation in patients with heart failure secondary to cardiac impairment outside the hospital setting.

Most data on intracardiac thrombus formation and thromboembolism have been related to cardiac impairment in association with left ventricular aneurysms. For example, the frequency of left ventricular thrombi in aneurysms seen at *post mortem* can range between 14 to 68%, which is consistent with findings at aneurysmectomy (50–95%).¹ However, the reported incidences of systemic thromboembolism in patients with left ventricular aneurysm demonstrate a wide range, from 0 to 52%.^{1,3–5} Thus, although it is generally considered that patients with chronic aneurysms (longer than three months) are at low thromboembolic risk, a high proportion still have intracardiac thrombus formation. There is thus some debate on the likelihood of thromboembolism.¹

In patients with heart failure, post acute myocardial infarction and cardiomyopathy, most studies have depended upon echocardiographic detection of thrombus. In a recent review, the incidence of arterial thromboembolic events in patients with heart failure ranged from 0.9 to 42.4 events per 100 patient-years, equivalent to an annual incidence of thromboembolism or stroke in patients with heart failure of approximately 1.9%.⁶ However, the prevalence of atrial fibrillation in these studies was 12–36%, which may have accounted for some of the thromboembolic events.⁶

Thromboembolism and stroke are also common complications in cardiac dysfunction secondary to cardiomyopathy. For example, the incidence of thromboembolic stroke in hypertrophic cardiomyopathy has been reported to be 3% per patient year, which is increased by the presence of atrial fibrillation.^{7,8} Thrombus has also been found in approximately 36% of patients with chronic dilated cardiomyopathy on two-dimensional echocardiography.⁹ Systemic emboli occurred in 11% of these patients, but there was no difference in the incidence of emboli when compared to those with no thrombus visualised at echocardiography.⁹ Falk *et al*¹⁰ reported that thrombus was more common in patients with dilated cardiomyopathy with fractional shortening of 10% or less compared to those with fractional shortening of 11–25%.

What are the reasons for the discrepancy between the presence of intracardiac thrombi and the wide range of thromboembolic risk in different studies? This

Factors influencing the likelihood of thromboembolism of intracardiac thrombi in cardiac dysfunction

- mechanical factors, including structural abnormalities (eg, aneurysm formation)
- flow abnormalities in a dilated, poorly contracting ventricle
- the duration of thrombus formation – recently formed, poorly adherent thrombus is more likely to embolise
- the mobility and protrusion of intracardiac thrombus
- the presence of an acute infarction, and whether significant global cardiac impairment is present
- rhythm abnormalities, especially atrial fibrillation
- valve disease
- abnormalities of haemostasis, suggesting a 'hypercoagulable' state

Many factors are often present in combination, contributing to an increased thromboembolic risk

Box 2

may be due to the likelihood of thromboembolism of cardiac thrombi, which is dependent upon many different factors, as discussed below (box 2).

MECHANICAL AND FLOW ABNORMALITIES IN CARDIAC IMPAIRMENT

Low cardiac output, aberrant flow through dilated cardiac chambers and poor contractility may all predispose to intracardiac thrombus formation and subsequent thromboembolism. In a left ventricular aneurysm, for example, there is both diastolic and systolic bulging or asynergy, resulting in severe stasis of blood, with consequent predisposition towards thrombus formation. Poor systolic function may also cause stasis of blood within a dilated left ventricular cavity (with or without aneurysm formation).¹¹

There is also evidence that the embolic potential of left ventricular thrombus may be directly related to the presence of adjacent segments of normally functioning myocardium (with altered flow characteristics) and inversely related to the stability of the thrombus. For example, in an echocardiographic study of 40 patients with cardiomyopathy, there were specific abnormally low flow profiles at the ventricular apex associated with the presence of left ventricular thrombus.¹² Similar abnormal flow profiles have been demonstrated by pulsed Doppler echocardiography in patients post myocardial infarction who subsequently develop intracardiac thrombus.¹³ In this latter study, the abnormalities were evident in diastole, suggesting that the absence of diastolic recoil of the apex of the heart was additive to the impaired systolic contraction in creating disturbed flow patterns.

Interestingly, in the cardiomyopathy patients without intracardiac thrombus, there was a higher prevalence of mitral regurgitation despite abnormal Doppler flow profiles.¹² The presence of mitral regurgitation may therefore serve as a protective factor against thrombus formation as the higher inflow velocities may result in a lower tendency for thrombus formation. The findings of these two studies therefore suggest that flow abnormalities are important in promoting thrombogenesis in patients with cardiac impairment, and that Doppler echocardiography may be useful in patient risk stratification by the identification of a high risk group (with abnormal flow patterns), who would benefit from prophylactic anticoagulation.¹⁴

DURATION AND MORPHOLOGY OF INTRACARDIAC THROMBUS

It has been argued that the duration of intracardiac thrombus is important, as recently formed, poorly adherent thrombus is more likely to dislodge than older thrombus which is likely to be more firmly adhered by fibroblastic infiltration. Although an estimate of the time required for infiltration and endothelialisation of intracardiac thrombus is approximately 14 days, anticoagulation for this time period might prevent new clot formation and allow the most recently formed thrombi to become sufficiently adherent. However, this time period cannot be precisely defined and is very likely to vary according to the haemodynamic status, aneurysm size and underlying pathology, together with the effectiveness of anticoagulation.

The morphology of a thrombus can help to predict subsequent embolisation. For example, thrombus protrusion and mobility, especially those related to a recent myocardial infarction, are associated with an increased embolic risk.^{15,16} Ongoing 'active' thrombus formation is also an important factor, as 'active' thrombi are at high risk of embolisation. One use of indium-111 platelet scintigraphy, for example, may be to detect 'active' thrombi, as ongoing thrombogenesis may account for the positive platelet scintigraphy in these patients.¹⁷

ABNORMAL HAEMOSTASIS IN CARDIAC IMPAIRMENT

Abnormalities in haemorrhological function and prothrombotic markers intrinsic to left ventricular dysfunction may contribute to the thromboembolic risk in patients with cardiac impairment. Indeed, patients with left ventricular aneurysms have abnormalities in clotting factor levels.¹⁸ In a study of 112 patients with coronary artery disease in sinus rhythm,¹⁸ those with left ventricular aneurysms had significantly elevated plasma fibrinogen, fibrin D-dimer (a marker of fibrin turnover and thrombogenesis¹⁹) and von Willebrand factor levels (a marker of endothelial dysfunction²⁰). These abnormalities were primarily due to systolic or contractile dysfunction, with little contribution from diastolic dysfunction, and were normalised by warfarin.^{18,21} Another study by Jafri *et al*²² found that, regardless of the aetiology, patients with heart failure show significant abnormalities of platelet activation (as reflected by platelet factor 4 and beta-thromboglobulin), and markers of haemostasis such as thrombin-antithrombin 4 complex (TAT4), fibrinopeptide A and fibrin D-dimer. Abnormalities of haemostasis were also shown by Sbarouni *et al*,²³ who

reported increased blood and plasma viscosity, platelet activation, fibrinopeptide A, fibrin D-dimer and von Willebrand factor in patients with heart failure. Finally, Yamamoto *et al*²⁴ found abnormal haemostasis in a small study of patients with dilated cardiomyopathy and hypertrophic cardiomyopathy.

All these studies therefore suggest increased thrombogenesis or a hypercoagulable state in patients with cardiac impairment. However, the haemostatic abnormalities were poorly interrelated and poorly related to the severity of heart failure and cardiac chamber size.^{18,21,23} Mechanisms proposed for these haemostatic abnormalities include neuroendocrine activation²³ and flow disturbances, in view of the correlation between some haemostatic markers and Doppler indices.²¹

Atrial fibrillation is commonly associated with left ventricular dysfunction, and abnormalities in haemostasis suggestive of a prothrombotic state have also been demonstrated in patients with this arrhythmia.²⁵ Atrial fibrillation is also associated with elevated levels of atrial natriuretic peptide, which may contribute to haemoconcentration, a raised haematocrit and subsequent thromboembolism and stroke.²⁶ If the mechanisms of thromboembolism are not simply mechanical but related to an underlying prothrombotic state, measurement of suitable markers of thrombogenesis may perhaps be useful in identifying 'high risk' patients and determining the duration and intensity of anticoagulant therapy required.

Investigation of cardiac impairment and thrombus formation

In patients with left ventricular dysfunction, investigations are required to determine the degree of cardiac impairment, to diagnose the presence of aneurysm and finally, to detect the presence or absence of thrombus.

ECHOCARDIOGRAPHY

Echocardiography is the method most commonly used for diagnosing left ventricular function and the presence of intracardiac thrombi. If atrial fibrillation is also present, echocardiography may be useful in assessing valve disease and in detecting the presence of intracardiac thrombi.

Transthoracic echocardiography is a sensitive and specific method for the detection of mural thrombus. Echocardiography is also widely available and relatively inexpensive. It is now the method of choice for detecting left ventricular thrombus, although the sensitivity of two-dimensional echocardiography in the detection of left ventricular thrombus varies between 77 and 95% with a specificity of 86–93%.^{27–30} Clear delineation of the endocardium and thrombus margin is essential to the correct diagnosis of thrombus and echocardiographic indications of left ventricular thrombi³¹ are summarised in box 2. Echocardiography may nevertheless still miss smaller collections of thrombus (especially those areas of thrombus <5mm in diameter) that are still capable of producing devastating strokes and other serious thromboembolic complications. About 15% (with a quoted range of 5–25%) of studies are technically inadequate and cannot exclude the presence of a thrombus.^{27,28} Asinger *et al*³¹ proposed a grading scale that incorporates the quality of the examination in classifying the index of suspicion for left ventricular thrombus (box 3).

Two-dimensional echocardiography may also have disadvantages in visualising the left ventricular apex for characteristic wall thinning and possible apical thrombus formation (seen in aneurysm formation), as the sector angle is 90 degrees and the apex is usually too near the probe in the four-chamber view.³² Overall cardiac motion towards the apex in systole also tends to accentuate apical dyskinesia and to obscure inferoposterior wall dyskinesia.¹⁴ Axial and lateral resolution problems can also produce intracavity echoes that may mimic thrombi. For example, normal or pathologic structures at the apex that may simulate thrombi include the papillary muscles, chordal structures and tangential information from normal myocardium. A final limitation of echocardiography is its inability to reflect thrombus activity, that is, whether or not ongoing thrombogenesis is present. It is useful, however, in quantifying thrombus size and mass.

Transoesophageal echocardiography is a recent advance in improving imaging of intracardiac thrombi. This technique is of particular value in patients who are poor subjects for transthoracic echocardiography, and if metal valve prostheses are present. Although the true sensitivity of transoesophageal echocardiography for detecting intracardiac thrombi is unknown, but it is likely to be related to the size of the thrombus and the ability to obtain adequate imaging of the heart.

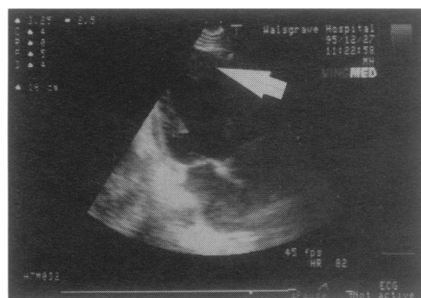
Echocardiography of left ventricular thrombi

Echocardiographic features of left ventricular thrombi

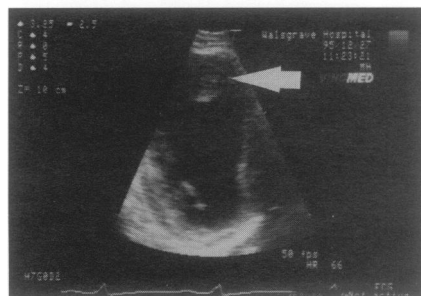- mass of echoes in the left ventricular cavity with a well circumscribed, defined border.
- abnormal motion pattern of the underlying myocardium, usually dyskinetic.
- distinct border shown between underlying myocardium and thrombus.
- echocardiographic 'texture' different, that is, acoustically distinct from that of underlying myocardium.
- usually apical position but not exclusive.
- free motion of an intracavity thrombus margin.
- ability to be recorded from more than one position.

Echocardiographic classification for suspicion of left ventricular thrombus (after Asinger *et al*³¹):

Class	Criteria
0	thrombus definitely not present; technically good examination
I	definite left ventricular echo mass but probably not thrombus; not technically good examination (probably cardiac structure other than thrombus)
II	definite abnormality, but nonspecific features or of uncertain nature
III	highly suspicious for thrombus; examination not technically adequate to definitely classify as diagnostic
IV	findings characteristic of thrombus (an echodense left ventricular mass discrete from the endocardial surface with other characteristics of thrombus); technically adequate examination



A



B

Figure Echocardiogram showing apical thrombus in a patient post-myocardial infarction. (A) standard subcostal long-axis view, (B) 'close-up' view of left ventricular apex (subcostal long-axis view)

RADIONUCLIDE STUDIES

Radionuclide studies may be useful in providing information on the degree of cardiac impairment and the presence of aneurysms. For example, equilibrium gated radionuclide ventriculography, employing 99m-technetium, is useful as an objective measure of left ventricular function. It also allows assessment of wall motion abnormalities, particularly by the study of phase and amplitude images.

Experimental studies have reported the use of radionuclide techniques in the detection of left ventricular thrombus. In addition, one useful radionuclide method of identifying left ventricular thrombus employs indium-111 platelet scintigraphy.^{28,33} This has a specificity of 100% and sensitivity of 71%, which is even greater than that of echocardiography.^{28,34} One further advantage of this method is its ability to assess the surface activity of the thrombus, and thus complement echocardiographic assessment. The use of indium-111 platelet scintigraphy may therefore be particularly helpful in identifying patients with chronic left ventricular thrombi at increased risk of embolisation. In one study, embolisation occurred in 23% of patients with a positive platelet scintigram and echocardiogram, compared with only 4% of patients with a negative platelet scintigram but positive echocardiogram.¹⁷ This method may therefore detect 'active' thrombi, which are at high risk of embolisation. However, platelet scintigraphy is essentially only available in specialist centres and is not widely available in clinical practice.

OTHER TECHNIQUES

Left ventricular contrast cineangiography may be useful for the diagnosis of significant wall motion abnormalities, including the presence of a left ventricular aneurysm. However, the investigation is less useful for the diagnosis of mural thrombus with a reported sensitivity of 31%, a specificity of 75% and a predictive accuracy of only 54%.³⁵ There is also the risk of dislodging mural thrombus (if present) and causing systemic thromboembolism by the procedure.

Other useful techniques for the investigation of left ventricular function and thrombus include magnetic resonance imaging^{32,36} and computed tomography,³⁷ but these techniques are limited to a few centres.

The role of anticoagulation in left ventricular dysfunction

ACUTE MYOCARDIAL INFARCTION

Patients with acute transmural myocardial infarction, especially those with large anterior myocardial infarctions or significant wall motion abnormalities, have a high risk of mural thrombus formation. Mural thrombus, in most instances following myocardial infarction, is often thought to resolve, either by endogenous fibrinolysis or endothelialisation, without the need for anticoagulants, thus reducing the risk of thromboembolism. However, there is lack of evidence for this.

By contrast, anticoagulant therapy has been shown to reduce the risk of embolisation of left ventricular thrombus following acute myocardial infarction.^{38,39} Turpie *et al*⁴⁰ reported that patients with anterior transmural myocardial infarction randomised to low dose heparin (5000 IU bid) had an incidence of intracardiac thrombus formation of 31.8%, which was reduced to 10.5% by the use of subcutaneous heparin at a dose of 12 500 IU bid subcutaneously. The importance of heparin was further emphasised in a review of 229 patients with their first acute anterior myocardial infarction, where patients initially receiving high-dose heparin had fewer left ventricular thrombi, irrespective of whether warfarin therapy was subsequently used.⁴¹ In the recent large Anticoagulants in the Secondary Prevention of Events in Coronary Thrombosis (ASPECT) study, concomitant warfarin therapy in patients following myocardial infarction reduced the risk of recurrent myocardial infarction (by 53%) and cerebrovascular events (by 40%), although there was only a limited reduction in mortality (by 10%, not statistically significant).⁴² This was consistent with previous studies, where randomised trials of anticoagulation in acute myocardial infarction have not shown a significant decrease in mortality in the groups receiving anticoagulants, but have shown a significant reduction in the incidence of systemic thromboembolism.^{43,44}

Contrary to expectation, the introduction of thrombolytic therapy (streptokinase or recombinant tissue plasminogen activator) in the acute management of patients with anterior myocardial infarction does not appear to reduce the risk of left ventricular thrombus formation.²⁷ Few data exist on whether early intervention with coronary angioplasty may reduce the risk of subsequent left ventricular thromboembolism.

Thus, following a large acute anterior myocardial infarction, especially if severe cardiac impairment is present, patients should be considered for full anticoagulation with heparin, followed by warfarin, in the absence of contraindications.

LEFT VENTRICULAR ANEURYSM

The definition of what a left ventricular aneurysm is remains controversial and may vary considerably between different studies and with different investigational methods.⁴⁵ Obviously, if definitions vary from study to study, the results or conclusions may do likewise; this may make some comparisons between the studies difficult to interpret.

It is generally accepted that the presence of a left ventricular aneurysm may have significant haemodynamic consequences. This includes the reduction in stroke volume and ejection fraction, and the presence of life-threatening arrhythmias. All of these changes may result in increased susceptibility to congestive heart failure, with important implications for patient survival.⁴⁶

Overall, the incidence of left ventricular aneurysm following myocardial infarction is about 7 to 10%, and surgical, autopsy and echocardiographic studies indicate that about half of all patients, with post-infarction ventricular aneurysm, have mural thrombus present.^{27,38,45} However, mural thrombus does appear to occur more frequently in the presence of an aneurysm.⁵ In an overview of six studies (mean follow-up periods of 6 to 15 months), Sherman *et al*⁴⁷ reported that late emboli occurred in only 1% of 98 anticoagulated patients, compared to 13% of 46 non-anticoagulated patients. It is also usually accepted, therefore, that the identification of mural thrombus in patients with left ventricular aneurysm warrants long-term oral anticoagulation as part of any medical management strategy.^{35,39,47}

It is also argued, however, that in chronic left ventricular aneurysms diagnosed at least six months after myocardial infarction, mural thrombus is common but the risk of embolism is low (an incidence of 0.35 per 100 patient-years) and that anticoagulation may not be warranted.^{3,11,45} One echocardiographic study reported that the presence of thrombi at six months follow-up was the same regardless of anticoagulant treatment.³⁸ In addition, two surgical studies showed no apparent effect of anticoagulation on the prevalence of mural thrombus identified at aneurysmectomy.^{35,48} The duration of anticoagulant therapy correlates inversely with the presence of thrombus, and this may account for the discrepancy in these findings of the benefits of anticoagulants.³⁵

Thus, despite the associated theoretical increase in thromboembolic risk by the presence of a thrombus in a left ventricular aneurysm, there is some evidence that these thrombi may only rarely embolise.²⁷ The precise reasons for this are unclear, but (as discussed earlier) the haemodynamic effects of left ventricular dysfunction or aneurysm may contribute to any altered thromboembolic risk in such patients. Aneurysm expansion may thus result in progressive haemodynamic deterioration with increasingly impaired left ventricular function.

The role of preventive strategies against thromboembolism in patients with left ventricular aneurysms therefore remains controversial, since the haemodynamic status of the patient may continue to alter with time. Nevertheless, anticoagulant therapy is recommended, at least in the initial period (3–6 months), after diagnosis of a left ventricular aneurysm, especially if intracardiac thrombus is present.

CHRONIC HEART FAILURE

The use of warfarin therapy in patients with chronic heart failure in routine clinical practice is uncommon. In a recent survey of patients acutely admitted with heart failure to our hospital, warfarin therapy was only prescribed to 19% (Lip GYH *et al*, submitted for publication). This is despite evidence that warfarin therapy may be beneficial in reducing the risk of thromboembolism and stroke in some subgroups of patients with heart failure.

For example, in one early study of 390 patients, there was a significant reduction in the incidence of thromboembolism in patients with chronic heart failure, especially in those with coexisting rheumatic heart disease, by the use of warfarin.² There was also a reduction in mortality by 5.8% (to 8%), with a 6–9% reduction in the incidence of thromboemboli.² Importantly, cardiac arrhythmia, a past history of congestive cardiac failure, or a past history of thromboemboli did not influence the outcome in these patients. Late thrombi are also common in patients with congestive heart failure and deteriorating left ventricular systolic function, although there is some evidence that impaired left ventricular function on its own is not a prerequisite for thrombus formation.³⁸ This is complemented by evidence that the reduction in heart rate and left

ventricular apical wall motion with the early use of beta-blocker therapy may actually increase the risk of thrombus formation.⁴⁹

A recent review by Baker *et al*⁶ reported that efficacy of anticoagulation in case series ranged from 0 to 100%. Warfarin therapy has however been associated with higher resolution of thrombus at echocardiography in patients with chronic heart failure when compared to patients on no therapy (59% vs 29%, respectively).¹⁶ Two controlled trials from almost 50 years ago also reported a decreased incidence of pulmonary thromboembolism in hospitalised patients treated with anticoagulants.^{50,51} However, if heart failure is only mild or moderate (NYHA Grade II and III), recent evidence from the V-HeFT study suggests that the incidence of thromboembolism or stroke is not high, with little benefit from warfarin therapy.⁵² The results from the V-HeFT study should be viewed with some caution as the study was not initially designed to investigate the benefits of antithrombotic therapy and the therapeutic level of anticoagulation was not routinely monitored as part of study protocol.

Thus, routine use of anticoagulants in patients with heart failure, unless severe, may not be justified. Furthermore, no controlled trial has fully assessed the efficacy or risks of anticoagulation for ambulant patients in heart failure and sinus rhythm in the outpatient setting.

ATRIAL FIBRILLATION AND LEFT VENTRICULAR DYSFUNCTION

The presence of heart failure or ventricular impairment is known to be additive to the risk of thromboembolism in patients with atrial fibrillation.⁵³ In the Stroke Prevention in Atrial Fibrillation study, for example, clinical predictors of an increase risk of stroke included a history of hypertension, recent (within three months) congestive heart failure, and a previous cerebrovascular event (either stroke or transient ischaemic attack); whilst echocardiographic predictors of stroke included a dilated left atrium on M-mode and global left ventricular dysfunction.^{54,55} On the basis of these clinical and echocardiographic predictors, the risk of stroke was 1.0% per year (for patients with no risk factors), rising to 6.0% per year (if one risk factor present); and 18.6% per year (if two or three risk factors were present).

CARDIOMYOPATHY

The benefits of anticoagulants in patients with dilated cardiomyopathy have been reported in many studies, with a reduction in thromboembolic events or resolution of thrombus on echocardiography.^{16,56,57} For example, Kyrle *et al*⁵⁶ reported that arterial or pulmonary thromboembolism occurred in 17 of 38 patients with dilated cardiomyopathy before starting oral anticoagulants, but no thromboembolic episodes occurred whilst on anticoagulants. In the study by Fuster *et al*,⁵⁷ none of the patients with dilated cardiomyopathy who were taking anticoagulants had a thromboembolic episode, compared to 14 thromboembolic events in the 104 patients who were not anticoagulated. However, there are no studies establishing the usefulness of anticoagulants in patients with hypertrophic cardiomyopathy who are in sinus rhythm.

Anticoagulation in cardiac impairment - the uncertainty, benefits and risks

The ability to select patients at high risk of thrombogenesis may be particularly relevant in patients with heart failure. This is particularly pertinent as a recent survey of British cardiologists indicated that anticoagulant therapy would not be initiated in patients with heart failure due to dilated cardiomyopathy or ischaemic heart disease who remained in sinus rhythm.⁵⁸ Reasons cited for not prescribing anticoagulant therapy included the fear of complications (54%), inconvenience (17%), lack of importance of thromboemboli (13%) and lack of manpower resources (9%).⁵⁸ As anticoagulation therapy is itself not without risk, clinicians contemplating antithrombotic therapy for prophylaxis against stroke and thromboembolic events in patients with left ventricular impairment have to balance the benefit of risk reduction against the risks of potentiating haemorrhage with warfarin therapy.

Overall, as discussed above, the evidence for the use of antithrombotic therapy in patients with cardiac impairment remains generally persuasive. In particular, a patient with severe cardiac impairment, with mural thrombus following a recent myocardial infarction (especially if an aneurysm is present) and who is in atrial fibrillation is at particularly high risk; anticoagulation is clearly required. However, for heart failure patients who are at low risk (eg, mild cardiac impairment, sinus rhythm), aspirin therapy may perhaps be sufficient, although there is lack of long-term data to fully confirm its benefits as thromboprophylaxis in such patients. Indeed there is some evidence that aspirin

Possible indications for anticoagulation therapy in cardiac impairment

Left ventricular aneurysm three months or more after acute myocardial infarction

- usually no need for echocardiography or anticoagulation treatment, unless established heart failure, intracardiac thrombus or severe cardiac impairment present

Acute myocardial infarction

- large infarction, with associated congestive cardiac failure
- anterior myocardial infarction without heart failure, if left ventricular thrombi are found on 2-dimensional echocardiogram

Dilated cardiomyopathy

- treatment with anticoagulants probably beneficial, regardless of presence or absence of left ventricular thrombi

Hypertrophic cardiomyopathy

- treatment with anticoagulants not established, unless mural thrombus present or previous thromboembolic episode.

In general, anticoagulation not required if the patient is in sinus rhythm, cardiac impairment is mild and there is no history of left ventricular thrombus, stroke or thromboembolic events

use long term after myocardial infarction is unproven and may even be harmful in patients with heart failure.⁵⁹

The risk of any bleeding with the use of anticoagulation therapy ranges from 11% to 40%.⁶⁰ Based on the results from five studies of anticoagulation following myocardial infarction (INR 2.8 to 2.8), Tsevat *et al*⁶¹ estimated rates of major and fatal bleeding of 4.4 and 0.6 per 100 patient-years respectively. However, the recent ASPECT study reported a major bleeding rate of only 1.5 per 100 patient-years in patients taking warfarin.⁴² There is, of course, a potentially higher risk of bleeding with a greater level of anticoagulation (for example, INR 2.5) when compared to patients with 'low level' anticoagulation (for example, INR 1.5).^{60,62} Nevertheless, in a study of patients with prosthetic heart valves, no difference in the prophylactic effect against thromboembolism was detected between the two groups.⁶² Similar conclusions were obtained in a study of patients with atrial fibrillation who were anticoagulated, in whom bleeding was most frequent in patients with unstable anticoagulation control and those with a previous history of thromboembolism.⁶³ Bleeding complications may, however, occur frequently, even when the INR (or Thrombotest) is within the therapeutic range.^{60,63} Theoretically, the risks of anticoagulation in patients with heart failure are also increased because of hepatic congestion and its effects on hepatic metabolism.⁶⁴ Finally, the optimal INR range for anticoagulant intensity has not been defined for patients with cardiac impairment.

The situation is therefore far from clear – just who is at risk of thromboembolism? Although warfarin will prevent stroke and other thromboembolic events, there is (at present) no easy way to stratify patients with heart failure for baseline risk and potential benefit. Suggested guidelines for initiating anticoagulant therapy in patients with left ventricular thrombi are summarised in box 4. Based on current evidence, patients sustaining a large anterior myocardial infarction with poor cardiac function, atrial fibrillation and a protruding, mobile left ventricular thrombus are at highest risk, requiring anticoagulant therapy. If patients are in sinus rhythm, anticoagulants should perhaps be reserved, especially for patients with severe cardiac impairment, the presence of intracardiac thrombus, and previous thromboembolism or stroke. Thus, until guidelines become available, clinical decisions to treat patients with cardiac impairment with anticoagulants must be made on an individual basis, based upon individual benefits and risks.

Conclusion

Warfarin has been established as thromboprophylaxis in certain subgroups of patients with cardiac impairment secondary to ischaemic heart disease. The evidence for aspirin as adequate thromboprophylaxis against thromboembolism and stroke in patients with cardiac impairment in sinus rhythm remains limited. A large-scale randomised controlled trial in ambulant patients with heart failure to evaluate the effectiveness of anticoagulant therapy and antiplatelet therapy is, however, long overdue. Nevertheless, the identification of patients with cardiac impairment who are at greatest risk of systemic embolisation is of particular importance – echocardiography and/or radionuclide studies are useful investigations for this purpose.

I thank Professor GDO Lowe for helpful advice during the preparation of this review. GL is recipient of the 1994 Edith Walsh and Ivy Powell research awards for cardiovascular disease research from the British Medical Association.

- Nixon JV. Left ventricular mural thrombus. *Arch Intern Med* 1983; 143: 1567-71.
- Griffith GC, Stragnell R, Levinson DC, Moore FJ, Ware AG. Study of beneficial effects of anticoagulant therapy in congestive heart failure. *Ann Intern Med* 1952; 37: 867-87.
- Lapeyre AC, Steele PM, Kazmier FJ, Vlietstra RE, Fuster V. Systemic embolism in chronic left ventricular aneurysm: incidence and the role of anticoagulation. *J Am Coll Cardiol* 1985; 6: 534-8.
- Mullen DC, Posey L, Gabriel R, Singh HM, Flemma RJ, Lopley D. Prognostic considerations in the management of left ventricular aneurysms. *Ann Thorac Surg* 1977; 23: 455-60.
- Schlichter J, Hellerstein HK, Katz LN. Aneurysm of the heart: a correlative study of one hundred and two proved cases. *Medicine (Baltimore)* 1954; 33: 43-86.
- Baker DW, Wright RF. Management of heart failure. IV. Anticoagulation for patients with heart failure due to left ventricular systolic dysfunction. *JAMA* 1994; 272: 1614-8.
- Furlan AJ, Cracium AR, Raju NR, Hart N. Cerebrovascular complication associated with idiopathic hypertrophic subaortic stenosis. *Stroke* 1984; 15: 282-4.
- Hardarson T, DeLaCazada CS, Curiel R, Goodwin JF. Prognosis and mortality of hypertrophic obstructive cardiomyopathy. *Lancet* 1973; 2: 1462-7.
- Gottdiener JS, Gay JA, Van-Voorhees LL, DiBianco R, Fletcher RD. Frequency and embolic potential of left ventricular thrombus in dilated cardiomyopathy: assessment by 2-dimensional echocardiography. *Am J Cardiol* 1983; 52: 1281-5.
- Falk RH, Foster E, Coats MH. Ventricular thrombi and thromboembolism in dilated cardiomyopathy: a prospective followup study. *Am Heart J* 1992; 123: 136-42.
- Meltzer RS, Visser CA, Fuster V. Intracardiac thrombi and systemic embolism. *Ann Intern Med* 1986; 104: 689-98.
- Maze SS, Kotler MN, Parry WR. Flow characteristics in the dilated left ventricle with thrombus: qualitative and quantitative Doppler analysis. *J Am Coll Cardiol* 1989; 13: 873-81.
- Delemarre BJ, Visser CA, Bot H, Dunning AJ. Prediction of apical thrombus formation in acute myocardial infarction based on left ventricular spatial flow pattern. *J Am Coll Cardiol* 1990; 15: 355-60.
- Kessler KM. Predictors of left ventricular thrombus formation: flow, asynergy and morphology. *J Am Coll Cardiol* 1990; 15: 361-2.

- 15 Haugland JM, Asinger RW, Mikell FL, Elspenger J, Hodges M. Embolic potential of left ventricular thrombi detected by two-dimensional echocardiography. *Circulation* 1984; 70: 588-98.
- 16 Stratton JR, Nemanich JW, Johannessen KA, Resnick AD. Fate of left ventricular thrombi in patients with remote myocardial infarction or idiopathic cardiomyopathy. *Circulation* 1988; 78: 1388-93.
- 17 Stratton JR, Ritchie JL.¹¹¹ In platelet imaging of left ventricular thrombi: predictive value for systemic emboli. *Circulation* 1990; 81: 1182-9.
- 18 Lip GYH, Lowe GDO, Metcalfe MJ, Rumley A, Dunn FG. Effects of warfarin therapy on plasma fibrinogen, von Willebrand factor and fibrin D-dimer in left ventricular dysfunction secondary to coronary artery disease with and without aneurysms. *Am J Cardiol* 1995; 76: 453-8.
- 19 Lip GYH, Lowe GDO. Fibrin D-dimer: a useful marker of thrombogenesis? *Clin Sci* 1995; 89: 205-14.
- 20 Lip GYH, Blann AD. von Willebrand factor and its relevance to cardiovascular disorders. *Br Heart J* 1995; 74: 580-3.
- 21 Lip GYH, Lowe GDO, Metcalfe MJ, Rumley A, Dunn FG. Is diastolic dysfunction associated with thrombogenesis? A study of circulating markers of a prothrombotic state in patients with coronary artery disease. *Int J Cardiol* 1995; 50: 31-42.
- 22 Jafri SM, Ozawa T, Mammen E, Levine TB, Johnson C, Goldstein S. Platelet function, thrombin and fibrinolytic activity in patients with heart failure. *Eur Heart J* 1993; 14: 205-12.
- 23 Sbarouni E, Bradshaw A, Andreotti F, Tuddenham E, Oakley CM, Cleland JG. Relationship between hemostatic abnormalities and neuroendocrine activity in heart failure. *Am Heart J* 1994; 127: 607-12.
- 24 Yamamoto K, Ikeda U, Furuhashi K, et al. The coagulation system is activated in idiopathic cardiomyopathy. *J Am Coll Cardiol* 1995; 25: 1634-40.
- 25 Lip GYH, Lowe GDO, Rumley A, Dunn FG. Increased markers of thrombogenesis in chronic atrial fibrillation: effects of warfarin therapy. *Br Heart J* 1995; 73: 527-33.
- 26 Petersen P, Kastrop J, Wilhelmsen R, Schutten HJ. Atrial natriuretic peptide in atrial fibrillation before and after electrical cardioversion therapy. *Eur Heart J* 1988; 9: 639-41.
- 27 Cregler LL. Antithrombotic therapy in left ventricular thrombosis and systemic embolism. *Am Heart J* 1991; 123: 1110-4.
- 28 Ezekowitz MD, Wilson DA, Smith EO, et al. Comparison of indium-111 platelet scintigraphy and two-dimensional echocardiography in the diagnosis of left ventricular thrombi. *N Engl J Med* 1982; 306: 1509-13.
- 29 Stratton JR, Lighty GW, Pearlman AS, Ritchie J. Detection of left ventricular thrombus by two-dimensional echocardiography: sensitivity, specificity and causes of uncertainty. *Circulation* 1982; 66: 156-66.
- 30 Visser CA, Kan G, David GK, Lie KI, Durrer D. Two dimensional echocardiography in the diagnosis of left ventricular thrombus: a prospective study of 67 patients with anatomic validation. *Chest* 1983; 83: 228-32.
- 31 Asinger RW, Mikell FL, Sharma B, Hodges M. Observations on detecting left ventricular thrombus with two dimensional echocardiography: emphasis on avoidance of false positive diagnoses. *Am J Cardiol* 1981; 47: 145-56.
- 32 Iga K, Matsuo M, Tsuji A, et al. [Usefulness of magnetic resonance imaging (MRI) in evaluation of left ventricular apical aneurysms] *Kokyu To Junkan* 1992; 40: 593-7.
- 33 Kessler C, Henningsen H, Reuther R, Kinnig B, Rösch M. Identification of intracardiac thrombi in stroke patients with indium-111 platelet scintigraphy. *Stroke* 1987; 18: 63-7.
- 34 Vandenberg BF.¹¹¹ In platelet scintigraphy and risk stratification for embolization from chronic left ventricular thrombi. *Circulation* 1990; 81: 1419-21.
- 35 Reeder GS, Lengyel M, Tajik AJ, Seward JB, Smith HC, Danielson GK. Mural thrombus in left ventricular aneurysm: incidence, role of angiography, and relation between anticoagulation and embolization. *Mayo Clin Proc* 1981; 56: 77-81.
- 36 Higgins CB, Byrd BF, McNamara MT, et al. Magnetic resonance imaging of the heart: a review of the experience in 172 subjects. *Radiology* 1985; 155: 671-9.
- 37 Nair CK, Sketch MH, Mahoney PD, Lynch JD, Mooss AN, Kenney NP. Detection of left ventricular thrombi by computerised tomography. *Br Heart J* 1981; 45: 535-41.
- 38 Weinreich DJ, Burke JF, Pauletto FJ. Left ventricular mural thrombi complicating acute myocardial infarction: long term follow-up with serial echocardiography. *Ann Intern Med* 1984; 100: 789-94.
- 39 Keating EC, Gross SA, Schlamowitz RA, et al. Mural thrombi in myocardial infarctions. *Am J Med* 1983; 74: 989-95.
- 40 Turpie AGG, Robinson JG, Doyle DJ, et al. Prevention of left ventricular mural thrombosis in acute transmural anterior myocardial infarction: a double blind trial comparing high dose with low dose subcutaneous calcium heparin. *N Engl Med J* 1989; 320: 352-7.
- 41 Kontny F, Dale J, Abildgaard U, Hegrenæs L, Lem P, Morstøl T. Adverse effect of warfarin in acute myocardial infarction: increased left ventricular thrombus formation in patients not treated with high-dose heparin. *Eur Heart J* 1993; 14: 1040-3.
- 42 ASPECT Study Group. Effect of long-term oral anticoagulant treatment on mortality and cardiovascular morbidity after myocardial infarction. *Lancet* 1994; 343: 499-503.
- 43 Ebert RV. Anticoagulants in acute myocardial infarction. Results of a cooperative clinical trial. *JAMA* 1973; 225: 724-29.
- 44 Working Party on Anticoagulant Therapy in Coronary Thrombosis to the Medical Research Council: assessment of short-term anticoagulant administration after cardiac infarction. *BMJ* 1969; 1: 335-42.
- 45 Cabin HS, Roberts WC. Left ventricular aneurysm, intraaneurysmal thrombus and systemic embolus in coronary artery disease. *Chest* 1980; 77: 586-90.
- 46 La Rovere MT, Pozzoli M, Traversi E, Opasich C, Specchia G. Exercise tolerance in patients with and without ventricular aneurysm. *Cardiology* 1987; 74: 483-9.
- 47 Sherman DG, Dyken ML, Fisher M, Harrison MJG, Hart RG. Antithrombotic therapy for cerebrovascular disorders. *Chest* 1990; 95 (suppl): 140S-155S.
- 48 Simpson MT, Oberman A, Kouchoukos NT, Rogers WJ. Prevalence of mural thrombi and systemic embolization with left ventricular aneurysm: effect of anticoagulation therapy. *Chest* 1980; 77: 463-9.
- 49 Johannessen KA, Nordrehaug JE, Lippe GVD. Increased occurrence of left ventricular thrombi during early treatment with timolol in patients with acute myocardial infarction. *Circulation* 1987; 75: 151-5.
- 50 Harvey WP, Finch C. Dicumarol prophylaxis of thromboembolic disease in congestive heart failure. *N Engl J Med* 1950; 242: 208-11.
- 51 Anderson GM, Hull E. Use of dicumarol as adjunct to treatment of congestive heart failure: results in controlled series of 61 cases. *South Med J* 1948; 41: 365-71.
- 52 Dunkman WB, Johnson GR, Carson PE, Bhat G, Farrell L, Cohn JN. Incidence of thromboembolic events in congestive heart failure. The V-HeFT VA Cooperative Studies Group. *Circulation* 1993; 87 (suppl 6): VI94-101.
- 53 Atrial Fibrillation Investigators. Risk factors for stroke and efficacy of antithrombotic treatment in atrial fibrillation: analysis of pooled data from randomized controlled trials. *Arch Intern Med* 1994; 154: 1449-57.
- 54 Stroke Prevention in Atrial Fibrillation Investigators. Predictors of thromboembolism in atrial fibrillation: I. Clinical features of patients at risk. *Ann Intern Med* 1992; 116: 1-5.
- 55 Stroke Prevention in Atrial Fibrillation Investigators. Predictors of thromboembolism in atrial fibrillation: II. Echocardiographic features of patients at risk. *Ann Intern Med* 1992; 116: 6-12.
- 56 Kyrle PA, Korninger C, Gossinger H, et al. Prevention of arterial and pulmonary embolism by oral anticoagulants in patients with dilated cardiomyopathy. *Thromb Haemost* 1985; 54: 521-3.
- 57 Fuster V, Gersh B, Giuliani E, Tajik A, Brandenburg R, Frye R. The natural history of idiopathic dilated cardiomyopathy. *Am J Cardiol* 1981; 47: 525-30.
- 58 Cleland JGF, Sbarouni E, Oakley CM, et al. Prophylaxis against thrombo-embolic events: Results of a survey of British Cardiologists. *Br Heart J* 1993; 69 (suppl): 51 (abstr).
- 59 Cleland JGF, Bulpitt CJ, Falk RH. Is aspirin safe for patients with heart failure? *Br Heart J* 1995; 74: 215-9.
- 60 Levine MN, Raskob G, Hirsh J. Hemorrhagic complications of long-term anticoagulant therapy. *Chest* 1990; 95 (suppl): 26S-36S.
- 61 Tsevat J, Eckman M, McNutt R, Pauker SG. Warfarin for dilated cardiomyopathy: a bloody tough pill to swallow? *Med Decis Making* 1989; 9: 162-9.
- 62 Saour JN, Sieck JO, Mamo LA, Gallus AS. Trial of different intensities of anticoagulation in patients with prosthetic heart valves. *N Engl J Med* 1990; 322: 428-32.
- 63 Lundström T, Rydén L. Haemorrhagic and thromboembolic complications in patients with atrial fibrillation on anticoagulant prophylaxis. *J Intern Med* 1989; 225: 137-42.
- 64 Husted S, Andreasen F. Problems encountered in long-term treatment with anticoagulants. *Acta Med Scand* 1976; 200: 379-84.