

# A comparison of 10 MHz ultrasound and 201-thallium/99m-technetium subtraction scanning in primary hyperparathyroidism

S.J. Gallacher, P. Kelly<sup>1</sup>, J. Shand<sup>3</sup>, F.C. Logue<sup>2</sup>, T. Cooke<sup>1</sup>, I.T. Boyle and J.H. McKillop

*University Departments of Medicine and <sup>1</sup>Surgery, and <sup>2</sup>Institute of Biochemistry, Glasgow Royal Infirmary, and <sup>3</sup>Department of Radiology, Stobhill Hospital, Glasgow, UK*

**Summary:** Both high resolution (10 MHz) ultrasound and 201-thallium/99m-technetium subtraction scanning (Tl/Tc) were carried out preoperatively in 25 patients with primary hyperparathyroidism.

Operative findings were the standard against which these two imaging methodologies were compared. Tl/Tc scanning showed a sensitivity of 42% and a specificity of 97%. By comparison, sensitivity of ultrasound was 38% and specificity 89%. Both techniques were positive together in nine instances and correctly localized the parathyroid adenoma in eight of these. In 44% of cases, however, both methods together failed to localize any abnormal parathyroid tissue.

The ability of these modalities to localize abnormal parathyroid tissue correctly tended to vary with gland size. Where both ultrasound and Tl/Tc scans were negative, median gland size was smaller at 170 mg (range 50–2,500 mg), compared with where Tl/Tc scanning was correct (750 mg, 150–6,820 mg;  $P < 0.03$ ), ultrasound was correct (960 mg, 100–6,820 mg;  $P < 0.03$ ) and both techniques together were correct (980 mg, 600–6,820 mg;  $P = 0.002$ ).

These results suggest that neither Tl/Tc scanning or ultrasound has sufficient sensitivity or specificity to be used routinely in the preoperative evaluation of patients with primary hyperparathyroidism.

## Introduction

Routine preoperative localization of parathyroid adenomas and/or hyperplasia continues to be the subject of some controversy.<sup>1</sup> High success rates of surgery with an experienced surgeon have cast doubt on whether any form of imaging technique is necessary.<sup>2</sup> These techniques have, however, over the past decade improved in sensitivity<sup>2,3</sup> and there is some evidence now that preoperative localization may both shorten operation (and anaesthetic) time and reduce the number of unsuccessful operations.<sup>3</sup>

Many different imaging modalities are now available and include thallium/technetium subtraction scanning,<sup>4</sup> high resolution (10 MHz) ultrasound,<sup>5</sup> computed tomography (CT)<sup>6</sup> and magnetic resonance imaging (MRI).<sup>7</sup> In this study the efficacy of the two most widely available techniques – 10 MHz ultrasound and thallium/technetium

subtraction scanning – were compared prospectively.

## Patients and methods

Ultrasound at 10 MHz and 201-thallium/99m-technetium subtraction scanning (Tl/Tc) was carried out in 30 consecutive patients presenting with primary hyperparathyroidism. The diagnosis was made on the basis of the presence of hypercalcaemia in association with either elevated or unsuppressed parathyroid hormone (PTH) concentrations. Serum calcium and albumin were measured by autoanalyser (Hitachi) and calcium was adjusted for the prevailing serum albumin concentration as previously described.<sup>8</sup> Intact PTH was measured by a highly sensitive two-site immunoradiometric assay.<sup>9</sup>

All ultrasound scans were carried out using a Diasonic DRF 400 ultrasound machine and a 10 MHz stand-off probe by one operator (JS) with the patient in a supine position with his neck hyperextended. This operator was 'blinded' to the results of the thallium/technetium scan which was

Correspondence: S.J. Gallacher, M.B., Ch.B., M.R.C.P. (UK), University Department of Medicine, Queen Elizabeth Building, Glasgow Royal Infirmary, Glasgow G31 2ER, UK.

Accepted: 16 November 1992

generally carried out first. The Tl/Tc scan was carried out with images acquired in one minute segments for 20 minutes after the intravenous administration of 80 MBq 201-thallium then 10 minutes after 180 MBq 99m-technetium.<sup>10</sup> These images were stored in a computer interfaced to a gamma camera and a 'subtraction' scan then obtained.

Twenty-five of these initial 30 patients went forward to neck exploration. All surgery was carried out by the same experienced surgeon (TC) who had full access to both imaging results at the time of operation. All tissue removed at surgery was examined by a pathologist and any parathyroid tissue found was weighed in order to give an assessment of the gland size. Surgery was not carried out in five of the patients initially studied – in each case this was because conservative management was felt to be more appropriate than surgery.

Details of patients studied and their preoperative biochemical parameters are shown in Table I. Size of the abnormal parathyroid gland removed is also shown. Since the data on the size of the abnormal parathyroid glands are skewed, the results are shown as medians and their associated range. For statistical comparison these data were logarithmically transformed and a Student's *t*-test carried out. Correlations where shown were made by regression analysis. Sensitivities and specificities for each technique were calculated assuming that in each patient there were four possible sites for a parathyroid adenoma.

## Results

The operative findings were the standard against which the two imaging methodologies were compared. Since only 25 of the original 30 patients went on to neck exploration, the data analysis is confined to these 25 patients.

A single parathyroid adenoma was identified at surgery in 23/25 patients. In one instance, two hyperplastic parathyroids were removed (with subsequent restoration of normocalcaemia) and in one no abnormal parathyroid tissue was found (and the patient remained hypercalcaemic). Post-operative serum calcium levels became normal in the 23 patients where a parathyroid adenoma was removed.

Thallium/technetium subtraction scanning correctly localized the abnormal parathyroid tissue in 10 out of 24 instances. The sensitivity of this technique was 42% and specificity 97%. Ultrasound at 10 MHz correctly localized the abnormal parathyroid tissue in 9 out of 24 instances (in one patient no abnormal parathyroid tissue was found at surgery). The sensitivity of this technique was 38%, with a specificity of 89%. In nine instances

both these imaging modalities were positive and were in agreement, and in eight of these instances the localization of the parathyroid adenoma was predicted correctly. However, in 11 patients (44%) both modalities were negative, though in two of these patients the thallium/technetium scan was difficult to interpret due to the presence of a multinodular thyroid. These two patients had large adenomas at surgery (2,500 mg, 600 mg).

The ability of these modalities to identify abnormal parathyroid tissue correctly tended to vary with the size of the abnormal gland (Figure 1). Where both techniques together failed to identify the abnormal parathyroid tissue, gland size was smaller at 170 mg (50–2,500 mg (median and range) compared with where thallium/technetium subtraction scanning alone was positive (750 mg, 150–6,820 mg;  $P < 0.03$ ), 10 MHz ultrasound alone was positive (960 mg, 100–6,820 mg;  $P < 0.03$ ) and both techniques combined were positive (980 mg, 600–6,820 mg;  $P = 0.002$ ). While thallium/technetium subtraction scanning tended to be able to localize smaller glands than 10 MHz ultrasound (and both techniques combined), this was not a statistically significant difference.

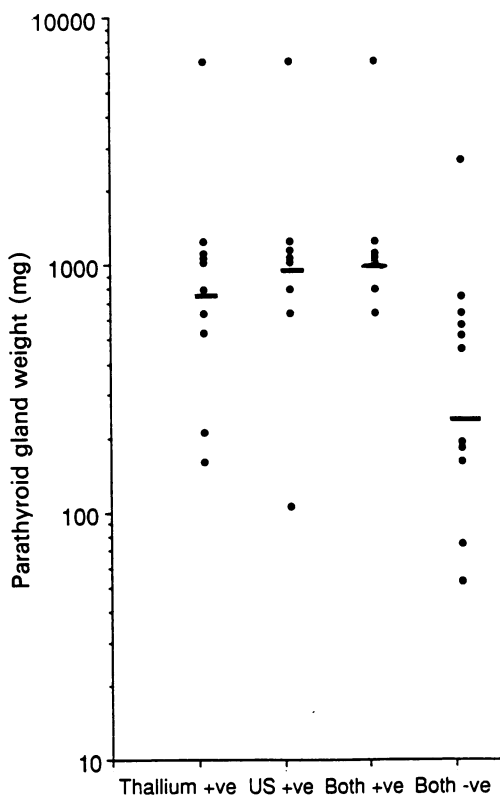
A significant positive correlation was evidence between PTH concentration and the size of the parathyroid adenoma ( $r^2 = 78\%$ ,  $P < 0.0001$ ) and PTH concentration and preoperative serum calcium concentration ( $r^2 = 63\%$ ,  $P < 0.0001$ ). A weaker, though again significant correlation, was evident between the preoperative serum calcium concentration and the size of the parathyroid adenoma ( $r^2 = 52\%$ ,  $P < 0.0001$ ).

## Discussion

The role of parathyroid imaging as a routine procedure prior to parathyroidectomy remains

**Table I** Details of patients studied and their preoperative biochemical profile

Number of patients	30 (23 female, 7 male)
Age (years)	62.5
SEM, range	2.3, 30–83
Serum calcium (mmol/l)	2.93
SEM, range (normal, 2.20–2.60)	0.05, 2.70–4.00
PTH (pmol/l)	10.5
SEM, range (normal, 1–5)	1.8, 2.7–56.0
Median gland size (mg)	540
Range	50–6,820



**Figure 1** Parathyroid gland weight at surgery compared with the result of preoperative imaging shown on a log scale. 'Thallium + ve' indicates where Tl/Tc imaging correctly localized abnormal parathyroid tissue, 'US + ve' indicates where ultrasound correctly localized abnormal parathyroid tissue, 'Both + ve' indicates where both Tl/Tc and ultrasound together were correct and 'Both - ve' indicates where both Tl/Tc and ultrasound together failed to detect any abnormal parathyroid tissue. Bars indicate medians.

controversial. A recent 'consensus' statement from the National Institutes of Health in the United States has suggested that parathyroid imaging should be reserved only for patients who have had a failed neck exploration.<sup>1</sup> Some evidence exists, however, that the use of preoperative parathyroid imaging may both reduce operating time and result in an increased number of successful operations.<sup>3</sup>

Many different techniques have been used in an attempt to localize parathyroid adenomas. At the present time the most widely used techniques include thallium/technetium subtraction scanning, 10 MHz ultrasound, computed tomographic (CT) scanning and magnetic resonance imaging (MRI).<sup>11</sup> Only one study to date has prospectively compared these four modalities.<sup>12</sup> Specificities of all four of these techniques were generally high (87–95%),

however sensitivities were not so high, with thallium/technetium scanning best at 73% and high resolution ultrasound poorest at 55%.

Direct comparison between thallium/technetium scanning and high resolution ultrasound generally shows both techniques are comparable with specificities very high and sensitivities in the range 74–80%.<sup>13,14</sup> Roses *et al.*,<sup>15</sup> however, in a study of 36 patients with primary hyperparathyroidism noted a sensitivity of only 49% for thallium/technetium subtraction scanning and 34% for ultrasound. Results were similar in this present study, with thallium/technetium subtraction scanning only having a sensitivity of 42% in localizing parathyroid adenomas with the sensitivity of 10 MHz ultrasound being even less good at 38%. These sensitivities are less good than the figures quoted in many of the initial studies using these modalities. Many of the initial studies with thallium/technetium scanning quoted sensitivities of the order of 65 to 90%.<sup>4,16,17</sup> Similarly sensitivities of around 70–80% were quoted for 10 MHz ultrasound.<sup>5</sup> However, other more recent studies have not been able to achieve sensitivities as high as in these initial series.<sup>2,11,12</sup> The reason for this discrepancy is not clear, however, the most important variable in localizing a parathyroid adenoma appears to be gland size.<sup>12</sup> With respect to thallium/technetium subtraction scanning, Gimlette *et al.*<sup>18</sup> noted the lower limit of detectability to correspond to a gland size of around 250 mg. The smallest gland detectable in this present study was 150 mg, though in keeping with Gimlette's data<sup>18</sup> the median gland size in those patients with positive thallium/technetium scans was significantly higher at 750 mg. With the use now of multichannel serum calcium analysers, hypercalcaemia is now to be found commonly as a chance occurrence and the average degrees of hypercalcaemia at presentation is less marked than was previously the case.<sup>19</sup> Since, as has been demonstrated in this study, serum calcium concentration is related to gland size, it may be that the mean size of parathyroid adenomas being treated surgically today is less than previously and therefore any imaging technique is likely to be less effective. Another possible factor to be taken into account is the fact that parathyroid hyperplasia is less easy to localize on imaging<sup>12</sup> – possibly because the glands tend to be smaller than parathyroid adenomas<sup>11</sup> – and if a greater proportion of patients in any given group had primary hyperparathyroidism secondary to hyperplasia rather than a solitary adenoma, then the sensitivity of the localizing technique used may be less good. This could not account for the poor sensitivities seen in this study as parathyroid hyperplasia was present in only one of 25 patients.

Where both these techniques are carried out, previous studies have suggested that the overall

sensitivity is higher than with either thallium/technetium scanning or ultrasound alone. Krubsack *et al.*<sup>12</sup> noted an overall sensitivity of 85% when thallium/technetium scanning and ultrasound were combined. Combining three or even four imaging techniques, however, did not add further to the sensitivity observed. Similarly, Gooding *et al.*<sup>14</sup> found combining thallium/technetium scanning with ultrasound to be more sensitive than either technique alone and these authors recommended that both these techniques should be used together in the preoperative assessment of the patient with primary hyperparathyroidism as both these techniques appear to be complementary. However, given the fact that ultrasound involves no exposure to radioactivity, the logical sequence of investigation would be to carry out high resolution ultrasound first. If this is positive, proceed to surgery. If this is negative a thallium/technetium scan should also then be carried out prior to surgery. While this sequence of investigation would appear attractive the fact that 44% of patients in this study had negative results for both techniques would appear to limit their usefulness even when combined.

This study has only investigated the use of imaging at the time of first neck exploration and furthermore only those patients with adenomas in

the neck, as opposed to the mediastinum, were studied. The effect of surgery in distorting tissue planes is such that thallium/technetium scanning is probably the investigation of choice in patients who have had a previous unsuccessful neck exploration.<sup>20</sup> However, some evidence exists that in this situation an experienced operator may achieve similar results to Tl/Tc scanning with high resolution ultrasound.<sup>14</sup> Furthermore, thallium/technetium scanning is probably also the technique of choice where a mediastinal adenoma is suspected.<sup>4</sup> Advances are also taking place in attempting to improve the sensitivity of nuclear medicine imaging, particularly with the use of 99m-technetium sestamibi in place of 201-thallium.<sup>21</sup> However, the place of this technique in routine imaging remains to be established.

While evidence exists that preoperative parathyroid localization may be beneficial, results from this study suggests that neither thallium/technetium subtraction scanning nor high-resolution ultrasound are sufficiently sensitive alone to be of value in the routine assessment of patients with primary hyperparathyroidism. This is particularly the case where hypercalcaemia is relatively mild. There may be a place, however, for combining these two techniques. Further studies are required to specifically address this issue.

## References

1. Consensus Development Conference Panel. Diagnosis and management of asymptomatic primary hyperparathyroidism: Consensus Development Conference statement. *Ann Intern Med* 1991, **114**: 593-597.
2. Winzelberg, G.G. Parathyroid imaging. *Ann Intern Med* 1987, **107**: 64-70.
3. Attie, J.N., Khan, A., Rumancik, W.M. Miskowitz, G.W., Hirsch, M.A. & Herman, P.G. Preoperative localisation of parathyroid adenomas. *Am J Surg* 1988, **156**: 323-326.
4. Young, A.E., Gaunt, J.I., Croft, D.N., Collins, R.E.C., Wells, C.P. & Coakley, A.J. Localisation of parathyroid adenomas by thallium 201 and technetium 99m subtraction scanning. *Br Med J* 1983, **186**: 136-138.
5. Reading, C.C., Charboneau, J.W., James, E.M. *et al.* High resolution parathyroid sonography. *Am J Roentgenol* 1982, **139**: 539-546.
6. Stark, D.D., Moss, A.A., Gooding, G.A.W. & Clark, O.H. Parathyroid scanning by computed tomography. *Radiology* 1983, **148**: 297-299.
7. Stark, D.D., Clark, O.H. & Moss, A.A. Magnetic resonance imaging of the thyroid, thymus and parathyroid glands. *Surgery* 1984, **96**: 1083-1091.
8. Gardner, M.D., Dryburgh, F.J., Fyffe, J.A. & Jenkins, A.S. Predictive value of derived calcium figures based on the measurement of ionised calcium. *Ann Clin Biochem* 1981, **18**: 106-109.
9. Logue, F.C., Perry, B., Chapman, R.S., Milne, I., James, K. & Beasall, G.H. A two-site immunoradiometric assay for PTH(1-84) using N and C terminal specific monoclonal antibodies. *Ann Clin Biochem* 1991, **28**: 160-166.
10. Fogelman, I., McKillop, J.H., Bessent, R.G., Boyle, I.T., Gray, H.W., Gunn, I. & Hutchison, J.S.F. Successful localisation of parathyroid adenomata by thallium 201 and technetium 99m subtraction scintigraphy. Description of an improved technique. *Eur J Nucl Med* 1984, **9**: 545-547.
11. Goris, M.L., Basso, L.V. & Keeling, C. Parathyroid imaging. *J Nucl Med* 1991, **32**: 887-889.
12. Krubsack, A.J., Wilson, S.D., Lawson, T.L. *et al.* Prospective comparison of radionuclide, computed tomographic, sonographic and magnetic resonance localisation of parathyroid tumours. *Surgery* 1989, **106**: 639-646.
13. Winzelberg, G.C., Hydrovitz, J.D., O'Hara, K.R. *et al.* Parathyroid adenomas evaluated by 201Tl/99mTc pertechnetate scintigraphy and high resolution ultrasonography. *Radiology* 1985, **155**: 231-235.
14. Gooding, G.A.W., Okerlund, M.D., Stark, D.D. & Clark, O.H. Parathyroid imaging: comparison of double-tracer (Tl-201, Tc-99m) scintigraphy and high resolution US. *Radiology* 1986, **161**: 57-64.
15. Roses, D.F., Sudarsky, L.A., Sanger, J. *et al.* The use of preoperative localization of adenomas of the parathyroid glands by thallium-technetium subtraction scintigraphy, high resolution ultrasonography and computed tomography. *Surg Gynecol Obstet* 1989, **168**: 99-106.
16. Ferlin, G., Borsato, M., Camerani, M., Conte, N. & Zotti, D. New perspectives in localising enlarged parathyroids by Technetium-Thallium subtraction scan. *J Nucl Med* 1983, **24**: 438-441.
17. Gunn, I.G., McKillop, J.H., McBride, D. *et al.* How reliable is Thallium-201/Technetium-99m subtraction scintigraphy in localising parathyroid adenomata? *Nuklear Medizin* 1986, **22** (Suppl): 511-513.
18. Gimlette, T.M.D., Brownless, S.M., Taylor, W.H., Shields, R. & Simkin, E.P. Limits to parathyroid imaging with thallium-201 confirmed by tissue uptake and phantom studies. *J Nucl Med* 1986, **27**: 1262-1265.

19. Fiskin, R.A., Heath, D.A. & Bold, A.M. Hypercalcaemia – a hospital survey. *Q J Med* 1980, NS 49: 405–418.
20. Young, A.E., Gaunt, J.I. & Croft, D. Location of parathyroid adenomas by <sup>201</sup>Tl and <sup>99m</sup>Tc subtraction scanning. *Br Med J* 1983, 287: 427–428.
21. O'Docherty, M.J., Kettle, A.G., Wells, P., Collins, R.E.C. & Coakley, A.J. Parathyroid imaging with technetium-99m-sestamibi: preoperative localisation and tissue uptake studies. *J Nucl Med* 1992, 33: 313–318.