

## Delayed Diagnosis

# Pubic osteomyelitis caused by *Staphylococcus simulans*

I. Sturgess, F.C. Martin and S. Eykyn<sup>1</sup>

Elderly Care Unit and<sup>1</sup>Microbiology Department, St Thomas' Hospital, Lambeth Palace Road, London SE1 7EH, UK

**Summary:** A patient is described who developed pubic osteomyelitis caused by an uncommon pathogen, *Staphylococcus simulans*.

### Introduction

Although community-acquired bacteraemic infections with coagulase-negative staphylococci are rare, hospital-acquired infections are common and increasing, particularly with intravenous devices.<sup>1</sup> We report a case of pubic osteomyelitis caused by *Staphylococcus simulans*, an unusual species of coagulase-negative staphylococcus, affecting an elderly disabled diabetic woman.

### Case report

A 77 year old previously active and independent woman presented in June 1988 with a profound right hemiparesis and dense dysphasia due to a left cerebral hemisphere infarction. Serum C-reactive protein (CRP) at this time was less than 10 mg/l. She had had non-insulin-dependent diabetes mellitus for 14 years controlled with diet and tolbutamide, and psoriasis since childhood in virtual remission on admission with no treatment. Recovery from her stroke was slow and hampered by a painful left hip due to pre-existing osteoarthritis.

In December 1988 she developed a painful right groin with tenderness over the right pubic bone. Neither plain X-rays nor isotope bone scan showed any abnormalities in the pelvis and in particular the region of the pubic bones was normal (Figure 1a). The diagnosis was unclear but the pain responded to a right ilio-inguinal nerve block. Later that month further pain in the right groin was diagnosed as an adductor femoris tear or tendinitis, and responded to a steroid and local anaesthetic injection at the right adductor tubercle. CRP at this time was again less than 10 mg/l. In March 1989 local treatment with a salicylate derivative was initiated for a large psoriatic lesion on the scalp which had developed since her admission. This lesion was not cultured and healed rapidly.

A month later deterioration in her functional ability was noted and the CRP was 252 mg/l, the total white cell count was  $17.5 \times 10^9/l$ . Daily physical examinations, including regular temperature measurements, were normal for 6 days, as were urine microscopy and culture and a chest X-ray. On the seventh day a tender pubic symphysis was noted and her CRP was 67 mg/l. A clinical diagnosis of pubic osteomyelitis was made. Two sets of blood cultures grew *S. simulans* in all bottles, fully sensitive to all anti-staphylococcal antibiotics, and treatment was started with flucloxacillin, 2 g intravenously 6 hourly for 11 days followed by 500 mg 6 hourly by mouth, and fusidic acid 500 mg orally three times daily.

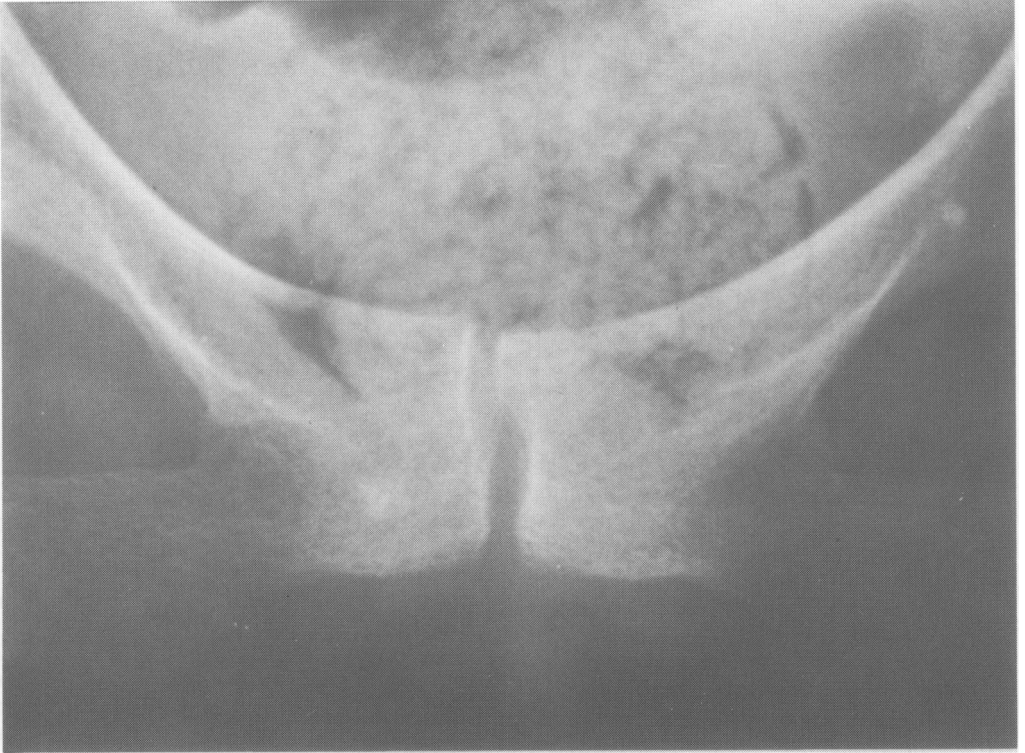Initially the pubic symphysis was radiologically normal but within a week rarefaction was detected (Figure 1b) and an isotope bone scan revealed a localized hot spot at the pubic symphysis (Figure 2). Clinical examination, repeated urine examination and two echocardiograms were otherwise unremarkable.

Her pain settled and antibiotics were therefore discontinued after 25 days of therapy. The pain recurred three days later and the CRP was 44 mg/l. In view of this flucloxacillin and fusidic acid were restarted and continued until not only her symptoms had resolved but the CRP had fallen to less than 10 mg/l. This was achieved after a further 31 days of therapy. Following cessation of antibiotics there were no clinical signs of recurrence of infection. Rehabilitation continued and she was discharged from hospital in August 1989, and has remained well.

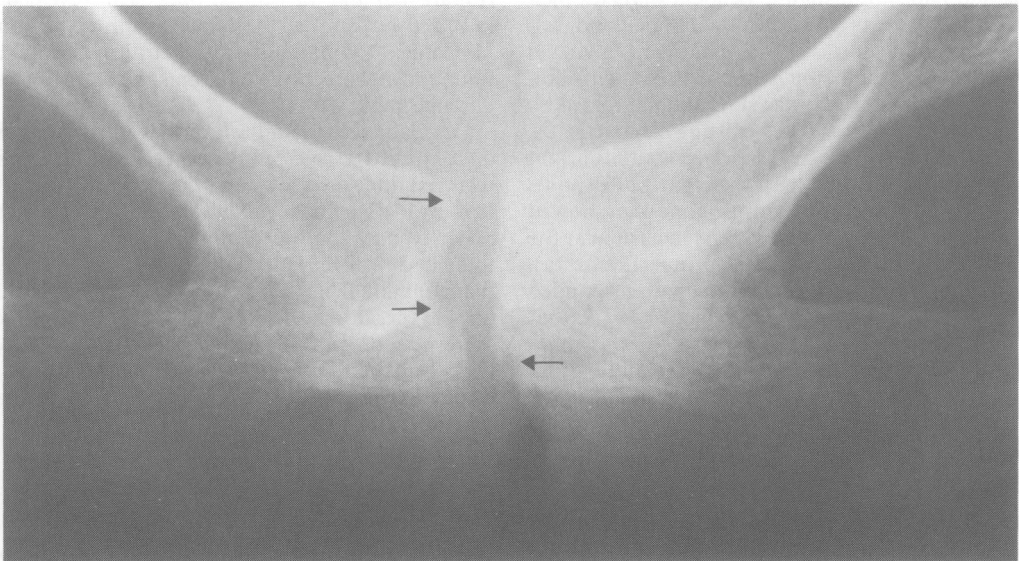
### Discussion

The coagulase-negative staphylococci are an ubiquitous group of bacteria that colonize the skin, particularly in areas of excessive surface humidity such as the groin, axilla and perineum. They

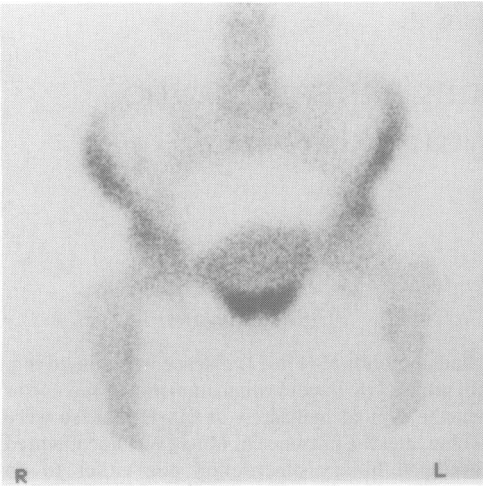
a



b



**Figure 1** Radiographic appearance of pubic symphysis. (a) Normal appearance and (b) demonstrating areas of rarefaction (arrows) consistent with pubic osteomyelitis.



**Figure 2** Isotope bone scan. Increased uptake in the region of the pubic symphysis.

include many species of which the commonest is *S. epidermidis*. In the past, few laboratories speciated coagulase-negative staphylococci and either reported them as coagulase-negative staphylococci or *S. epidermidis (sensu lato)* or even *S. albus*. Techniques for speciation became available in the early 1980s and routine identification of coagulase-negative staphylococcus is now possible. There have been occasional recent reports of infections caused by *S. simulans*, including native valve endocarditis<sup>2,3</sup> and urinary tract infections,<sup>4</sup> which suggest that *S. simulans* is an important if rare cause of significant infection. In common with *S. lugdunensis*, a recently described species of coagulase-negative staphylococcus, *S. simulans* can cause severe infections that are more usually associated with *S. aureus* than with coagulase-negative staphylococci.

Less than 1% of community-acquired bacteraemias are caused by coagulase-negative staphylococci (St Thomas' Hospital figures) and such patients usually have endocarditis

occasionally with concomitant vertebral osteomyelitis. Endocarditis can be notoriously difficult to diagnose, particularly in the elderly, and can present with a stroke. The stroke in this patient had occurred some 9 months before the development of pubic osteomyelitis and the CRP on presentation was normal. Endocarditis was also thought to have been excluded by two normal echocardiograms, negative urine microscopy and no clinical stigmata.

Positive blood cultures and a raised CRP with the clinical picture described was virtually diagnostic of pubic osteomyelitis and biopsy was not considered justified.

*S. simulans* is occasionally found as part of the normal skin flora and it is of relevance that she had a psoriatic lesion on her scalp. She had also received a steroid injection into the right adductor tubercle 4 months before the development of pubic osteomyelitis.

Pubic osteomyelitis has been reported in previously fit children,<sup>5</sup> and intravenous drug abusers.<sup>6</sup> In the elderly it usually follows genitourinary procedures,<sup>7</sup> and Gram-negative organisms predominate.

*S. simulans* has been responsible for only eight episodes of bacteraemia in patients (including this case) at St Thomas' Hospital since 1970 (S. Eykyn, personal communication). Six of these have been hospital-acquired infections, three associated with intravenous lines, one catheter-associated urinary tract infection and one wound infection. All six strains were resistant to beta-lactam antibiotics. One episode of *S. simulans* bacteraemia was community acquired. This involved a 63 year old man who had native valve endocarditis, whose strain, like that of the case presented, was fully sensitive. This patient required emergency valve replacement.

To our knowledge, this is the first case of pubic osteomyelitis caused by *S. simulans* and demonstrates, firstly, the insidious nature of osteomyelitis in the elderly and, secondly, the pathogenic potential of coagulase-negative staphylococci other than *S. epidermidis*.

## References

1. Winston, D.J., Dudnick, D.V., Chapin, M., Ho, W.G., Gale, R.P. & Martin, W.J. Coagulase-negative staphylococcal bacteraemia in patients receiving immunosuppressive therapy. *Arch Intern Med* 1983, **143**: 32–36.
2. McCarthy, J.S., Stanley, P.A. & Mayall, B. A case of *Staphylococcus simulans* endocarditis affecting a native heart valve. *J Infection* 1991, **22**: 211–212.
3. Jansen, B., Schmacher-Perdreau, F., Peters, G., Reinhold, G. & Schonemann, J. Native valve endocarditis caused by *Staphylococcus simulans*. *Eur J Clin Microbiol Infect Dis* 1992, **11**: 268–269.
4. Iwantschiff, A., Kuhen, E. & Brandis, H. Species distribution of coagulase-negative staphylococci isolated from clinical sources. *Zbl Bakt Hyg A* 1985, **260**: 41–50.
5. Heldrich, F. & Harris, V. Osteomyelitis of the pubis. *Acta Paediatr Scand* 1979, **68**: 62–67.
6. Sequira, W., Jones, E., Siegel, M.E., Lorenz, M. & Kallick, C. Pyogenic infections of the pubic symphysis. *Ann Intern Med* 1982, **96**: 604–606.
7. Bouza, E., Winston, D.J. & Hewitt, W.L. Infectious osteitis pubis. *Urology* 1978, **12**: 663–669.