

Juvenile proximal spinal muscular atrophy with early hypertrophy of calves

J. M. GOBERNADO*
M.D.

C. RIVA*
M.D.

A. GIMENO*
M.D.

E. GARCÍA-ALBEA*
M.D.

A. ANAYA†
M.D.

*Service of Neurology, Ramón and Cajal Center, and †Service of Pathology, Puerta of Hierro Clinic, Madrid, Spain

Summary

The clinical, electrophysiological, histological and ultrastructural features of a patient with chronic spinal muscular atrophy of adolescent onset associated with hypertrophied calf-muscle are described. This recently recognised entity must be distinguished from other types of spinal muscular atrophy.

KEY WORDS: spinal muscular atrophy, hypertrophied calf-muscle.

Introduction

Since the papers of Werdnig (1891) and Hoffmann (1893) with the first descriptions of hereditary spinal muscular atrophy (SMA), this field has become increasingly complex with numerous reports on a variety of clinical pictures. Marsden (1975) and more recently Pearn (1980) has suggested classifications on the basis of the clinical and genetic findings.

Pearn and Hudgson (1978) reported a new variant of SMA, characterized by X-linked recessive inheritance, adolescent onset, early hypertrophy of calves and a slowly progressive clinical course, with histological and electrophysiological evidence of chronic denervation atrophy.

The purpose of this report is to describe a new case of juvenile proximal SMA and calf hypertrophy associated with pes cavus, scoliosis, gynaecomastia and cryptorchidism.

Case report

The patient was first seen in 1975 when he was a 16-year-old boy. He is the oldest of 3 children born to healthy non-consanguineous parents.

His motor development was normal until he was eleven when he realized that he could not run

properly. The following year his calves were noted to have become very large. During the next 4 years, the weakness slowly progressed and he began to suffer painful cramps in the calf muscles, but in recent years the condition seems clinically stable. A maternal uncle probably had the same disease.

Examination revealed gross hypertrophy of the calf muscles (Fig. 1); there was slight weakness and atrophy of triceps brachialis and pectoralis and atrophy of quadriceps with associated fasciculation. Weakness was prominent in the proximal muscles of both legs. No facial or neck weakness was noted. The cranial nerves were normal, without evidence of colour blindness or dysphagia. The patellar reflexes were absent. Sensation, sphincters, and co-ordination were normal and no intellectual impairment was appreciated. There was also bilateral pes cavus, slight scoliosis, gynaecomastia, and left cryptorchidism.

Complete blood count, sedimentation rate, blood urea nitrogen, uric acid, serum alkaline phosphatase, bilirubin, glucose, and protein electrophoretic and immunoelectrophoretic patterns were normal. Cerebrospinal fluid was also normal for protein content, electrophoretic and immunoelectrophoretic patterns, glucose and serology. Serum creatine kinase level was slightly increased at 178 iu/litre (normal 0-150). Aldolase, serum glutamic oxaloacetic acid, transaminase and lactic dehydrogenase serum enzymes were normal as were lactic acid levels after ischaemic exercise. X-ray examination showed slight scoliosis. The electroencephalogram and electrocardiogram were normal. Electromyographic examination of both quadriceps and gastrocnemius muscles revealed a reduced number of motor units at maximal voluntary effort, and large action potentials of longer duration than normal. Maximal motor conduction velocities and terminal motor latencies in both

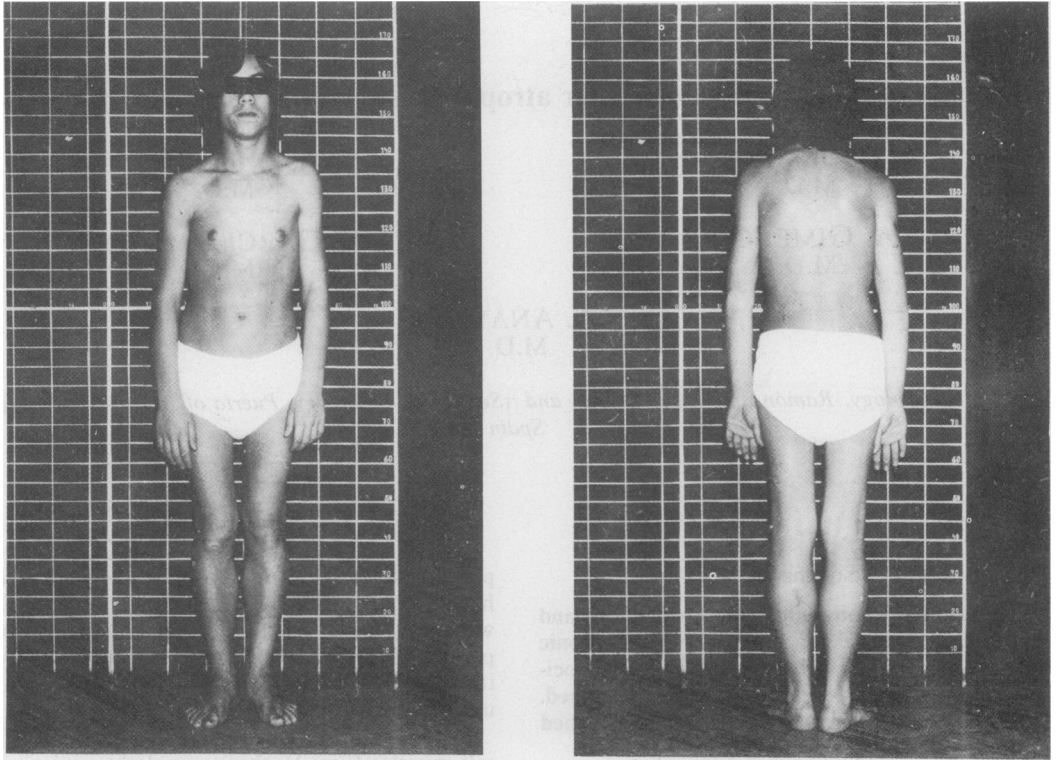


FIG. 1. The patient showing (a) significant hypertrophy of calves with pronounced proximal wasting and a slight scoliosis with shoulder asymmetry; (b) gynaecomastia.

both peroneal and right median nerves were normal. The latency and amplitude of evoked sensory potentials in sural and median nerves were normal.

The left gastrocnemius muscle was biopsied. Light microscopy showed relatively normal fascicles with discrete groups of angulated atrophic fibres and some degree of excessive variation in the size of muscle fibres with evidence of hypertrophy in some of them. Type I and type II fibres were present in approximately equal number, and both types of fibres were involved in the atrophic process. Of the normal sized fibres, 40–60% contained subsarcolemmal deposits of red-staining granular material, which showed intense SDH* and DPNH-TR** oxidative reactions (Fig. 2). In the ultrastructural study, the majority of the muscle fibres were normal in size with diameters ranging from 30 to 50 μm . There were few small clusters of angulated atrophic fibres with diameters of less than 20 μm . Subsarcolemmal aggregates of elongated and bizarre mitochondria were seen in the normal-sized fibres. The atrophic fibres showed altered distribution of the myofibrils, some of which were cut longitudinally and others transversally, with shortened and thickened Z-lines forming rod-like electrodense areas.

Discussion

Several types of juvenile proximal SMA have been described, including: the common autosomal recessive Wohlfart-Kugelberg-Welander type (Wohlfart, Fex and Eliasson, 1955; Kugelberg and Welander, 1956); the autosomal recessive type described in an inbred community in the Ryukyuan islands of southern Japan, that includes pes cavus and scoliosis (Kondo, Tsubaki and Sakamoto, 1970); an autosomal recessive type associated with microcephaly and mental subnormality described in 3 brothers (Spiro, Fogelson and Goldberg, 1967); an autosomal dominant type (Kugelberg and Welander, 1956); an X-linked recessive type associated with exaggerated deep reflexes and extensor plantar responses reported in 3 brothers (Nishigaki, Ando and Takeda, 1966); and another X-linked recessive variety with hypertrophy of calves recently described by Pearn and Hudgson (1978).

The patient reported presents a slowly progressive disease with onset at 11 years old, characterized essentially by hypertrophied calf-muscles, generalized symmetrical muscle atrophy most marked proximally, fasciculation in the quadriceps muscles, and

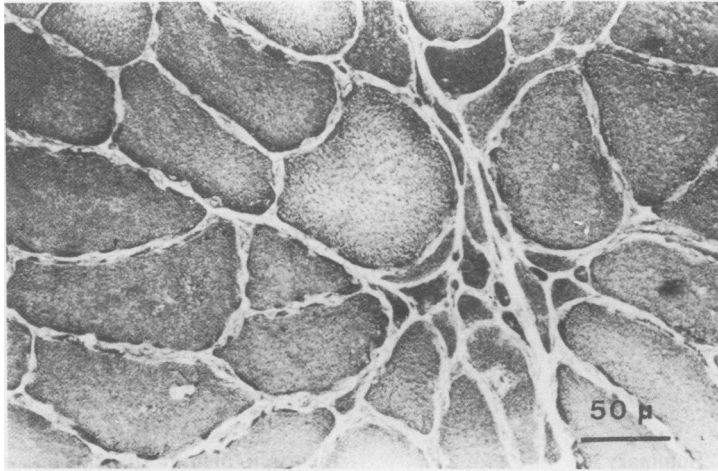


FIG. 2. Left gastrocnemius muscle. DPNH-TR. Group of angulated atrophic fibres within fascicles of normal fibres. Some grade of excessive variation in the size of muscle fibres with hypertrophy in some of them. Some non-atrophic fibres contain discrete subsarcolemmal deposits with intense oxidative reaction.

diminished or absent reflexes, associated with pes cavus, scoliosis, gynaecomastia and cryptorchidism. The clinical, electrophysiological and pathological findings indicate the presence of chronic denervation atrophy, probably due to anterior horn cell disease. The mode of inheritance could not be clearly established in our proband. However, as he is a male with an otherwise unremarkable family history, except for a possibly affected maternal uncle, an X-linked recessive inheritance seems probable. The clinical signs are consistent with the juvenile proximal SMA type described by Pearn and Hudgson (1978). Although malformations, such as pes cavus, scoliosis and gynaecomastia have occasionally been found with SMA (Namba, Aberfeld and Grob, 1970), as far as we know, they have not been previously reported with this variety of the condition.

Clinically, these patients may resemble cases of Becker or limb girdle muscular dystrophy, but the electrophysiological and muscular biopsy findings are distinctive.

The importance of recognition lies in distinguishing such cases from other types of SMA so that more accurate prognosis and genetic advice can be given. The case reported can be included within the classification of SMA recently suggested by Pearn (1980), contributing in our opinion support for the usefulness of this classification.

References

- HOFFMANN, J. (1893) Über chronische spinale Muskelatrophie im Kindesalter auf familiärer Basis. *Deutsche Zeitschrift für Nervenheilkunde*, **3**, 427.
- KONDO, K., TSUBAKI, T. & SAKAMOTO, F. (1970) The Ryukyuan muscular atrophy. An obscure heritable neuromuscular disease found in the islands of southern Japan. *Journal of the Neurological Sciences*, **11**, 359.
- KUGELBERG, E. & WELANDER, L. (1956) Heredofamilial juvenile muscular atrophy simulating muscular dystrophy. *Archives of Neurology and Psychiatry*, **75**, 500.
- MARSDEN, C.D. (1975) Inherited neural atrophy and degeneration predominantly of lower motor neurons. In: *Peripheral Neuropathy* (Eds. P. J. Dyck, P. K. Thomas and E. H. Lambert) Vol II, p. 771. Saunders, Philadelphia, London, Toronto.
- NAMBA, T., ABERFELD, D.C. & GROB, D. (1970) Chronic spinal muscular atrophy. *Journal of the Neurological Sciences*, **11**, 401.
- NISHIGAKI, S., ANDO, K. & TAKEDA, A. (1966) A pedigree with atypical hereditary neurogenic amyotrophy. *Clinical Neurology (Tokyo)*, **6**, 189.
- PEARN, J. (1980) Classification of spinal muscular atrophies. *Lancet*, **i**, 919.
- PEARN, J. & HUDGSON, P. (1978) Anterior-horn cell degeneration and gross calf hypertrophy with adolescent onset. A new spinal muscular atrophy syndrome. *Lancet*, **i**, 1059.
- SPIRO, A.J., FOGELSON, M.H. & GOLDBERG, A.C. (1967) Microcephaly and mental subnormality in chronic progressive spinal muscular atrophy of childhood. *Developmental Medicine and Child Neurology*, **9**, 594.
- WERDNIG, G. (1891) Zwei frühinfantile hereditäre Fälle von progressiver Muskelatrophie unter dem Bilde der Dystrophie, aber auf neurotischer Grundlage. *Archiv für Psychiatrie und Nervenkrankheiten*, **22**, 437.
- WOHLFART, G., FEX, J. & ELIASSON, S. (1955) Hereditary proximal spinal muscular atrophy—a clinical entity simulating progressive muscular dystrophy. *Acta Psychiatrica et Neurologica*, **30**, 395.

(Accepted 18 August 1982)