

Haemodialysis and charcoal haemoperfusion in acute inorganic mercury poisoning

D. P. WORTH*
M.B., M.R.C.P.

A. M. LEWINS*
S.R.N.

A. M. DAVISON*
B.Sc., M.D., F.R.C.P.

M. JILL LEDGERWOOD†
A.I.M.L.S.

ANDREW TAYLOR†
Ph.D.

*Department of Renal Medicine, St James's University Hospital, Leeds LS9 7TF and †Robens Institute of Industrial and Environmental Health and Safety, University of Surrey, Guildford GU2 5XH

Summary

A 29-year-old gardener developed acute renal failure following the ingestion of 'Mersil', a combination of mercurous and mercuric chloride, achieving a plasma mercury concentration of 22,000 nmol/litre (400 µg/litre). Haemodialysis and charcoal haemoperfusion were ineffective in removing mercury despite prior treatment with the chelating agent dimercaprol. The acute renal failure resolved after 10 days and there are no residual sequelae.

KEY WORDS: mercury poisoning, haemoperfusion, renal failure.

Introduction

Poisoning with mercury is uncommon but may follow exposure to inorganic, organic or elemental forms of the metal. Absorption, distribution, excretion and toxicity depend upon the compound to which the patient is exposed, organic and elemental mercury being well absorbed (80-100%) from both the gastrointestinal and respiratory tracts, whereas retention of ingested inorganic mercury is no more than 15% (Clarkson, 1972). Elemental and organic mercury compounds are lipophilic and in these forms can accumulate in neural tissue and cause serious toxic effects (Magos, 1975; Clarkson and Brown, 1977). Elemental mercury is also oxidized to the mercuric ion which is then, like the absorbed metal salt, concentrated in the kidney (Clarkson and Brown, 1977), and within a few hours of a single dose of inorganic mercury over 85% becomes concentrated in the kidney (Rothstein and Hayes, 1960). Elimination by tubular secretion into the urine occurs but

considerable excretion of toxic doses is also achieved by exfoliation of renal tubular cells (Camber, 1962).

The rate of excretion of inorganic mercury is complex. Using whole body counting Rothstein and Hayes (1960) described three phases: the first was responsible for the excretion of 35% of a single dose within a few days, a second phase with a half-time of 30 days accounted for 50%, and a slow third phase had a half-time of 100 days. Organic mercury is excreted mainly by the faecal route (Hammond *et al.*, 1980). Ingestion of inorganic mercury has an irritant, corrosive action to the mucosal surfaces of the mouth and throat which causes a burning sensation and vomiting followed by the passage of bloody diarrhoea. In severe cases death may ensue consequent upon circulatory collapse. Renal failure becomes evident within a few hours. Because of its solubility, mercuric chloride is the most toxic of the inorganic salts with a mean lethal dose in the adult of 0.2-1.0 g. Death is associated with blood mercury concentrations of 75,000 nmol/litre (15,000 µg/litre—Hilmy, Rahim and Abbas, 1976).

The appropriate treatment for acute inorganic mercury poisoning is chelation therapy using dimercaprol (BAL, British Anti-Lewisite: 2,3-dimercapto-1-propanol) followed, if renal failure develops, by dialysis. For dialysis to eliminate mercury effectively it has been shown *in vitro* that prior administration of dimercaprol is necessary (Maher and Schreiner, 1959). However, a number of clinical case reports indicate that in the treatment of acute mercury poisoning by dialysis little mercury is removed even with the use of dimercaprol except in the first few hours after exposure (Leumann and Brandenberger, 1977, Kahn, Denis and Blum, 1977). We would like to confirm this and also report the ineffectiveness of

charcoal haemoperfusion as a means of removing mercury.

Case report

A 29-year-old groundsman ingested an unknown quantity of 'Mersil', a moss killer containing 50% mercurous and 30% mercuric chloride. Within 30 min vomiting and diarrhoea occurred and he subsequently experienced haematemesis, diarrhoea, sore throat, lethargy and postural hypotension. On admission to hospital 5 hr after the poisoning there was poor peripheral perfusion and hypotension, the latter improving after 1 litre of plasma. In view of the strong likelihood of the development of acute renal failure and the possibility of attempting to remove mercury by haemodialysis (HD) or haemoperfusion (HP) he was transferred to the Renal Unit. On arrival he was mildly dehydrated and hypotensive (95/60 mmHg) but there were no other features of note. Twelve hours after exposure to the mercury, serum creatinine and urea were 306 $\mu\text{mol/litre}$ and 9.6 mmol/litre respectively; profound oliguria (<10 ml/24 hr) persisted for 8 days necessitating haemodialysis on 6 occasions.

Dimercaprol, 100 mg intramuscularly 4-hourly, was started 15 hr after ingestion and the first haemodialysis (Gambro Lundia Major, cuprophane membrane thickness 11.5 μm effective area 1.36 m^2) in series with a charcoal column ('Haemocol 300'

haemoperfusion column) was performed for 4 hr commencing 30 hr after ingestion (Fig. 1). The plasma mercury concentration at this time (determined by cold-vapour atomic absorption spectroscopy) was 22,000 nmol/litre (normal: <30 nmol/litre).

Further measurements made at intervals throughout the combined haemodialysis and haemoperfusion showed no significant removal of mercury by either the charcoal column or the dialyser, except at 30.5 hr after ingestion when the values before and after the haemoperfusion column were 24,750 and 19,250 nmol/litre, respectively (Table 1).

Charcoal haemoperfusion was not undertaken further although the patient required intermittent haemodialysis until there was a satisfactory return of renal function. Dimercaprol therapy was continued for 5 days. He is now asymptomatic with no detectable sequelae from his poisoning.

Discussion

This patient exhibited the typical signs and symptoms of acute inorganic mercury toxicity. He presented with evidence of corrosive trauma to the gastrointestinal tract, shock and the rapid development of renal failure requiring treatment by haemodialysis. Despite preliminary administration of dimercaprol and continued chelation therapy in conjunction with dialysis and haemoperfusion it was

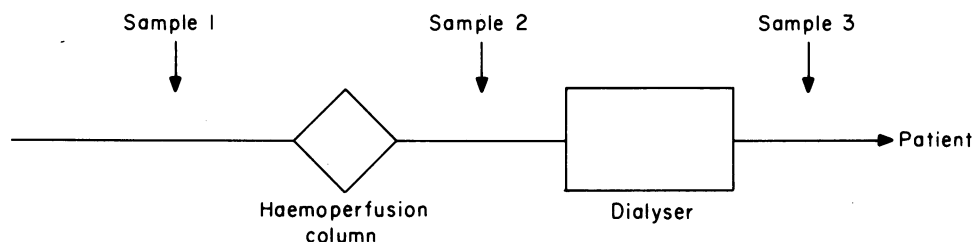


FIG. 1. Diagram of extracorporeal circuit used in combined haemoperfusion and haemodialysis.

TABLE 1. Mercury concentrations during the 7 days after ingestion

| Hours after ingestion | Mercury concentrations (nmol/litre) | | |
|-----------------------|-------------------------------------|--------------|---------------|
| | Pre-haemoperfusion column | Pre-dialyser | Post-dialyser |
| 30.0 | 22,000 | — | — |
| 30.5 | 24,750 | 19,250 | 19,250 |
| 31.5 | 27,500 | 26,000 | 26,000 |
| 33.0 | 23,750 | 22,000 | 21,250 |
| 48.0 | 17,000 | — | — |
| 120.0 | 7,850 | — | — |
| 168.0 | 8,350 | — | — |

1 $\mu\text{g/litre}$ = 5 nmol/litre.

evident that very little mercury was removed across the dialysis membrane or by the charcoal column. Since mercury within the plasma is almost exclusively bound to protein (Clarkson, 1972) this is not unexpected and is in agreement with the observation of Leumann and Brandenberger (1977) and Samuels *et al.* (1982) who treated patients by haemodialysis. The patient treated by Samuels *et al.* (1982) excreted large amounts (11,500 nmol/litre) of mercury into the urine as soon as renal function was restored and although the urine mercury concentrations in our patient were not determined, the fall in plasma mercury (Table 1) would suggest that a similar response occurred.

These observations are in contrast to those recently described by Giunta *et al.* (1983) who successfully treated a 45-year-old woman with dimercaprol (10 mg/kg/day), tiopronin (33 mg/kg/day), haemoperfusion and haemodialysis, achieving elimination of 41% of the ingested mercuric chloride by dialysis. This markedly different experience may be related to several factors, including the use of a dialysis membrane of low solute resistance (polyacrylonitrile). The early administration of dimercaprol—6 hr compared with 15 hr post-ingestion in our patient—may have allowed prompt chelation with subsequent removal by dialysis before significant 'trapping' by protein binding occurred. It is also of interest that Giunta *et al.* (1983) found erythrocyte mercury concentrations to be much higher than those in plasma, which if rapid erythrocyte-plasma equilibration were to occur following removal of mercury from plasma, might account for the unchanged plasma mercury concentrations which we observed before and after the dialyser. Direct comparison, however, between the case of Giunta *et al.* (1983) and the present report is difficult as they have not given details of the plasma mercury concentrations during haemodialysis. Further studies should measure erythrocyte and plasma mercury concentrations both before and after the dialyser, together with dialysate and urine concentrations for the fate of the dimercaprol-mercury chelate to be clarified.

In contrast to the observations on haemodialysis our findings regarding the ineffectiveness of haemoperfusion are in agreement with those of Giunta *et al.*

(1983). Although we found haemodialysis with cuprophan to be ineffective, it is possible that with the use of highly permeable membranes, such as those used in haemofiltration, more efficient removal of the dimercaprol-mercury chelate may be achieved. However, prompt supportive treatment and early administration of chelating agents remain of paramount importance in the management of acute inorganic mercury poisoning.

Acknowledgments

We thank Dr C. Mitchell, Scarborough General Hospital for referring this patient.

The support of the Yorkshire Kidney Research Fund is gratefully acknowledged.

References

- CAMBER, H. (1962) The influence of the size of the dose on the distribution and elimination of organic mercury in the rat. *Industrial Hygiene Journal*, **23**, 304.
- CLARKSON, T.W. (1972) The pharmacology of mercury compounds. *Annual Review of Pharmacology*, **12**, 373.
- CLARKSON, T.W. & BROWN, S.S. (Eds) (1977) *Clinical chemistry and chemical toxicity of metals*, Vol. 1, Elsevier, Amsterdam.
- GIUNTA, F., DI LANDRO, D., CHIARANDA, M., ZANARDI, L., DAL PALU, A., GIRON, G.A., BRESSA, G. & CIMA, L. (1983) Severe acute poisoning from the ingestion of a permanent wave solution of mercuric chloride. *Human Toxicology*, **2**, 243.
- HAMMOND, P.B., BELILES, R.P., DOULL, J., KLASSON, C.D. & AMDUR, M.O. (1980) (Eds) *Toxicology*, 2nd edn, p. 422, MacMillan, New York.
- HILMY, M.C., RAHIM, S.A. & ABBAS, A.H. (1976) Normal and lethal mercury levels in humans. *Toxicology*, **6**, 155.
- KAHN, A., DENIS, R. & BLUM, D. (1977) Accidental ingestion of mercuric sulphate in a four year old child. *Clinical Pediatrics*, **16**, 956.
- LEUMANN, E.A. & BRANDENBERGER, H. (1977) Haemodialysis in a patient with acute mercuric cyanide intoxication. Concentrations of mercury in blood dialysate, urine, vomitus and faeces. *Clinical Toxicology*, **11**, 301.
- MAGOS, L. (1975) Mercury and mercurials. *British Medical Bulletin*, **31**, 241.
- MAHER, J. & SCHREINER, G.E. (1959) The dialysis of mercury and mercury-BAL complex. *Clinical Research*, **7**, 298.
- ROTHSTEIN, A. & HAYES, A.D. (1960) The metabolism of mercury in the rat studied by isotope techniques. *Journal of Pharmacology and Experimental Therapeutics*, **130**, 166.
- SAMUELS, E.R., HEICK, H.M.C., MCLAINE, P.N. & FARANT, J.P. (1982) Case of accidental inorganic mercury poisoning. *Journal of Analytical Toxicology*, **6**, 120.

(Accepted 2 September 1983)