

Subconjunctival haemorrhage: a feature of acute severe asthma

R. Rodriguez-Roisin, A. Torres, A.G.N. Agustí, P. Ussetti and A. Agustí-Vidal

Servei de Pneumologia, Hospital Clinic, Facultat de Medicina, Universitat de Barcelona, Spain

Summary: Bilateral subconjunctival haemorrhage was observed on 5 separate occasions in 4 patients presenting a fulminant form of acute severe asthma. Four of these episodes required ventilatory support. All patients recovered from their asthma attack after treatment with bronchodilators, corticosteroids, and oxygen. The incidence of this previously unreported finding represents 5% of the total number of patients with acute severe asthma mechanically ventilated in our intensive care unit from 1976.

Introduction

The first comprehensive textbook on asthma was written in 1698 by John Floyer (1717). In his original description of a patient with acute severe asthma, Floyer commented 'the face often blacketh by the stagnation of blood in it'. However, intense accessory muscle use and wheezing, tachypnoea, tachycardia and pulsus paradoxus are considered the most familiar clinical signs of this condition (McFadden *et al.*, 1973). Bilateral subconjunctival haemorrhage is an extremely common clinical finding, characteristically present in numerous diseases (Duke-Elder, 1965), including whooping cough (Feigin, 1979). To our knowledge, this feature has not previously been described in patients with acute severe asthma. We wish to draw attention to this finding observed on 5 separate occasions in 4 patients suffering from a fulminant form of acute severe asthma.

Case reports

Case 1

First episode: A 42 year old male was admitted for the first time in a sudden severe attack (grade 4 on Sherwood-Jones scale) of recent onset asthma. The patient showed severe respiratory failure (PaO_2 , 12.4 kPa; $Paco_2$, 7.3 kPa; pH, 7.13; Fio_2 , 0.4) and a widespread bilateral subconjunctival haemorrhage with an associated left orbital haemorrhage (Figure 1). With intensive medical treatment, including adrenaline, corticosteroids, methylxanthines, and oxygen therapy, the patient did well; a few hours later, arterial

blood gases were acceptable. Complete clinical recovery was achieved in a few days.

Second episode: Six months later, he was re-admitted in cardiorespiratory arrest following a fulminant presentation of acute severe asthma (PaO_2 , 19.3 kPa; $Paco_2$, 10 kPa; pH, 7.01; oxygen via ambu-bag).

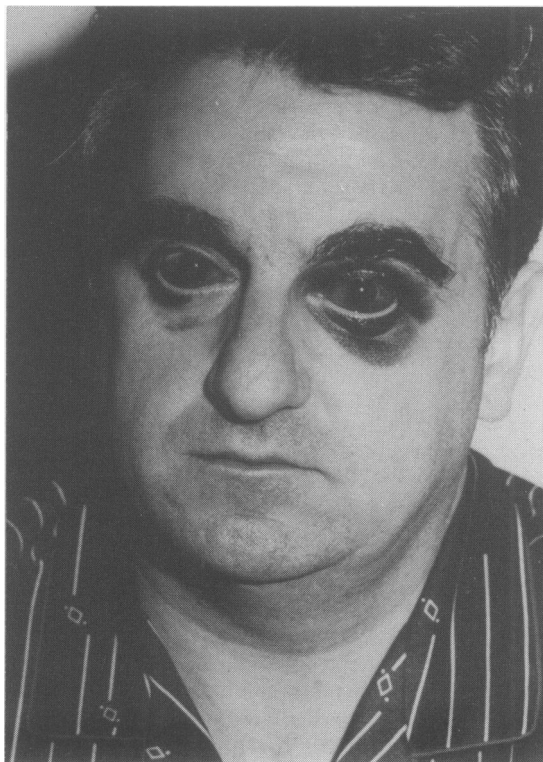


Figure 1 Case 1, first episode.

Correspondence: R. Rodriguez-Roisin, M.D., Servei de Pneumologia, Hospital Clínic i Provincial, Villarroel, 170, 08036 Barcelona, Spain

Accepted: 27 February 1985

Again, bilateral subconjunctival haemorrhage was observed. This second episode took place during an outbreak of asthma in Barcelona (Ussetti *et al.*, 1984). The patient recovered after 8 h of mechanical ventilation together with conventional therapy with intravenous methylxanthines and high doses of corticosteroids.

Case 2

A 49 year old male was hospitalized because of acute exacerbation of a long standing extrinsic asthma which regularly required bronchodilator treatment. Over the first hours of admission, he exhibited increasing agitation and was unable to cooperate, developing a grade 4 of severity (P_{aO_2} , 6.7 kPa; P_{aCO_2} , 8.3 kPa, pH 7.17; F_{iO_2} , 0.28). Spontaneous bilateral subconjunctival haemorrhage was rapidly evident. The patient required mechanical ventilation for 3 d and was discharged 2 weeks later, with mild to moderate hypoxaemia.

Case 3

A 43 year old woman was admitted to the hospital because of the sudden onset of severe asthma while she was cleaning her home. She had previously been admitted on three different occasions in cardiorespiratory arrest over the last 5 y following the development of similar episodes. She was under regular treatment for asthma with bronchodilators and corticosteroids. On admission, the patient exhibited mild-moderate hypoxaemia, severe hypercapnia and acidosis (P_{aO_2} , 8.7 kPa; P_{aCO_2} , 12.8 kPa; pH, 7.04, F_{iO_2} , 0.21) and was physically exhausted. Prominent bilateral subconjunctival haemorrhage was also evident. She was immediately put under mechanical ventilation for the first 24 h with rapid clinical recovery.

Case 4

A 48 year old male was admitted in cardiorespiratory arrest, 30 min after the onset of a sudden attack of asthma (P_{aO_2} , 4 kPa; P_{aCO_2} , 17.3 kPa; pH, 6.77; F_{iO_2} , 0.21). An extensive bilateral subconjunctival haemorrhage was manifest. He suffered from a chronic severe asthma and had had an acute severe attack on four occasions over the last 4 y. He was put on mechanical ventilation and intravenous corticosteroids and methylxanthines were given. Twelve hours later, he was weaned with good clinical recovery in a week and discharged under continuous treatment with oral corticosteroids, salbutamol in aerosol and long-acting xanthines. Arterial blood gases were normal.

On all five occasions, subconjunctival haemorrhage resolved spontaneously over 4–6 weeks. There were

no signs of upper airway obstruction, coagulation disorders or capillary and platelet defects.

Discussion

In respiratory medicine, subconjunctival haemorrhage has been classically related to whooping cough (Duke-Elder, 1965), where the paroxysmal fits of coughing play a key pathogenetic role. On 5 occasions, our 4 patients exhibited bilateral subconjunctival haemorrhage at the peak of their fulminant attacks of severe asthma without any previous episode of intensive coughing. Other causes of subconjunctival haemorrhage (Duke-Elder, 1965), namely trauma, local acute inflammation of the conjunctiva, local or systemic vascular disorders or acute febrile systemic infections, were all ruled out. The most likely pathogenetic mechanism in these asthmatic patients appears to be a sudden and severe congestion of venous blood into the territory of the superior vena cava from raised intra-thoracic airway pressures in an attempt to overcome massive and generalized airway obstruction. It is of interest to note that mechanical ventilation, which can abruptly aggravate the elevated intra-thoracic pressures of these patients, was always initiated after the onset of subconjunctival haemorrhage.

Upper airway obstruction, which could be a contributory factor (Lisboa *et al.*, 1980), was also absent. Moreover, the clinical and functional features of asthma in these patients were not remarkable. Between 1976 and 1981, 26 patients with acute severe asthma needing mechanical support attended our intensive care unit (Picado *et al.*, 1983). Between January 1, 1982 and December 31, 1984, 51 additional cases requiring mechanical ventilation were admitted. Arterial blood gases were available shortly before or after intubation in 51 out of these 77 patients. Mean arterial P_{O_2} (F_{iO_2} range, 0.21–1.0), P_{aCO_2} and pH values in this large group of patients with severe asthma were 9.1 ± 8.4 kPa, 10.8 ± 2.2 kPa, and 7.06 ± 0.12 , respectively, as compared to 9.7 ± 5.8 kPa, 12.1 ± 3.5 kPa, and 6.99 ± 0.14 , respectively, in the present 4 cases. The latter thus show more severe CO_2 retention and respiratory acidosis than those patients without subconjunctival haemorrhage, in keeping with a very severe asthma attack. It can thus be postulated that the presence of subconjunctival haemorrhage may be related to the severity of the asthma. The incidence of subconjunctival haemorrhage among asthma patients in our series is approximately 5%.

The clinical appearance of bilateral subconjunctival haemorrhage is obvious and characteristic and shows a benign course over a few weeks without any associated visual disturbance. It frequently causes

considerable alarm to the patient, although in most of the cases its only importance is related to the associated facial disfigurement. No treatment is required, but in severe cases a local injection of hyaluronidase or urokinase can be necessary (Duke-Elder, 1965). Although uncommon, subconjunctival haemorrhage should be included in the list of clinical signs indicating a fulminant presentation of acute severe asthma. Its presentation in the context of a patient with generalized airway obstruction should alert physicians as a sign of impending severe asthma.

References

- DUKE-ELDER, S. (1965). Anomalies of the circulation (Chap II). In: *System of Ophthalmology*, Vol III, Diseases of the Outer Eye, Part I, Duke-Elder, S. (ed.), p. 9, Henry Kimpton: London.
- FEIGIN, R.D. (1979). Pertussis (whooping cough). In: *Text-book of Pediatrics*, Vaughan III, V.C., McKay, R.J., Behrman, R.E., Nelson, W.E. (ed), p. 766, Saunders, W.B., Philadelphia.
- FLOYER, J. (1717). In *A Treatise of the Asthma* (2nd ed). R. Wilkin: London.
- LISBOA, C., JARDIM, J., ANGUS, E. & MACKLEM, P.T. (1980). Is extrathoracic airway obstruction important in asthma? *American Review of Respiratory Diseases*, **122**, 155.
- Thus, Floyer (1717) may well have been familiar with subconjunctival haemorrhage in acute severe and, of course, untreated asthma attacks during the seventeenth century.

Acknowledgements

We gratefully acknowledge the secretarial work of Herminia Lorente. The work was supported by grant no. 1787/82 from the CAICYT.

- PICADO, C., MONTSERRAT, J.M., ROCA, J., RODRIGUEZ-ROISIN, R., ESTOPÁ, R., XAUBET, A., MARÍN, A. & AGUSTÍ-VIDAL, D. (1983). Mechanical ventilation in severe exacerbation of asthma. Study of 26 cases with six deaths. *European Journal of Respiratory Diseases*, **64**, 102.
- McFADDEN, E.R., KISER, R., & DeGROOT, W. (1973). Relations between clinical and physiologic manifestations. *New England Journal of Medicine*, **288**, 221.
- USSETTI, P., ROCA, J. AGUSTÍ, A.G.N., MONTSERRAT, J.M., RODRIGUEZ-ROISIN, R. & AGUSTÍ-VIDAL, A. (1984). Another asthma outbreak in Barcelona: role of oxides and nitrogen. *Lancet*, **i**, 156.