

Vitamin E – its role in neurological function

D.P.R. Muller

Department of Child Health, Institute of Child Health (University of London), 30 Guilford Street, London WC1N 1EH, UK.

Summary: Studies in patients with abetalipoproteinaemia, other chronic and severe fat malabsorptive states and a selective defect in vitamin E absorption, together with neuropathological studies in the vitamin E deficient human, monkey and rat indicate that vitamin E is important for normal neurological function. Appropriate vitamin E supplementation is, therefore, advisable for all patients with chronic fat malabsorption who have low serum vitamin E concentrations. Serum vitamin E concentrations should also be measured in patients with spinocerebellar disorders, whatever the aetiology.

Introduction

Vitamin E was discovered in 1922 when Evans and Bishop demonstrated the existence of a fat-soluble factor which was necessary for normal reproduction in the rat. Since that time a variety of vitamin E deficient syndromes have been produced experimentally in different animal species (Wasserman & Taylor, 1972), but with the possible exception of haemolytic anaemia and oedema in some premature infants (Oski & Barnes, 1967; Ritchie *et al.*, 1968; Bell & Filer, 1981) the role of vitamin E in human nutrition has been the subject of much dispute. Research into the role of vitamin E in human nutrition has suffered from numerous and exaggerated claims which led Gordon *et al.* (1958) to describe vitamin E as 'a shady lady to be approached gingerly by respectable or discreet investigators in human nutrition'.

Over recent years, however, evidence has accumulated which indicates that the vitamin has an important function in the maintenance of normal neurological structure and function. The evidence comes from four principal sources; from patients with (a) abetalipoproteinaemia, (b) other chronic disorders of fat absorption, (c) an apparent selective defect in vitamin E absorption and (d) from comparative neuropathological studies in man and experimental animals. This evidence will be considered in turn.

Abetalipoproteinaemia

The clinical features of this rare inherited condition were first described by Bassen & Kornzweig in 1950. Ten years later three independent groups, one of which included Professor Wolff, demonstrated the total

absence of beta (low density) lipoprotein from the plasma of affected individuals (Lamy *et al.*, 1960; Mabry *et al.*, 1960; Salt *et al.*, 1960). It was subsequently shown that apoprotein B, the major apoprotein of low density lipoprotein was undetectable (Gotto *et al.*, 1971). As this apoprotein is also an essential component of prebeta (very low density) lipoproteins and chylomicrons, these lipoprotein species are also absent from the plasma of patients with abetalipoproteinaemia.

Amongst the clinical features of abetalipoproteinaemia are an ataxic neuropathy and pigmentary retinopathy which usually develop towards the end of the first decade of life and are 'devastating' (Herbert *et al.*, 1978). In their paper, Wolff and colleagues suggested the possibility 'that these disturbances result from disordered fat absorption and transport' and went on to discuss vitamin A but not vitamin E as a possible candidate (Salt *et al.*, 1960).

It was subsequently shown that although low concentrations of serum vitamin E are found in many disorders of fat malabsorption (Figure 1), the most severe deficiency occurs in abetalipoproteinaemia in which the vitamin is undetectable in plasma when using a colorimetric assay (Kayden *et al.*, 1965; Muller *et al.*, 1974) or high performance liquid chromatography and fluorimetry (D.P.R. Muller, unpublished observation). Thus abetalipoproteinaemia provided an ideal model for studying the effects of vitamin E deficiency in man. For this reason and also because the vitamin E deficient chick was known to develop a cerebellar disorder with ataxia (Pappenheimer & Goettsch, 1931) and neurological lesions had been described in several other animal species (Wasserman & Taylor, 1972), we decided to treat children with abetalipoproteinaemia with very large oral doses of

vitamin E (approximately 100 mg/kg/day tocopheryl acetate – Ephyphal supplied by Hoffmann-La Roche and Co).

Eight patients have now been followed who have been receiving such therapy for periods of 14 to 19 years. Vitamin E status has been assessed by estimating serum concentrations and by *in vitro* tests of red cell haemolysis (autohaemolysis or peroxide haemolysis), as described previously (Muller *et al.*, 1974).

After supplementation with large oral doses of vitamin E, absorption could be demonstrated in all eight patients. Serum concentrations, which were initially undetectable, became measurable although they never reached the normal range because of the absence of low density lipoprotein, a major carrier of the vitamin. *In vitro* haemolysis which was abnormally high in all patients in whom it was measured before treatment, fell to within normal limits in all eight patients after supplementation.

The long-term clinical results of vitamin E therapy in the eight patients have been reported in detail elsewhere (Muller *et al.*, 1977; Muller & Lloyd, 1982; Runge *et al.*, 1985). The five patients who first received vitamin E supplements before the age of 16 months show no clinical abnormalities; motor nerve conduction studies and electrodiagnostic tests of retinal function remain normal. The three other patients (cases 6–8 of the previous reports) already showed some neurological dysfunction before supplementation with vitamin E in later childhood.

Patient 6 had absent tendon reflexes when diagnosed at 18 months of age. He received vitamin E from the age of 3 years. At 11 years he had slight diminution in vibration sense in all limbs and by 18 he had minimal reduction in proprioception in the limbs and a slight reduction of the action potential in the sural and radial nerve but no other neurological or retinal abnormalities have developed. He now works in a car body repair workshop and attends a college of further education.

Patient 7 was the girl initially reported by Salt, Wolff and colleagues in 1960. At diagnosis at the age of 18 months she had absent tendon reflexes; at 5 years she developed a mild pigmentary retinopathy, even though normal serum concentrations of vitamin A had been maintained (Wolff *et al.*, 1964). Since the start of vitamin E supplementation at 8 years, the retinal appearance has remained unchanged. She is now 28 years of age and has no neurological or visual symptoms; retinal function is normal and the only neurological findings are absent tendon reflexes and a slight reduction in the sural nerve action potential. She is a secondary school teacher with a university degree and has recently married.

The eldest patient is now almost 30 years old (Patient 8). He was diagnosed at 7 years and first received vitamin E at the age of 10, by which time he already had marked ataxia, absent tendon reflexes, delayed motor nerve conduction velocities, a pigmentary retinopathy and abnormal retinal function. Since starting oral supplements of vitamin E he has shown definite improvement – see Table I. Within 2 years his gait, motor nerve conduction velocities and the electro-oculogram had improved, although his fundal appearances remained unchanged and his tendon reflexes absent. Since then there has been further improvement in his gait, and his motor nerve conduction velocities and retinal function tests have returned to normal. He is currently employed making furniture in a sheltered workshop and is able to drive a car.

Other investigators have also reported the beneficial effects of large oral doses of vitamin E in this condition (Azizi *et al.*, 1978; Herbert *et al.*, 1978; Miller *et al.*, 1980; Hegele & Angel, 1985).

Other chronic disorders of fat absorption

Patients with other severe and chronic fat malabsorptive states and severe vitamin E deficiency might also be expected to show similar neurological findings to

Table I Long term progress of case 8* diagnosed at the age of 7½ years; started oral vitamin E at age 10½ years

Age at examination (y)	Neurological examination			Electrodiagnostic tests		
	Reflexes	Gait	Fundi	MNC (m/s)	ERG	EOG (%)
7½	reduced	ataxic	pigmentation	—	—	—
10	absent	worse	unchanged	40	abnormal	flat
12	absent	improved	unchanged	50–60	—	170 ^R , 165 ^L
17	absent	improved	unchanged	50–60	normal	250 ^R , 200 ^L
25	absent	improved	unchanged	normal	normal	normal
Normal				> 45		> 180

MNC – motor nerve conduction, ERG – electroretinogram, EOG – electro-oculogram; ^R right eye, ^L left eye.

*Case numbers are the same as in previous reports (Muller *et al.*, 1977; Muller & Lloyd, 1982; Runge *et al.*, 1985).

those described in abetalipoproteinaemia. Individuals with reduced intraluminal bile salt concentrations, such as biliary atresia (see Figure 1), are particularly at risk because bile salt concentrations greater than the critical micellar concentration are necessary for the efficient solubilization and absorption of vitamin E (Harries & Muller, 1971). A number of reports have now appeared relating a neurological syndrome to severe vitamin E deficiency in patients with a variety of chronic fat malabsorptive states. The majority of these reports have been in children with cholestatic liver diseases (Rosenblum *et al.*, 1981; Elias *et al.*, 1981; Guggenheim *et al.*, 1982, 1983; Alvarez *et al.*, 1983; Sokol *et al.*, 1983). The neurological features in abetalipoproteinaemia and in these patients with cholestasis are very similar (Muller *et al.*, 1983) although it initially appeared that retinal changes were less common in the latter group. However, this may prove not to be the case as Alvarez *et al.* (1983) reported that all 13 children with cholestasis had abnormal electroretinograms and 4 of them showed various degrees of retinal degeneration. Most of the patients had normal serum vitamin A concentrations. In general, patients with inadequate intestinal bile salt concentrations are unable to absorb oral supplements of vitamin E and require intramuscular preparations. There have been reports of neurological improvement following such treatment (Guggenheim *et al.*, 1982).

A relationship between fat malabsorption, severe vitamin E deficiency and neurological sequelae has also been reported in adults with multiple ileal resections which result in impaired reabsorption of bile salts (Howard *et al.*, 1982; Harding *et al.*, 1982) and in a small number of patients with cystic fibrosis who had complications (multiple intestinal resections and liver disease) in addition to pancreatic insufficiency (Elias *et al.*, 1981; Bye *et al.*, 1985; Willison *et al.*, 1985). Appropriate supplementation with vitamin E in some of these patients has also resulted in clinical improvement (Elias *et al.*, 1981; Harding *et al.*, 1982; Howard *et al.*, 1982).

Isolated defect of vitamin E absorption

There have recently been some case reports of patients with vitamin E deficiency and a similar neurological syndrome, but without evidence of generalized fat malabsorption (Malloy *et al.*, 1981; Burck *et al.*, 1981; Laplante *et al.*, 1984; Harding *et al.*, 1985). The patient we described (Harding *et al.*, 1985) was a 23 year old woman who developed a progressive neurological disorder comprising ataxia, areflexia and marked loss of proprioception at the age of 14 and was found to have undetectable serum concentrations of vitamin E. She also had increased serum concentrations of cholesterol, triglyceride and low density lipoprotein.

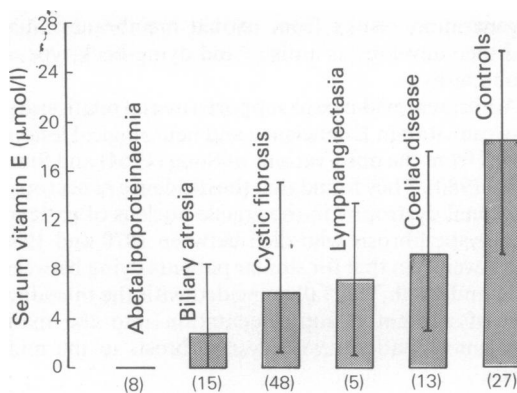


Figure 1 Serum vitamin E concentrations (mean and range) in 5 groups of children with fat malabsorption and controls. Numbers of children in each group in brackets.

Serum concentrations of vitamin E have been maintained within the normal range on modest doses of oral vitamin E (approximately 20 mg/kg/day) and her neurological condition has stabilized since beginning treatment.

These patients are of great potential interest as they may provide important new information regarding the absorption and transport of vitamin E. There have been suggestions from clinical observations that the absorption of vitamin E may differ from that of the other fat soluble vitamins. For example, patients with abetalipoproteinaemia require massive oral doses of vitamin E to maintain an adequate vitamin E status, whereas only conventional doses of vitamins A, D and K are needed (Muller & Lloyd, 1982). Those patients with a selective defect of vitamin E absorption also indicate that there is good reason to include serum vitamin E estimations in the investigation of spinocerebellar syndromes developing in childhood or early adult life, particularly if the clinical features are similar to that found in abetalipoproteinaemia.

Neuropathological studies

Neuropathological studies have been reported in the vitamin E deficient human, rat and monkey. In all three species degeneration of the axons of the posterior columns and a selective loss of large calibre myelinated sensory axons in the spinal cord and peripheral nerves, which is particularly severe in the posterior columns, has been reported (Nelson *et al.*, 1981). As a result of these observations, Nelson *et al.* (1981) suggested that chronic and severe vitamin E deficiency in the rat, monkey, and human leads to degeneration and loss of sensory axons in the posterior columns, sensory roots, and peripheral nerves. He also concluded that this

degeneration results from axonal membrane injury and then develops as a distal and dying-back type of axonopathy.

Additional evidence to support a causal relationship between vitamin E deficiency and neurological lesions comes from the observations of Sung (1964) and Sung *et al.* (1980). They found that the incidence at necropsy of axonal dystrophy in the gracile nucleus of patients with cystic fibrosis who died between 1970 and 1980 was lower than that for similar patients dying between 1952 and 1969. This fall coincided with the introduction of vitamin E supplementation into the management of patients with cystic fibrosis in the mid-1960s.

Mechanism of action

The mode of action of vitamin E in the nervous system has not been established. *In vitro*, and probably *in vivo*, it acts as an antioxidant and it appears that it is the only significant lipid-soluble, chain-breaking type of antioxidant present in human blood (Burton *et al.*, 1983). The neuropathological findings support the concept that it is important for the maintenance of the integrity and stability of biological membranes and one postulate is that it protects the phospholipids of biological membranes from peroxidation. It could also be important in maintaining other molecules in their correct oxidation state.

An intriguing question is why the axonal membrane is particularly susceptible to a deficiency of this vitamin. Cavanagh (1984) has pointed out the logistical problems of neurones with long axons, whereby the cell body has to maintain the very large surface area of the axonal membrane. The axonal membrane may therefore be particularly susceptible to free radical attack if its antioxidant mechanisms are compromised, and the longest fibres would be expected to be the first to suffer. Cavanagh also compared the axonal membrane to that of the red blood cell which is separated from its source of metabolites in time rather than distance and pointed out that the latter is highly dependent on the antioxidant-reduced glutathione.

In order to gain an understanding of the mechanisms involved we (Goss Sampson *et al.*, 1985) and others (Vatassery *et al.*, 1984) have begun to investigate the neurobiology of vitamin E and other antioxidant systems in man and experimental animals.

References

ALVAREZ, F., LANDRIEU, P., LAGET, P., LEMONNIER, F., ODIEVRE, M. & ALAGILLE, D. (1983). Nervous and ocular disorders in children with cholestasis and vitamin A and E deficiencies. *Hepatology*, 3, 410.

The vitamin E concentration varies in different neuroanatomical regions, and in the brain the cerebral cortex has the highest and the cerebellum the lowest concentration of the vitamin.

Treatment with vitamin E

The evidence linking vitamin E deficiency with neurological abnormalities is now sufficiently strong to recommend vitamin E supplementation for all patients with chronic fat malabsorption who have reduced serum concentrations of the vitamin. It is, however, essential that the vitamin should be administered appropriately and this will vary with different patient groups. A recent study (Stead *et al.*, 1985) has shown that in adults with cystic fibrosis (except those with grossly abnormal liver function) an oral dose of 10 mg/kg/day for at least one month followed by a maintenance dose of 200 mg/day (i.e. 1 tablet of tocopheryl acetate-Ephynal) is normally adequate to maintain serum concentrations of vitamin E within the normal range. In patients with abetalipoproteinaemia, however, it is necessary to give very large oral doses of about 100 mg/kg/day if an adequate vitamin E status is to be achieved. In patients with greatly reduced luminal bile salt concentrations, it is likely that oral preparations will not be absorbed and that the vitamin will have to be given intramuscularly. However, before embarking on long-term, regular, intramuscular treatment it is our practice to assess intestinal absorption by giving a large oral load (1–2 g) of tocopheryl acetate and monitoring serum concentrations of the vitamin at regular intervals over the following 24 hours. If there is evidence of absorption, as judged by a significant increase in serum concentrations, large oral doses are given and serum levels carefully monitored to ensure that normal concentrations are reached and maintained. If no absorption of the oral load can be documented intramuscular therapy should be given.

Acknowledgements

I should like to thank Professor O.H. Wolff for his continual support and advice over the years and the various colleagues both within and outside the Institute of Child Health without whom these studies would not have been possible. I am grateful to Hoffmann La Roche and Co. for their financial support and interest.

AZIZI, E., ZAIMAN, J.L., ESCHAR, J. & SZEINBERG, A. (1978). Abetalipoproteinaemia treated with parenteral and oral vitamin A and E and with medium chain triglycerides. *Acta Paediatrica Scandinavica*, 67, 797.

- BASSEN F.A. & KORNZWEIG, A.L. (1950). Malformation of the erythrocytes in a case of atypical retinitis pigmentosa. *Blood*, **5**, 381.
- BELL, E.F. & FILER, L.J. (1981). The role of vitamin E in the nutrition of premature infants. *American Journal of Clinical Nutrition*, **34**, 414.
- BURCK, U., GOEBEL, H.H., KUHLENDHAHL, H.D., MEIER, C. & GOEBEL, K.M. (1981). Neuromyopathy and vitamin E deficiency in man. *Neuropaediatrics*, **12**, 267.
- BURTON, G.W., JOYCE, A. & INGOLD, K.U. (1983). Is vitamin E the only lipid soluble, chain-breaking antioxidant in human blood plasma and erythrocyte membranes. *Archives of Biochemistry and Biophysics*, **221**, 281.
- BYE, A.M.E., MULLER, D.P.R., WILSON, J., WRIGHT, V.M. & MEARNS, M.B. (1985). Symptomatic vitamin E deficiency in cystic fibrosis. *Archives of Disease in Childhood*, **60**, 162.
- CAVANAGH, J.B. (1984). The problems of neurons with long axons. *Lancet*, **i**, 1284.
- ELIAS, E., MULLER, D.P.R. & SCOTT, J. (1981). Association of spinocerebellar disorders with cystic fibrosis or chronic childhood cholestasis and very low serum vitamin E. *Lancet*, **ii**, 1319.
- EVANS, H.M. & BISHOP, K.S. (1922). On the existence of a hitherto unrecognized dietary factor essential for reproduction. *Science (Washington DC)*, **56**, 650.
- GORDON, H.H., NITOWSKY, H.M., TILDON, J.T. & LEVIN, S. (1958). Studies of tocopherol deficiency in infants and children. *Pediatrics*, **21**, 673.
- GOSS SAMPSON, M.A., METCALFE, T.A. & MULLER, D.P.R. (1985). Vitamin E concentrations in neurological tissues from man and the rat. *Journal of Neurochemistry*, **44**, S52.
- GOTTO, A.M., LEVY, R.I., JOHN, K. & FREDRICKSON, D.S. (1971). On the nature of the protein defect in abetalipoproteinaemia. *New England Journal of Medicine*, **284**, 813.
- GUGGENHEIM, M.A., JACKSON, V., LILLY, J. & SILVERMAN, A. (1983). Vitamin E deficiency and neurologic disease in children with cholestasis: a prospective study. *Journal of Pediatrics*, **102**, 577.
- GUGGENHEIM, M.A., RINGEL, S.P., SILVERMAN, A. & GRABERT, B.E. (1982). Progressive neuromuscular disease in children with chronic cholestasis and vitamin E deficiency: diagnosis and treatment with alpha tocopherol. *Journal of Pediatrics*, **100**, 51.
- HARDING, A.E., MATTHEWS, S., JONES, S., ELLIS, C.J.K., BOOTH, I.W. & MULLER, D.P.R. (1985). Spinocerebellar degeneration associated with a selective defect of vitamin E absorption. *New England Journal of Medicine*, **313**, 32.
- HARDING, A.E., MULLER, D.P.R., THOMAS, P.K. & WILLISON, H.J. (1982). Spinocerebellar degeneration secondary to chronic intestinal malabsorption. A vitamin E deficiency syndrome. *Annals of Neurology*, **12**, 419.
- HARRIES, J.T. & MULLER, D.P.R. (1971). Absorption of vitamin E in children with biliary obstruction. *Gut*, **12**, 579.
- HEGELE, R.A. & ANGEL, A. (1985). Arrest of neuropathy and myopathy in abetalipoproteinaemia with high-dose vitamin E therapy. *Canadian Medical Association Journal*, **132**, 41.
- HERBERT, P.N., GOTTO, A.M. & FREDRICKSON, D.S. (1978). Familial lipoprotein deficiency. In *The Metabolic Basis of Inherited Diseases*, Stanbury, J.B., Wyngaarden, J.B. and Fredrickson, D.S. (eds). 4th Edn. p. 544. McGraw-Hill: New York.
- HOWARD, L., OVESEN, L., SATYA-MURTI, S. & CHU, R. (1982). Reversible neurological symptoms caused by vitamin E deficiency in a patient with short bowel syndrome. *American Journal of Clinical Nutrition*, **36**, 1243.
- KAYDEN, H.J., SILBER, R. & KOSSMANN, C.E. (1965). The role of vitamin E deficiency in the abnormal autohemolysis of acanthocytosis. *Transactions of the Association of American Physicians*, **78**, 334.
- LAMY, M.J., FRÉZAL, J., POLONOVSKI, J. & REY, J. (1960). L'absence congénitale de betalipoproteins. *Comptes Rendus des Seances de la Société de Biologie et de ses Filiales (Paris)*, **154**, 1974.
- LAPLANTE, P., VANASSE, M., MICHAUD, J., GEOFFROY, G. & BROCHU, P. (1984). A progressive neurological syndrome associated with an isolated vitamin E deficiency. *Canadian Journal of Neurological Sciences*, **11**, 561.
- MABRY, C.C., DIGEORGE, A.M. & AUERBACH, V.H. (1960). Studies concerning the defect in a patient with acanthocytosis. *Clinical Research*, **8**, 371.
- MALLOY, M.J., KANE, J.P., HARDMAN, D.A., HAMILTON, R.L. & DALAL, K.B. (1981). Normotriglyceridemic abetalipoproteinaemia. Absence of the B-100 apolipoprotein. *Journal of Clinical Investigation*, **67**, 1441.
- MILLER, R.G., DAVIS, C.J.F., ILLINGWORTH, D.R. & BRADLEY, W. (1980). The neuropathy of abetalipoproteinaemia. *Neurology*, **30**, 1286.
- MULLER, D.P.R., HARRIES, J.T. & LLOYD, J.K. (1974). The relative importance of the factors involved in the absorption of the vitamin E in children. *Gut*, **15**, 966.
- MULLER, D.P.R. & LLOYD, J.K. (1982). Effect of large oral doses of vitamin E on the neurological sequelae of patients with abetalipoproteinaemia. *Annals of the New York Academy of Science*, **393**, 133.
- MULLER, D.P.R., LLOYD, J.K. & BIRD, A.C. (1977). The long-term management of abetalipoproteinaemia. Possible role for vitamin E. *Archives of Disease in Childhood*, **52**, 209.
- MULLER, D.P.R., LLOYD, J.K. & WOLFF, O.H. (1983). Vitamin E and neurological function. *Lancet*, **i**, 225.
- NELSON, J.S., FITCH, C.D., FISCHER, V.W., BROUN, G.O. JR. & CHOU, A.C. (1981). Progressive neuropathologic lesions in vitamin E-deficient rhesus monkeys. *Journal of Neuropathology and Experimental Neurology*, **40**, 166.
- OSKI, F.A. & BARNES, L.A. (1967). Vitamin E deficiency, a previously unrecognized cause of hemolytic anemia in the premature infant. *Journal of Pediatrics*, **70**, 211.
- PAPPENHEIMER, A.M. & GOETTSCHE, M. (1931). A cerebellar disorder in chicks, apparently of nutritional origin. *Journal of Experimental Medicine*, **53**, 11.
- RITCHIE, J.H., FISH, M.B., McMASTERS, V. & GROSSMAN, M. (1968). Edema and hemolytic anemia in premature infants: a vitamin E deficiency syndrome. *New England Journal of Medicine*, **279**, 1185.
- ROSENBLUM, J.L., KEATING, J.P., PRENSKY, A.L. & NELSON, J.S. (1981). A progressive neurologic syndrome in children with chronic liver disease. *New England Journal of Medicine*, **304**, 503.
- RUNGE, P., MULLER, D.P.R., McALLISTER, J., CALVER, D., LLOYD, J.K. & TAYLOR, D. (1985). Oral vitamin E supplements can prevent the retinopathy of abetalipoproteinaemia. *British Journal of Ophthalmology*, in press.
- SALT, H.B., WOLFF, O.H., LLOYD, J.K., FOSBROOKE, A.S. CAMERON, A.H. & HUBBLE, D.V. (1960). On having no

- betalipoprotein. A syndrome comprising a-beta-lipoproteinaemia, acanthocytosis and steatorrhoea. *Lancet*, **ii**, 325.
- SOKOL, R.J., BOVE, K.E., HEUBI, J.E. & IANNACCONE, S.T. (1983). Vitamin E deficiency during chronic childhood cholestasis: Presence of sural nerve lesion prior to 2 1/2 years of age. *Journal of Pediatrics*, **103**, 197.
- STEAD, R.J., MULLER, D.P.R., MATTHEWS, S. HODSON, M.E. & BATTEN, J.C. (1985). The effect of abnormal liver function on vitamin E status and supplementation in adults with cystic fibrosis. *Gut*, (in press).
- SUNG, J.H. (1964). Neuroaxonal dystrophy in mucoviscidosis. *Journal of Neuropathology and Experimental Neurology*, **23**, 567.
- SUNG, J.H., PARK, S.H., MASTRI, A.R. & WARWICK, W.J. (1980). Axonal dystrophy in the gracile nucleus in congenital biliary atresia and cystic fibrosis (mucoviscidosis): beneficial effect of vitamin E therapy. *Journal of Neuropathology and Experimental Neurology*, **39**, 584.
- VATASSERY, G.T., ANGERHOFER, C.K. & PETERSON, F.J. (1984). Vitamin E concentrations in the brains and some selected peripheral tissues of selenium-deficient and vitamin E-deficient mice. *Journal of Neurochemistry*, **42**, 554.
- WASSERMAN, R.H. & TAYLOR, A.N. (1972). Metabolic roles of fat-soluble vitamin D, E and K. *Annual Reviews of Biochemistry*, **41**, 179.
- WILLISON, H.J., MULLER, D.P.R., MATTHEWS, S., JONES, S., KRISS, A., STEAD, R.J., HODSON, M.E. & HARDING, A.E. (1985). A study of the relationship between neurological function and serum vitamin E concentrations in patients with cystic fibrosis. *Journal of Neurology, Neurosurgery and Psychiatry*, **48**, 1097.
- WOLFF, O.H., LLOYD, J.K. & TONKS, E.L. (1964). A-beta-lipoproteinaemia with special reference to the visual defect. *Experimental Eye Research*, **3**, 439.