

Intramural pseudodiverticulosis – an unusual cause of benign oesophageal stricture

W.P. Stephens*, A. Mossman, J.F. Ratcliffe¹, D.A. Gould² and S. Oleesky

Manchester Royal Infirmary, Oxford Road, Manchester M13 9WL, ¹Booth Hall Children's Hospital, Manchester M9 2AA and ²North Manchester General Hospital, Manchester M8 6RB, UK.

Summary: Three cases of intramural pseudodiverticulosis of the oesophagus are described together with a review of the relevant literature. This unusual condition, diagnosed by characteristic features on the barium swallow, is associated with a high incidence of benign oesophageal stricture which responds readily to endoscopic dilatation.

Introduction

We report three cases of benign stricture occurring in the upper and middle thirds of the oesophagus in association with widespread intramural pseudodiverticulosis. This unusual disease and its association with stricture formation is either ignored by or very poorly described in standard textbooks. We believe that wider recognition should be accorded to this benign condition which can produce an ominous history of dysphagia in a middle-aged person.

Case reports

Case 1

In 1984, a 63 year old licensee was admitted to hospital with the provisional diagnosis of cancer of the oesophagus. There was a two year history of progressive dysphagia with a sensation of food sticking towards the upper end of his oesophagus. He had been unable to eat solid food for 6 months, but his weight had not fallen. There was no history of corrosive fluid ingestion and he did not suffer from heartburn. He was on oral prednisolone maintenance therapy for asthma and although his alcohol consumption had been high in the past he claimed to have abstained for a number of years. In 1965 a Bilroth 1 partial gastrectomy was performed for gastric ulceration and a subsequent barium meal in 1970 showed a normal oesophagus.

Barium swallow in 1984 showed an irregular stricture at the level of the thoracic inlet which was about

0.5 cm diameter and causing incomplete hold-up. Below the stricture there was extensive intramural pseudodiverticulosis extending down to a small hiatus hernia (Figure 1).

At oesophagoscopy under general anaesthetic the stricture, 23 cm from the teeth, was found to be pliant and dilated easily with bougies (H. Bassett, personal communication). The mucosa at the level of the stricture was raw and histological appearances were those of active non-specific inflammation. The oesophagus below the stricture was macroscopically normal although histological evidence of inflammation was found. The biopsies did not contain fungal elements. The orifices of the pseudodiverticula were not visible.

There has been no recurrence of dysphagia during a 6 month follow-up period.

Case 2

In 1972, a 65 year old woman was investigated for intermittent dysphagia by barium swallow and meal. A hiatus hernia associated with gastro-oesophageal reflux was found but there was no suggestion of stricture formation. Extrinsic indentation of the upper oesophagus by a thyroid nodule was thought to be the cause of her symptoms and a benign swelling of the thyroid was removed surgically. In 1967, coeliac disease had been diagnosed and during the course of these investigations a barium meal had again shown a hiatus hernia with no other oesophageal abnormality.

In 1980, at the age of 72, she presented as an emergency with acute dysphagia suggesting bolus obstruction of the oesophagus. An emergency barium swallow confirmed a foreign body stuck in a narrowed oesophagus at the level of the aortic arch. A small

*Correspondence and present address: W.P. Stephens, M.D., M.R.C.P., Department of Medicine, Park Hospital, Moorside Road, Davyhulme, Manchester M31 3SL, UK.
Accepted: 30 August 1985

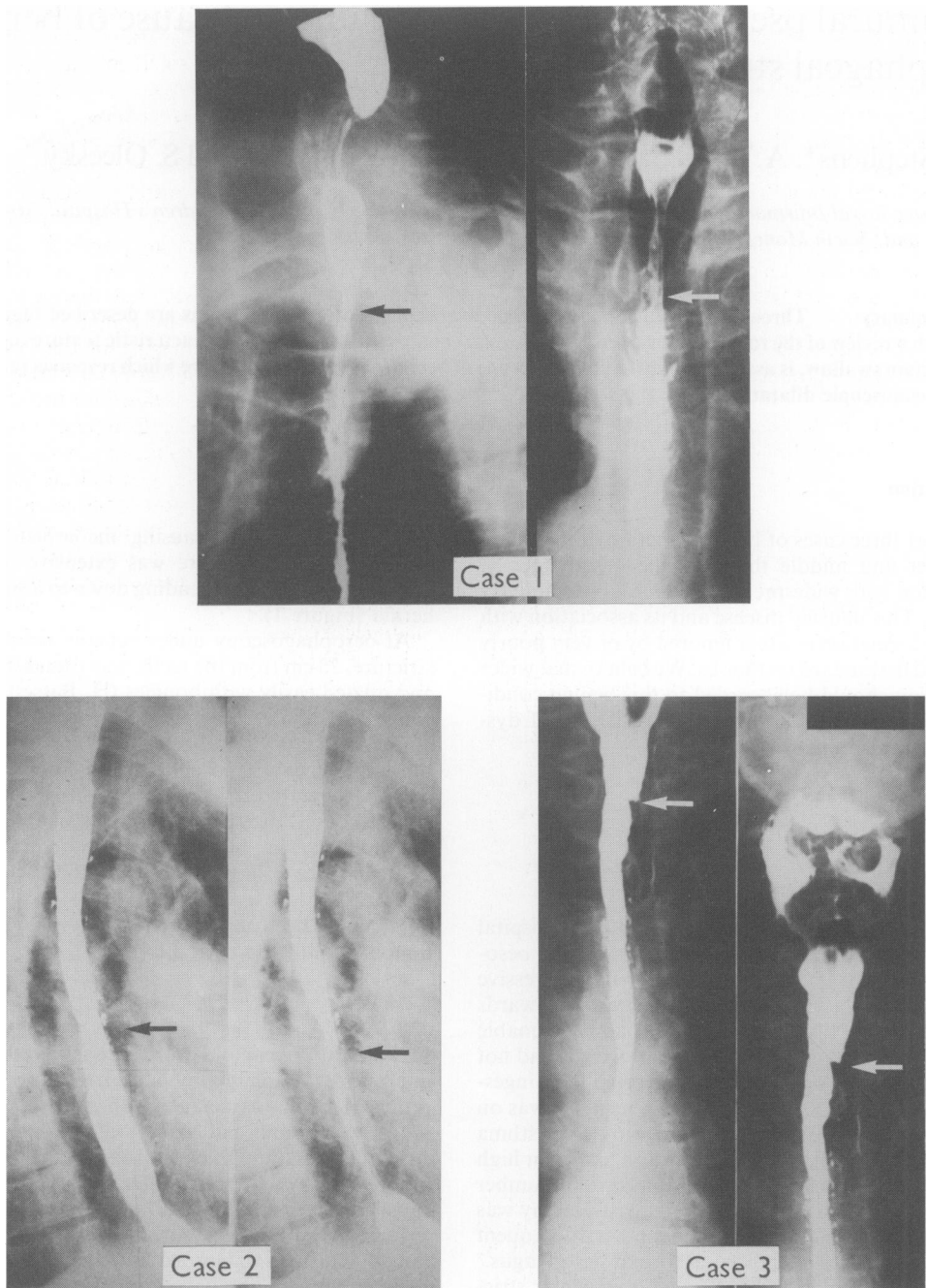


Figure 1 Barium swallow appearances in three cases of intramural pseudodiverticulosis of the oesophagus. The sites of stricture formation are marked ←.

amount of contrast passed the blockage and showed multiple tiny intramural collections of barium. She was treated conservatively, the obstruction resolved spontaneously and a formal barium swallow 3 days later confirmed a stricture of the middle third of the oesophagus associated with widespread intramural pseudodiverticulosis (Figure 1).

The X-rays from 1972 were still available and retrospective review of these films showed the presence of intramural pseudodiverticulosis at that time.

At oesophagoscopy, the stricture was encountered 25 cm from the teeth, it measured about 1 cm diameter and was dilated with bougies. The orifices of the pseudodiverticula could not be seen. There was oesophagitis above the hiatus hernia. Biopsies were not taken for histological examination nor for fungal culture.

Since 1980, she has required periodic oesophageal dilatation to relieve her dysphagia.

Case 3

In 1983, a 58 year old publican was admitted as an emergency complaining that a lump of food had been stuck in his throat for 26 hours. Further questioning revealed that he had suffered from intermittent dysphagia for solid food for several years. There had previously been episodes of complete oesophageal blockage, but these had always resolved spontaneously within hours. He had diabetes mellitus and was managed on oral hypoglycaemic agents.

He was treated conservatively and 2 days later his dysphagia cleared abruptly. A barium swallow examination showed a long narrow stricture in the mid-oesophagus with intramural pseudodiverticulosis affecting the same area. There was an intraluminal polyp at the distal limit of the pseudodiverticulosis. A hiatus hernia was not present (Figure 1).

At oesophagoscopy, the polyp was removed and histological examination showed no evidence of malignancy. Dilatation was not required in this case and during the last year he has not been troubled significantly by his dysphagia.

Discussion

These are the only cases of intramural pseudodiverticulosis of the oesophagus (IPO) to be reported in Britain since the condition was first described by Mendl *et al.* in 1960. Nevertheless, the frequency of recent reports emanating from the United States suggests that IPO is more common than was once suspected (Santos *et al.*, 1984). Analysis of 66 published case reports shows 10 patients in the age group 1 to 15 years, 18 aged 15 to 50 years, and the remainder as old as 86 years. The sex ratio is 1.4/1 (male to

female). Table I shows further clinical details.

The most frequent presenting symptom is dysphagia. The diagnosis is made upon the X-ray appearance of multiple small intramural outpouchings of the oesophagus. These are typically 1–3 mm in diameter and described as 'collar-stud' or 'flask-like' when filled with barium. The pseudodiverticula may be branched and bridging between adjacent outpouchings is frequently seen. Autopsy studies show that these are not true diverticula, but are the dilated ducts of intramural mucus-secreting glands (Fromkes *et al.*, 1977). The exact reason for the duct dilatation is unknown, but it is postulated that the disease is primarily inflammatory in origin – desquamated cellular debris causes plugging of the mucosal and submucosal glands, the ducts dilate, release the inspissated plug and are then outlined on barium swallow (Bruhlmann *et al.*, 1981). Computed tomographic scan appearances are consistent with submucosal inflammation and fibrosis; generalized thickening of the oesophageal wall with loss of the normal soft tissue planes is seen together with multiple small collections of intramural gas (Pearlberg *et al.*, 1983).

The distribution of pseudodiverticula coincides with the anatomical distribution of mucosal and submucosal glands (Table I). A congenital abnormality of the mucus glands has been suggested (Bruhlmann *et al.*, 1981), but cases 1 and 2 are the first in which a normal oesophageal mucosa has been documented prior to the appearance of IPO. Studies of

Table I The essential clinical features of 66 previously published cases of intramural pseudodiverticulosis of the oesophagus

Dysphagia on presentation:	53	(80%)
Constant	31	(47%)
Intermittent	16	(24%)
Progressive	6	(9%)
Bolus obstruction	18	(27%)
Stricture on barium meal:	60	(90%)
Upper third	29	(48% of those with strictures)
Middle third	15	(25%)
Lower third	15	(25%)
Entire oesophagus	1	
Distribution of diverticula:		
Upper third	34	(52%)
Middle third	48	(73%)
Lower third	34	(52%)
Entire oesophagus	24	(36%)
Associated conditions:		
Diabetes mellitus	13	(20%)
Gastro-oesophageal reflux	13	(20%)
Alcohol abuse	10	(15%)

oesophageal motility have not shown a consistent abnormality in this condition and increased intraluminal pressure does not seem to be implicated in the aetiology (Santos *et al.*, 1984). It is difficult to make the diagnosis at endoscopy; in only 20% of cases are the orifices of the pseudodiverticula visible (Muhletaler *et al.*, 1980).

The strictures are typically high in the oesophagus in contrast to the site of stricture formation in benign peptic oesophagitis. Radiologically they appear relatively mild in comparison to the degree of dysphagia and there is a tendency for the strictures to occur where the density of pseudodiverticula is greatest. There is no characteristic histological appearance of the mucosa either at the site of the stricture or within the pseudodiverticula (Cantor & Riley, 1982). It has been suggested that the changes of IPO are secondary to stricture formation (Muhletaler *et al.*, 1980). However, this would not explain those cases in which the pseudodiverticula are found distal to a stricture and in case 1 and case 2 we found no evidence of a stricture predating the appearance of IPO. It remains speculative whether an inflammatory reaction around the diverticula induces stricture formation or whether a primary inflammatory process of the oesophagus causes both the stricture and the appearances of IPO.

There is debate regarding the relationship of IPO to oesophageal candidiasis. A third of patients are found

to have *Candida albicans* on mucosal biopsy or culture from oesophageal washings (Bruhlmann *et al.*, 1981) and it is at present speculative whether this represents an innocent commensal organism, fungal colonisation of the pseudodiverticula or the fundamental cause of the inflammatory process with aggregates of hyphae blocking the glandular ducts. *C. albicans* can be detected in the oesophagus of up to 30% of healthy individuals (Santos *et al.*, 1984). Our patients had no evidence of fungal involvement of the oesophagus.

The strictures respond readily to operative dilatation and long remissions in the dysphagia are the rule. No treatment is required for the 10% of cases with uncomplicated IPO; follow-up radiological studies suggest that the oesophageal appearances change very little over the years (Peters *et al.*, 1982). There seems to be very little evidence that antifungal therapy has a beneficial action in the absence of clear evidence of oesophageal moniliasis (Bruhlmann *et al.*, 1981).

Awareness of this unusual benign oesophageal condition and its relationship to stricture formation can relieve the anxiety of both the patient suffering from dysphagia and his doctor.

Acknowledgements

We wish to thank Dr B. Longstaffe (Bristol) and Professor A.G. Johnson (Sheffield) for permission to report Case 2.

References

- BRUHLMANN, W.F., ZOLLIKOFER, C.L., MARANTA, E., HEFTI, M.L., BIVETT, J., GIGER, M., WELLAUER, J. & BLUM, L. (1981). Intramural pseudodiverticulosis of the esophagus. *Gastrointestinal Radiology*, **6**, 199.
- CANTOR, D.S. & RILEY, T.L. (1982). Intramural pseudodiverticulosis of the esophagus. *American Journal of Gastroenterology*, **77**, 454.
- FROMKES, J., THOMAS, F.B., MEKHJIAN, H., CALDWELL, J.H. & JOHNSON, J.C. (1977). Esophageal intramural pseudodiverticulosis. *American Journal of Digestive Diseases*, **22**, 690.
- MENDL, K., MCKAY, J.M. & TANNER, C.H. (1980). Intramural diverticulosis of the oesophagus and Rokitansky-Aschoff sinuses in the gall bladder. *British Journal of Radiology*, **33**, 496.
- MUHLETALER, C.A., LAMS, P.M. & JOHNSON, A.C. (1980). Occurrence of oesophageal intramural pseudodiverticulosis in patients with pre-existing benign oesophageal stricture. *British Journal of Radiology*, **53**, 299.
- PEARLBERG, J.L., SANDLER, M.A. & MADRAZO, B.L. (1983). Computed tomographic features of esophageal intramural pseudodiverticulosis. *Radiology*, **147**, 189.
- PETERS, M.E., CRUMMY, A.B., WOJTOWYCZ, M.M. & TOUSSAINT, J.B. (1982). Intramural esophageal pseudodiverticulosis. *Pediatric Radiology*, **12**, 262.
- SANTOS, G.H., BAKER, S.R. & FRATER, R.W.M. (1984). Intramural pseudodiverticulosis of the esophagus. *Journal of Thoracic and Cardiovascular Surgery*, **87**, 120.