

# Generalized muscular pseudohypertrophy in cysticercosis

J.S. Chopra, Nitya Nand, K. Jain, R. Mittal and L. Abrol.

Postgraduate Department of Medicine and Pathology, Medical College and Hospital, Rohtak-124001, India.

**Summary:** A 32 year old male Hindu, presenting with generalized muscular hypertrophy (Veritable Hercules), together with subcutaneous nodules and epilepsy, due to cysticercosis is described.

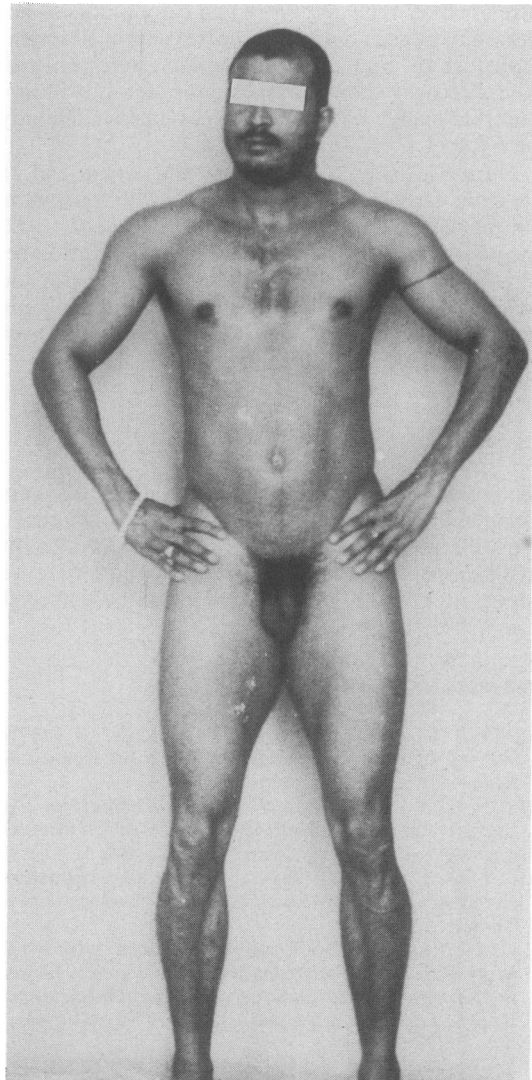
## Introduction

Cysticercosis usually presents with epilepsy (MacArthur, 1934) or intermittent obstructive hydrocephalus (Dixon & Lipscomb, 1961). Involvement of skeletal and cardiac muscle in cysticercosis usually remains silent. Although myalgic, nodular and pseudohypertrophic forms have been described, with pseudohypertrophy probably the rarest (Serre *et al.*, 1970), painless, symmetrical massive enlargement of muscles superficially resembling primary muscle disease is not documented in the standard text books of neurology. We report here one such patient, who, in addition to generalized muscular pseudohypertrophy, had palpable subcutaneous nodules. The diagnosis of cysticercosis was suspected clinically and it was proved histopathologically.

## Case report

A 32 year old vegetarian Hindu farmer was admitted with the complaints of generalized increase in muscle bulk and weakness of 8 months' duration. These complaints were insidious in onset and gradual in progression. The enlargement of thigh muscles was so much that the patient was unable to walk comfortably. There was no history of visual or behavioural disturbances, epileptic fits, headache, vomiting, fever or myotonia. There was no evidence of any hormonal preparation intake.

Physical examination revealed that the patient had the typical look of a muscleman (Veritable Hercules – Figure 1). There was generalized symmetrical increase in muscle bulk involving neck, trunk and extremities. His height was 172 cm and weight 73 kg. The neck measured 20 cm, biceps 29.5 cm, calf muscles 35.5 cm and thighs 59.5 cm. The muscle power was grade IV (MRC scale), being disproportionate to the bulk.



**Figure 1** Showing generalized muscular hypertrophy especially of thigh, calf and neck muscles.

There was no muscular tenderness, myotonia or muscle oedema. The muscles felt tense on palpation. The reflexes were retained and the cranial nerves including fundus and higher functions were normal.

Examination of the scalp revealed multiple subcutaneous nodules varying in size (0.5–1 cm diameter), freely mobile, non-tender and firm in consistency. The extremities, tongue and conjunctiva did not show any nodularity.

Investigations revealed haemoglobin 9.5 g/dl and white blood cells  $10 \times 10^9/l$ , with 62% eosinophils. Erythrocyte sedimentation rate was 25 mm in the first hour. Urinalysis, repeated stool examination and blood biochemistry did not reveal any abnormality. X-rays of chest, skull, abdomen and extremities did not show any calcification. Electrocardiogram, electroencephalogram and electromyogram were normal. Nodule biopsy showed cysticercosis, and blind biopsies from hamstring and quadriceps muscles similarly were full of *Cysticercus cellulosae*.

During his stay in the hospital the patient had an epileptic fit which was controlled with phenytoin 100 mg twice a day. As suggested by Rao *et al.* (1972) the patient was given a course of 40 mg prednisolone/day for 6 weeks. Following this, his muscle size and weight did not change but the muscles became soft and he was able to walk. The muscle power also improved to some extent.

### Discussion

Although muscular involvement in cysticercosis is not uncommon, symmetrical generalized muscular pseudohypertrophy is rare and may present difficulty in diagnosis. Jolly & Pallis (1971) reviewed seven such previously reported cases and presented two more all

from India. since then, two other patients from this country (Rao *et al.*, 1972; Sawhney *et al.*, 1976) and one from Brazil (Armburst-Figueiredo *et al.*, 1970) have been reported. The scanty literature on muscle cysticercosis provides limited information and the pathogenesis of the condition is rather uncertain. It is not likely to be due to the presence of cysts alone. MacArthur (1934) postulated that the dead larvae acted as a foreign irritant and the cause of local inflammatory changes. Further, increase in the size of cyst wall was the result of reaction to the disintegration of the larvae. The exact cause of these changes is still a matter of speculation. From the nature of exudates and partial response to steroids one can assume that the condition, at least in part, may be allergic in character (Rao *et al.*, 1972). Sawhney *et al.* (1976) have, however, suggested that it may be due to expanding cysts which might compromise the intramuscular blood circulation and this in turn might produce changes in the muscle fibres.

Muscle enlargement, therefore, implies that the previous infestation must have been considerable. This is clearly borne out by the fact that this patient had not only muscular enlargement but also palpable multiple subcutaneous scalp nodules and epilepsy.

As in the present case, individual subcutaneous nodules are often readily palpable but individual intramuscular nodules are difficult or even impossible to palpate. This is particularly so if the cysts are deeply embedded in the large muscle masses of thighs and calves. The contrast between appearance of biopsy packed with parasites and tense but smooth muscle mass was probably due to the multiplicity of cysts in close proximity to one another which made it tense and hard and thereby making it impossible for any intramuscular nodule to be palpable.

### References

- ARMBURST-FIGUEIREDO, J., SPECIALLI, J.G. & LISON, M.P. (1970). Forma miopatica cysticercose. *Arquivos De Neuropsiquiatria (Sao Paulo)*, **28**, 385.
- DIXON, H.B.F. & LIPSCOMB, F.M. (1961). Cysticercosis: An analysis and follow up of 450 cases. *Medical Research Council, Special Report Series (London)*, **299**, 1.
- JOLLY, S.S. & PALLIS, C. (1971). Muscular pseudohypertrophy due to cysticercosis. *Journal of the Neurological Sciences*, **12**, 155.
- MACARTHUR, W.P. (1934). Cysticercosis as seen in the British Army with special reference to production of epilepsy. *Transactions of the Royal Society of Tropical Medicine and Hygiene (London)*, **27**, 345.
- RAO, C.M., SATTAR, S.A., GOPAL, P.S., MOHAN-REDDY, C.C. & SADASIVUDU, B. (1972). Cysticercosis resembling myopathy. A report of a case. *Indian Journal of Medical Sciences*, **26**, 841.
- SAWHNEY, B.B., CHOPRA, J.S., BANERJI, A.K. & WAHI, P.L. (1976). Pseudohypertrophic myopathy in cysticercosis. *Neurology*, **26**, 270.
- SERRE, H., SIMON, L. & LAMBOLEY, C. (1970). Les manifestations musculaires – la cysticercose humaine. *Rhumatologie*, **22**, 357.