severe and some slighter fits every twenty-four hours till the operation. I need only describe one, for Dr. John Smith, with whom I saw the case, the house physician, and clinical assistants at Guy's Hospital, and I myself agreed that the fits were all similar, except that they differed in degree. The patient knew when a fit was coming on by a sensation of numbness and tingling in the right fingers and thumb. Then in less than a minute there were a series of rapidly-repeated extensions of the right wrist and metacarpo-phalangeal joints. At the same time there were a series of rapid abductions of the hand to the ulnar side. The next stage consisted of rapid flexions of the phalangeal and metacarpo-phalangeal joints, so that the fingers were dug into the palms of the hands, causing considerable pain. Then followed a series of rapid flexions and extensions of the elbow, after which the fit was over. It usually lasted, exclusive of the stage of numbness, about ninety seconds. The slighter fits were much shorter, and consisted only of a little movement of the fingers. In a few, after the flexions of the elbow, the shoulder was for a few seconds rapidly adducted and abducted, and the head was jerked to the left. It is said that she was unconscious after the first fit, but those observed by us were never followed by unconsciousness.

In between the fits the right upper extremity was in all movements weaker than the left. The hand lay pronated, and the supinators were unable to move it. On the right side she could only move the dynamometer to 50, but on the left to 90. There was no paresis of the muscles of the head, face, eyes, tongue, trunk, or lower extremities. Both knee-jerks and both plantar reflexes were present, but were better marked on the right than the left. There was no clonus of either knee or ankle. Both elbow-jerks were absent. Both wrist-jerks were present, that on the right being exaggerated.

She was an intelligent woman. Sensibility to touch, pain, and temperature was quite normal over the whole body. In the right hand she could easily tell the addition of 1 oz. to 20 oz.

The fields of vision were normal; she recognised colour and form correctly. The pupils were equal, and reacted well. There was no ocular paralysis. There was early optic neuritis in the right eye, the left was normal. Smell, taste, and hearing were all normal. The diagnosis was made of a growth on the cortex of the left cerebrum implicating the arm area, and secondary to the disease of the breast. The fits were so frequent that the patient desired an operation, although she was told that it would not prevent other secondary deposits.

On January 6th Mr. Arbuthnot Lane exposed the middle of the fissure of Rolando. Over an area which as nearly as could be judged corresponded with the part of the arm area in the ascending parietal convolution, the cortex at one part was of a rather more brownish-green tint than was normal. This part was cut away to such a depth that white matter was exposed. When frozen and cut, it clearly consisted of growth. At the operation it was not definitely marked off from healthy grey matter, which it resembled so closely that several considered it to be healthy.

January 7th. There is paralysis of the whole of the right face, except the orbicularis palpebrarum and the occipito-frontalis. No ocular symptoms. The tongue lies on the floor of the mouth quite motionless. The right upper and the right lower extremities are completely paralysed, but no sensory defect is noticeable. She is completely aphasic.

January 8th. The condition is the same, except that the right pupil is larger than the left, and last night it was observed that the right side of the face was sweating, although the left was quite dry.

January 11th. Her condition is unchanged, except that the tongue can be protruded a little; the facial paralysis is less marked and the pupils are equal.

January 14th. The movements of the facial and lingual muscles are still improving. She can slightly move the right toes, and can detect 1 oz. added to 20 oz. in the right palm.

January 19th. She has still further regained the power of movements of the face and tongue; the movement of the right foot has ceased to improve. She can say five or six words distinctly.

January 22nd. She can still feel the slightest touch of the skin in any part of her body, including the right upper extremity.

The power of localisation of sensations was tested in the following way: She was blindfolded. Some spot on the right upper extremity was touched with a pin point as lightly as possible, and she was asked to touch with her left fingers the spot touched. The spot touched and the spot she indicated as being touched were both marked. This was done on many parts of the right upper extremity, and similar experiments were carried out on the right upper extremities of two healthy women and one healthy man. A comparison of the results showed that the patient and the three healthy individuals were in the majority of instances quite accurate; that sometimes all four were inaccurate, and then the distance between the spot touched and that to which the touch was referred varied from ½ inch to 2½ inches. The patient was a little less accurate than the healthy persons, but the difference was not great. In all cases the subject was more likely to be accurate if the pressure of the pin was firm, and if there was no delay between the attempt to localise and the touch. All four subjects were more correct below the elbow than above it. It was impossible to test the patient's left upper extremity owing to the paralysis of the right. A few experiments in which the head of the pin was used instead of the point gave the same result. These experiments were repeated on other days than this, but always with the same result.

February 7th. Optic neuritis still present. Up to this time her condition since the last note has not changed, but from this date she became drowsy, her pulse was very slow, she had cerebral vomiting, and she sank and died on February 13th, it being clear that there were other deposits in the brain.

She never had a fit after the operation, nor had she any numbness. Her mental condition was quite good till February 7th. She never had any anæsthesia; pain was localised as such; and her temperature sense was normal. The temperature was usually different in the two axillæ.

Post-mortem Appearance of the Brain.—The gap left by the piece of grey matter removed was oval, and occupied the position shown in the figure. It was limited in front by the fissure of Rolando, behind it extended slightly on to the supramarginal convolution, its long axis just crossing the lower interparietal sulcus. The floor of the area removed exposed white matter, soft and discoloured here and there with shreddy filaments of growth. There were secondary growths, all of which had evidently recently grown very rapidly in the upper part of the left ascending

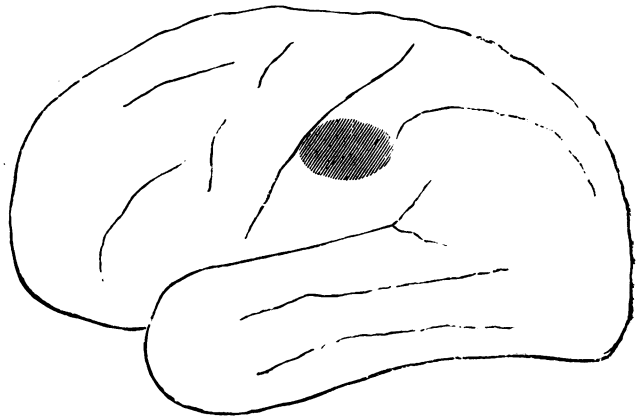

The shaded part indicates the area excised.

parietal, in the posterior part of the third left frontal, in the upper part of the left angular and in the middle of the right ascending frontal convolutions. The presence of these makes it unprofitable to study the aphasia, the paralysis of the face, arm, and tongue, or to seek for changes in the spinal cord.

REFERENCES.

[1] Ziehen: *Introduction to Physiological Psychology*, English Translation, p. 133. [2] Diller and Buchanan: *American Journal of Medical Sciences*, July, 1893. [3] The Condition of the Bones of the Skull and Dura Mater in Cases of Tumour of the Brain, *Guy's Hospital Reports*, vol. xliii. [4] Starr: Cortical Lesions of the Brain, *American Journal of Medical Sciences*, April, 1884. Mills: Cerebral Localisation in its Practical Relations, *Brain*, Part 47, p. 383. Ferrier: Croonian Lectures, BRITISH MEDICAL JOURNAL, vol. ii, 1890, p. 72. [5] A Case illustrating Kinæsthesia, *Brain*, Parts 59 and 60. [6] *Phil. Trans.*, 1890. [7] BRITISH MEDICAL JOURNAL, May 27th, 1893. [8] *Journal of Physiology*, vols. xi and xii. [9] *International Clinics*, Series iii, vol. i. [10] *Op. cit.* [11] *International Clinics*, *Op. cit.* [12] *Journal of Nervous and Mental Disease*, 1888, p. 672. [13] *Journal of Physiology*, vol. xii.

THE NEUROGLIA ELEMENTS IN THE HUMAN BRAIN.

BY W. LLOYD ANDRIEZEN, M.B.LOND.,

From the Pathological Laboratories of University College, London, and the West Riding Asylum, Wakefield.

THE present preliminary account deals only with the neuroglia elements in the human brain. The research was begun at University College in May, 1892, and continued at the laboratory of the West Riding Asylum since January last. The whole material examined consists of twenty-seven human brains, and the regions studied were the ascending frontal, the occipital (or calcarine), and the hippocampal regions of the brain.

Among animals studied were fœtal, young and adult cats, adult rats, rabbits, cats, and the ox; the results obtained from these confirm in the main features those obtained in the human brain. While in the human brain the nerve elements have been largely and extensively studied both in health and in disease, the neuroglia elements have been comparatively neglected, partly owing to a widely-spread belief in a mere passive *rôle* they were supposed to play, and partly owing to inadequacy of the methods used, for while the general and special methods with the anilines, picro-carmine, osmic acid, hæmatoxylin, and gold chloride—to mention only the chief—have shown much of the nerve elements, a method has been wanting which should not only exhibit the former elements down to their finest ramifications and actual endings, but should do the same for the neuroglia elements with faithfulness and precision, so as also to demonstrate the relations of these two elements to another and to the ground substance.

This is now possible by Golgi's method of staining with silver chromate, which since 1886 marked an epoch in neurology of which the publication of his great work *Sulla fina Anatomia dela Sistema Nervosa* was the beginning of a revolution

of our old ideas on the mechanism and mode of action of the nervous system which is still in progress. With young and embryonic nervous systems that method gives the best results; with slight modifications it has given in my hands results of much success for the adult brains of animals, and by a rather more modified process, similar, and in some respects better, results have been obtained for the human brain. The results obtained in the present research were due to such a method, the details of which will be published later.

From each of the specimens of human brain used, forty to sixty sections were selected and mounted for study; thus, on the whole, rather more than a thousand sections were used, while, of these, only those on which the staining was most precise, uniform, and perfect were utilised to elucidate the details of the neuroglia elements as below. Such an investigation soon made it evident that the neuroglia elements present possess such marked differential characters among themselves that they obviously form two great morphological groups, which, from their most striking appearance, may be justly called (*a*) the neuroglia fibre cell, (*b*) the protoplasmic neuroglia cell. The classification here proposed, and, as far as I am aware, for the first time, while *primâ facie* morphological, is also, as will be shown, a physiological one, while independent studies on their etiology and pathology all point in the same direction, as will be evident shortly. The illustrations accompanying were drawn by the aid of Schroeder's camera lucida.

A. THE NEUROGLIA FIBRE CELL.

There are two species of this cell (see Figs. 1 and 2), and

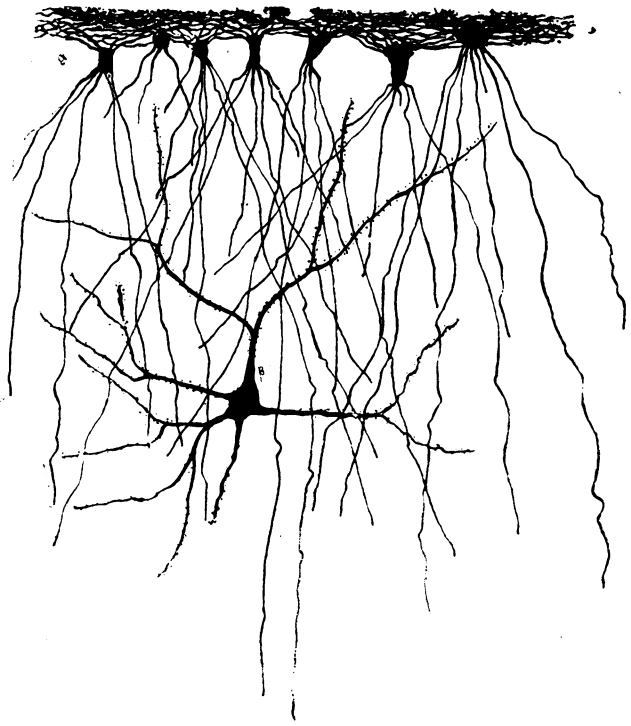

Fig. 1.—α. Seven caudate neuroglia fibre cells of the first layer of the human cortex, sending processes some of which reach one half way down the depth of the cortex nearly to the midst of the third layer. β. One small pyramidal nerve cell of the third layer (upper part of).

their topographical distribution is correspondingly different. One species (α) is situated in the first layer of the cortex, and sends its streaming fibres down into the third layer; these are the caudate cells. (Fig. 1). The other (β) is situated in the medullary substance or white matter, and has radiating fibres passing in all directions (stellate fibre cells, Fig. 2).

1. *The Caudate Fibre Cells.*—These form a distinct feature in the first layer of the grey matter in specimens of human brain. The cell bodies are imbedded in the grey substance, and are the most superficial in position of all cell elements—whether nerve or glia—in the cortex. The cell bodies have a rounded apex pointing downwards, and giving rise to a tail-like tuft of smooth fibres streaming into the deeper layers of the cortex. The wider and flatter base is directed towards the surface, and gives origin to an entirely different system of radiating tangential fibres. (Fig. 1.) The individual fibres are extremely long, smooth contoured, and of uniform calibre

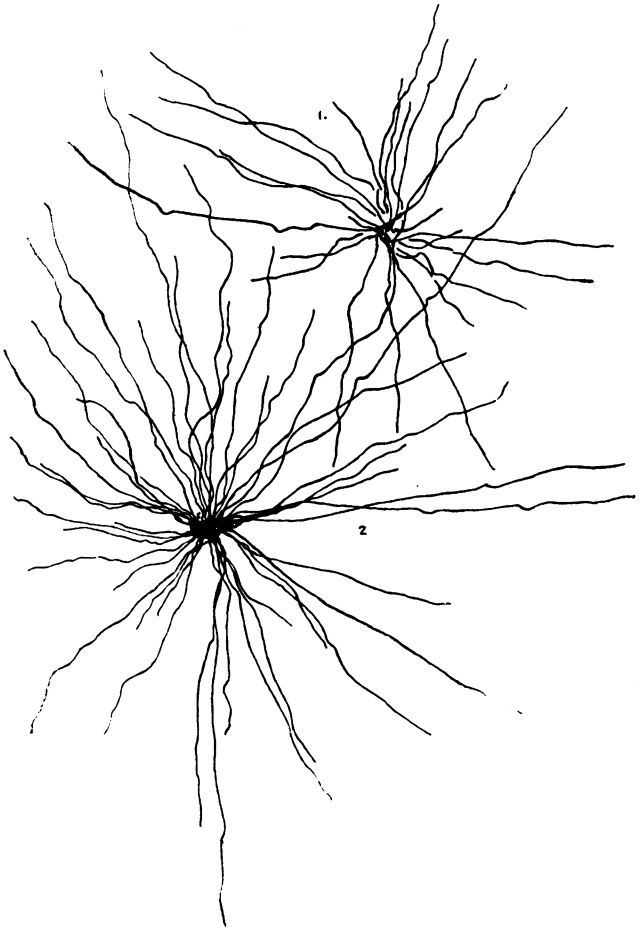

Fig. 2.—Two neuroglia fibre cells of the medullary substance or white matter of the human brain (Schroeder's camera lucida drawings).

throughout, of remarkably uniform thickness one with another, unbranched, slightly wavy in their course, which is, on the whole, almost rectilinear, and exhibiting here and there small sharp curves and small angular bends, while sharp transverse fractures are not infrequent. They form a fine fretwork of cortical fibres. The caudate cells thus have two if not three systems of fibres: (1) the descending apical (tuft of) fibres which pass deeply into the grey matter; (2) the superficial tangential system of fibres forming a true feltwork; and (3) a few shorter fibres passing to the superjacent pia. None of the fibres anastomose, and none show any special vascular connections.

The Stellate Fibre Cell.—This has been recognised by most observers, especially in the white matter and septa of the cord, and can be isolated by maceration in 30 per cent. alcohol (Ranvier). This form of stellate cell, however, is entirely distinct—as shall be shown—from, and should not confounded with, the protoplasmic glia cells, which also have a stellate shape in general, and which with the ordinary methods show but little apparent difference from the stellate fibre cell. The distinction here too clearly comes out when these are studied by Golgi's method. Hitherto all neuroglia cells in the adult brains have been included under one category of "spider" cells (Deiters, Meynert, and others),

which others have named stellate cells. But it can be demonstrated that these form two distinct, and in many respects opposed, groups—namely, into stellate fibre cells and stellate protoplasmic cells showing important and fundamental differences. In the stellate fibre cell a distinct cell body is hard to recognise, partly owing to the enormous number of fibres which emerge from and intercross in the cell body, and so obscure and conceal it, partly owing to optical diffraction effects at the body or focus where so many fibres meet and decussate, and partly because there is but a small and scanty remnant of protoplasm to constitute the cell body. With a wide angle of light perfectly focussed and free from chromatic aberration, and with equally good lenses, the best preparations will show only a very small quantity of protoplasm in the cell body, which, however, is mainly constituted of the meeting and intercrossing fibres. (Fig. 2.) Many of these neuroglia fibres therefore pass right through the cell body. In calibre and contour they are remarkably like the fibres of their congeners the caudate fibre cells, and exhibit the same peculiar sharp curves and angular bends in a course otherwise straight, and also the same sharp transverse fractures. They stain, too, of the same colour, never branch or anastomose, are of considerable length (being on an average five to eight times as long as the processes of the protoplasmic neuroglia cells), and do not exhibit the special vascular attachments which the protoplasmic glia cell exhibits. It should therefore be distinguished from the next great class of neuroglia elements—namely, the protoplasmic glia cell.

B. THE PROTOPLASMIC GLIA CELL.

This occurs abundantly throughout the grey matter in all the layers of the cortex, while the stellate fibre cell is absent from, or only most sparingly present in, the grey cortex; while, on the other hand, it is exceedingly abundant in the medullary substance, where the protoplasmic glia cell is correspondingly rare.

The protoplasmic glia cell has a distinct cell body, which is irregularly oval, frequently pyriform. Its processes are but

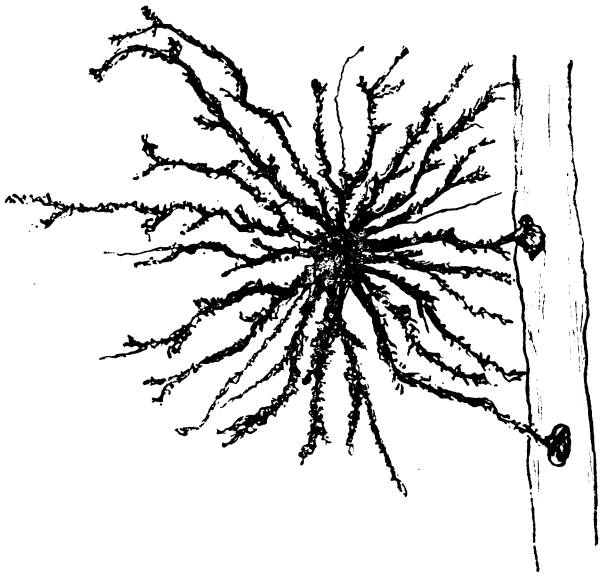

Fig. 3.—A protoplasmic neuroglia cell from the human brain (fourth layer of cortex), showing two expanded conical disc-like attachments to a vessel. Highly magnified.

of slight or moderate length relatively to the fibres of the neuroglia fibre cell, which are from five to eight times as long. The appearance of the protoplasmic glia cell is highly characteristic, and in specimens stained with silver chromate it is impossible to confound these cells (Fig. 3), with the neuroglia fibre cells (Fig. 2). The various protoplasmic processes also exhibit great variations of calibre, some being stout and coarse, and others exceedingly fine (see Fig. 3). The protoplasmic processes are also dendritic, a thing never seen in the stellate fibre cells. A most striking feature is the shaggy granular contour, as if a fine moss constituted the protoplasmic processes. The neuroglia fibres with good illumination have a deep brown, which is slightly translucent, giving these fibres almost a horny appearance; the dendritic shaggy granular protoplasmic processes, on the other hand, take a distinct reddish-grey tint. Further, by one or more of their coarser processes the protoplasmic cells are attached to the perivascular sheaths (Fig. 3). The cells of the perivascular sheath can be seen in fortunate preparation to give forth processes which stream into the circumjacent brain substance, and are granular and resembling the finer protoplasmic processes above described in appearance and coloration. Finally, a fact of the utmost significance, and one clearly demonstrated by the silver staining, is the presence of a lymph space surrounding the protoplasmic glia cells and its branches, and directly continuous with the perivascular lymph spaces. For it not infrequently happens—unless precautions are taken to prevent it—that, in addition to the intimate staining of the nerve and glia elements, a fine dark precipitate of silver chromate takes place in the perivascular spaces and on the surface of the cortex. In the very regions where this occurs, the protoplasmic glia cells, which, when their intimate structure is stained, present the normal appearance as in Fig. 3, may show the superadded surface deposit, and this deposit is continuous over the vascular processes, and so with that in the perivascular spaces. Sometimes the deposit will not have gone on to cover all the processes, so that those which stand out naked and uncovered exhibit the usual appearances as in Fig. 3. These appearances—which can be repeatedly verified—seem to demonstrate not only the well-known perivascular lymph space, but also a system of lymph spaces surrounding the body and dendritic processes of the protoplasmic glia cells, and directly continuous with the perivascular lymph space. The neuroglia fibre cells exhibit no such lymph spaces. Thus it is clear that the neuroglia elements of the brain are not a uniform structure, nor can their functions be regarded as correspondingly simple and uniform. For the fibre cell elements and the protoplasmic cell elements stand opposed to each other; the former constituting a plexus system of well organised fibres which form a passive supporting feltwork in the brain, while the latter constitute a group of active protoplasmic elements present in abundance only in the grey matter, and having vascular and lymphatic relations of a striking character, and one which points to their active *rôle* in the circulatory and lymphatic economy of the brain.

Finally it can be shown that the protoplasmic glia cells with vascular attachments are mesoblastic in origin; and that the fibre cells (both caudate and stellate) are epiblastic in origin. Thus in the olfactory epithelium we have a differentiation of the the primitive epiblast into sustentacular cells and bipolar nerve cells—situated between the basement membrane and the surface. No vessels or other connective elements have ingrown. In the more complex retina—which also is free from connective or other mesoblastic elements—the epiblast has given rise to three superposed layers of nerve elements, and to a well marked system of sustentacular elements, the fibres of Müller. In the embryonic spinal cord the primitive epiblast shows an early differentiation into nerve elements and supporting elements (neuroblasts and spongioblasts of His) and the distinction is obvious and can be recognised before the invasion of mesoblastic elements (blood vessels and connective tissue) from the outside.[1] In the embryonic cord of the chick and of amphibia similar observations have been announced.[2] In all these we have sustentacular elements of epiblastic origin, contemporaneous in origin with the nerve elements, and continuing into adult life as sustentacular structures (fibre cells). The protoplasmic glia cells—those connected with vessels—are to be regarded as ontogenetically younger, and derived from connective elements which have come in with the ingrowth and invasion of vessels, and developed in large numbers in the cerebral cortex. The fibre cells, judging from their numbers in the adult brain—especially the cortex—would seem to have produced an enormous number of wavy fibres of great length, while in the very act of such extraordinary fibrilla-

[1] His, *Archiv f. Anat. u. Phy.*, 1889. Golgi, *Sulla fina Anatomia*, 1886.
[2] Cajal, *Estructura de la Medula Espinal de los Reptiles*, 1891.

tion there protoplasm is used up and exhausted, only a small remnant persisting to mark the cell body. Finally, as instructive analogies may be pointed out the epithelial cells of the Malpighian layer of the epidermis which presents fibrils passing through the cell bodies and constituting the intercellular "bridges" (Ranvier), comparable to the fibres passing through the cell bodies in the stellate neuroglia fibre cells; for were the epithelial cell-bodies further apart, and the fibrils relatively longer, their appearance would be not unlike that of the stellate neuroglia fibre cells, an analogy which strengthens the relationship (by genesis) of the neuroglia fibre cells to epithelial elements.

The protoplasmic glia elements are really the elements which exhibit a morbid hypertrophy in pathological conditions (alcoholism, G.P.), and which may show further morbid activities, in the last stage of which their protoplasm will deposit numerous organised fibrillæ, in the act of doing which the protoplasm proper is used up, except a scanty remnant, which may persist, ghost-like, to mark the position of what was once a protoplasmic cell body.

Thus in fundamental facts of structure, in their topographical distribution, in ontogenesis, in their relationships to vascular and lymphatic systems, and in the morbid changes they show it would seem that there are ample grounds for supporting the classification of the neuroglia elements into protoplasmic cells and fibre cells. The growing importance of these elements is becoming daily obvious, especially in brain pathology.

CONGENITAL (?) DILATATION AND HYPERTROPHY OF THE COLON FATAL AT THE AGE OF 11 YEARS.

By T. J. WALKER, M.D.,
Surgeon to the Peterborough Infirmary.
WITH PATHOLOGICAL REPORT
By JOSEPH GRIFFITHS, M.D.,
Pathologist at Addenbrooke's Hospital, Cambridge.

THE boy (F. S.), aged 11, the subject of this note, died on February 6th, 1890. At birth nothing unusual was noticed about the child, but within a few weeks the abdomen was observed to be unusually large, this enlargement increasing to such a degree that when 3 months old the child was taken to the Peterborough Infirmary for treatment. Nothing was then detected beyond considerable flatulent distension. The bowels acted regularly, and the child took nourishment freely, and did not apparently suffer special discomfort from the distension. Carminatives were administered, and strict directions as to diet given, but the condition remained unchanged, and the child ceased to attend.

About three years after the boy was again brought to the infirmary; the distension by this time had enormously increased, but again careful examination detected nothing more than a general tympanites, and the boy did not continue to attend. From this time until his death he was only occasionally under medical care. I used frequently to see him playing quietly or walking in the streets, but had nothing to do with him medically. On February 6th I was told of his death.

On inquiry I learned from the mother that from the time I saw him at the hospital eight years before, his body had gradually enlarged, that he suffered very little pain; his bowels were always confined, but could be relieved by enemata, or by passing a piece of soap into the rectum; his appetite was always bad, his breathing short, his muscular development feeble, his health generally varying with the degree of distension of the abdomen—that occasionally wind would "roar away" from the anus, the body becoming greatly reduced. Latterly the boy had suffered more pain, and had wasted considerably, but he had not been in any way alarmingly worse, and had died suddenly whilst an enema was being administered.

A *post-mortem* examination was made by Dr. Kirkwood and Dr. A. Platt, and the rough sketch of the corpse is drawn to scale from their measurements.

The height of the boy was a little over 4 feet; the total length over the abdomen, taken with a tape from the suprasternal notch to the pubes was 2 feet 3½ inches. This being thus divided:

	Ft.	Ins.
Suprasternal notch to base of ensiform	0	4½
Base of ensiform to umbilicus	0	13
Umbilicus to pubes	0	10
Girth just above nipples	0	27
Girth at point of greatest distension, 4 inches above umbilicus	3	11
Antero-posterior diameter at level of umbilicus	0	13

The diagram does not show, of course, the enormous width of the abdomen, which was very striking.

The body was emaciated, the lower part of the thorax greatly expanded and thrown upwards. On opening the abdomen, nothing was seen but an enormous coil of intestine, looking like a large leg and thigh, with the knee completely flexed; this, on further examination, was seen to be the transverse and descending colon, which measured 23 inches round; tracing it down it was seen that the excessive dilatation reached to the sigmoid flexure, gradually diminishing in this section of the bowel, the last part of which and the rectum were normal; there was no appearance of the slightest constriction, either in the rectum or the sigmoid flexure; in the lowest part of the colon was a considerable mass of soft fæces, which was readily squeezed into the rectum and out of the anus; tracing the distended bowel upwards it was found to diminish somewhat as it approached the cæcum, and the whole of the small intestine was normal in every respect. The ascending and descending colon had both a distinct mesentery. There were no adhesions or other ordinary signs of peritonitis, but the peritoneum was extraordinarily thick.

The distension of the abdomen had spread out and thrown up the lower part of the thorax, so that the thoracic cavity was described by Dr. Kirkwood as resembling a shallow pie dish; the back of the diaphragm being fixed the anterior edge was tilted up, so that the under surface of the liver looked directly forwards; the depth from the suprasternal notch to the top of the diaphragm was about 2½ inches, the lungs and heart being crowded into a space altogether inadequate for their normal development and action. The condition of the mesenteric glands, as seen in the specimen, is sufficient to account for the emaciation and increasing feebleness described by the mother of the boy. The immediate

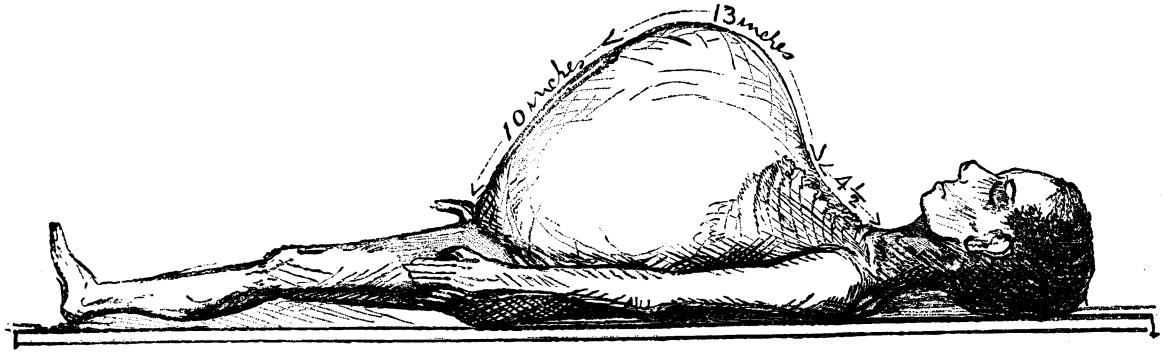

[Drawn from measurements taken after death.]