

The treatment of lupus nephritis by methyl prednisolone pulse therapy

S. DOSA*
M.D., M.R.C.P.

W. LAWLER
M.B., Ch.B.

S. A. CAIRNS
B.Sc., M.B., M.R.C.P.

N. P. MALLICK
B.Sc., M.B., F.R.C.P.

I. N. SLOTKI
B.Sc., M.B., Ch.B.

*Department of Renal Medicine, Manchester Royal Infirmary, and
Department of Pathology, University of Manchester*

Summary

Four patients with proliferative glomerulonephritis due to systemic lupus erythematosus were treated with intravenous methyl prednisolone 'pulse' therapy. In all, eight courses of therapy were given, three for acute oliguric renal failure; and on each occasion there was a good response to the treatment. Clinical, histological and immunological details of the patients are presented. The diagnosis, treatment, and monitoring of disease activity in lupus nephritis are discussed in the light of this experience.

Introduction

Renal involvement in systemic lupus erythematosus (SLE) has been studied extensively and death from renal failure is one of the serious consequences of the disease (Dubois and Tuffanelli, 1964; Estes and Christian, 1971; Feng, Cheah and Lee, 1973). Renal histopathological changes are valuable both as a prognostic indicator and in monitoring disease activity. The prognosis is broadly proportional to the extent of glomerular proliferative changes and acute renal failure due to diffuse proliferative glomerulonephritis with crescent formation is almost invariably associated with early death (Baldwin *et al.*, 1970; Pollack, Pirani and Kark, 1961; Baldwin and Gallo, 1975).

Whilst oral corticosteroids alone are of some benefit in the treatment of diffuse proliferative lupus nephritis (LN) (Pollack *et al.*, 1961, 1973; Ackerman, 1970) other forms of therapy have recently been advocated, especially for patients with severe renal failure. Some success has been reported with combination therapy consisting of steroids, immunosuppressants, dipyridamole and anticoagulants, but morbidity and mortality attributable to therapy do occur (Ponticelli *et al.*, 1974; Brown *et al.*,

1974). Encouraging preliminary results have been obtained with plasmapheresis (Jones *et al.*, 1976) but this technique is not available in all centres, is time-consuming and costly and its effectiveness needs further evaluation. A simple therapeutic regime is clearly preferable.

Over the past 3 years the authors have employed intravenous methyl prednisolone (MP) pulse therapy in cases of SLE with severe renal involvement. Here they describe their results in four patients with diffuse proliferative LN, two of whom presented with acute oliguric renal failure.

Case reports

Details of the four patients are summarized in Table 1.

Case 1

In 1967, at the age of 19 years, a Chinese girl developed acute renal failure during her first pregnancy. Renal biopsy showed diffuse proliferative glomerulonephritis with crescents. The pregnancy was terminated and, with oral steroids and azathioprine, renal function improved. Proteinuria persisted and she remained on high doses of oral steroids. Her third pregnancy was terminated in 1971 following an abrupt deterioration in renal function. By 1972 she was Cushingoid and hypertensive. The steroids were tailed off and by May 1973 she was asymptomatic. At this time the anti-nuclear factor (ANF) became positive, there was depletion of complement components, creatinine clearance was 50 ml/min and heavy proteinuria, 9 g/24 hr, persisted. Repeat renal biopsy showed mesangial proliferation with crescents progressing to sclerosis. In July 1974 she had a further episode of acute renal failure. She was treated with methyl prednisolone 250 mg i.v. for 12 days and cyclophosphamide and chlorambucil. There was substantial recovery of renal function and anti-DNA antibody and complement levels improved (Fig. 1). She had a further episode of acute oliguric renal

* Present address: Department of Nephrology, University of Cincinnati, U.S.A.

Requests for reprints: Dr N. P. Mallick, Consultant Physician, Department of Renal Medicine, Manchester Royal Infirmary, Oxford Road, Manchester 13.

TABLE 1. Summary of clinical state and investigations of the four patients

Patient	ARA* criteria fulfilled	Biopsy appearance	Clinical condition immediately before MP† therapy	Other therapy given with MP†	Complement		Anti-DNA antibody		Proteinuria		Creatinine clearance	
					Before	After	Before	After	Before	After	Before	After
1	4	Mesangial proliferation. Capsular crescents progressing to sclerosis. IgM, IgA, C3 deposits. Immune complexes in mesangial and intramembranous location.	a. Acute oliguric renal failure. b. Acute oliguric renal failure.	Cyclophosphamide; Chlorambucil; Oral prednisone; Oral prednisone.	CH50 7 CH50 37 C3 0·17	CH50 60 CH50 N C3 N	58 69 <10	21 <10	14 4 4	7 4 0	2 0 4-6	20
2	4	Mesangial proliferation. Capsular crescents. IgG and C3 in mesangium.	a. Declining renal function. Proteinuria, leucopenia, thrombocytopenia. b. Declining renal function.	Oral prednisone	N	N	35 <10	<10	20 4	4 30	30 49	49
3	4	Immune complex glomerulonephritis with deposits of IgM, IgG and C3 in membrane and mesangium.	a. Rash, proteinuria, thrombocytopenia. b. Recurrent immunological evidence of disease activity.	Oral prednisone	CH50 12 C1q 12 C4 16 C3 1	CH50 N C1q N C4 30 C3 N	26 10	10	15 6	170 170	170	170
4	3	1. Diffuse proliferative glomerulonephritis Crescents, IgM, C3, C1q, in membrane and mesangium. 2. Reduction in cellularity. Progression towards sclerosis. Crescents still present.	a. Oligoanuric renal failure. b. Declining renal function. Heavy urinary sediment.	Azathioprine; Oral prednisone. Azathioprine; Oral prednisone.	CH50 34·2 C1q 66 C3 0·66	CH50 N C3 N C1q N	18·5 —	—	18 5	5 2	2 15	15

Range of normal values: CH50 45-80 u./ml.

C3 1-2 g/l.

C1q 70-160%

C4 60-170%

Anti-DNA antibody 0-10 u./ml.

N = within normal range
* American Rheumatism Association.In Column 4 'a' and 'b' indicate separate relapses.
† Methyl prednisolone.

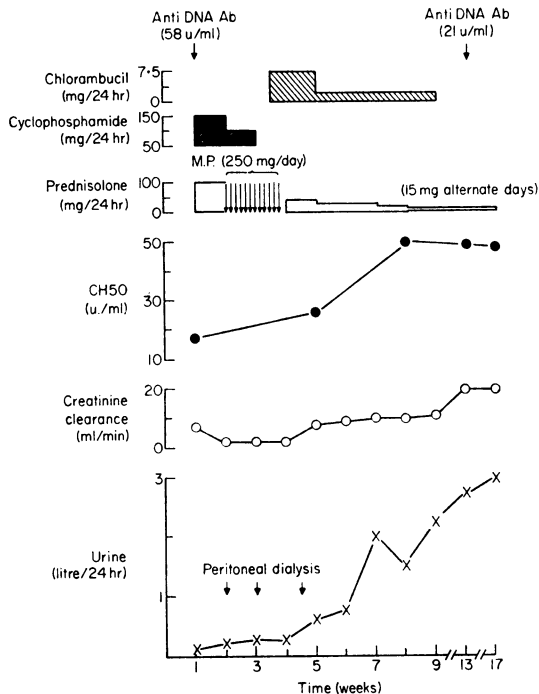


FIG. 1. Clinical Course - Case 1.

failure in August 1976 when renal biopsy showed widespread glomerulosclerosis. She received a further course of methyl prednisolone with recovery of some renal function which was accompanied by a return to normal of anti-DNA antibody, CH50 and C3 levels. Following this episode she managed well on diet until August 1977 when she died in end stage renal failure.

Case 2

A 49-year-old woman presented in October 1975 with a nephrotic syndrome and microscopic haematuria. The ANF was negative and serum complement components and anti-DNA antibody normal. Renal biopsy showed mesangial proliferation with crescents. By June 1976 her creatinine clearance had declined in 9 months from 50 to 30 ml/min and she had developed leucopenia and thrombocytopenia. The ANF was now positive and the anti-DNA antibody was raised. Following methyl prednisolone one g i.v. daily for 5 days the white cell and platelet counts and anti-DNA antibody were normal and the creatinine clearance had risen to 50 ml/min. A further course of methyl prednisolone was given in October 1976 when her creatinine clearance fell abruptly to 10 ml/min. The anti-DNA antibody and serum complement levels were normal. The creatinine clearance rose following the course to 48 ml/min.

Case 3

A 15-year-old girl developed SLE in September 1975 when she presented with a facial rash and nephrotic syndrome. She had thrombocytopenia and a circulating antinuclear antibody. The ANF was positive, anti-DNA antibody raised and CH50, C₁q, C₄ and C₃ low. Her condition partially responded to oral prednisolone, 100 mg/day but proteinuria persisted. The anti-DNA antibody remained raised and there was continuing evidence of complement activation. She became Cushingoid and azathioprine and chloroquine therapy were added. When her coagulation defect had resolved a renal biopsy showed mesangial proliferation and crescent formation. Following a recurrence of her nephrotic syndrome, facial rash and thrombocytopenia in June 1976 she received a course of methyl prednisolone. The proteinuria declined, creatinine clearance rose and the platelet count returned to normal. With the exception of a persistently low C₄, complement components and anti-DNA antibody were normal. The patient was maintained on low doses of oral prednisolone until October 1976 when a rising anti-DNA antibody and falling CH50 and C₃ levels prompted a further methyl prednisolone course which reversed the changes. Now (1977) the features of Cushing's syndrome have regressed and the facial erythema has almost resolved.

Case 4

A 57-year-old man presented in August 1976 with oligo-anuric renal failure, oedema and hypertension. The antinuclear factor was negative but anti-DNA antibody raised and CH50, C₁q and C₃ low. There were red cells and granular casts in the urine. Renal biopsy showed diffuse proliferative glomerulonephritis with crescents. Oliguria persisted despite oral steroids and azathioprine so he received a 5-day course of methyl prednisolone followed by low dose oral steroids and azathioprine (Fig. 2). Renal function improved, serum complement levels returned to normal and urinary sediment cleared. A further course of methyl prednisolone was given in September 1976 when renal function declined and urinary cell and cast excretion recurred. Recovery was again observed. A renal biopsy showed less cellularity with progression towards sclerosis. Crescents were still present.

Discussion

The diagnosis of SLE is often difficult at initial presentation. Cohen and Canoso (1972) found that only 67% of their patients fulfilled the American Rheumatism Association (ARA) criteria (Cohen, Reynolds and Frankin, 1971) for systemic lupus erythematosus at first, whereas 7 years later 94% did so. The present cases accord with this finding. Only

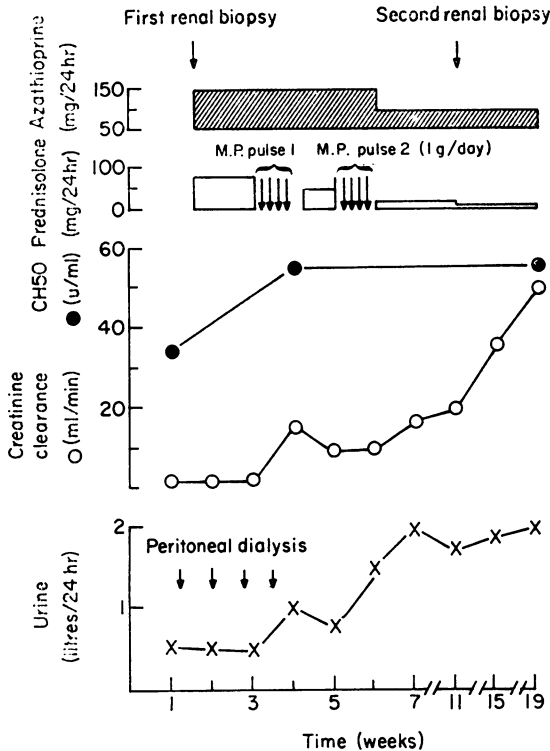


FIG. 2. Clinical Course - Case 4.

one of the present cases fulfilled the American Rheumatism Association criteria at presentation whereas now all but one do so. In a larger series, twelve out of 260 patients presenting with proteinuria developed a positive ANF at a later stage of their illness, the diagnosis of SLE eventually being established in five of these cases (Cairns, Dosa and Mallick, unpublished).

The criteria for diagnosing systemic lupus erythematosus are becoming more precise but difficulties still arise (Davis *et al.*, 1973). Serum complement and anti-DNA antibody levels are affected in systemic lupus erythematosus and their value as markers of disease activity has been extensively reviewed (Schur and Sanderson, 1968; Epstein, 1973; Schur, 1975; Hughes, 1975; Bardana *et al.*, 1975; Cameron *et al.*, 1976). The LE cell phenomenon is a less sensitive index of the presence or activity of its eponym than was previously supposed (Sharp *et al.*, 1971).

The varying natural history of SLE makes assessment of therapy difficult; particularly in cases with only mild renal involvement where prolonged survival is usual (Baldwin *et al.*, 1970; Zweiman *et al.*, 1968) but is easier to judge in patients with severe diffuse proliferative lesions. In such cases treatment

with corticosteroids in a dose of 40–60 mg/day over prolonged periods has improved survival significantly but steroid toxicity is frequent (Feng *et al.*, 1973; Pollack *et al.*, 1961, 1973). Indeed, it contributes to early mortality and may be responsible for some of the late morbidity and mortality of lupus patients (Bulkley and Roberts, 1975; Urowitz *et al.*, 1976). Gary, Maher and Schreiner (1967) found that intensive therapy sufficient to suppress disease activity during the acute phase may be safely followed by minimal daily steroid therapy. Cathcart *et al.* (1976) showed that methyl prednisolone pulse therapy results in rapid improvement in renal function and reversal of associated immunological abnormalities, and that these benefits are sustained with low dose maintenance steroid therapy. Recent evidence suggests that methyl prednisolone therapy reduces the level of circulating soluble immune complexes in patients with lupus nephritis even when large doses of oral prednisolone fail to do so, and that this fall correlates well with improvement in clinical activity of the disease (Levinsky, Cameron and Soothill, 1977).

The clinical presentation and type of renal involvement in the present patients suggested a poor prognosis, since two of them were originally in acute oliguric renal failure and, in all, the biopsy appearances were of severe diffuse proliferative lupus nephritis with glomerular crescent formation. Case 1 (initially thought to have idiopathic glomerular disease) is possibly unique in having suffered and survived four episodes of oliguric renal failure due to lupus nephritis. Therapy with oral prednisolone produced benefit but at a price. She developed so grotesque an appearance (florid Cushingoid habitus with extensive striae) that she was rejected by her husband and family. Later episodes were successfully treated with methyl prednisolone pulses combined with maintenance low dose oral prednisolone and there were no significant side effects. In Case 4, who was initially anuric, methyl prednisolone pulse therapy produced a dramatic improvement in renal function and a subsequent relapse was rapidly reversed by a further pulse.

Despite improvement in the glomerular filtration rate following methyl prednisolone only a transient reduction in proteinuria was observed in the four patients but, as noted previously, the level of proteinuria is a poor guide to renal disease activity (Pollack *et al.*, 1961; Ackerman, 1970).

The effect of methyl prednisolone pulse therapy on the immunological abnormalities associated with lupus nephritis was impressive. In Case 3, serum complement levels, which had remained low during several months of oral steroid therapy were, with the exception of C4, normal within a few weeks of starting pulse therapy. A similar response was

obtained in all the patients with evidence of complement consumption. In all cases, there was a sharp fall in anti-DNA antibody titres with therapy.

In Case 4, despite clinical and immunological improvement a repeat renal biopsy two weeks after the second pulse showed only slight decrease in cellularity and progression towards sclerosis. The findings on immunofluorescence remained unchanged and on electron microscopy there was still extensive immune complex deposition in mesangial and intramembranous locations. It seems likely that factors other than the simple presence of immune complexes play an important part in the renal damage of lupus nephritis and are altered by methyl prednisolone therapy.

Extrarenal manifestations of disease were suppressed in the present patients even when this had not been achieved by oral steroids. No side effects associated with methyl prednisolone therapy were observed and because of the lower maintenance steroid dosage, Cushingoid features subsequently regressed in two of the patients. Methyl prednisolone pulse therapy is effective in the treatment of severe proliferative lupus nephritis regardless of the degree of renal impairment and should be considered as the first line of treatment for this condition. Response to such therapy appears to be rapid and, because of its simplicity and lack of side effects, it can be readily repeated if relapse occurs. In the authors' experience, once remission has been achieved it can be maintained with low dose daily or alternate day maintenance steroid therapy which produces few side effects.

References

- ACKERMAN, G.L. (1970) Alternate-day steroid therapy in lupus nephritis. *Annals of Internal Medicine*, **72**, 511.
- BALDWIN, D.S. & GALLO, G.R. (1975) Lupus nephritis. *Clinics in Rheumatic Diseases*, **1**, 639.
- BALDWIN, D.S., LOWENSTEIN, J., ROTHFIELD, N.F., GALLO, G. & McCLUSKEY, R.T. (1970) The clinical course of the proliferative and membranous forms of lupus nephritis. *Annals of Internal Medicine*, **73**, 929.
- BARDANA, E.J., HARBECK, R.J., HOFFMAN, A.A., PIROFSKY, B. & CARR, R.I. (1975) The prognostic and therapeutic implications of DNA: anti-DNA antibody immune complexes in systemic lupus erythematosus (S.L.E.). *The American Journal of Medicine*, **59**, 515.
- BROWN, C.B., TURNER, D., OGG, C.S., WILSON, D., CAMERON, J.S., CHANTLER, C. & GILL, D. (1974) Combined immunosuppression and anticoagulation in rapidly progressive glomerulonephritis. *Lancet*, **ii**, 1167.
- BULKLEY, B.H. & ROBERTS, W.C. (1975) The heart in systemic lupus erythematosus and the changes induced in it by corticosteroid therapy. *The American Journal of Medicine*, **58**, 243.
- CAMERON, J.S., LESSOF, M.H., OGG, C.S., WILLIAMS, B.D. & WILLIAMS, D.G. (1976) Disease activity in the nephritis of systemic lupus erythematosus in relation to serum complement concentrations. *Clinical and Experimental Immunology*, **25**, 418.
- CATHCART, E.S., IDELSON, B.A., SCHEINBERG, M.A. & COUSER, W.G. (1976) Beneficial effects of methyl prednisolone 'pulse' therapy in diffuse proliferative lupus nephritis. *Lancet*, **i**, 163.
- COHEN, A.S. & CANOSA, J.J. (1972) Criteria for the classification of systemic lupus erythematosus - status 1972. *Arthritis and Rheumatism*, **15**, 540.
- COHEN, A.S., REYNOLDS, W.E. & FRANKIN, E.C. (1971) Preliminary criteria for the classification of systemic lupus erythematosus. *Bulletin on Rheumatic Diseases*, **21**, 643.
- DAVIS, P., ATKINS, B., JOSSE, R.G. & HUGHES, G.R.V. (1973) Criteria for classification of S.L.E. *British Medical Journal*, **3**, 90.
- DUBOIS, E.L. & TUFFANELLI, D.L. (1964) Manifestations of systemic lupus erythematosus. *Journal of the American Medical Association*, **190**, 104.
- EPSTEIN, W.V. (1973) Immunological events preceding clinical exacerbation of systemic lupus erythematosus. *American Journal of Medicine*, **54**, 631.
- ESTES, D. & CHRISTIAN, C.L. (1971) The natural history of systemic lupus erythematosus by prospective analysis. *Medicine*, **50**, 85.
- FENG, P.H., CHEAH, P.S. & LEE, Y.K. (1973) Mortality in systemic lupus erythematosus: a ten year review. *British Medical Journal*, **4**, 772.
- GARY, N.E., MAHER, J.F. & SCHREINER, G.E. (1967) Lupus nephritis: renal function after prolonged survival. *New England Journal of Medicine*, **276**, 73.
- HUGHES, G.R.V. (1975) Antinuclear antibodies in S.L.E. - clinical and pathological significance. *Clinics in Rheumatology*, **1**, 545.
- JONES, J.V., CUMMING, R.H., BUCKNALL, R.C., ASPLIN, C.M., FRASER, I.D., BOTHAMLEY, J., DAVIS, P. & HAMBLIN, T.J. (1976) Plasmapheresis in the management of acute systemic lupus erythematosus? *Lancet*, **i**, 709.
- LEVINSKY, R.J., CAMERON, J.S. & SOOTHILL, J.F. (1977) Serum immune complexes and disease activity in lupus nephritis. *Lancet*, **i**, 564.
- POLLACK, V.E., PIRANI, C.L., DUJOVNE, I. & DILLARD, M.G. (1973) In: *Glomerulonephritis*, p. 1167. (Kincard-Smith, P., Mathew, T.H., Lovell-Becker, E., Eds.). John Wiley & Sons. New York, London, Sydney, Toronto.
- POLLACK, V.E., PIRANI, C.L. & KARK, R.M. (1961) Effect of large doses of prednisone on the renal lesions and life span of patients with lupus glomerulonephritis. *Journal of Laboratory and Clinical Medicine*, **57**, 495.
- PONTICELLI, C., IMBASIATI, E., BRANCACCIO, D., TARANTINO, A. & RIVOLTA, E. (1974) Acute renal failure in systemic lupus erythematosus. *British Medical Journal*, **3**, 716.
- SHARP, G.S., IRVIN, W.C., LAROQUE, R.L., VELEZ, C., DALY, V., KAISER, A.D. & HOLMAN, H.R. (1971) Association of autoantibodies to different nuclear antigens with clinical patterns of rheumatic disease and responsiveness to therapy. *The Journal of Clinical Investigation*, **50**, 350.
- SCHUR, P.H. (1975) Complement in lupus. *Clinics in Rheumatic Diseases*, **1**, 519.
- SCHUR, P.H. & SANDERSON, J. (1968) Immunological factors and clinical activity in lupus erythematosus. *New England Journal of Medicine*, **278**, 533.
- UROWITZ, M.B., BOOKMAN, A.A.M., KOEHLER, B.E., DUNCAN, A.G., SMYTHE, H.A. & OGYZLO, M.A. (1976) The bimodal mortality pattern of systemic lupus erythematosus. *The American Journal of Medicine*, **60**, 221.
- ZWEIMAN, B., KORNBUM, J., CORNOG, J. & HILDRETH, E.A. (1968) The prognosis of lupus nephritis. *Annals of Internal Medicine*, **69**, 441.