

CASE REPORTS

Riedel's thyroiditis leading to severe but reversible pituitary failure

W. F. KELLY
B.Sc., M.R.C.P.

K. MASHITER
Ph.D.

SELWYN TAYLOR
D.M., F.R.C.S.

G. F. JOPLIN
Ph.D., F.R.C.P.

Endocrine Unit and Department of Surgery, Royal Postgraduate Medical School, Hammersmith Hospital, Du Cane Road, London W12 0HS

Summary

This patient with histologically proved Riedel's thyroiditis had hypothyroidism of sufficient severity to cause panhypopituitarism, and it was this which first brought him to medical attention. The beneficial effects are described of surgery in relieving severe dysphagia and stridor, and of prednisone in softening and shrinking the hard neck mass. The extent of pituitary failure, and the degree of recovery on treatment with thyroxine are reported, together with details of 4 other cases of Riedel's thyroiditis seen by one of the authors (S.T.).

Introduction

In 1883 Professor B. M. C. L. Riedel operated on a man with a hard neck mass compressing the trachea. His clinical diagnosis had been carcinoma. The mass was firmly adherent to adjacent structures, precluding complete removal, but a piece the size of a walnut was taken out. Histology showed fibrous tissue with no evidence of malignancy, and the patient recovered with relief from stridor. Riedel reported 2 cases in 1896, adding a third case in 1897 and a follow-up of his third case in 1910. While commenting on the beneficial effects of surgery in his own cases, Riedel mentioned that spontaneous regression could occur, quoting details of a patient of Silatschek (Riedel, 1910).

Using the strict histological criteria of Woolner, McConahey and Behrs (1957), Riedel's thyroiditis is rare; only 20 cases were found among 42 000 thyroid operations done in 36 years at the Mayo Clinic (Woolner, McConahey and Behrs, 1957). In the last 15 years 4 other cases of Riedel's thyroiditis have been seen by one of the authors (S.T.) (Katsikas, Shorthouse and Taylor, 1976).

Correspondence to: Dr W. F. Kelly, Endocrine Unit, Hammersmith Hospital, London W12 0HS.

Case history

The patient, a single man aged 26 years, was referred to the Hammersmith Hospital in November 1975 with a 4-year history of increasing tiredness, and symptoms of postural hypotension. In the previous 6 months he had lost 12 kg in weight and had been vomiting intermittently. There were symptoms of hypothyroidism with increasing lethargy, constipation and preference for warm weather; also, there had been decreased libido for several months, and he was only shaving once per week. There was no relevant past medical or family history.

On examination the most significant abnormality was a hard ill-defined slightly tender mass at the front of the neck, with no movement on swallowing. Normal thyroid tissue was not palpable. The skin was cool and abnormally dry and the reflexes showed a delayed relaxation phase. The facial, axillary and pubic hair growth was subnormal, but the penis and testes were normal in size and development. Blood pressure was 80/50 mmHg lying down and standing, the visual fields were full to confrontation, and optic discs were normal.

Methods of hormone assays

Hormone measurements were carried out by double antibody radioimmunoassay as previously reported by Marshall *et al.* (1973) for luteinizing hormone (LH) and follicle stimulating hormone (FSH), by Hartog *et al.* (1964) for human growth hormone (GH), and by Kuku *et al.* (1974) for thyroid stimulating hormone (TSH). MRC Standard (69/104) was used for LH and FSH, and WHO 1st International Reference Preparation (MRC 66/217) for GH and MRC 68/38 for TSH. Serum cortisol was measured by competitive protein binding assay according to Marshall *et al.* (1972)

and testosterone by radioimmunoassay (Collins, 1972). Serum thyroxine (T_4) and triiodothyronine (T_3) were measured by radioimmunoassay (Kjeld *et al.*, 1975).

Pre-treatment investigations, November 1975

Hormone levels. The serum T_4 was 39 nmol/l (normal 71–148), and T_3 1.0 nmol/l (normal 1.5–3.1). Basal TSH was 12 mu./l (normal <4) rising to 29 mu./l at 30 min (normal <25) and 27 mu./l at 60 min (normal <20) after 200 μ g thyrotrophin releasing hormone (TRH) i.v., i.e. a response typical of primary hypothyroidism (Fig. 1).

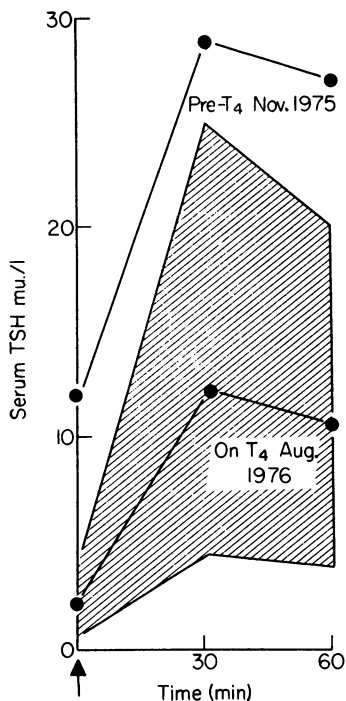


FIG. 1. Serial TRH tests. Hatched area shows limits of normal response. Arrow denotes 200 mcg TRH i.v.

During an insulin-tolerance test when the patient became clinically hypoglycaemic with a trough blood glucose of 2.3 mmol/l, serum cortisol rose from a basal value of 72 nmol/l (normal 100–550) to a peak of 221 nmol/l (normal >550), and growth hormone (Fig. 2) rose from <1 mi.u./l to only 1.8 mi.u./l (normal >20). The short tetracosactrin (Synacthen, CIBA) test using 0.25 mg i.m. showed a low basal cortisol (80 nmol/l) rising to only 232 nmol/l at 60 min.

Serum LH was low at <1 u./l (normal 3–8), rising to only 1.5 u./l at 30 min (normal >8) and 1.5 u./l

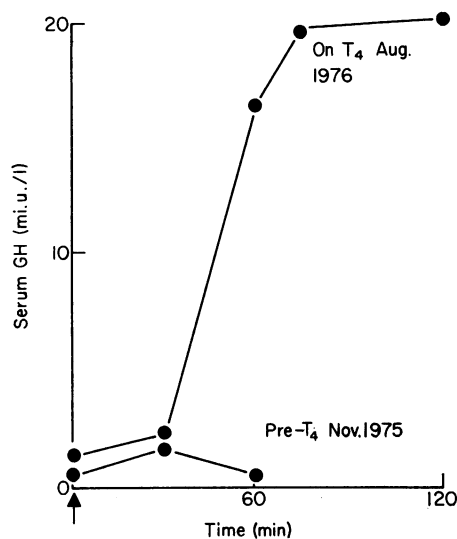


FIG. 2. Serial insulin tolerance tests. Peak GH normally exceeds 20 mi.u./l.

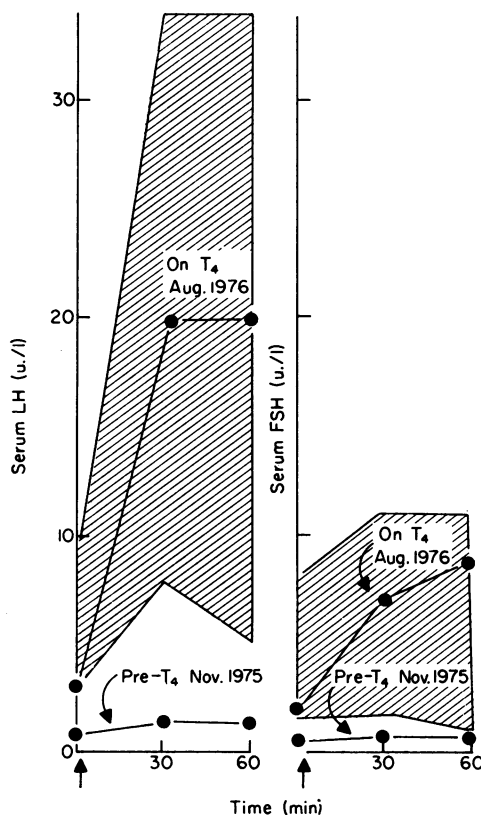


FIG. 3. Serial GnRH stimulation tests. Hatched areas show limits of normal response. Arrows denote 100 μ g GnRH i.v.

at 60 min (normal >6) after 100 μg gonadotrophin releasing hormone (GnRH) i.v. The FSH response showed a similar pattern (Fig. 3). Serum testosterone was low, 2 nmol/l (normal 9–24) with subnormal response to 5.5 nmol/l on the ninth day following 5 injections of human chorionic gonadotrophin (HCG, Paynes & Byrne) 2000 units i.m. on alternate days (Fig. 4).

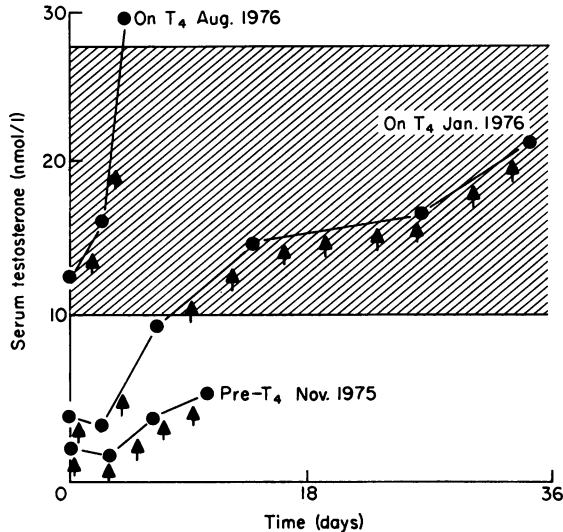


FIG. 4. Serial HCG stimulation tests. Hatched area shows normal range, unstimulated, in men. Arrows indicate 2000 units HCG i.m.

Other investigations. Thyroid scan showed a trivial uptake and only on the right side of the neck, and radiographs showed that the trachea was deviated to the right and severely compressed. Radiographs of the pituitary fossa and an excretion urogram were normal. The karyotype was 46 XY, normal male. Haemoglobin was 7.5 g/dl, reticulocytes 2%, serum iron 3 $\mu\text{mol/l}$ (low), transferrin 2 g/l (normal), ESR 144 mm in one hr.

Antibodies to thyroid cytoplasm were positive but tests for antibodies to adrenal, pituitary and testis were negative and serum immunoglobulins were normal. Routine biochemistry, including liver function tests, was normal.

Progress

On November 5th 1975 the patient had a syncopal attack, but improved following a 2.4-litre blood transfusion. It became apparent that dysphagia and stridor were developing and there were further syncopal attacks, some occurring whilst lying at rest. Prednisone 15 mg/day was commenced on

November 22nd, with improvement in vigour by 24 hr. On November 25th the neck was explored. Normal thyroid tissue was not identifiable, and hard, adherent fibrous tissue precluded removal of much of the mass but the trachea was freed. Histology showed changes of Riedel's thyroiditis (Fig. 5), with fibrous tissue infiltrating adjacent muscle. There was no evidence of malignancy, tuberculosis, syphilis, or lymphoid follicles such as are found in Hashimoto's thyroiditis. Postoperatively thyroxine was commenced, increasing to 0.2 mg/day.

On December 11th the patient was discharged home, also taking prednisone 7.5 mg/day. There was considerable improvement, and by January 1976 the patient was both clinically and biochemically euthyroid, with stridor still in abeyance. In April 1976 the neck mass had disappeared and prednisone was stopped. In May 1976 there was a respiratory tract infection with clinical features of adrenocortical insufficiency, but with good response to recommencing prednisone, which was rapidly reduced to zero by August 1976, when the only continuing medication was thyroxine 0.2 mg/day.

Improvement occurred rapidly in most of the stimulation tests on thyroxine therapy alone. TRH (Fig. 1), GH response to insulin-induced hypoglycaemia (Fig. 2), GnRH (Fig. 3) and HCG (Fig. 4) tests were all normal by August 1976. Testing of adrenocortical function by daily injections of 1 mg tetracosactrin (Synacthen Depot, CIBA) for 7 days on several occasions showed a progressive increase in serum cortisol response, the highest value reached in August 1976 being 869 nmol/l. However, basal cortisol remained low (56 nmol/l at 9 a.m.) and by August 1976 did not increase after insulin-induced hypoglycaemia.

In November 1976 the patient had again become clinically and biochemically hypothyroid (T_4 43 nmol/l, TSH >25 mu./l), probably owing to inadequate thyroxine being taken because of vomiting from adrenocortical insufficiency. At that time, insulin-induced hypoglycaemia (glucose 0.7 mmol/l) again showed impaired GH response (maximum serum GH was 9 mi.u./l) and both cortisol and plasma ACTH were undetectable. Tetracosactrin injections increased serum cortisol to 817 nmol/l. When thyroxine and prednisone were given under supervision, vomiting ceased and there was improvement in vigour.

The patient was readmitted in April 1977 for reassessment, taking thyroxine 0.2 mg/day and prednisone 1 mg on alternate days. There were now symptoms of severe neck compression with dysphagia and stridor, and recurrence of the mass in the neck was evident. Radiographs showed considerable narrowing of the lumen of the trachea. During emergency tracheostomy, dissection of the neck

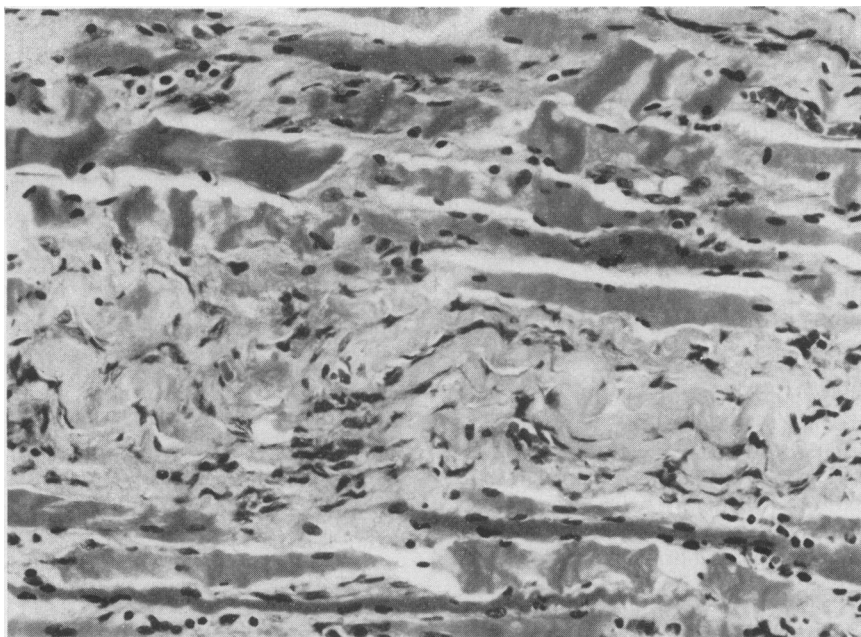


FIG. 5. Thyroid biopsy. Riedel's thyroiditis. Skeletal muscle fibres are separated by fibrous tissue containing scanty inflammatory cells. HE, $\times 300$.

was again extremely difficult owing to hard fibrous tissue, and normal thyroid tissue was not found. Symptoms were relieved, but 16 days later there was secondary haemorrhage and death.

Post-mortem examination confirmed the presence of fibrous tissue enclosing the trachea and extending into the upper mediastinum. There was no evidence of either retroperitoneal fibrosis, or of sclerosing cholangitis. The macroscopic appearance of the pituitary gland was normal, but the adrenals were small, consistent with atrophy secondary to corticosteroid therapy.

Discussion

The presentation and natural history of Riedel's thyroiditis is variable. Before operation, 5 of Woolner's 20 cases had hypothyroidism, 4 complained of dysphagia and one had dyspnoea; no patient complained of neck pain and 3 were noted to have neck tenderness. Katsikas *et al.* (1976) report dysphagia, in 2 of 4 patients, dyspnoea in one and neck pain and tenderness in 2 patients, but before surgery no patient was hypothyroid. Thus, the features in the present case reflecting the thyroid pathology *per se* were fairly typical. The special interest in this case was that his initial diagnosis was of total pituitary failure, and it was only later that a slightly tender neck swelling was noted, drawing attention to the primary defect in the thyroid gland.

Circulating thyroid antibodies are detectable in the majority of patients with idiopathic primary hypothyroidism, but are sometimes found in hypothyroidism secondary to pituitary failure (Vallotton, Pretell and Forbes, 1967). The presence in the serum of the present patient of a significant titre to thyroid cytoplasm is unusual since this was absent in all of 6 other cases of Riedel's thyroiditis (Doniach, 1976). The titre in this patient was, however, less than that customary in Hashimoto's thyroiditis. Thyroid antibodies were present in one and absent in 3 of the 4 cases of Katsikas *et al.* (1976). So far, attempts to explain Riedel's thyroiditis as an auto-immune process, or a defect in cell-mediated immunity have failed. Serum complement levels and lymphocytes were normal in all of 5 patients tested by Shorthouse *et al.* (1974).

The effect of corticosteroids in Riedel's thyroiditis is controversial, and recently it has been stated that surgery offers the only useful treatment (de Groot and Stanbury, 1975). However, a beneficial effect of corticosteroids in reducing the hardness of the thyroid was observed in case 2 of Katsikas *et al.* (1976). While the authors have no doubt as to the immediate efficacy of surgery in relieving stridor in their patient, they suspect that the initial diminution of size of the mass may have been due to prednisone. The dose of prednisone was deliberately kept as low as possible to try to avoid long-term adrenal

suppression. The initial dose did not exceed 15 mg/day, and, after 2 weeks, reduction in dose commenced. Eventually it became clear that maintenance corticosteroid therapy was essential to avoid adrenocortical insufficiency, as little as 1 mg/day of prednisone sufficing most of the time. On review, it is now apparent that tracheal constriction and neck induration were both held in abeyance by 7.5 mg daily of prednisone, but worsened on doses lower than this.

The association of primary hypothyroidism and reversible impairment of pituitary function has been previously shown for the GH and cortisol responses to insulin-induced hypoglycaemia (Root *et al.*, 1967; Vince *et al.*, 1970; Tunbridge, Marshall and Burke, 1973). Minozzi *et al.* (1973) found that basal plasma ACTH concentration was low and the response to insulin-induced hypoglycaemia was subnormal, but returned to normal when thyroxine was given. In primary hypothyroidism, basal plasma cortisol concentration is reported as normal (de Groot and Stanbury, 1975), and plasma free cortisol was also normal (Brien, 1976), but the acute responses to insulin stress (Tunbridge *et al.*, 1973) and ACTH (de Groot and Stanbury, 1975) may be impaired. In the present patient, however, plasma cortisol was low, and it is not clear why the pituitary-adrenal axis failed completely to return to normal in parallel with other endocrine functions when the patient was given thyroxine. The dose and duration of corticosteroid therapy was not sufficient, in the authors' experience, to cause serious problems of steroid withdrawal. The adrenal glands continued to respond to tetracosactrin but endogenous ACTH was undetectable basally and during severe hypoglycaemia, so the defect was at the level of the hypothalamus or pituitary gland. The previous case of primary hypothyroidism presenting with the clinical picture of hypopituitarism at the same endocrine Unit (reported by Tunbridge *et al.*, 1973) showed impaired cortisol and GH response to hypoglycaemia before treatment, but recovery to normal with thyroxine. In the present patient the GnRH test also returned to normal with treatment with thyroxine. The authors are not aware of a previous report of Riedel's thyroiditis presenting as pan-hypopituitarism, as described in this patient; it is also very unusual for primary hypothyroidism to present in this way.

Acknowledgments

We thank Dr S. J. Cooper of Lowestoft for referring the patient; Dr P. Lewis, consultant histopathologist, Professor D. Doniach (thyroid antibody studies) and Dr W. J. Irvine (organ specific antibody studies), Dr L. Rees (ACTH assay), the staff of our Immunoassay Laboratories, Dr King Davies, general practitioner, Dr E. Vogl of Hoechst UK Ltd for generous supplies of GnRH and the N.I.A.M.D.D., U.S.A., for TSH for the radioimmunoassay.

References

- BRIEN, T.G. (1976) The adrenocortical status of patients with thyroid disease. *Clinical Endocrinology*, **5**, 97.
- COLLINS, W.P. (1972) Radioimmunoassay of plasma testosterone. *Journal of Steroid Biochemistry*, **3**, 333.
- DE GROOT, L.J. & STANBURY, J.B. (1975) In: *The Thyroid and its Diseases*, 3rd edn. John Wiley & Sons, London.
- DONIACH, D. (1976) Personal communication.
- HARTOG, M., GAAFAR, M.A., MEISSER, B. & FRASER, T.R. (1964) Immunoassay of growth hormone in acromegalic patients. *British Medical Journal*, **2**, 1229.
- KATSIKAS, D., SHORTHOUSE, A.J. & TAYLOR, S. (1976) Riedel's thyroiditis. *British Journal of Surgery*, **63**, 929.
- KJELD, J.M., KUKU, S.F., DIAMANT, L., FRASER, T.R., JOPLIN, G.F. & MASHITER, K. (1975) Production and storage of ¹²⁵I thyroxine and ¹²⁵I tri-iodothyronine of high specific activity. *Clinica chimica acta*, **61**, 381.
- KUKU, S.F., HARSOULIS, P., YOUNG, J.L. & FRASER, T.R. (1974) Concentrations of immunoreactive thyrotrophin hormone in urine of normal subjects, patients with thyroid disorders, and hypopituitarism and after infusion of human thyrotrophic hormone. *Journal of Endocrinology*, **62**, 645.
- MARSHALL, J.C., ANDERSON, D.C., BURKE, C.W., GALVAO-TELES, A. & FRASER, T.R. (1972) Clomiphene citrate in man: increase of cortisol, luteinizing hormone, testosterone and steroid binding globulins. *Journal of Endocrinology*, **53**, 261.
- MARSHALL, J.C., ANDERSON, D.C., FRASER, T.R. & HARSOULIS, P. (1973) Human luteinizing hormone in man: studies of metabolism and biological action. *Journal of Endocrinology*, **56**, 431.
- MINOZZI, M., FAGGIANO, M., LOMBARD, G., CARELLA, C., CRISCOULO, T., OLIVER, CH. & VAGUE, PH. (1973) Somatotropic and corticotrophic functions in primary hypothyroidism before and after thyroxine treatment. *Acta endocrinologica*. Copenhagen, **75**, 483.
- RIEDEL, B.M.C.L. (1896) Die chronische zur Bildung eisenharter Tumoren Führende Entzündung der Schilddrüse. *Verhand der deutschen Gesellschaft für Chirurgie*, **25**, 101. (Translated in: LEVITT, T. (1954) *The Thyroid*. Churchill Livingstone, Edinburgh.)
- RIEDEL, B.M.C.L. (1896) Die chronische zur Bildung chronischer Strumitis. *Verhandlungen der deutschen Gesellschaft für Chirurgie*, **26** (1), 127. (Translated in: LEVITT, T. (1954) *The Thyroid*. Churchill Livingstone, Edinburgh.)
- RIEDEL, B.M.C.L. (1910) Über Verlauf und Ausgang der Strumitis chronica. *Münchener medizinische Wochenschrift*, **57**, 1946. (Translated in: LEVITT, T. (1954) *The Thyroid*. Churchill Livingstone, Edinburgh.)
- ROOT, A.W., ROSENFELD, R.L., BONGIOVANNI, A.M. & EBERLEIN, W.R. (1967) The plasma growth hormone response to insulin induced hypoglycemia in children with retardation of growth. *Pediatrics*, **39**, 6, 844.
- TUNBRIDGE, W.M.G., MARSHALL, J.C. & BURKE, C.W. (1973) Primary hypothyroidism presenting as pituitary failure. *British Medical Journal*, **1**, 153.
- VALLOTTON, M.B., PRETELL, J.Y. & FORBES, A.P. (1967) Distinction between idiopathic primary myxoedema and secondary pituitary hypothyroidism by the presence of circulating thyroid antibodies. *Journal of Clinical Endocrinology*, **27**, 1.
- VINCE, F.P., BOUCHER, B.J., COHEN, R.D. & GODFREY, J. (1970) The response of plasma sugar, free fatty acids, 11-hydroxycorticosteroids and growth hormone to insulin-induced hypoglycaemia and vasopressin in primary myxoedema. *Journal of Endocrinology*, **48**, 389.
- WOOLNER, L.B., MCCONAHEY, W.M. & BEAHR, O.H. (1957) Invasive fibroid thyroiditis (Riedel's struma). *Journal of Clinical Endocrinology and Metabolism*, **17**, 201.