

The anal cushions – a fresh concept in diagnosis

HAMISH THOMSON
M.S., F.R.C.S.

Gloucestershire Royal Hospital

Summary

The anal canal is lined by cushions of specialized submucosal tissue which assist the continence mechanism. Starting with that premise, its various afflictions are examined and found to be more logically related, and much more readily understood.

THE anatomy of the anal canal's interior is more complex than usually described and its special features deserve wider recognition because they help to explain the various ways in which the simple disorders to which it is prone may present.

Perhaps the most singular characteristic of the anal lining is its great vascularity. The superior rectal artery distributes on average 5 substantial branches in the anal submucosa, and others are contributed by the middle and inferior rectal vessels. What can be the purpose of such a blood supply, so much in excess, it would seem, of metabolic requirement? The answer involves an understanding of the venous system. The anal submucosal venous plexus is quite unlike any other in the body. It is distinguished by the presence of discrete sacculations which intercommunicate by means of segments of vein of normal calibre. They are normal structures, being found at birth and in all adults. Direct communications between them and the arteries have been demonstrated by serial histological section (Stelzner, Staubesand and Machleidt, 1962), latex injection (Thomson, 1975a), and radiologically (Schmidt and Staubesand, 1972; Parnaud *et al.*, 1975) and, it appears, provide a mechanism whereby they can be rendered engorged – which is presumably the purpose of the arterial profusion.

This rich submucosal vascular arrangement forms, of course, a bulky layer, but not in fact a continuous one. The vessels are grouped in 3 more or less separate masses of tissue, the anal cushions (Thomson, 1975a) which occur in the right-anterior, right-posterior and left-lateral positions. The vertical mucosal folds of Morgagni are superimposed on them and often subdivide, to a greater or lesser extent, the left-lateral and right-posterior ones. The columns of Morgagni and the cushions themselves represent

the adaptation of the thick spongy submucosa to the changing diameters of the anal canal.

The cushions are supported by a well developed arrangement of smooth muscle and elastic tissue. It emerges from the inner surface of the internal sphincter as a series of bands in 2 or 3 overlapping rows to coalesce lower down in a web-like scaffold around the dilations of the venous plexus.

The anal submucosa, then, is a specialized layer disposed in 3 main masses, capable, by virtue of the venous sacculations and their rich arterial supply, of great changes in size. Encircled by the internal and external sphincters it assists in anal closure, providing perhaps the capacity for fine adjustment of continence (Fig. 1). Acceptance of this concept of

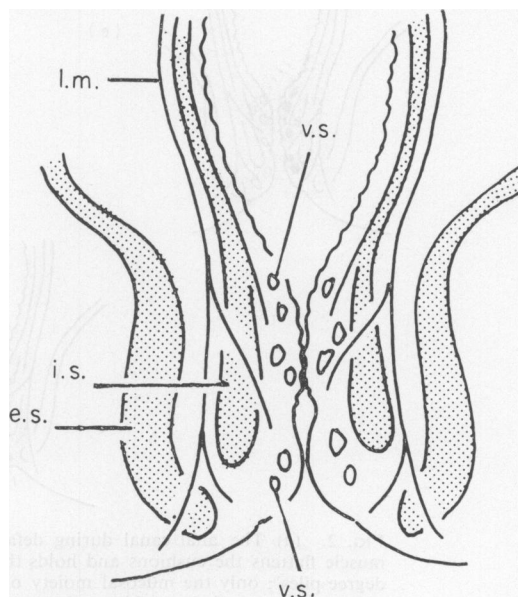


FIG. 1. A longitudinal section of the closed anal canal. The anal cushions are shown compressed together by the encircling internal (i.s.) and external (e.s.) sphincters. The venous sacculae (v.s.) and their submucosal support in the cushions are indicated. l.m. is the longitudinal muscle.

the anal lining prompts a fresh look at the various ailments which afflict it.

Normally, on defaecation the anal cushions are held out of the way by the anal submucosal muscle, whose contraction flattens and braces them against

the internal sphincter (Fig. 2a). Recurrent bleeding from them – bright red because it stems from damaged capillaries in the lamina propria, the layer immediately beneath the mucosal epithelium (Graham-Stewart, 1962) – denotes some degree of

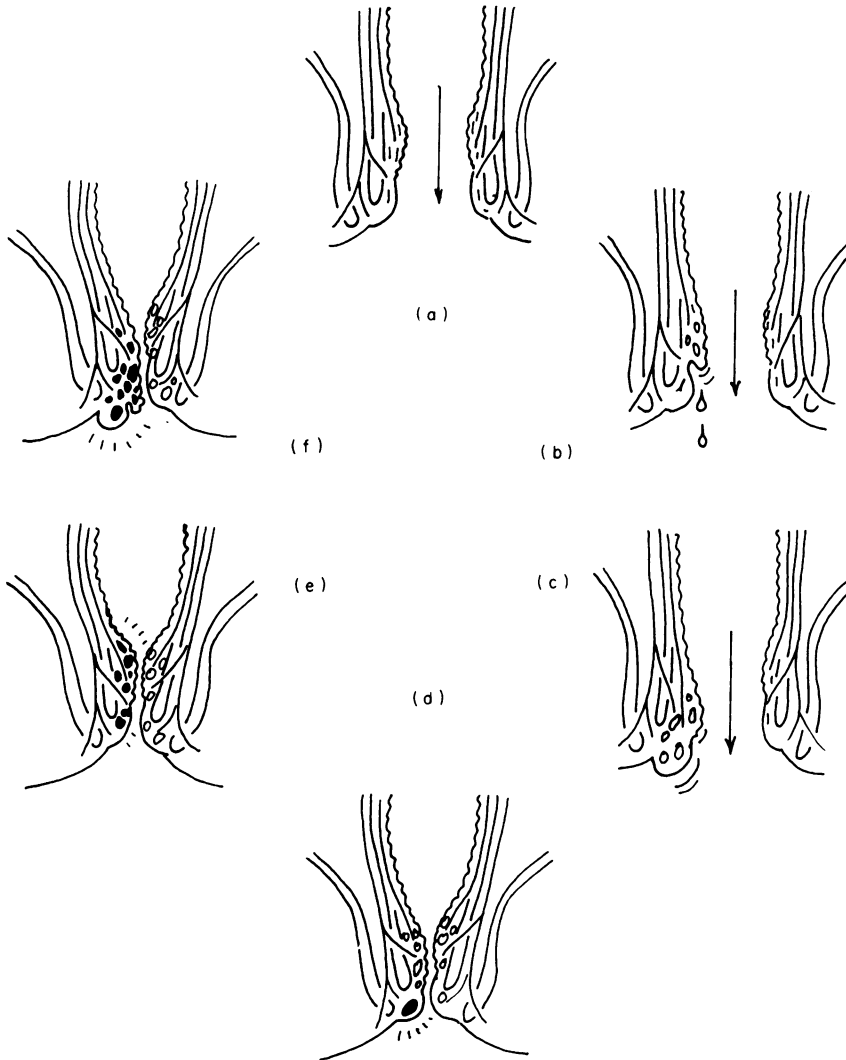


FIG. 2. (a) The anal canal during defaecation; contractions of the anal submucosal muscle flattens the cushions and holds them up against the internal sphincter. (b) 'First degree piles': only the mucosal moiety of a cushion is descending and bleeding occurs in the absence of detectable prolapse. (c) 'Second or third degree piles': the entire cushion is disrupted from its attachments. The venous saccules, no longer supported, are engorged. (d) 'Thrombosed external pile' or 'perianal hae-matoma (sic)': thrombosis has occurred in one of the venous saccules in the pecteneal moiety of a cushion, and protrudes at the anal verge. (e) Spontaneous thrombosis of a normal cushion: cases are encountered occasionally when an apparently previously normal anal cushion undergoes thrombosis. (f) 'Strangulated piles': a prolapsing cushion, ('second' or 'third degree' pile) has undergone thrombosis.

disruption of this mechanism. In the absence of detectable prolapse, it is probably due to momentary displacement during defaecation of the more lax and friable mucosal moiety, causing it to become pinched between the passing stool and the pectinate line (where the cushion is more firmly pinned down). It indicates some disintegration of the supporting tissues and constitutes 'first degree piles' (Fig. 2b). It seems possible, however, that occasional bleeding may occur owing solely to the trauma of a constipated stool.

Prolapse, or downward displacement of a cushion of whatever degree – its commonest disorder – is the condition to which we should properly confine the term 'piles'. It is the result of stresses at defaecation (Thomson, 1975b). By its Valsalva effect, excessive straining causes engorgement of the cushions so that they swell into the lumen of the reflexly relaxed anal canal. They are then subjected to the shearing effect of the passing stool (Fig. 2c). Alternatively, the passage simply of excessively hard stools would have the same result. Depending on the extent of tissue stretching and fragmentation they will either reduce spontaneously after evacuation (first degree piles), require manual replacement but stay back (second degree piles), or prolapse persistently (third degree piles). Usually only one or two cushions are affected in any individual, the right-anterior one being the commonest to occur singly. A mid-line posterior cushion is an occasional finding which on prolapse sometimes appears as a horseshoe-like bolster of tissue. Finally, in third degree piles the mucosa is often thickened and inflamed, presenting a bright red granular surface, sometimes partially replaced by squamous epithelium, whilst in other cases it may be thin, so that the venous sacculations bulge clearly underneath it.

The third phenomenon to affect the anal cushions is thrombosis. It is responsible for 3 separate clinical entities.

Firstly, it may affect one of the series of larger venous dilatations to be found under the pecten (they can easily be seen in the young simply by distracting the anus so that the pecten, the zone of smooth hairless skin between the anal verge and the pectinate line, is pulled on to the surface). It presents

as the well known but misnamed 'perianal haematoma' (or 'thrombosed external pile'), a painful dark hard lesion of sudden onset (Fig. 2d). Incision and expression of the clot will confirm its nature, revealing in a fresh case the shiny intimal lining of the venous sacculum in which it arose. Sub-pecteneal thrombosis might be a better name for it.

Secondly, it may, very rarely and apparently spontaneously, affect the entire venous plexus of a cushion which had previously seemed normal, when the patient experiences the sudden onset of anal pain, and digital examination reveals a tender swollen indurated cushion (Fig. 2e).

Thirdly, and more commonly, it may occur in a pile – in a cushion, in other words, undergoing prolapse at defaecation. It presents then as an 'attack of the piles', or 'strangulated piles' (Fig. 2f). The affected cushion swells up and protrudes painfully from the anus. It is important to understand the basic pathology and not be misguided by the second name to attempt manual replacement. The condition settles spontaneously in the course of 2 or 3 weeks and may cause sufficient tissue destruction and fibrosis to cure the pile. Occasionally a pedunculated nubbins of fibrous tissue results – a 'fibrous anal polyp'.

Thus, the anal cushions may bleed, prolapse, or thrombose. Although the lesions vary according to circumstances, consideration of the anatomical derivation in each case will usually allow logical interpretation.

References

- GRAHAM-STEWART, C.W. (1962) Injection treatment of haemorrhoids. *British Journal of Medicine*, **1**, 213.
- PARNAUD, E., GUNTZ, M., BERNARD, A. & CHOME, J. (1976) Anatomie normale macroscopique et microscopique du réseau vasculaire hémorroïdal. *Archives françaises des maladies de l'appareil digestif*, **65**, 501.
- SCHMIDT, H. & STAUBESAND, J. (1972) Der röntgenologische Nachweis des Corpus Cavernosum Recti. *Fortschritte aus den Gebiete der Röntgenstrahlen und der Nuklearmedizin*, **116**, 297.
- STELZNER, F., STAUBESAND, J. & MACHLEIDT, H. (1962) Das Corpus Cavernosum Recti. *Archiv für klinische Chirurgie*. Berlin, **299**, 302.
- THOMSON, H. (1975a) The nature of haemorrhoids. *British Journal of Surgery*, **62**, 542.
- THOMSON, H. (1975b) Piles: their nature and management. *Lancet*, **ii**, 494.