

Galactorrhoea following surgical procedures to the chest wall: the role of prolactin

I. A. MACFARLANE*
M.B., M.R.C.P.

M. D. ROSIN
M.B., F.R.C.S

The Royal Infirmary, Leicester

Summary

Normal prolactin levels were found in two cases of galactorrhoea following surgical procedures to the chest wall and one was treated successfully with bromocriptine. Studies were then carried out to test the claim that chest-wall injury is one of the common causes of hyperprolactinaemia. Serum prolactin levels were measured before and after thoracotomy in 7 patients, following traumatic rib fractures in 8 patients and after burns to the chest in one patient. No evidence was found to suggest that sustained hyperprolactinaemia follows chest wall surgery or injury, and the role of prolactin in the condition 'chest wall injury' galactorrhoea is discussed.

Introduction

During the past 30 years there have been several reports of galactorrhoea following surgery to the chest wall. These include thoracotomy incisions (Salkin and Davis, 1949; Grossman *et al.*, 1950; Berger, Joison and Braverman, 1966; Quinlan, 1968; Weir, 1971), mastectomy (Aufses, 1955) and chest trauma with lacerations (Grimm, 1955). These cases were all women, mostly Negro, who had normal periods and fertility previously. Usually both breasts became enlarged and tender within a short time after surgery. Galactorrhoea, often profuse and spontaneous, soon developed from one or both breasts and continued for several months or years. Menstruation usually continued normally.

Galactorrhoea has also followed herpes zoster of the upper thorax (Bhattacharya and Girgla, 1976), burns to the chest with keloid formation (Morley *et al.*, 1977) and several neurological disorders involving thoracic dermatomes (Relkin, 1965). In men, gynaecomastia but not galactorrhoea has been reported following thoracotomy (Camiel, Benninghoff and Alexander, 1968).

It has been suggested that stimulation of the intercostal nerves from T₂ to T₆ causes prolactin

release (Kolodney, Jacobs and Daughaday, 1972). Furthermore, chest-wall injury has been described as one of the common causes of hyperprolactinaemia (Besser and Thorner, 1976). The authors have seen 2 cases of galactorrhoea following surgery to the chest wall who had normal prolactin levels.

The first case was a 39-year-old woman who underwent mitral valve replacement in 1972. Two days after the operation she developed painful, enlarged breasts and profuse galactorrhoea. The galactorrhoea continued for 5 years and in 1977 endocrine assessment revealed a normal serum prolactin and no other cause for her lactation. Bromocriptine 5 mg/day soon abolished the galactorrhoea and breast engorgement but both returned within days of stopping the drug 6 months later. The second case was a 14-year-old girl who developed painful breasts and bilateral, copious galactorrhoea a few weeks after a dermabrasion operation to remove tattoos from both breasts and shoulders. The galactorrhoea gradually diminished but was still present 7 years later. Her serum prolactin was normal on several occasions. In both patients, menstruation continued regularly during the galactorrhoea.

In view of the normal prolactin levels in these 2 cases and because there have been no studies of the changes in prolactin following chest wall injury, the prolactin was measured in patients after rib fractures, undergoing thoracotomy and after chest burns.

Patients studied

Thoracotomy patients

Seven patients (aged 35-70 years) undergoing thoracotomy were studied (4 female). Two were mitral valvotomies through the left 5th intercostal space; two led to pneumonectomy for carcinoma of lung through the 5th intercostal space; one was an exploratory thoracotomy through the 5th space and inoperable cancer was found; and one was a pleurectomy through the 6th space. Intercostal drains were left *in situ* in all patients for several days.

* Present address: Department of Medicine, Royal Infirmary, Manchester M13 9WL.

Rib fracture patients

Eight patients (32–84 years; 6 male) brought into Casualty were studied. All patients had displaced fractures involving one or more ribs from the 2nd to the 6th rib inclusive. Four patients had 5 or more ribs fractured, all of which were displaced and required intercostal drains to be inserted.

Burns patient

A 25-year-old man sustained burns to most of his upper arms, his neck and the front and back of his chest. Half the burnt area required skin grafts on several occasions over the next 2 months.

Methods

In the thoracotomy group, blood was taken for serum prolactin estimation at: 24 hr pre-operation; 30 min after skin incision; the following morning; 48 hr post-operation; one week post-operation; and in 3 cases 2 weeks post-operation. In the rib fracture group, blood was taken: on admission to Casualty; 24 hr after admission; 48 hr after admission; and one week after admission. In the burns case, blood was taken: on admission; 24 hr; 48 hr; then at weekly intervals for 4 weeks. Samples were spun, separated and stored at -20°C . Serum prolactin level was measured by double antibody radio-immunoassay and standardized against MRC 71/222, IRP, the normal range being up to 500 mu./l. All samples from the same patient were measured in the same assay.

Results

Thoracotomy patients

In this group prolactin levels were greatly increased 30 min into operation but by 24 hr had fallen and at 48 hr were not significantly elevated from the pre-operative levels (Fig. 1). The mean levels

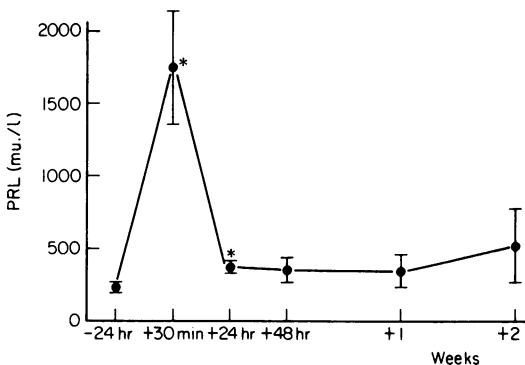


FIG. 1. Mean serum prolactin levels (PRL) in 7 thoracotomy patients (± 1 s.e. mean). * Denotes a significant elevation from pre-operative levels ($P < 0.02$).

at one week and 2 weeks (390 mu./l and 583 mu./l) were not significantly elevated above pre-operative levels.

Rib fracture patients

On admission the mean prolactin level was 709 mu./l. By 48 hr the mean level was within the normal range (474 mu./l) and at one week was 501 mu./l (Fig. 2).

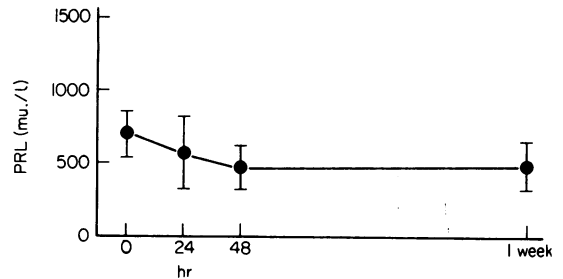


FIG. 2. Mean serum prolactin levels (PRL) in 8 rib fracture patients (± 1 s.e. mean).

Burns patient

This patient's elevated serum prolactin level on admission (1250 mu./l) fell to normal (150 mu./l) within 24 hr. It remained within the normal range for the next month except at 3 weeks. However, he had undergone skin grafting 18 hr previously (Fig. 3).

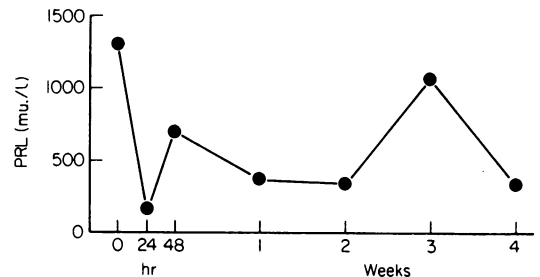


FIG. 3. Serum prolactin levels (PRL) in a 25-year-old man with severe chest burns.

Discussion

Although the number of patients studied was small, the data suggest that sustained hyperprolactinaemia is not commonly associated with thoracotomy or chest wall injuries. The high levels seen during operation and on admission in the fracture and burns cases are compatible with the acute elevations of prolactin associated with stress

as has been shown in several studies (Noel *et al.*, 1972; Sowers *et al.*, 1977; Koninckx, 1978). In the previously reported cases of galactorrhoea due to chest-wall injury, few had prolactin levels measured. In one case with sustained, moderate hyperprolactinaemia there was also amenorrhoea (Morley *et al.*, 1977). In 2 other cases prolactin levels were normal in one and slightly elevated in the other (Boyd, Reichlin and Turksoy, 1977).

Lactation has also been reported following abdominal operations including hysterectomy (Sheld and Charme, 1969), cholecystectomy and laparotomy (Lavoie, 1968). Clinically, these cases were similar to the 'chest wall injury' patients but obviously the galactorrhoea could not be explained by thoracic nerve irritation.

Several hormones are necessary for the development of the normal breast, mainly oestrogen, progesterone and prolactin (Frantz, 1978). Other hormones are probably involved. During pregnancy the breast is primed with oestrogen, progesterone and other hormones. The combination of high levels of prolactin and a sudden fall of oestrogen and progesterone at birth stimulates lactation. In non-puerperal lactation, associated with a normal menstrual cycle, many studies have shown that prolactin levels are normal in a large proportion of cases (Kleinberg, Noel and Frantz, 1977). Grossly elevated prolactin levels, however, are not necessarily accompanied by galactorrhoea and patients who have very high prolactin levels and galactorrhoea often have an irregular menstrual cycle.

Thus, the authors believe that persistent hyperprolactinaemia is not the cause of the galactorrhoea that occasionally complicates chest wall injury. It is possible that 'chest wall injury' galactorrhoea only occurs in those individuals whose breasts have been previously primed with oestrogen and progesterone. In these cases sudden peaks of prolactin induced by the stress of surgery or chest trauma initiate lactation which continues despite the presence of normal serum prolactin levels.

Acknowledgments

We wish to thank the staffs of the Cardiothoracic Unit, Groby Road Hospital, Leicester, and the Casualty Department, Royal Infirmary, Leicester, for access to their patients; Dr F.D. Rosenthal and Dr T.J. Davies for advice and criticism. We are indebted to Dr S.M. Shalet and Dr C.G. Beardwell for advice on the preparation of this manuscript, Dr M. Palmer for statistical analysis, the Guildford S.A.S. centre for the prolactin estimations and Mrs A. Hurst for typing.

References

- AUFSES, A.H. (1955) Abnormal lactation following radical mastectomy. *New York State Journal of Medicine*, **55**, 1914.
- BERGER, R.L., JOISON, J. & BRAVERMAN, L.E. (1966) Lactation after incision on the thoracic cage. *New England Journal of Medicine*, **274**, 1493.
- BESSER, G.M. & THORNER, M.O. (1976) Bromocriptine in the treatment of the hyperprolactinaemia-hypogonadism syndromes. *Postgraduate Medical Journal*, **52** (Suppl. 1), 64.
- BHATTACHARYA, S.K. & GIRGLA, H.S. (1976) Lactation associated with herpes zoster pectoralis. *Journal of Tropical Medicine and Hygiene*, **79**, 94.
- BOYD, A.E., REICHLIN, S. & TURKSOY, R.N. (1977) Galactorrhea-amenorrhea syndrome. Diagnosis and therapy. *Annals of Internal Medicine*, **87**, 165.
- CAMIEL, M.R., BENNINGHOFF, D.L. & ALEXANDER, L.L. (1968) Gynecomastia after incision on the thoracic cage. *Annals of Thoracic Surgery*, **5**, 42.
- FRANTZ, A.G. (1978) Prolactin. *New England Journal of Medicine*, **298**, 201.
- GRIMM, E.G. (1955) Non-puerperal galactorrhea. *Quarterly Bulletin of Northwestern University Medical School*, **29**, 350.
- GROSSMAN, S., BUCHBERG, A.S., BRECHER, E. & HALINGER, L.M. (1950) Idiopathic lactation following thoracoplasty. *Journal of Clinical Endocrinology*, **10**, 729.
- KLEINBERG, D.L., NOEL, G.L. & FRANTZ, A.G. (1977) Galactorrhea: a study of 235 cases, including 48 with pituitary tumors. *New England Journal of Medicine*, **296**, 589.
- KOLODNEY, R.C., JACOBS, L.S. & DAUGHADAY, W.H. (1972) Mammary stimulation causes prolactin secretion in non-lactating women. *Nature*. London, **238**, 284.
- KONINCKX, P. (1978) Stress hyperprolactinaemia in clinical practice. *Lancet*, **i**, 273.
- LAVOIE, J. (1968) Lactation after surgery. *Canadian Journal of Surgery*, **11**, 464.
- MORLEY, J.E., DAWSON, M., HODGKINSON, H. & KALK, W.J. (1977) Galactorrhea and hyperprolactinemia associated with chest wall injury. *Journal of Clinical Endocrinology and Metabolism*, **45**, 931.
- NOEL, G.L., SUH, H.K., STONE, J.G. & FRANTZ, A.G. (1972) Human prolactin and growth hormone release during surgery and other conditions of stress. *Journal of Clinical Endocrinology and Metabolism*, **35**, 840.
- QUINLAN, J.J. (1968) Lactation following thoracotomy. *Canadian Journal of Surgery*, **11**, 60.
- RELKIN, R. (1965) Galactorrhea. A review. *New York State Journal of Medicine*, **65**, 2800.
- SALKIN, D. & DAVIS, E.W. (1949) Lactation following thoracoplasty and pneumonectomy. *Journal of Thoracic Surgery*, **18**, 580.
- SHELD, H.H. & CHARME, L.S. (1969) Non-puerperal galactorrhea following hysterectomy. *New York Journal of Medicine*, **69**, 590.
- SOWERS, J.R., RAJ, R.P., HERSHMAN, J.M., CARLSON, H.E. & MCCALLUM, R.W. (1977) The effect of stressful diagnostic studies and surgery on anterior pituitary hormone release in man. *Acta endocrinologica*, **86**, 25.
- WEIR, J.H. (1971) Post-thoracotomy galactorrhea successfully treated with clomiphene citrate. *American Journal of Obstetrics and Gynecology*, **111**, 106.