

CASE REPORTS

**Bronchiectasis and Marfan's syndrome**

M. E. FOSTER  
M.B., B.Chir.

D. R. FOSTER\*  
F.R.C.R.

*Departments of Cardio-thoracic Surgery and \*Radiology, University Hospital of Wales, Cardiff*

**Summary**

Marfan's syndrome is a rare hereditary disorder characterized by skeletal, cardiovascular and ocular abnormalities. Pulmonary abnormalities occur in approximately 10% of patients, the commonest being spontaneous pneumothorax and emphysema. A patient is described who had Marfan's syndrome and bronchiectasis, an association only described on 2 previous occasions in the literature.

A 39-year-old factory worker presented with a history of persistent cough and purulent sputum since childhood. He was a non-smoker with no relevant family history. He had marked clubbing of fingers and toes. Examination of the chest revealed bilateral basal crepitations.

Chest radiography demonstrated extensive cystic bronchiectasis of the left lower lobe. This was confirmed by bilateral bronchography (Fig. 1) which also showed minor changes on the right side.

The patient was tall and thin with a depressed sternum and high arched plate. Examination of the cardiovascular systems was normal whilst ECG showed right axis deviation. Ophthalmoscopy showed no ectopia lentis.

Metacarpal index of 9.2 was in the range for Marfan's syndrome (Fig. 2). The patient underwent left lower lobectomy. There was gross bronchiectasis with numerous cystic cavities, confirmed on histological examination. The patient made an uneventful post operative recovery

**Discussion**

The diagnosis of Marfan's syndrome in this patient is based on the presence of characteristic skeletal features with a high metacarpal index. Cardiovascular and ocular abnormalities were not clinically evident but are not essential for diagnosis.

Pulmonary abnormalities occur in approximately 10% of patients with Marfan's syndrome, the most

common being spontaneous pneumothorax and generalized emphysema (Dwyer and Trowcale, 1965). Other complications include cystic disease (Oswald and Parkinson, 1945), pulmonary malformation (Van

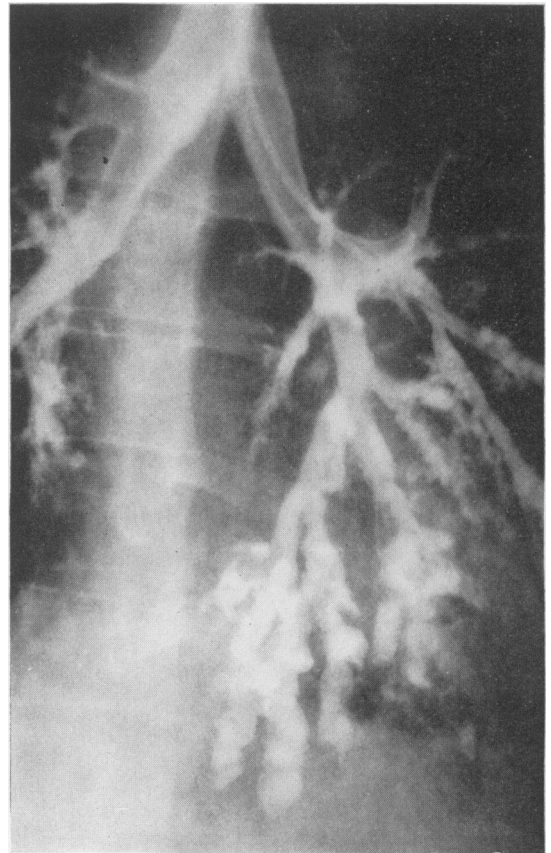


FIG. 1. Bronchogram showing bilateral cystic bronchiectasis particularly involving the left lower lobe.

Buchem, 1958) and an increased susceptibility to pneumonia (Green and Emerson, 1943).

Bronchiectasis in Marfan's syndrome was first described by Katz (1952). He recorded a 24-year-old male with the typical osseous and cardiac manifestations, including a depressed sternum and evidence of aortic incompetence. He also had extensive bilateral cystic bronchiectasis, confirmed by bronchography. Katz postulated that the bronchiectasis in this case was either due to an intrinsic bronchial defect present in Marfan's syndrome or related to the high incidence of recurrent respiratory infection in patients with thoracic cage deformity.

Teoh (1977) described a Chinese girl with Marfan's

syndrome complicated by spontaneous pneumothorax and bilateral cystic bronchiectasis. He suggested that these were separate pulmonary manifestations of the syndrome since pneumothorax is seldom reported as complicating bronchiectasis.

In a review of pulmonary disease in Marfan's syndrome, Turner and Stanley (1976) postulated that the occurrence of pneumothorax and emphysema was related to weakness in the pulmonary connective tissue framework.

Although it is difficult to exclude coincidental bronchiectasis in a patient with Marfan's syndrome, it appears likely that bronchiectasis represents an additional pulmonary complication of the syndrome.

Bronchiectasis has been described in a number of other congenital abnormalities, the most well known being Kartagener's syndrome of bronchiectasis, dextrocardia and sinusitis or absent frontal sinuses. Other rare associations include congenital absence of bronchial cartilage, congenital heart disease and congenital kyphoscoliosis. The association of bronchiectasis with Marfan's syndrome can now be added to the literature.

#### Acknowledgments

We wish to thank Mr E.G. Butchart, Consultant Cardio-Thoracic Surgeon, for permission to report a patient under his care.

#### References

- DWYER Jr, E.M. & TROWCALE, F. (1965) Spontaneous pneumothorax and pulmonary disease in Marfan's syndrome. *Annals of Internal Medicine*, **62**, 1285.
- GREEN, H. & EMERSON, P.W. (1943) Arachnodactylia. *Archives of Pediatrics*, **50**, 299.
- KATZ, H.L. (1952) Thoracic manifestation in Marfan's syndrome (arachnodactyly). *Quarterly Bulletin of Sea View Hospital*, **13**, 95.
- OSWALD, N. & PARKINSON, T. (1949) Honeycomb lungs. *Quarterly Journal of Medicine*, **18**, 1.
- TEOH, P.C. (1977) Bronchiectasis and spontaneous pneumothorax in Marfan's syndrome. *Chest*, **72**, 672.
- TURNER, J.A. McM. & STANLEY, N.N. (1976) Fragile lung in the Marfan syndrome. *Thorax*, **31**, 771.
- VAN BUCHEM, F.S.P. (1958) Cardiovascular disease in arachnodactyly. *Acta medica Scandinavica*, **161**, 197.

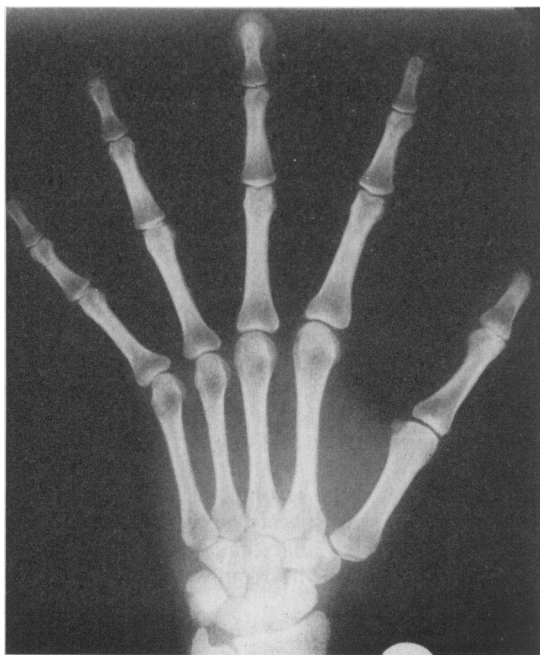


FIG. 2. Radiograph of hand showing arachnodactyly.