

Cholestatic jaundice: an immune response to prajmalium bitartrate

HESCHI H. ROTMENSCH*
M.D.

MEIR LIRON*
M.D.

ISRAEL YUST**
M.D.

AVRAHAM KLEJMAN†
M.D.

ELLA LIVNI‡
Ph.D.

TAMI MOALEM†
M.Sc.

ALEXANDER GEFEL*
M.D.

*Tel-Aviv Municipal-Governmental Medical Center, *Rokach Hospital, Department of Medicine E; **Ichilov Hospital, Department of Medicine B; †Immunological Laboratories, Meir Hospital, Kfar Saba; ‡Laboratory of Cellular-Immunology, Beilinson Hospital, Petach Tikva, and the Sackler School of Medicine, Tel-Aviv University*

Summary

Cholestatic jaundice associated with chills, pruritus and blood eosinophilia developed in a patient who received prajmalium bitartrate therapy for ventricular arrhythmia following acute myocardial infarction. Discontinuation of the drug resulted in a spontaneous improvement in the clinical and biochemical findings. Challenge by prajmalium bitartrate caused rapid reappearance of the clinical and biochemical features.

In immunological studies, deposits of IgG and IgA were detected at the bile canaliculi by fluorescent staining, and the patient's lymphocytes produced macrophage migration inhibition after *in vitro* incubation with prajmalium bitartrate. Thus, laboratory results support the assumption of an allergic mechanism.

Introduction

Prajmalium bitartrate (N-propyl ajmaline hydrogen tartrate, NPAB) is a highly effective antiarrhythmic agent (Bussmann *et al.*, 1978). In addition to its direct effects on the cardiovascular system, cholestatic jaundice is a well documented complication of this agent (Buscher *et al.*, 1976; Lindner, Weber and Kloeppe, 1976). It appears within 10 to 18 days after the first dose in a non-sensitized person, and disappearance of the clinical and biochemical signs is the rule after withdrawal of the medication.

The pathogenic mechanisms involved in drug-induced cholestasis are not well understood and little immunological information is available.

The present report is of a case of cholestatic jaundice induced by NPAB, in which there is evidence of the involvement of immune mechanisms.

Case report

A 50-year-old male was admitted with an acute myocardial infarction. His hospital course was unremarkable, except for multiple ventricular premature beats which were successfully treated by *i.v.* ajmalin, 0.6 mg/min, and then by maintenance oral NPAB 80 mg/day.

Twenty days after the initiation of NPAB the patient was again admitted suffering from extreme malaise, shaking chills, pruritus, nausea and vomiting. Jaundice was noted shortly afterwards. There was no history of previous gall bladder disease, drug intolerance, rash, arthritis, exposure to viral hepatitis, and alcohol abuse. Physical examination revealed mild jaundice, body temperature 37.5°C, and was otherwise normal. The pertinent laboratory results are depicted in Fig. 1. Hepatitis B surface antigen (HB_sAG) was negative. The chest X-ray and oral cholecystogram were unremarkable. Since an adverse reaction to NPAB was suspected, this medication was discontinued. During the subsequent days the patient's condition improved markedly, and all evidence of hepatic injury subsided (Fig. 1). On the 12th hospital day, a liver biopsy was performed showing an inflammatory infiltration in the portal spaces and mild proliferation of marginal bile ductules with portal fibrosis (Fig. 2).

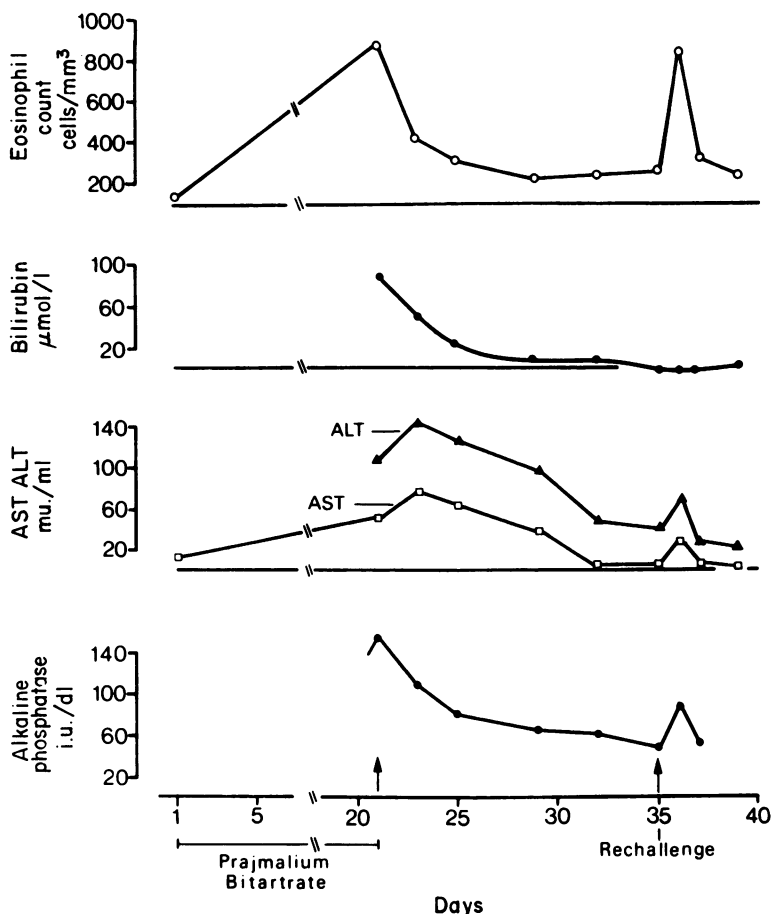


FIG. 1. Pertinent laboratory data during the course of cholestatic jaundice and rechallenge. AST - aspartate aminotransferase (normal range, 5-40 mu./ml); ALT - alanine aminotransferase (normal range, 5-40 mu./ml); alkaline phosphatase (normal range, 20-80 i.u./dl).

With the patient's informed consent a re-challenge test and immunological studies were performed.

Ten hr after a single oral dose of 20 mg NPAB the patient experienced profound weakness and anorexia. A concomitant rise in alkaline phosphatase, alanine aminotransferase (ALT) and the eosinophil count was observed (Fig. 1). Forty-eight hours later all laboratory tests returned to normal.

Immunological studies

Cellular Responses

Macrophage migration inhibition factor (MIF) assay against NPAB was performed by interacting the patient's lymphocytes with macrophages of normal guinea-pigs according to the method of Rajapakse and Glynn (1970). Concentrations of 5, 10, 25, 50 and 100 μg NPAB/ml of culture were tested. This test was also performed in 5 patients

who had received NPAB for a prolonged period without evidence of adverse effects.

As indicated by the Migration Index of 0.72 the patient's lymphocytes produced significant migration inhibition in the presence of 25 $\mu\text{g}/\text{ml}$ NPAB. The tests were negative in the controls.

Lymphocyte stimulation test was first performed against phytohaemagglutinin, Concanavalin A and Pokeweed mitogen and then against NPAB at concentrations of 0.1, 1.0, 5.0, 10.0 and 20.0 $\mu\text{g}/\text{ml}$ using a method described by Douglas (1972). No sensitization was observed on exposure to NPAB, while the response to the mitogens was normal.

Humoral Responses

Levels of immunoglobulins and complement components C_3 , C_4 , CH_{50} were within normal limits.

Antibodies to smooth muscle and mitochondria

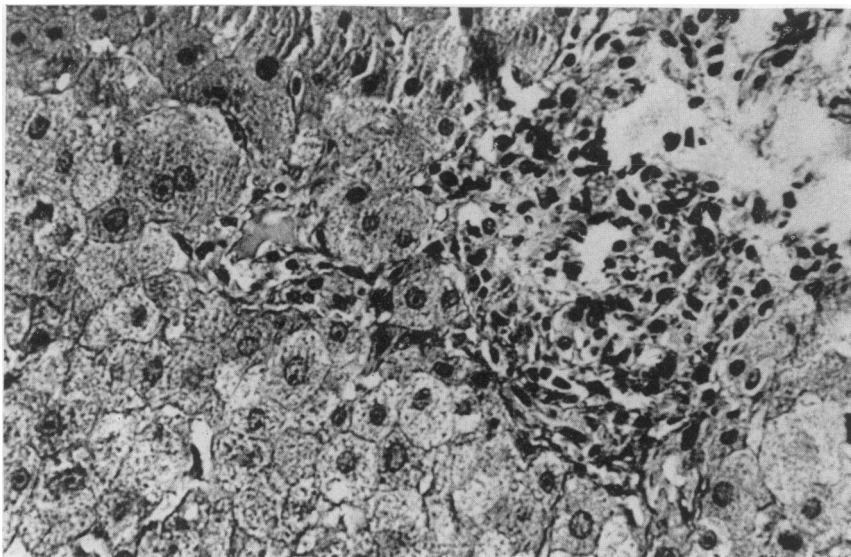


FIG. 2. Liver biopsy showing inflammatory infiltration in portal spaces and mild proliferation of marginal bile ductules (HE, $\times 160$).

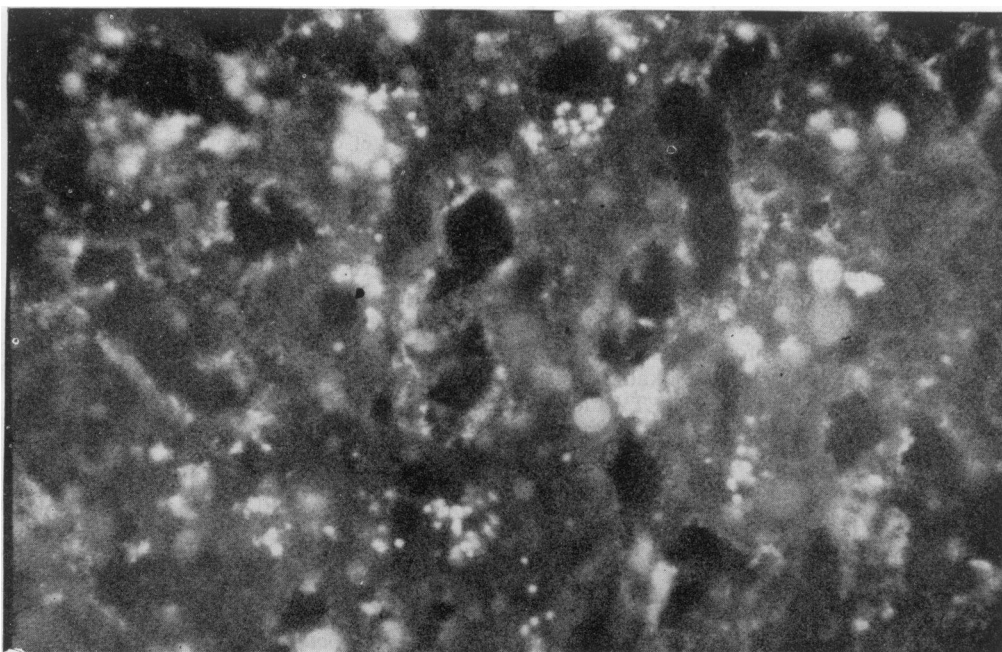


FIG. 3. Granular deposits of IgG are seen along the bile canaliculi (staining with fluorescein-conjugated antihuman IgG, $\times 320$).

were not detected; antinuclear factor, anti-DNA and lupus erythematosus preparations were negative.

Indirect mast cell degranulation test was performed by incubating mast cells from normal rats with human serum (patient and control) and the antigen as previously described (Dreyfuss *et al.*, 1965). The patient's serum did not cause significant degranulation of mast cells in the presence of NPAB in concentrations of 1.25, 2.5 and 5.0 mg/ml.

The presence of immune-precipitates and complement in the patient's liver sections was investigated using fluorescein-conjugated goat antiserum to human IgG, IgM, IgA and C₃ as described by Myers *et al.*, (1973). Three biopsies from normal livers taken at operations were examined as controls. Immunofluorescent staining of the patient's liver tissue revealed IgG and IgA deposits at the bile canaliculi, while no precipitates were demonstrated in the control tissues.

Discussion

Little is known about the mechanism of cholestasis associated with a chemical. Drug-induced alterations in bile salt metabolism have been demonstrated (Campbell *et al.*, 1977) but it remains unproved whether these findings are the cause or the effect of the cholestasis. Recently, Samuels and Carey (1978) postulated that the pathogenesis of chlorpromazine (CPZ) cholestasis in man may relate in some way to the intrinsic membrane-toxic properties of CPZ or its metabolites.

In the case presented, clinical features indicate that the liver damage may be attributed to a hypersensitivity syndrome rather than to direct hepatic toxicity, since allergic manifestations such as fever, chills, and eosinophilia were associated with the cholestasis, and challenge with a small dose of NPAB resulted in reappearance of the clinical and biochemical features. The *in vitro* inhibition of macrophage migration by NPAB indicates that the patient's lymphocytes had become sensitized to that drug as compared to controls. The presence of immune precipitates at the bile canaliculi suggests a possible humoral immunological process, such as antibodies towards a hapten bound to proteins or the hapten-protein complex, or an immune complex disease.

It may be speculated that structural alterations of bile canaliculi, such as those previously demonstrated by electron-microscopy in association with phenothiazine cholestasis (Perez, Schaffner and Popper, 1972), are the result of a localized immune reaction which subsequently alters bile salt composition.

Although the exact immunological sequence of

events remains to be elucidated, the data support the view that the clinical and histopathological features of cholestasis following the administration of NPAB were possibly mediated by immunopathogenic mechanisms.

Acknowledgment

We are grateful to Professor Bahar (Ichilov Hospital, Tel-Aviv) for the histopathological sections and their interpretation, to Mr Boris Tartakovsky (Weizmann Institute, Rehovot) for performing the lymphocyte stimulation test and to Mrs N. Vardinon (Department of Immunology, Tel-Aviv University) for performing the indirect mast cell degranulation test.

Addendum

Since the preparation of this paper the authors had the opportunity to observe another patient who developed cholestatic jaundice following the administration of NPAB. Immunofluorescent staining of the patient's liver tissue demonstrated IgG, IgM and IgA deposits at the bile canaliculi, while the MIF test in the presence of the drug was negative.

References

- BUSCHER, H.P., TALKE, H., RADEMACHER, H.P., GESSNER, U., OEHLERT, W. & GEROK, W. (1976) Intrahepatic cholestasis due to N-propyl-ajmaline. *Deutsche medizinische Wochenschrift*, **101**, 699.
- BUSSMANN, W.D., MÜLLER, E., HANEL, H.J. & KALTENBACH, M. (1978) Orally administered prajmalium bitartrate in acute and chronic ventricular arrhythmias. *American Journal of Cardiology*, **41**, 577.
- CAMPBELL, C.B., MCGUFFIE, C., WEEDON, A.P. & POWELL, L.W. (1977) Cholestatic liver disease associated with diphenylhydantoin therapy. Possible pathogenic importance of altered bile salt metabolism. *American Journal of Digestive Diseases*, **22**, 255.
- DOUGLAS, S.D. (1972) Electronmicroscopic and functional aspects of human lymphocytes response to mitogens. *Transplantation Reviews*, **11**, 39.
- DREYFUSS, F., HELLMAN, M., KLOPSTOCK, A., SCHWARTZ, J. & VARDINON, N. (1965) The basophil degranulation test in patients hypersensitive to drugs. *Acta allergologica*, **21**, 17.
- KLAJMAN, A. (1973) Membrano-proliferative glomerulonephritis associated with persistent viral hepatitis. *American Journal of Clinical Pathology*, **60**, 222.
- LINDNER, H., WEBER, D. & KLOEPEL, G. (1976) Prajmalium bitartrate-induced liver damage. *Deutsche medizinische Wochenschrift*, **101**, 1876.
- MYERS, B.D., GRIFFEL, B., NAVEH, D., JANKIELOVITZ, T. & KLAJMAN, A. (1973) Membrano-proliferative glomerulonephritis associated with persistent viral hepatitis. *American Journal of Clinical Pathology*, **60**, 222.
- PEREZ, V., SCHAFFNER, F. & POPPER, H. (1972) Hepatic drug reactions. *Progress in Liver Diseases*, **4**, 597.
- RAJAPAKSE, D.A. & GLYNN, L.E. (1970) Macrophage migration inhibition test using guinea-pig macrophages and human lymphocytes. *Nature*. London, **226**, 857.
- SAMUELS, A.M. & CAREY, M.C. (1978) Effects of chlorpromazine hydrochloride and its metabolites on Mg²⁺- and Na⁺, K⁺-ATPase activities of canalicular enriched rat liver plasma membranes. *Gastroenterology*, **74**, 1183.