

Peritoneal biopsy for diagnosis of abdominal tuberculosis

H. S. SHUKLA*
M.S., F.R.C.S.

S. BHATIA†
M.B. B.S.

Y. P. NAITRANI*
M.S.

PRITAM DAS*
M.S., F.R.C.S.

S. C. GUPTA†
M.D., F.R.C.Path.

*Departments of *Surgery and †Pathology, M.L.N. Medical College, Allahabad*

Summary

Eighty-eight patients with abdominal tuberculosis were studied for the diagnostic value of peritoneal biopsy. Peritoneum for biopsy was obtained during laparotomy in 41 cases and by making a small incision in the right iliac fossa, under local anaesthesia, in 47 cases. In 80% histopathological examination revealed caseation or giant cells and epithelioid cell infiltration. In 20% non-specific inflammatory changes were present. Thus, histopathological examination of the peritoneum was helpful in the diagnosis of abdominal tuberculosis in all the 88 patients.

Introduction

Histopathological or bacteriological proof of abdominal tuberculosis is mandatory for diagnosis, owing to the prolonged nature of antituberculous treatment and for differentiation from other granulomatous diseases. But accurate diagnosis of abdominal tuberculosis continues to be difficult (Bockus, 1964; Das and Shukla, 1975) in spite of a declining incidence (Das and Shukla, 1976). The diagnostic usefulness of peritoneal biopsy has been examined in known cases of abdominal tuberculosis.

Methods

Patients with abdominal tuberculosis admitted to the SRN Hospital, Allahabad, were examined by peritoneal biopsy. Those who presented with intestinal obstruction were subjected to laparotomy by right paramedian or mid-line incision. A 2- to 3-cm piece of parietal peritoneum was excised from the laparotomy incision for histopathological examination. In the remainder, open peritoneal biopsy was performed. In these cases a small incision was made in the right iliac fossa, under local anaesthesia, exposing the peritoneum and a

2- to 3-cm piece removed for histopathological examination. This procedure was also done in ascitic cases. At the time of peritoneal biopsy, the condition of the terminal ileum and caecum was noted, but no other procedure was done. The peritoneum and muscle layers were closed with chromic catgut suture material in layers, and the skin with interrupted linen. In the postoperative period, oral liquid feeds were allowed after 6 to 8 hr. There were no complications of this open peritoneal biopsy procedure.

Patients

There were 57 females (65%) and 31 males (35%). The predominant age group was 21-30 years (45%) followed by 11-20 years (25% cases). The mean age was 29.2 years with a range of 3 to 56 years.

Results

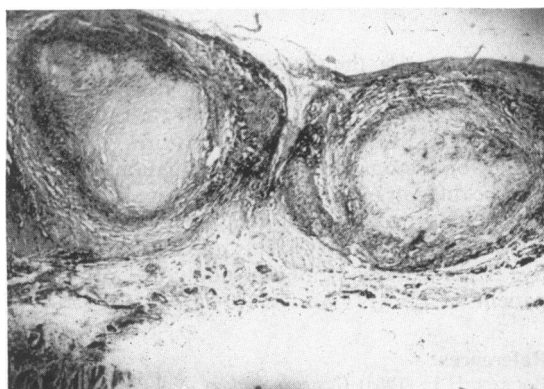
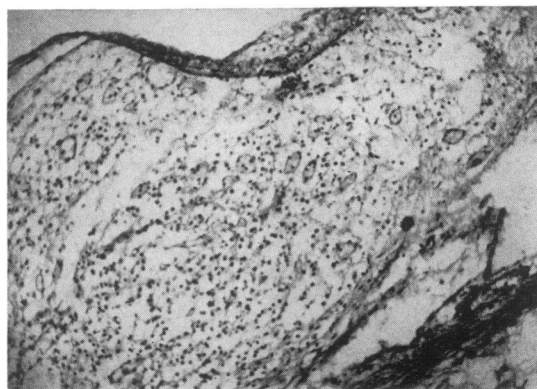
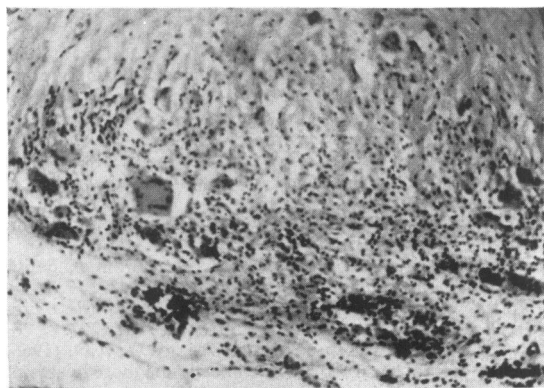
Various types of abdominal tuberculous lesions are shown in Table 1. A gut lesion was always considered dominant although concomitant mesenteric adenitis and peritoneal tubercles were also found. The clinical presentation of these patients has already been described (Das and Shukla, 1976).

Forty-four of 47 having peritoneal biopsies had non-enteral tuberculosis affecting: the mesenteric lymph nodes in 14; the peritoneum in 16; and giving ascites in 14 cases. In contrast, peritoneal biopsy at the time of laparotomy was done in 41 cases with intestinal obstruction in 33, an abdominal mass in 4, and for exploration in 4 cases (Table 1).

The histopathological findings in the peritoneum showed three types of changes: (i) caseation necrosis (Fig. 1); (ii) Langhans-type giant cells and epithelioid cells (Fig. 2); (iii) non-specific inflammatory changes

TABLE 1. Types of tuberculous lesion and mode of peritoneal biopsy

Lesions	No. of cases (males)	Open peritoneal biopsy	Laparotomy biopsy
Ileo-caecal	9 (6)	0	9
Small bowel stricture	22 (8)	3	19
Mesenteric lymphadenitis	18 (4)	14	4
Tuberculous peritonitis	25 (7)	16	9
Ascitic tuberculous peritonitis	14 (6)	14	0
Total	88	47	41

FIG. 1. Open peritoneal biopsy showing tuberculous granuloma with caseation necrosis (HE, $\times 28$).FIG. 3. Open peritoneal biopsy showing increased vascularity, round cell infiltration and mesothelial hyperplasia (HE, $\times 70$).FIG. 2. Open peritoneal biopsy showing foreign body giant cell, round cell infiltration, and fibrosis tissue formation (HE, $\times 70$).

(Fig. 3). In none of the patients was the peritoneum normal. In 18 patients who had received antituberculous treatment for 1–3 months, caseation necrosis was found in 2, giant cells and epithelioid cells in 6 and non-specific histopathological change in 10. Thus more than 50% of the patients showing

non-specific histopathological change had prior treatment with antituberculous drugs. There was a definite association between a particular peritoneal histopathology and clinical type of abdominal tuberculosis (Table 2). Thus, in patients with ascitic tuberculous peritonitis, there was specific tuberculous histopathology in all; but in those with intestinal and mesenteric lymph node tuberculosis, non-specific changes were found in more than 33%.

Discussion

Confirmation of the diagnosis may be the main problem in the management of abdominal tuberculosis. There are no diagnostic clinical features (Hoon, Dockerty and Pemberton, 1950) and a greater awareness on the part of the clinician will lead to accurate clinical diagnosis in only 50% of cases. (Leading Article, 1977). Diminishing incidence of tuberculosis (Bockus, 1964), similarity with Crohn's disease (Hoon *et al.*, 1950; Tandon and Prakash, 1972) and the variability of tuberculous abdominal lesions (Shukla and Hughes, 1978) may lead to further difficulty in diagnosis. Yet confirmation of diagnosis is essential for administration of antituberculous treatment with the exception of concomitant pulmonary tuberculosis (Das and

TABLE 2. Histopathological findings on peritoneal biopsy in 88 patients with abdominal tuberculosis

	Caseation No.	Giant cell epithelioid cells No.	Non-specific inflammation No
Ileo-caecal tuberculosis	1	5	3
Small bowel stricture	3	13	6
Mesenteric lymphadenitis	3	9	7
Tubercular peritonitis	13	10	2
Ascitic tuberculous peritonitis	10	3	0
Total	30	40	18

Shukla, 1976; Hoon *et al.*, 1950; Sharma, Kala and Bhargawa, 1972).

In the absence of a specific immunological response to the tubercle bacillus and with the inaccuracy of radiological contrast studies in many cases (Hoon *et al.*, 1950), therapeutic confirmation of the diagnosis by administration of antituberculous treatment has been advocated (Logan, 1969). However, it has two main drawbacks: (i) the absence of response may be due to infection by a resistant strain of mycobacteria (Das and Shukla, 1975); and (ii) in truly tuberculous cases, differentiation from Crohn's disease will be difficult on subsequent abdominal exploration (Tandon and Prakash, 1972).

The diagnostic value of punch peritoneal biopsy has varied from 24 to 42% in India (Mehrotra, Mathur and Agarwal, 1966; Jain *et al.*, 1964; Sarin, Mehta and Sarin, 1961). Over 80% diagnostic accuracy of open peritoneal biopsy in this study is due to the availability of adequate peritoneal tissue for examination. With needle biopsy, adequate tissue is not obtained in 7% of ascitic to 36% of non-specific cases (Mehrotra *et al.*, 1966; Sarin *et al.*, 1961), although in ascitic tuberculosis, 100% accuracy of needle biopsy may be obtained (Levine, 1967). Mehrotra *et al.* (1966) demonstrated the limitations of punch peritoneal biopsy in one case where first biopsy showed normal peritoneum but an open biopsy at the time of operation showed tuberculous changes, emphasizing that adequate tissue examination will give better results. Non-specific inflammatory changes of peritoneum, consisting of increased vascularity and mesothelial hyperplasia were considered tuberculous and were found in 43% of their cases of abdominal tuberculosis by Mehrotra (1966). Das and Shukla (1975) found non-specific changes in 37%. In the present series, 20% showed non-specific changes, which were more common if the patient had received previous antituberculous treatment.

Availability of representative tissue at the outset

is important for the diagnosis of abdominal tuberculosis by the demonstration of acid-fast bacilli by culture, tissue stain or guinea-pig inoculation or characteristic histopathological features. Obtaining tissue for histopathological examination, however, may be difficult in cases not undergoing laparotomy. It is demonstrated in this study that, in such cases, open peritoneal biopsy yields adequate representative tissue without significant additional risk to the patient.

References

- BOCKUS, H.L. (1964) *Gastroenterology*, Vol. 3, 2nd edn, pp. 327-329. Saunders, Philadelphia and London.
- DAS, P. & SHUKLA, H.S. (1975) Abdominal tuberculosis: Demonstration of tubercle bacilli in tissues and experimental production of hyperplastic enteric lesion. *British Journal of Surgery*, **62**, 610.
- DAS, P. & SHUKLA, H.S. (1976) Clinical diagnosis of abdominal tuberculosis. *British Journal of Surgery*, **63**, 941.
- HOON, J.R., DOCKERTY, M.D. & PEMBERTON, J. DE J. (1950) Collective review: ileocaecal tuberculosis including comparison of this disease with non-specific regional enterocolitis and non-caseated tuberculated enterocolitis. *International Abstracts of Surgery*, **60**, 417.
- JAIN, S.C., MISRA, S.N., MISRA, N.P. & TANDON, P.L. (1964) Peritoneal biopsy in ascites. *Journal of the Indian Medical Association*, **42**, 219.
- LEADING ARTICLE (1977) Abdominal tuberculosis in Britain. *British Medical Journal*, **1**, 1557.
- LEVINE, H. (1967) Needle biopsy of peritoneum in exudative ascites. *Archives of Internal Medicine*, **120**, 542.
- LOGAN, V.St.C.D. (1969) Anorectal tuberculosis. *Proceedings of the Royal Society of Medicine*, **62**, 1227.
- MEHROTRA, M.P., MATHUR, K.S. & AGARWAL, A.N. (1966) Value of peritoneal biopsy in clinically diagnosed cases of abdominal tuberculosis. *Journal of the Association of Physicians of India*, **12**, 625.
- SARIN, L.R., MEHTA, S.R. & SARIN, J.C. (1961) Punch biopsy of peritoneum. *British Medical Journal*, **1**, 100.
- SHARMA, G.C., KALA, P.C. & BHARGAWA, V. (1972): Obstructive tuberculosis lesion of the large gut. *American Journal of Proctology*, **23**, 218.
- SHUKLA, H.S. & HUGHES, L.E. (1978) Abdominal tuberculosis in Britain a continuing problem. *British Journal of Surgery*, **65**, 403.
- TANDON, H.D. & PRAKASH, A. (1972) Pathology of intestinal tuberculosis and its distinction from Crohn's disease. *Gut*, **13**, 260.