

# Acquired hernias of the diaphragm

C.D. Johnson and H. Ellis

*Department of Surgery, Westminster Hospital, Page Street Wing, London SW1P 2AP, U.K.*

**Summary:** We present our experience over five and a half years of acquired hernias of the diaphragm. Each case represents a different presentation of this condition, which may follow blunt or penetrating trauma or iatrogenic injury. Diaphragmatic hernia may present in the acute phase after injury but late presentation may occur after many years, with chronic abdominal or respiratory symptoms, or with acute intestinal obstruction. The problems in diagnosis and management are discussed.

## Introduction

Acquired diaphragmatic hernias may arise from penetrating or blunt trauma, or may be iatrogenic. A hernia may present immediately after the injury, or after a delay, sometimes of many years. This report describes all five cases of acquired diaphragmatic hernias presenting to this hospital during a six year period, from July 1982 to June 1987.

## Case reports

### *Case 1 – blunt trauma – acute presentation*

A 30 year old man was admitted as an emergency following a road traffic accident. He was a rear seat passenger in a car, which had been struck by a lorry. He had clinical and radiological evidence of fractured ribs on the left, with a haemopneumothorax. The abdomen was soft and non-tender. He had a fractured mandible, but there was no other injury. A chest drain was inserted with partial resolution of the haemothorax. A further chest X-ray showed the presence in the left chest of a gas-filled viscus. Water soluble contrast was instilled through a nasogastric tube, and confirmed that the stomach had herniated through the left diaphragm (Figure 1). At thoracotomy later that night, the diaphragm was found to be ruptured in two places. The stomach had herniated into the chest through one laceration in the dome. The spleen had herniated through a posterior circumferential tear,

and was lacerated. This was the source of the intrathoracic bleeding.

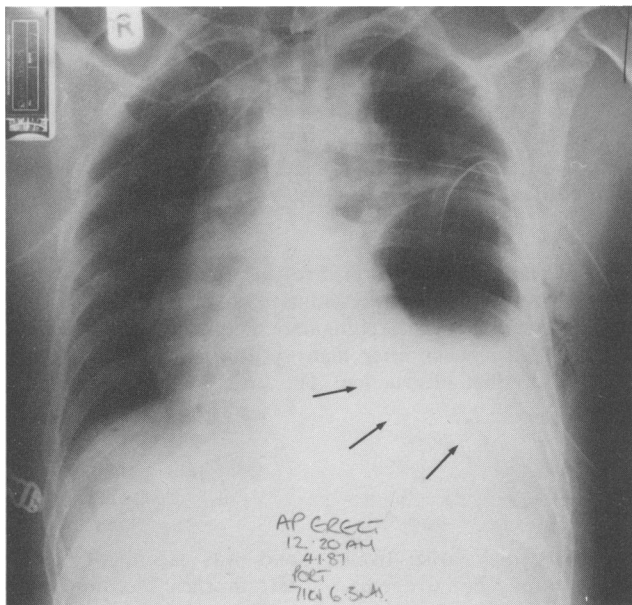
The abdomen was explored through the diaphragmatic rent; no evidence of any further intra-abdominal injury was found. The spleen was repaired using Dexon mesh, and the diaphragmatic lacerations were sutured. He made an uneventful recovery and remains well 10 months after injury.

### *Case 2 – blunt trauma – delayed presentation*

A 60 year old woman was admitted as an emergency after she had been knocked over by a motorcycle. There were multiple rib fractures on the left side, with a flail segment involving four ribs. There was a severe compound fracture of the left forearm, and a transverse compound fracture of the right tibia and fibula. The right superior and inferior pubic rami were also fractured.

The following day, the chest X-ray showed left basal shadowing. A chest drain was inserted and she was ventilated. Her wounds were debrided and the fractures were fixed externally.

She remained stable on the ventilator until the third day after injury, when the radiological appearances suggested a left diaphragmatic hernia. The presence of stomach in the left chest was confirmed with water soluble contrast. On the fourth day she was allowed to breathe spontaneously, and her condition deteriorated immediately. She underwent a left thoracotomy. The stomach and omentum had herniated through a linear defect in the dome of the diaphragm. This defect was in the line of a jagged fractured rib which was protruding through the pleura. The left lower lobe was collapsed with a small laceration.



**Figure 1** Case 1. Portable chest X-ray showing two drains in the left hemithorax, with a curvilinear shadow below the drains. This represents the upper border of the stomach, which has herniated through the diaphragm. The diagnosis was confirmed by instillation of contrast material through a nasogastric tube. The stomach is faintly opacified in the lower chest (arrows). The mediastinum is displaced to the right.

The aorta was contused but appeared intact. The herniated viscera were reduced and the defect in the diaphragm was repaired. The lung laceration was oversewn and the flail segment was fixed by wiring the fractures.

The chest injury resolved uneventfully, without any important sequelae. Orthopaedic injuries required several operative procedures and her right knee remains stiff. There is no evidence of recurrence of the diaphragmatic hernia 3 years after injury.

#### *Case 3 – penetrating injury – late presentation*

A 31 year old man was transferred from another hospital as an emergency. Six months previously he had sustained a stab wound to the left side of the chest. A left pleural effusion had been drained but no other treatment was carried out. Two months later he presented with left hypochondrial and left chest pain. Chest X-ray suggested the possibility of a chronic empyema. He was managed conservatively for some time. He then reported that for one week he had had increasing constipation, and had not passed flatus for two days. Computed tomographic (CT) scan of the chest demonstrated the presence of transverse colon in the left pleural cavity. He was transferred to this hospital, and a

left thoracotomy was performed. Transverse colon and omentum had herniated into the chest through a 6cm defect in the dome of the diaphragm. There were dense adhesions between the colon and the posterior chest wall. The colon at this point was ischaemic and had perforated. The adhesions were divided and the colon was mobilised. Colonic gas was aspirated through the perforation, which was repaired and patched with omentum. The hernia was reduced and the defect was repaired. The pleural cavity was irrigated and closed with drainage. He made an uneventful recovery. There has been no recurrence 5 years later.

#### *Case 4 – blunt injury – late presentation*

A 39 year old man presented with a 2-year history of recurrent chest infections, which had always responded rapidly to antibiotics. Chest X-rays showed a persistent opacity in the left lower lung field. At the age of 17 he had been the passenger in a car which left the road and overturned. The driver of the vehicle was killed and this patient sustained a fracture of the 6th and 7th cervical vertebrae, which required cervical fusion. He was unaware of any other injury at that time.

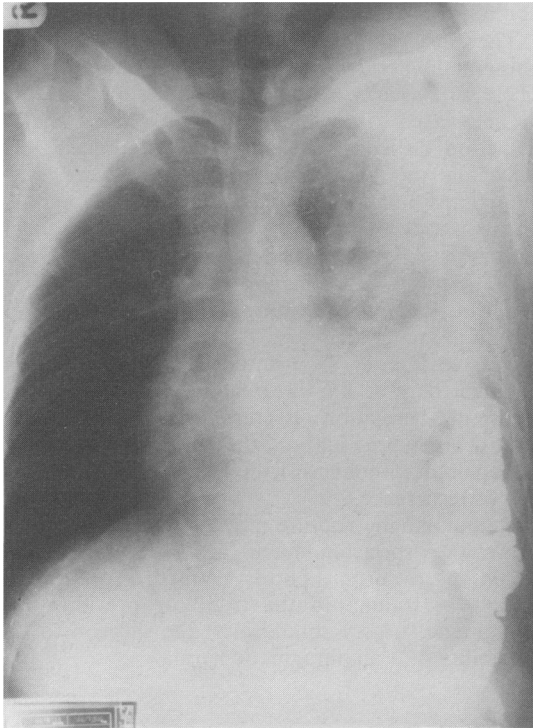
CT scan showed lobulated fat densities in the left

chest. Barium follow-through studies demonstrated colon in the left chest (Figure 2).

His diaphragmatic hernia was repaired through a left thoracoabdominal approach. Colon and omentum had herniated into the chest through a 5×4 cm defect at the lateral margin of the left hemidiaphragm. There were dense adhesions between the bowel and the lung. The adhesions were divided and the hernia was reduced after extending the defect medially by 4 cm. The diaphragmatic defect was closed without tension, and the chest was closed with drainage. He made an uneventful recovery and remains well 7 months later.

#### Case 5 – iatrogenic hernia – late presentation

A 39 year old woman presented with a one year history of pain in the right iliac fossa. At the age of 4 years she had had a transthoracic oesophagogastrectomy for an oesophageal stricture secondary to reflux oesophagitis. She had had an appendicectomy, tubal ligation, salpingo-oophorectomy, and finally a hysterectomy 3 years previously. Barium meal and follow-through showed the oesophagogastrectomy, but was otherwise normal. Barium



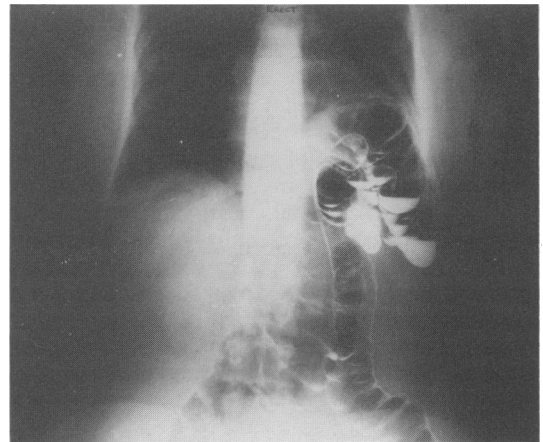
**Figure 2** Case 4. Barium follow-through outlines the colon in the left hemithorax.

enema showed a diaphragmatic hernia, with the splenic flexure lying in the left hemithorax (Figure 3). At laparotomy a 4×5 cm defect was found at the hiatus, with the stomach drawn up into the chest to the oesophageal anastomosis. The splenic flexure of the colon had herniated through the defect into the left chest. The colon was reduced without difficulty and the defect was repaired around the stomach with a Gore-tex patch. She made an uneventful recovery and remains well 6 months later.

#### Discussion

These cases illustrate the wide range of presentation that may be found with acquired traumatic or iatrogenic diaphragmatic hernia. There is no case of herniation immediately after penetrating injury in this series. Penetrating wounds are frequently managed by surgical exploration, and any diaphragmatic injury is repaired before a hernia can develop. Case 3 demonstrates that failure to explore such a wound can lead to the late development of a hernia.

Severe blunt trauma to the trunk is associated with diaphragmatic rupture in about 5% of cases.<sup>1,2</sup> The rupture may be immediately obvious (as in Case 1) or may only become apparent after an interval of a few days (Case 2). These patients frequently have other injuries, including intracranial haematomas (25%), fractures of the pelvis (25%) and long bones (50%), and injuries to intra-abdominal viscera (50%) and injuries to the heart and great vessels (10%), but somewhat surprisingly, fractured ribs are not universal, with a reported



**Figure 3** Case 5. Barium enema shows colon passing through the diaphragmatic defect into the left hemithorax.

incidence of 47% in large series.<sup>3-8</sup> The usual mechanism of injury is thought to be compression of the abdomen, with rupture of the diaphragm under the increased pressure (as in Case 1) but occasionally the diaphragm may be torn by direct trauma from fractured ribs (as in Case 2).

The diagnosis should be suspected in any patient who has major trauma to the trunk, especially with fractured ribs, or if there is basal shadowing on the chest X-ray. The presence of a gas filled viscus in the left chest is diagnostic. Opacification with water soluble contrast may be helpful in doubtful cases. If the patient's condition is stable, ultrasound or CT may provide additional useful information. Diaphragmatic rupture can also be diagnosed by peritoneal lavage or induced pneumoperitoneum. The lavage fluid or air is observed to pass into the chest. However, these procedures are not without risk of injury to the bowel or pulmonary collapse, and should be carried out with caution. Any induced pneumo- or hydrothorax should be aspirated promptly.<sup>9</sup>

When the diagnosis of diaphragmatic hernia is made immediately after admission, the preferred operative approach is through a laparotomy. This enables a thorough inspection of the abdominal contents.<sup>8,10,11</sup> Any intra-abdominal injury can then be dealt with. In up to 10% of cases, when there is a massive haemothorax, or when signs are confined entirely to the chest and the abdomen is soft, thoracotomy may be preferable.<sup>11</sup> In either instance the patient should be prepared and draped so that both body cavities may be entered simultaneously, should this prove necessary.

When the diagnosis is delayed, even by a few days, as in Case 2, a different approach is required. The patient's condition will now be stable, and there will be no suggestion of intra-abdominal injury. Adhesions develop rapidly in the chest, and may form within a few days of injury. For both these reasons, thoracotomy is the approach of choice when diagnosis is delayed.

Late presentation of traumatic diaphragmatic hernias may occur at any time after the patient's discharge from hospital. Post-traumatic hernias have been described presenting 40 years or more after the initial injury.<sup>12-14</sup> The difficulty with these patients is to make the diagnosis, because symptoms are vague, unless obstruction supervenes.

One patient (Case 3) had symptoms referable to the chest and the abdomen, only a few months after diaphragmatic injury, yet the diagnosis of

diaphragmatic hernia was not made until he developed large bowel obstruction. Two other cases presented many years after the initiating event, one with chest symptoms, the other with abdominal pain. In each case the diagnosis was not considered until radiological investigations suggested the presence of abdominal contents in the chest. In fact one patient (Case 4) had no recollection of any injury to the trunk, and the history of cervical fusion for fractured vertebrae was disregarded until the diagnosis was made.

Incisional hernia of the diaphragm was initially described after transthoracic repair of a hiatus hernia,<sup>15</sup> and has been recorded after various other transdiaphragmatic procedures.<sup>16</sup> Only two other cases have been reported following oesophago-gastrectomy.<sup>16</sup> This may represent under-reporting, although it is possible that, as the majority of patients who have oesophago-gastrectomy do so for carcinoma, there may be few who survive long enough to develop a symptomatic hernia.

Incisional hernia of the diaphragm is said to be much less frequent following circumferential incision rather than a radial incision. Transdiaphragmatic surgery should be planned with this in mind, and it is recommended that any incision in the diaphragm should be closed with interrupted non-absorbable sutures.

The surgical approach to long-standing diaphragmatic hernias should be by a thoracotomy. There are usually considerable adhesions between the herniated viscus and the lung, which makes reduction difficult from within the abdomen. The defect in the diaphragm should be closed with interrupted non-absorbable sutures, if this can be done without tension. Large defects require a patch with prosthetic material such as Marlex or Gore-tex. The prognosis of diaphragmatic hernia repair is excellent. Patients presenting acutely rarely die from the diaphragmatic injury, but may succumb from associated injuries. Occasionally respiratory embarrassment may be life-threatening. Following repair, recurrent herniation is rare.<sup>7,14,17-19</sup> Similarly, after delayed presentation, these hernias can usually be repaired without difficulty and with a very low risk of recurrence.

Diaphragmatic rupture may present at any point along the spectrum from acute life-threatening condition to chronic poorly defined disorder. The history of trauma to the trunk or previous diaphragmatic surgery should alert the surgeon to the possibility of a diaphragmatic hernia.

## References

1. Waldschmidt, M.L. & Laws, H.L. Injuries of the diaphragm. *J Trauma* 1980, **20**: 587-592.
2. Brearley, S. & Tubbs, N. Rupture of the diaphragm in blunt injuries of the trunk. *Injury* 1981, **12**: 480-484.
3. Williams, R.S. Traumatic rupture of the diaphragm. *Med J Aust* 1982, **1**: 208-211.
4. McElwee, T.B., Myers, R.T. & Pennell, T.C. Diaphragmatic rupture from blunt trauma. *Am Surg* 1984, **50**: 143-149.
5. Visset, J., Le Neel, J.C., Duveau, D., Paineau, J. & Hingrat, J.Y. Ruptures traumatiques du diaphragme. *Presse Med* 1983, **12**: 1211-1214.
6. van der Werken, C., Lubbers, E.J.C. & Goris, R.J.A. Rupture of the diaphragm by blunt trauma as a marker of injury severity. *Injury* 1984, **15**: 149-152.
7. McCune, R.P., Roda, C.P. & Eckert, C. Rupture of the diaphragm caused by blunt trauma. *J Trauma* 1976, **16**: 531-537.
8. Ward, R.E., Flynn, T.C. & Clark, W.P. Diaphragmatic disruption secondary to blunt abdominal trauma. *J Trauma* 1981, **21**: 35-38.
9. Brooks, J.W. Blunt traumatic rupture of the diaphragm. *Ann Thor Surg* 1978, **26**: 199-203.
10. Niville, E.C., Himpens, J.N., Bruosa, P.C. & Gruwez, J.A. The use of laparotomy in the treatment of recent diaphragmatic rupture due to blunt trauma. *Injury* 1984, **15**: 153-155.
11. Rodriguez-Morales, G., Rodriguez, A. & Shatney, C.H. Acute rupture of the diaphragm in blunt trauma; analysis of 60 patients. *J Trauma* 1986, **26**: 438-444.
12. Ebert, P.A., Gaertner, R.A. & Zuidema, G.D. Traumatic diaphragmatic hernia. *Surg Gynecol Obstet* 1967, **125**: 59-65.
13. Dajee, A., Schepps, D. & Hurley, E.J. Diaphragmatic injuries. *Surg Gynecol Obstet* 1981, **153**: 31-32.
14. Arendrup, H.C. & Jensen, B.S. Traumatic rupture of the diaphragm. *Surg Gynecol Obstet* 1982, **154**: 526-530.
15. Effler, D.B. Allison's repair of hiatal hernia: late complication of diaphragmatic counterincision and technique to avoid it. *J Thor Cardiovasc Surg* 1965, **49**: 669-676.
16. Johnson, C.D. & Shandall, A.A. Incisional hernia of the diaphragm causing large bowel obstruction. *J R Coll Surg Edinb* 1987, **32**: 51-52.
17. Grimes, O.F. Traumatic injuries of the diaphragm. *Am J Surg* 1974, **128**: 175-181.
18. Bekassy, S.M., Dave, K.S., Wooler, G.H. & Ionescu, M.I. 'Spontaneous' and traumatic rupture of the diaphragm. *Ann Surg* 1973, **177**: 320-324.
19. Waldhausen, J.A., Kilman, J.W., Helman, C.H. & Battersby, J.S. The diagnosis and management of traumatic injuries of the diaphragm including the use of Marlex prostheses. *J Trauma* 1966, **6**: 332-343.