

Alveolar soft-part sarcoma: a hormone-sensitive tumour?

J.A. Pang, T.F. Yeung and C.S. Cockram

Department of Medicine, The Chinese University of Hong Kong, Prince of Wales Hospital, Shatin, NT, Hong Kong.

Summary: Alveolar soft-part sarcoma is a rare, slow-growing, malignant tumour which metastasizes frequently to the lungs. Treatment with radiotherapy or chemotherapy is largely ineffective, and most patients die within 4 years of developing metastases. We report an unusual patient who survived 9 years after detection of pulmonary metastases. Initial treatment with cytotoxic chemotherapy was ineffective. However, during subsequent treatment with Chinese herbs when she developed galactorrhoea and amenorrhoea (probably due to drug-induced hyperprolactinaemia), her lung metastases regressed, and it is likely that this contributed to her prolonged survival. We hypothesize that alveolar soft-part sarcoma may be a hormone-sensitive tumour, and hormonal manipulation may be an alternative form of treatment which is worth considering.

Introduction

Alveolar soft-part sarcoma is a rare tumour arising in skeletal muscle, with only 177 reported cases according to a recent review.¹ It affects young people, with a mean age at presentation of 20 years in women and 30 years in men, and a female predominance of about 2:1.² Although the primary tumour is slow-growing, blood-borne metastases invariably occur and cause death in over half the patients within 10 years of initial diagnosis.² The lungs are the commonest site of metastases (42%), and in a detailed analysis of 53 cases,² only 1 in 16 patients survived for more than 4 years after detection of pulmonary secondaries. As far as we are aware, spontaneous regression of lung metastases has never been reported.

Wide excision of the primary tumour is commonly performed, but treatment of metastases is largely ineffective. They are relatively resistant to radiotherapy,^{3,4} and results of combined treatment involving local excision, radiotherapy and chemotherapy have also been disappointing.⁴⁻⁶ However, there is an exceptional patient who responded well to thiotepa,³ and another who remained disease-free 5 years after resection of 92 lung metastases followed by combination chemotherapy.⁷

We wish to report a patient with alveolar soft-part sarcoma who survived for over 9 years after detection of pulmonary metastases. This patient

was highly unusual in that her enlarging pulmonary metastases regressed when she was treated with oral and topical Chinese herbs. During the period of treatment, she also developed galactorrhoea and amenorrhoea. The temporal relationship of these events will be discussed.

Case report

A 20 year old woman had excision of a right buttock mass in 1975. Histological examination of the lobulated tumour showed large cells with eosinophilic cytoplasm arranged in a prominent repetitive 'alveolar' pattern typical of alveolar soft-part sarcoma.

Lung metastases were discovered on a routine chest X-ray the following year, and she was given cytotoxic chemotherapy (details unknown), but there was no radiological response. In 1978, she became pregnant. This was uneventful until late in the third trimester, when she had an episode of severe haemoptysis. It settled with conservative treatment and a boy was successfully delivered. However, she had another severe haemoptysis in the puerperium, and serial chest X-rays from 1976 to 1979 showed an increase in size of the lung metastases. She consulted a Chinese herbalist, and on his advice took a herbal mixture orally and applied a herbal paste on her chest and back under occlusive dressing from March 1979 to July 1982. She was

forewarned that her breasts would swell with this treatment, and she developed breast enlargement, galactorrhoea and amenorrhoea a few months later. Clinically, she remained well, and further chest X-rays in 1981 and 1982 showed a remarkable improvement. Compared with the chest X-ray in 1979, a follow-up film in January 1983 showed complete disappearance of some shadows and shrinkage of others. Although one lesion in the right lower zone increased in size, this was an exception (Figure 1). Herb treatment was stopped in July 1982 because of the radiological improvement, and galactorrhoea ceased within 2 months, followed by return of menses 2 months later.

In March 1983, 8 months after stopping the herb treatment, she developed a right haemothorax, and this was treated with intercostal tube drainage. In May, the locally applied herbal paste was restarted, and she developed amenorrhoea and galactorrhoea 8 months later. In December 1983, she had another episode of haemoptysis. In March 1984, she developed progressive dyspnoea and her chest X-ray deteriorated. She was referred to another hospital, where she received 6 courses of chemotherapy at monthly intervals (Day 1: cyclophosphamide 1g, doxorubicin 60mg; Days 1-5: dacarbazine 250mg daily) with no apparent benefit. In April 1985, she had two attacks of giddiness, vertigo and vomiting. Two months later, she was

referred to this hospital because of a painful swelling in the right side of her chest.

Physical examination on admission showed a warm tender swelling beneath her right breast, over which a loud bruit could be heard. She had marked galactorrhoea, gross hepatomegaly and unsteadiness on walking. A chest X-ray showed a large mass occupying most of the right hemithorax, multiple cannon ball metastases in the left lung, and an enlarged cardiac shadow. Computed tomography of the thorax and abdomen confirmed these findings and showed additional tumour involvement of the right atrium, posterior mediastinum, liver and retroperitoneum. Computed tomography scan of the brain revealed metastases in the left frontoparietal region without any detectable pituitary or hypothalamic lesion. Her serum prolactin concentration was 3330 pmol/l (normal range 96-841 pmol/l). Over the next 2 weeks, she deteriorated relentlessly and died. Permission for post-mortem examination was not granted.

Discussion

The early course of this patient's illness is typical of alveolar soft-part sarcoma except for the successful pregnancy. This uncommon event has only been reported once previously.⁸ During the next 3 years

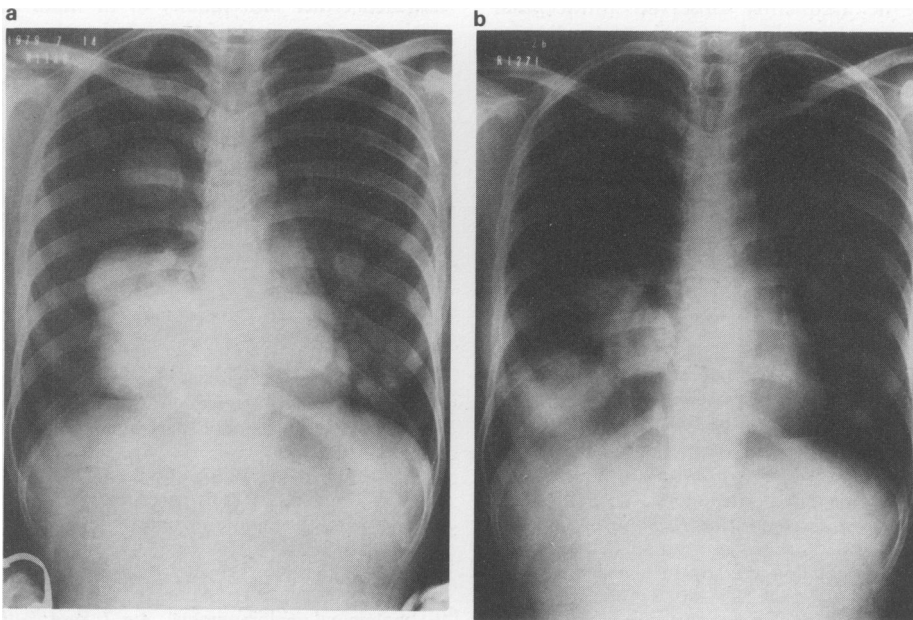


Figure 1 Chest radiographs in July 1979 (a) and January 1983 (b), showing complete disappearance of some shadows, e.g. right upper zone, left lower zone; and shrinkage of others. One lesion in the right lower zone, however, increased in size.

after delivery when she received only Chinese herbs, her chest X-rays showed unequivocal improvement, and it is likely that this contributed to her prolonged survival.

The temporal relationship between administration of the herbs and the duration of galactorrhoea and amenorrhoea strongly suggests that the latter were drug-induced effects. The timing was typical, and the patient was forewarned that her breasts would swell with the treatment. Presumably, the herbalist had observed this effect in other similarly treated patients. In addition, the prolactin level was elevated despite lack of computed tomographic evidence of a pituitary or hypothalamic lesion. Unfortunately, all attempts to identify the active principles in the herb mixtures failed.

It is tempting to speculate that the patient's tumour may have been hormone-sensitive, and that her radiological improvement is associated with a change in hormonal environment induced by herb treatment. Apart from the temporal relationship, tentative support for this interpretation also comes from the observation that her four episodes of haemorrhage occurred at times when hormonal changes were expected to be great, namely, in late pregnancy, early puerperium, after cessation of galactorrhoea and amenorrhoea, and soon after recommencement of these symptoms. There is some recent evidence that alveolar soft-part sarcoma may arise from modified smooth muscle cells of vascular media and the frequently observed intracellular crystalline material is a form of renin (a 'malignant angioreninoma').⁹ Therefore, it is conceivable that such hormone-containing tissue may be influenced by other hormones.

Another possibility is that the herbs may have a cytotoxic effect independent of their putative hormonal effects. However, this is unlikely because the patient did not suffer from any of the adverse effects associated with 'conventional' cytotoxic

chemotherapy despite the long duration of treatment.

Treatment of metastatic alveolar soft-part sarcoma is unsatisfactory. Based on our experience with this case, we believe that an attempt to manipulate the patient's hormonal environment with relatively non-toxic drugs may be worthwhile. The hormonal changes observed were hypersecretion of prolactin and hypogonadism (amenorrhoea) presumably secondary to the hyperprolactinaemia. Conventional therapy aimed at mimicking these effects could utilize the prolactin-stimulating properties of drugs such as domperidone or metoclopramide. However, the patient deteriorated rather than improved during pregnancy and in the early puerperium, and this would suggest that it is the hypogonadism rather than increased prolactin secretion which is important. If this is indeed the case, then it would be logical to attempt treatment of this rare tumour by inducing hypogonadism using, for example, a gonadotrophin-releasing hormone (GnRH) analogue in such a way as to inhibit gonadotrophin secretion. Such agents are relatively free from side effects, do not preclude the use of other forms of therapy should they prove ineffective, and are being increasingly applied to treat hormone-sensitive tumours such as breast and prostate cancer.

With tumours as rare as alveolar soft-part sarcoma, therapeutic regimens inevitably have to be assessed either individually or in small numbers of patients. Our experience with this patient is anecdotal and interpretation is hampered by our ignorance of the composition of the herbal remedy prescribed. However, it is our belief that the circumstantial evidence is sufficiently strong to make worthwhile a trial of therapy aimed at inducing hypogonadism either by reducing the secretion of sex steroids or by blocking their effects.

References

- Hurt, R., Bates, M. & Harrison, W. Alveolar soft-part sarcoma. *Thorax* 1982, **37**: 877-886.
- Lieberman, P.H., Foote, F.W. Jr., Stewart, F.W. & Berg, J.W. Alveolar soft-part sarcoma. *JAMA* 1966, **198**: 121-125.
- Asvall, J.E., Hoeg, K., Kleppe, K. & Prydz, P.E. Alveolar soft-part sarcoma. *Clin Radiol* 1969, **20**: 426-432.
- Ruberfeld, S. Radiation therapy in alveolar soft-part sarcoma. *Cancer* 1971, **28**: 577-580.
- Balfour, R.S. The alveolar soft-part sarcoma: review of the literature and report of a case. *J Oral Surg* 1974, **32**: 214-220.
- Blumberg, M.B. & Chang, C.H. Alveolar soft-part sarcoma. *South Med J* 1976, **69**: 282-285.
- Baum, E.S., Fickenscher, L., Nachman, J.B. & Idriss, F. Pulmonary resection and chemotherapy for metastatic alveolar soft-part sarcoma. *Cancer* 1981, **47**: 1946-1948.
- Christopherson, W.M., Foote, F.W. Jr. & Stewart, F.W. Alveolar soft-part sarcomas. Structurally characteristic tumors of uncertain histogenesis. *Cancer* 1952, **5**: 100-111.
- DeSchryver-Kecsckemeti, K., Kraus, F.T., Engleman, W. & Lacy, P.E. Alveolar soft-part sarcoma - a malignant angioreninoma. *Am J Surg Pathol* 1982, **6**: 5-18.