

Review Article

Cerebral scintigraphy – the phoenix rises again

Basil J. Shepstone

Department of Radiology, University of Oxford, Oxford, UK.

Summary: This paper reviews the development of cerebral scintigraphy from its early days of planar imaging with simple technetium-99m labelled compounds to the recent revival of the technique in the form of positron-emission and single-photon emission tomography. A short explanation of instrumentation and radiopharmaceuticals is given as a prelude to a description of both techniques in normal and pathological situations. Particular emphasis is placed on the more readily-available single-photon emission-tomographic techniques using labelled amines in the functional investigation of disorders not readily diagnosed by computed tomography.

Nuclear medicine is an eclectic sub-speciality, drawing on basic science, medicine and technology and never is this more clearly illustrated than in tracing the history of cerebral scintigraphy.

Advances in neurosurgery have taken at least some of the neurological disorders out of the realms of pure academic medicine and the accurate diagnosis of cerebral conditions has of course become mandatory. Nowadays the exquisite technique of computed tomography is generally available and a generation of younger radiologists is already emerging who have little idea of the rigours of pneumoencephalography and ventriculography for technician and patient alike, but more especially for the latter. It is therefore probably difficult for them to imagine how welcome cerebral scintigraphy was when it became available some years ago. This involved the injection of suitable radionuclides into the blood or cerebrospinal fluid and the result was an image of regional function in the brain (cerebral scintigraphy) or in the cerebrospinal fluid pathways (radionuclide cisternography). Disease was then detected by assessing the degree to which the so-called blood-brain barrier was rendered inoperative or the normal channels of cerebrospinal fluid flow altered. The functional aspect of nuclear medicine investigations has always been given great emphasis by its exponents and, as will be shown in this article, their claim is justified.

Planar cerebral imaging

Routine cerebral scintigraphy became universally available as a result of the combination of an appropriate detector and suitable radionuclides. The basis of all detection systems is the scintillation unit (Figure 1), containing the all-important sodium iodide crystal and photomultiplier tubes which formed the basis, initially, of the old rectilinear scanner and were then incorporated into the gamma camera, invented by Hal Anger in 1961 (Figure 2a). The latter makes use of one large scintillator crystal and a number of photomultiplier tubes arranged so that the spatial relationships of radioactive tracers in the brain are correctly recorded and displayed on a television screen (from which a hard copy can be produced) or fed into the memory of a linked computer system (Figure 2b). Nowadays it is impossible to conceive of a gamma-camera system not linked to a computer which enables so-called regions-of-interest to be drawn over areas of uptake and which can subsequently be represented as activity-time curves (Figure 3). The use of the computerized gamma camera in this so-called dynamic mode is one of its most useful attributes.

An appropriate tracer was available with the discovery that the attributes of technetium-99m in the form of the pertechnetate ion, diethylene diaminetetraacetic acid or gluconate made it ideal for cerebral scintigraphy. Technetium-99m is an easily-available radionuclide of nearly pure gamma emission, short half-life and excellent clearance from the body, which offers the combination of being very safe for the patient in quantities capable

Correspondence: B.J. Shepstone, M.A., M.Sc., D.Phil., M.D., D.Sc., F.R.C.R., The Medical School Offices, John Radcliffe Hospital, Headington, Oxford OX3 9DJ, UK
Received: 25 June 1987

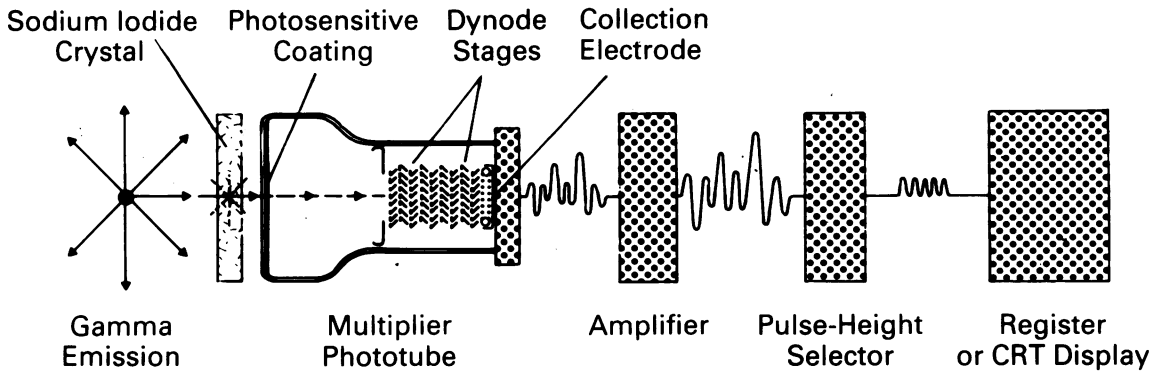


Figure 1 The basic scintillation detector. Gamma rays from the patient strike a sensitive sodium iodide crystal, where they are converted into light photons. These, in turn, strike a photo-sensitive coating and are changed into electrons. The electrons are multiplied by the dynode stages in the photo-multiplier until a large number are available to constitute an electrical current. The current is amplified and eventually reaches a television screen. The pulse-height selector filters out pulses produced by the wrong kind of radiation, e.g. cosmic ray activity and unwanted radionuclides administered previously.




Figure 2(a) A modern scintillation or gamma camera mounted on a gimbal mounting so that the camera can rotate around the patient if necessary and so also produce cross-sectional images.

of producing maximum information density.

When pertechnetate is used as a cerebral imaging agent, the normal brain is not visualized. Only if there is a lesion causing breakdown of the so-called blood-brain barrier does uptake occur in the lesion itself. The detection of any lesion depends on the differential between the uptake of tracer and that in surrounding tissue. As the pertechnetate is carried

to the head in the blood, there will obviously be background 'noise' and physiochemical devices are used to reduce this as far as possible, e.g. potassium perchlorate to reduce choroid plexus and thyroid uptake, atropine to reduce salivary gland activity, uptake in the surrounding paranasal sinuses and oral mucosa and the muscles of the face and neck. Normal planar images are depicted in Figure 4.

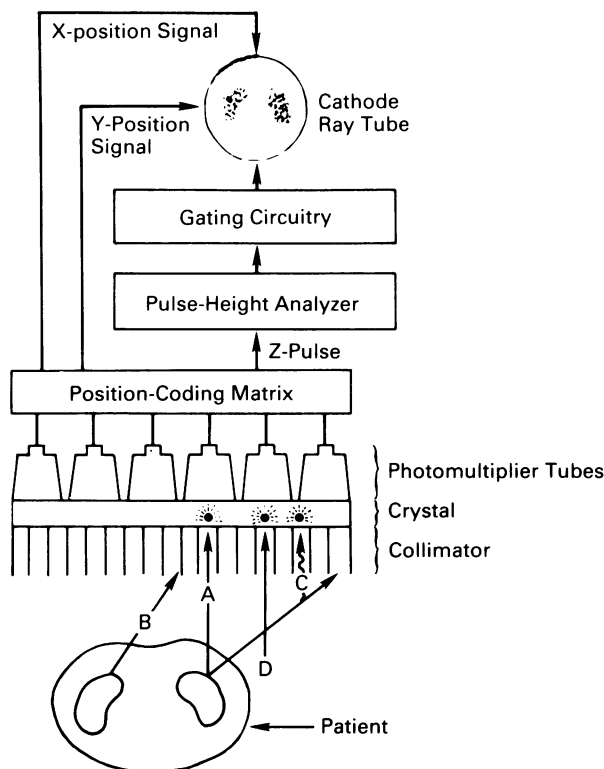


Figure 2(b) A schematic view of the gamma camera and its circuitry. The lead collimator will only allow parallel rays such as A, C and D to reach the crystal. Rays such as B will be absorbed by the lead. The pulse-height analyser and gating circuitry will later filter off D (cosmic radiation) and C (scattered radiation) because their energies will not be appropriate. The position-coding matrix circuit will assign the pulse to the correct position on the television screen, which will obviously correspond to the coordinates of the photomultipliers which are activated. The Z-pulse provides intensity.

The customary procedure in planar brain imaging is to use the injection of tracer to generate what is in effect a cerebral angiogram. Sequential images are recorded at short time intervals, which can later be displayed individually or in so-called 'cine mode'. Otherwise activity in selected regions-of-interest (e.g. left and right cerebral hemispheres) can be displayed as a function of time. It is then customary to generate a so-called 'equilibrium' or 'blood-pool' image, which is simply a summation of all the dynamic images. Finally, late static images are recorded in the antero-posterior, postero-anterior and two lateral projections. Occasionally a view from the top, a vertex projection, is also recorded.

Except for activity in the venous sinuses, such a series of scintigrams will show the normal brain to be relatively clear of activity. However any lesion involving breakdown of the blood-brain barrier will cause a focus of increased uptake. Although this is

a sensitive process, it is sadly not specific and this is one of the drawbacks of nuclear medicine. The differential diagnosis is wide and the working diagnosis often has to be based on other evidence such as clinical history and the like. Occasionally the position or shape of the lesion will be useful, as in the case of cerebrovascular accidents and subdural haematomata respectively, but this is unfortunately not always the case.

Tumours, cerebral vascular accidents, infections and traumatic foci all show as foci of increased uptake. Some examples are given in Figure 5.

There can therefore be no doubt that the relatively simple and non-invasive planar cerebral scintigram was a suitable screening method. However, it was obvious that it could not compete with computed tomography when it was invented in 1973, at least as far as morphology and specificity were concerned. However, it would appear that computed tomography did not occur *de novo*, but

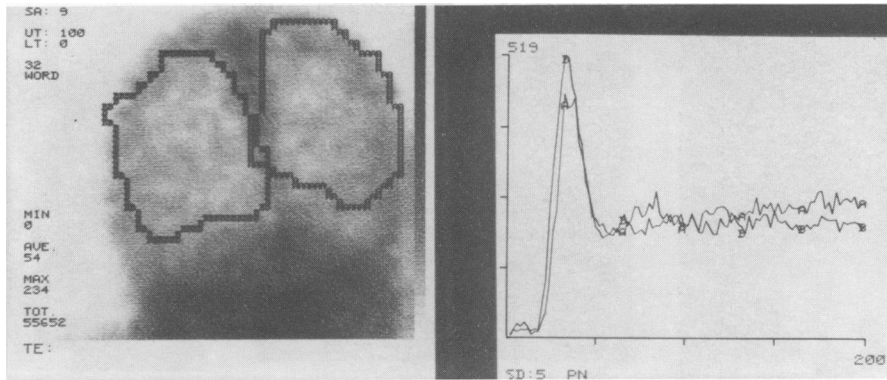


Figure 3 An example of an activity-time curve (right). The number of counts collected in sequential small fixed time intervals (say one or two seconds) are accumulated in the computer memory for a few minutes. So-called 'regions-of-interest' are then drawn over each cerebral hemisphere (left), following which the inbuilt software will compute and display the variation of the counts per small time interval (activity) as a function of the duration of the study (time).

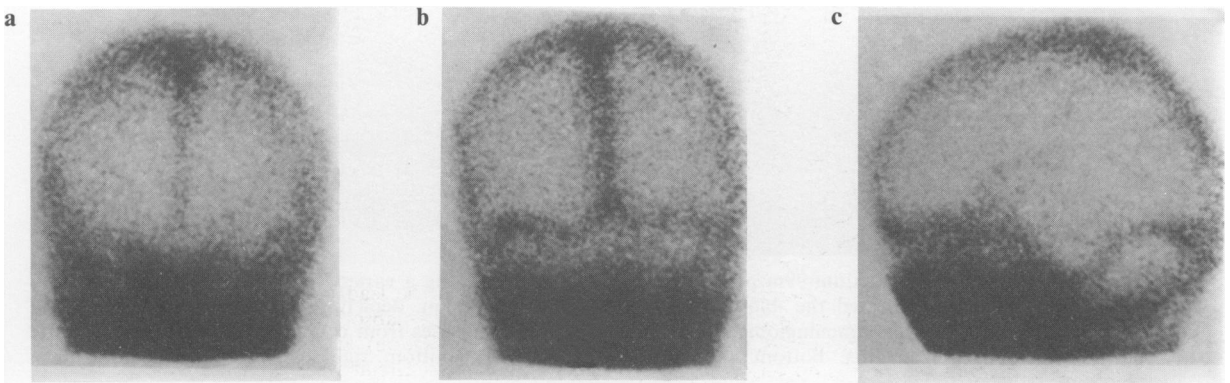


Figure 4 Normal planar scintigrams of the head using technetium-99m as pertechnetate: anterior (a) posterior (b) and a lateral (c). Most of the activity is in the venous sinuses and the soft tissues of the head. The normal brain is relatively free of activity. High activity blackens X-ray film, but appears white on polaroid film. (From *Clinical Nuclear Medicine*, Eds Maisey, Britton and Gilday, London, Chapman & Hall. Reproduced with permission.)

was a direct result of pioneering work in the nuclear medicine field and which has also led to revolutionary techniques in what is known as emission computed tomography. This should be reduced to the acronym ECT, but because of conflict with another well-known technique, has instead become known as PET or SPECT, standing for positron-emission tomography and single-photon emission-computed tomography, respectively.

Single-photon emission computed tomography (SPECT)

In 1963, some years before Hounsfield became a household name, Dr David Kuhl, then only a medical student at the University of Pennsylvania,

and his colleague, Dr Edwards, hit on the unique idea of obtaining transverse sectional views of the brain. Four small scintillation detectors were arranged to view the patient's head in the anterior, posterior and two lateral directions at the desired level. As they made rectilinear passes across each direction, the detected radiation events were stored on magnetic tape. The detectors were then rotated 15° about the patient's head, still in the same plane, and a further series of readings taken. This process was then repeated until the four recorders covered the whole brain. The data were then finally processed by computer to provide the first cross-sectional view of the brain.¹

It is interesting to note that as early as 1917 the Austrian mathematician, Radon, showed that a

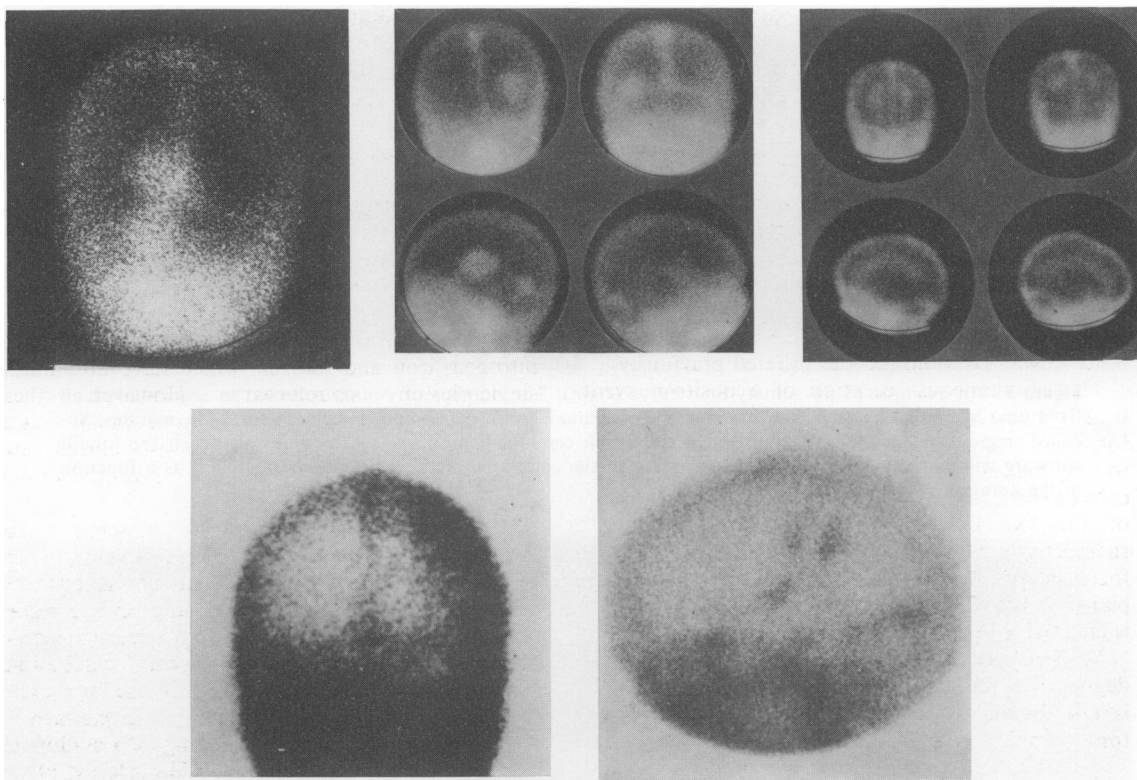


Figure 5 Examples of technetium-99m pertechnetate scintigrams showing a variety of cerebral lesions, where the radionuclide has penetrated the 'blood-brain barrier' into the lesion, depicting the latter as a photon-abundant area. Top left: falx meningioma; top middle: cerebral metastases from carcinoma of bronchus; top right: tuberculous ventriculitis; bottom left: subdural haematoma; bottom right; middle cerebral artery infarction.

two- or three-dimensional object can be reconstructed from the infinite set of all its projections. These concepts were probably first used to great effect in meteorology, whereby two-dimensional weather maps could be reconstructed from satellite readings. There is no difference mathematically between weather satellites recording from earth and detectors recording from a body. The work of Kuhl and Edwards antedated Hounsfield and Cormack's work by some 10 years and it is sad that they were not given a share of the Nobel Prize that accrued to this great achievement in 1979.

Nowadays, the principle of acquiring cross-sectional images as outlined above is still used, the only essential difference being that a rotating gamma camera is employed instead of a rectilinear scanner. The technique is referred to as single-photon emission computed tomography, abbreviated to SPECT. As this is now a universally-demanded technique it is unlikely that

any department of nuclear medicine will henceforth acquire a non-rotating camera. However, it should be pointed out that the count rates from a rotating camera are significantly lower than that of a ring system, the latter being comparable in sensitivity to PET scanners. However, sensitivity in rotating systems can be improved by the use of so-called fan-beam and other focussing collimators. Some examples of SPECT images are given later in Figures 7 to 13.

Positron-emission tomography (PET)

The location of positron-emitting radionuclides injected into the body are, contrary to expectation, detected by the presence of high-energy gamma rays. The latter arise when the positrons (which are of course positively-charged electrons) collide with electrons and both are annihilated in an exchange of matter into energy, resulting in two high-energy

gamma rays that travel away from each other in opposite directions (Figure 6).

The gamma camera must therefore be converted into a positron camera. The essential difference between the two is that the positron camera must have two orthogonally situated detectors, one on each side of the patient, which are electronically linked so that only coincidental events are recorded. This direct-line geometry obviates the need for selective interference collimators of the kind needed in single-photon emission situations where there is the possibility of interference by gamma rays of different energies, e.g. background radiation or other unwanted radionuclides injected previously.

The simultaneous reception of a positron event by the two diametrically-opposed detectors allows for focus at a given plane in the patient, in contrast to the lack of this facility in a planar gamma-camera. It is possible to combine the spatial sensing of the two detectors in such a way that all radioactivity lying on a given plane will be in sharp focus in the final image, while activity from other planes is distributed over such a wide area that it is effectively invisible on the image.

Modern positron cameras have a considerable degree of sophistication. Their external appearance is not dissimilar from the now-familiar computed tomographic and magnetic resonance imaging

machines. Internally they now have banks of detectors all carefully aligned so that, in spite of their numbers, they are always in pairs facing each other. The Neuro-ECAT machine, designed specifically for cerebral studies at the University of California, Los Angeles, for instance, has three octagonal detector planes, each with 88 bismuth germanate detectors. The number of PET units world-wide is at present around 50, with their numbers increasing at about 10% per annum.

Positron-emitting radionuclides are important because they include a number of very important biological elements such as carbon, oxygen, nitrogen, iron and fluorine which have no suitable single-photon counterpart. However, these radionuclides have the overwhelming twin disadvantages of being cyclotron-produced and having very short half-lives. That of oxygen-15, for example, is only 15 minutes.

By extension, this involves the presence in the hospital of both a cyclotron and a laboratory where these short-lived radionuclides can be incorporated on-line into or converted to an appropriate radiopharmaceutical, as well as being rendered sterile, apyrogenic and generally biologically compatible. The positron camera must also be in the same area.

All of this requires an extensive investment in space and money, the latter running into millions of pounds. The result is that only a few selected places have positron-facilities. They abound in the USA, and the West German government has considered the technique so important that their major nuclear medicine departments have been provided with positron facilities. In this country, alas, only the Royal Postgraduate Medical School has such a facility at present. However, one or two centres are experimenting with less-expensive detectors and the longer-lived positron emitters.

Radiopharmaceuticals used in positron-emission tomography

As Holman *et al.* have stated, conventional brain scintigraphy has always been a misnomer and should be called 'non-brain imaging', the reason of course being that the single-photon radiopharmaceuticals such as technetium-99m pertechnetate, DTPA or gluconate do not penetrate normal brain.² Only when the blood-brain barrier is damaged do they appear as focal areas of increased uptake in cerebral tissues. The quest has therefore been on for some time to produce radiopharmaceuticals capable of investigating the normal brain.

Of all the useful positron-emitting elements cited

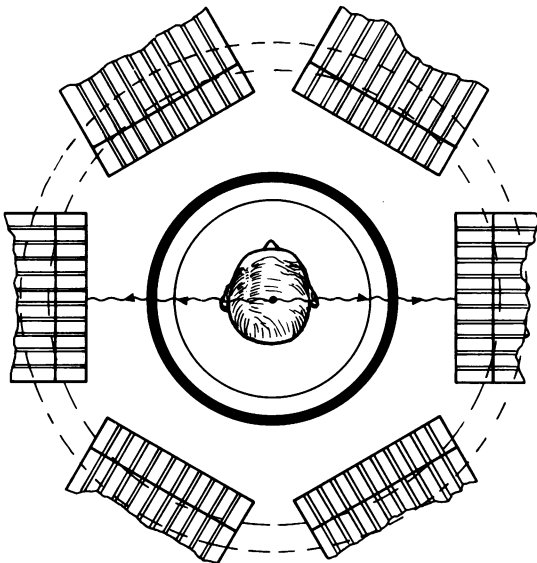


Figure 6 Schematic representation of a positron-emission tomographic device. The annihilation gamma rays travel in opposite directions from a joint source within the brain. Using diametrically opposed detectors, the twin gamma rays are selected for coincidence and a cross-sectional image is built up from the coincident scintillations.

above, the unexpected fluorine in the form of fluorine-18 deoxyglucose has proved to be the most useful in cerebral studies. This is now known as the 'FDG method'. After intravenous injection, FDG enters the brain and is phosphorylated by cerebral hexokinase. The metabolic product, FDG-6-PO₄, remains fixed in the brain, where it undergoes only slow dephosphorylation. The change in fluorine-18 activity and glucose concentration with time can be measured by a combination of cerebral scintigraphy and plasma concentration measurements and if these parameters are put into the appropriate equations, local cerebral glucose utilization can be determined and represented pictorially as a cross-sectional image.

Oxygen-15 has also had a long run of usefulness in determining cerebral oxygen utilization and blood volume. The uptake of nitrogen-13 labelled ammonia has also been used to estimate blood flow.

Several neutrally-charged lipophilic radiolabelled compounds have been developed and it is nowadays customary to divide them into two groups: (1) those whose cerebral distribution is proportional to blood flow and (2) those where the localization image is dependent on the distribution of receptor binding.

Mainly PET investigators have access to radiopharmaceuticals in the second category of receptor binding. In particular, these are the dopamine receptors 3-*N*-[carbon-11]-methyl spiperone, fluorine-18 spiroperidol and haloperidol and the opiate receptor, carbon-11 carfentanil. For example, serial measurements of the latter agent in patients before and after administration of the competitive opiate antagonist, naloxone, can differentiate specific opiate receptor binding from non-specific binding.³

Radiopharmaceuticals used in single-photon emission computed tomography

There is no question that the impetus provided by the success of PET users has stimulated research on more practical gamma-emitting radiopharmaceuticals that cross the intact blood-brain barrier and localize in normal brain tissue, lesions then being identified by photon-deficient areas in the brain image or changes in the pattern of normal distribution.

Following the distinction between agents depending on cerebral blood flow and those relying on receptor binding, the former includes the large group of the iodoamphetamines, the cyclic amines and cyclic diaminodithiol. Among the receptor

binders there is however to date only a muscarinic acetylcholine receptor.⁴

Amines are important chemical mediators of brain function and affect transport of brain metabolites, rates of synthesis and metabolism. A number of labelled amines that cross the normal blood-brain barrier and remain fixed to the brain for sufficient time to permit tomographic imaging have been synthesized in the last few years.

Radiolabelled di-beta-(morpholinoethyl)-selenide (MOSE) and di-beta-(piperidinoethyl) selenide (PIPSE) were early examples of compounds that are neutral and lipid-soluble at normal blood pH and so diffuse into cells.

Winchel *et al.* demonstrated that a large number of amines pass the blood-brain barrier, resulting in high brain concentration after intravenous injection.⁵ As with PIPSE and MOSE, the penetration of the blood-brain barrier is due to the free diffusion of the unionized form of the compound. The most promising of these has been *n*-isopropyl-*p*-iodoamphetamine labelled with iodine-123 (IMP) which is extracted from brain *proportional to blood flow*. There are three possible mechanisms for localization: pH gradient, metabolism into an impermeable metabolite and receptor binding, but it is not yet certain which, if any, are appropriate.

One disadvantage of IMP is that its uptake from sites such as the lung may recirculate and redistribute in the brain, altering the image resolution and accuracy of lesion detection in the brain.⁴ As a result, coupled with what nowadays always seems to be the ultimate in synthesizing a new radiopharmaceutical, i.e. to find a technetium-99m-based compound, the search has been on to find a more appropriate agent.

Technetium-99m hexamethylpropylamine oxime (HM-PAO), has subsequently been developed in this country by Amersham International. It differs from iodine-123 IMP in that the latter requires living brain cells in order to be extracted from the blood, whereas technetium-99m HM-PAO is not brain-cell specific. It is, for instance, being used to detect tumours elsewhere in the body.³ There may well be a role for both agents because, although they are both dependent on brain blood flow, iodine-123 IMP also reflects the status of brain cells.

The exciting prospect for the future is that experience with technetium-99m cerebral blood flow agents indicates that it might be possible to image so-called 'recognition-site ligands' if the appropriate tracers can be designed. Iodine-123 remains too expensive to permit the high doses necessary for adequate resolution and which are accessible with

technetium-99m. The lead in this respect has so far been taken by PET, which has been successful in the study of the dopamine receptor system. However, even now iodine-123-labelled meta-iodoguanidine has become available for imaging the autonomic nervous system, as well as iodine-123 methyl-iodo-lysergic acid diethylamide (LSD) for serotonin receptors; iodine-123 paraiododexetimide for muscarinic cholinergic receptors and iodine-123 ligands for alpha and beta adrenergic receptors. Iodine-123 iodospiroperiodol may even equal the ability of the PET agents in imaging dopamine-receptors.³

Positron-emission tomographic studies of normal brain⁶

As implied above, the fluorine-18 deoxyglucose scintigram may be used to study the normal brain at 'rest' and during sensory, motor or cognitive stimuli. For example, after stimulation of the visual system, the metabolic response in the primary and secondary visual cortex has been found to be directly proportional to the complexity of the stimulus.⁷ Auditory stimulation resulted in metabolic patterns which correlated with content and strategy required to perform the auditory perception test.⁸ Verbal stimuli activated left frontal and temporal occipital regions, with non-verbal stimuli activating the opposite hemisphere.⁶ Mean cerebral glucose utilization declines by about 26% over the age span from 18 to 78 years and is probably the true counterpart of the old tale that we all lose about 10,000 neurones per day from the day of our birth!⁹ This age-dependent fall-off is apparently more rapid in the frontal region. An interesting recent finding is that the cortical areas of a child's brain have twice the degree of glucose utilization of adults. From the ages of four to eight, a child has an excessive number of synaptic connections and it would appear that environmental influences direct the brain to select which synapses to retain and which to reject, the latter beginning to disappear from the age of ten or so.

There is a significant decrease in carbon-11 carfentanil binding to opiate receptors in the thalamus of sexually aroused persons, probably as a result of the secretion of endogenous opiates.¹⁰ There is also a slight increase in the dopamine-receptor number during the second half of the menstrual cycle. The two forms of the distribution enzyme monoamine oxidase, designated A and B, have been imaged using carbon-11 deprenyl and carbon-11 clorgyline respectively.

Single-photon computed-emission tomography of normal brain²

SPECT studies of normal brain with iodine-123 IMP or technetium-99m HM-PAO demonstrate bilaterally symmetrical activity. Activity is greatest in a strip along the cortical convexities, corresponding to the grey matter, and is also high in the basal ganglia. The regions between the basal ganglia and that corresponding to cortical white matter show rather less activity. Activities in the temporal, parietal and occipital cortical regions are fairly uniform, but that in the frontal region is patchy. Depressions in activity due to the inter-hemispheric and Sylvian fissures and the ventricular system are also visible. Activity in the visual centre is again dependent on the degree of stimulation and auditory-centre activity is also in evidence (Figure 7).²

Clinical studies with positron-emission tomography⁶

Stroke

At the infarct site local glucose utilization is less depressed than blood flow, probably due to local anaerobic glycolysis and it is not until many weeks after the initial event that reduction in flow occurs. At this stage metabolic depression greater than 50% coincides with regions of low attenuation on computed tomography.

However, in areas distant from the infarct which appear normal on computed tomography there are often areas of glucose hypometabolism, e.g. in the cerebral and cerebellar hemispheres contra-lateral to supratentorial infarcts. Therefore, estimating the extent of the stroke by computed tomography is often misleading and only the FDG scintigram is able to define the true functional impairment.

Depression

Kuhl *et al.* have shown that FDG uptake patterns and the global cerebral metabolic rate in depressed patients were normal.¹¹ However, some well-known images of the brain during the mood fluctuations of a rapid-cycling manic-depressive affective disorder, obtained by Baxter *et al.*, have been reproduced in many articles.¹² The image shows decreased count rate during two depressive phases and increased rates during a manic phase. As a rainbow-type colour system has been used to provide artificial colour for the images, the depressive images, not unexpectedly, appear blue!

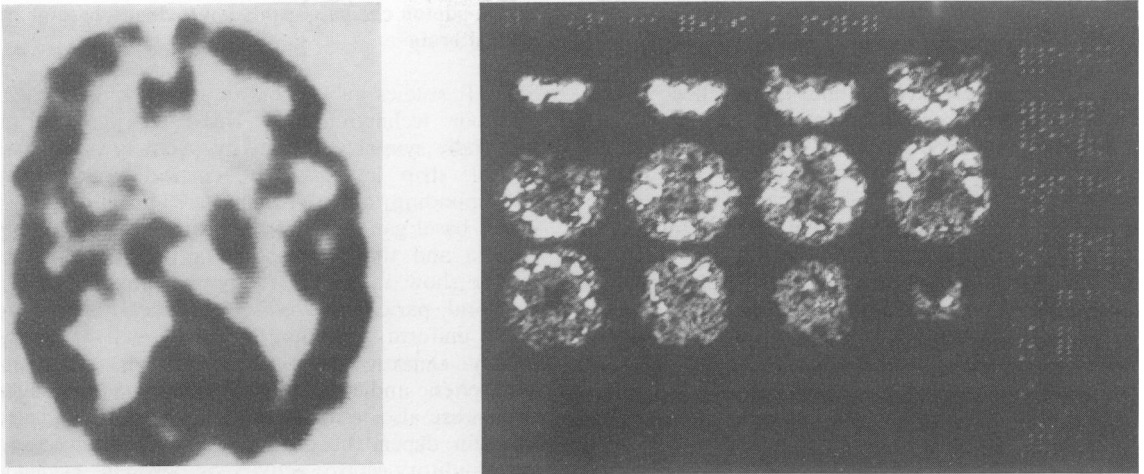


Figure 7 Left: a normal single-photon emission tomographic cross-section using iodine-123 iodo-amphetamine. Activity is present mainly in the cortex and in the visual centre. Right: a series of normal cerebral sections using technetium-99m HM-PAO.

Dementias

FDG studies in elderly demented patients have been very exciting indeed. Patients with multi-infarct dementia often have evidence of small, old infarcts on computed tomography, but the FDG scintigram is much more sensitive. In Alzheimer's disease the abnormal metabolic patterns reflect neuronal degeneration that is most severe in the associated cortex, with marked hypometabolism in the parietal and dorsolateral occipital cortex giving a characteristic banana-shaped photon-deficient area around the photon-dense visual cortex. Uptake is less depressed in the frontal, temporal and calcarine occipital parts of the cortex and least in the caudate nucleus and the thalamus.

Basal ganglia disorders

The caudate nucleus and the thalamus can both be visualized by positron-emission tomography. However, in Parkinson's disease relative glucose distribution appears normal, but global cerebral utilization is reduced. By contrast, markedly depressed glucose utilization in the caudate and putamen has been observed in patients with Huntington's disease, regardless of the duration of the disease and the presence or absence of caudate-nucleus atrophy on computed tomography. There was also some evidence that striatal glucose utilization was reduced in asymptomatic carriers of the autosomal dominant genes for this condition. In Wilson's disease, the putamen appears relatively

hypometabolic compared with the caudate nucleus.

As indicated in the pharmaceutical section, however, great strides have been made in the development of labelled recognition-site ligands. For example, it has been found in experimental animals that there is a linear relationship between the accumulation of fluorine-18 L-DOPA in the caudate nucleus and the concentration of dopamine.

Epilepsy

There seems to be little doubt that interictal FDG scintigrams demonstrate hypometabolic areas considered very likely to be responsible for seizures in patients with partial epilepsy, even though these zones appear normal on computed tomography and often do not agree with the electro-encephalographic findings, although the latter may be useful in confirming whether a hypometabolic area is indeed epileptogenic.¹³ The converse may be useful in deciding whether an EEG focus is a primary epileptogenic zone or propagation at a distance from the primary. This may be useful in pre-surgical evaluation of such foci. It has also been noted that there is a relative decrease in the number of opiate receptors in these hypometabolic cases. During a seizure, there appears to be an increase in glucose metabolism in the affected zone. No focal abnormalities are found at any stage with petit mal, only a diffuse increase in cerebral glucose metabolism at the time of the seizure.

Schizophrenia

Wong *et al.* have demonstrated a striking decrease in D2 dopamine-receptor density in the caudate nucleus in schizophrenic patients.¹⁴ If this is confirmed it will be the first clear demonstration of neuroreceptor abnormality in a psychiatric condition. As far as FDG studies are concerned, there would appear to be reduced uptake in the temporal cortex, putamen and other regions of the brain. On the other hand, on treatment with neuroleptic drugs, these patients show increases in glucose metabolism in these zones. Blockade of dopamine receptors by these drugs would appear to unleash other types of neuronal activity. When schizophrenic patients are given amphetamine, which considerably exacerbates symptoms, there is a greater reduction in regional glucose metabolism than in normal controls.

Cerebral tumours

A variety of positron-emitting tracers are being used to determine the metabolic status and the extent of tumours. For example, after surgery or radiotherapy, carbon-11 methionine before and after phenylalanine blockade can delineate the extent of the tumour and differentiate this from radiation necrosis, as uptake in the tumour itself will be reduced to lower levels after blockade. Others have used the radiopharmaceutical to assess the adequacy of brain-tumour surgery. Fluorine-18 1-doxy-2-fluoro-L-fucose can be used to assess glycoproline metabolism in experimental gliomas. In many centres the PET image alone is used to distinguish between high- and low-grade brain tumours.³

Clinical studies with single-photon emission-computed tomography²

As has been described, the two most popular agents that have been used for single-photon emission computed tomography are iodine-123 iodoamphetamine (IMP) and technetium-99m hexamethylpropyleneamine oxine (HM-PAO). IMP requires living brain cells in order to be extracted from the blood. HM-PAO is not brain cell-specific and is a measure of blood flow.

The core of nuclear medicine in the near future undoubtedly lies in positron-emission tomography. However, the vast amount of pioneering work with this modality has been translated with great effect into single-photon emission-computed tomography. As a result, many of the clinical appearances

described above using positron emitters can be simulated with IMP and HM-PAO.

Stroke

In stroke patients the abnormality is immediate, unlike the defect on computed transmission computed tomography which does not appear until 3-4 days after the onset of the event (Figure 8). Even when transmission images are positive, the perfusion defects are often larger and in the sections involving the visual field, disruptions in the field may be observed. Recent studies by Yeh and his colleagues have convincingly demonstrated that HM-PAO studies are far more sensitive than transmission computed tomography in patients with stroke.¹⁵ In transient ischaemic attacks without focal neurological signs, both transmission and emission studies tend to be normal.

Epilepsy

Once again, in the majority of patients with partial epilepsy both regional blood flow and metabolism are increased within the epileptic focus during the actual episode. Between seizures reduced uptake is noted in the focal areas and these, in turn, do not always correspond to electroencephalographic or computed tomographic evidence (Figure 9).

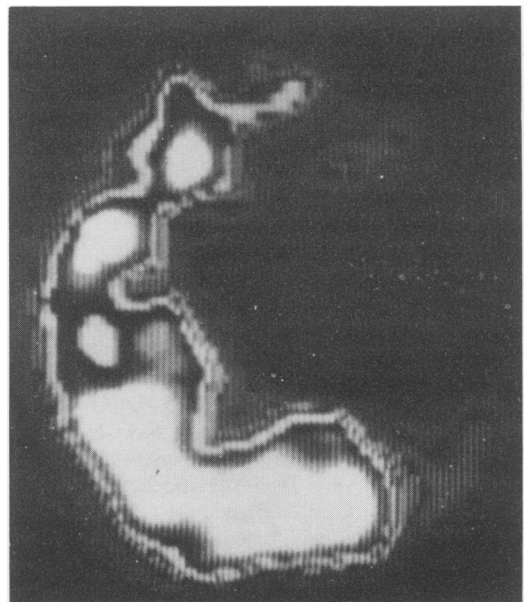


Figure 8 SPECT image using technetium-99m HM-PAO of a section through the brain of an elderly man with a middle cerebral artery infarction.

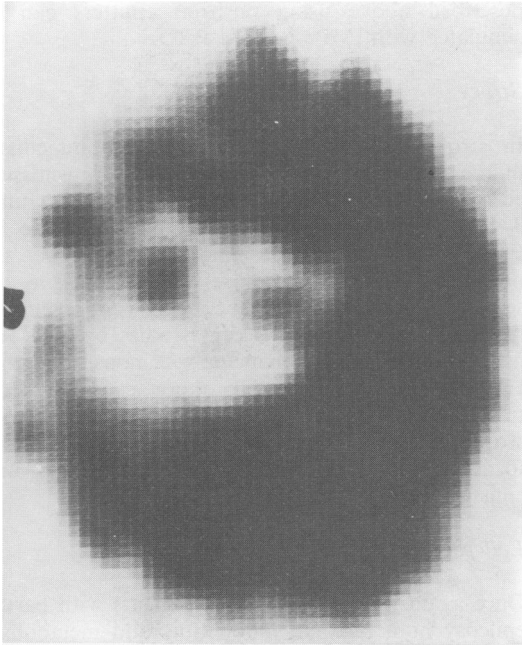


Figure 9 SPECT image using technetium-99m HM-PAO of a section through the brain of an 8 year old girl with partial seizure disorder, showing a photon-deficient area in the right frontal area.

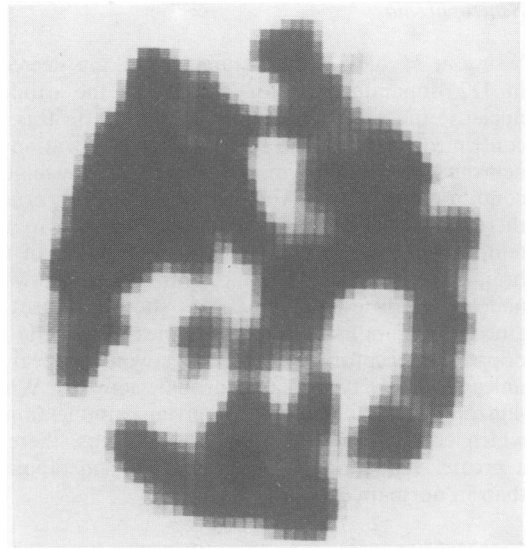


Figure 10 SPECT image using technetium-99m HM-PAO of a cerebral section from an elderly woman with multi-infarct dementia.

Psychiatric disorders

HM-PAO and IMP images show the characteristic distribution of blood-flow abnormalities seen in multi-infarct dementia (Figure 10), Pick's disease (Figure 11), Alzheimer's disease (Figure 12) and the diminution of blood flow to the basal ganglia seen in Huntingdon's disease. Figure 13 shows a case of schizophrenia before and after remission whilst being maintained on the same drugs. The frontal hypoperfusion/hypometabolic defect is very striking.

Receptor imaging

Recognition sites are characterized by being present in very low numbers and so have very low capacity for the radioactive ligand. Consequently the iodine-123 must have very high specific activity. Iodine-123 of this kind labelled to lysergic acid diethylamide has been used to identify serotonin receptors and more recently, iodine-123 methyl-iodolysergic acid diethylamide has been developed. Iodine-123 iodospiroperidol has been designed for the study of dopamine receptors. Also, Kung has reported on iodine-123 SKF-103108a, a radiotracer

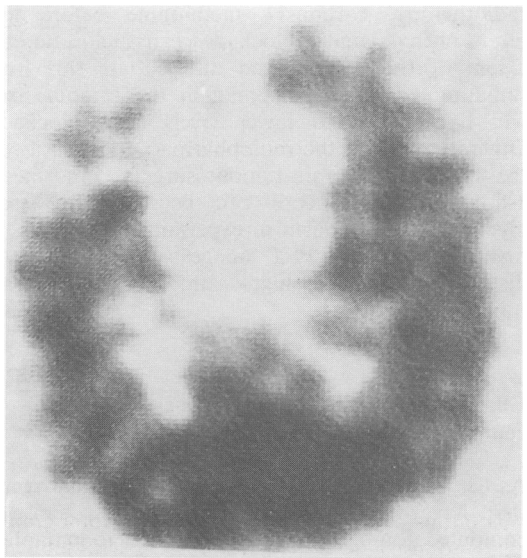


Figure 11 Cerebral SPECT image using technetium-99m HM-PAO, showing a large, central photon-deficient area in the frontal zone, now considered to be compatible with Pick's disease. The patient was an elderly man.

designed for imaging the so-called D1 dopamine receptors.¹⁶

Ideally, of course, one would aim to have technetium-99m labelled receptors. Goldfarb *et al.* have described a multipurpose technetium-99m

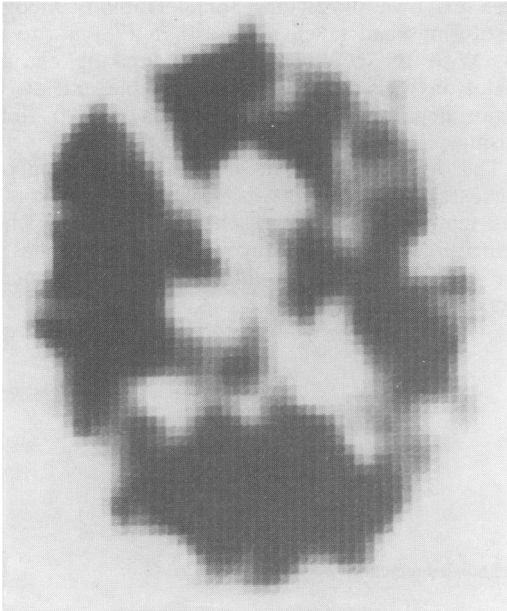


Figure 12 An elderly woman with dementia of the Alzheimer type produced this SPECT cross-section with technetium-99m HM-PAO. The banana-shaped posterior defect is now becoming a well-recognized feature in this condition.

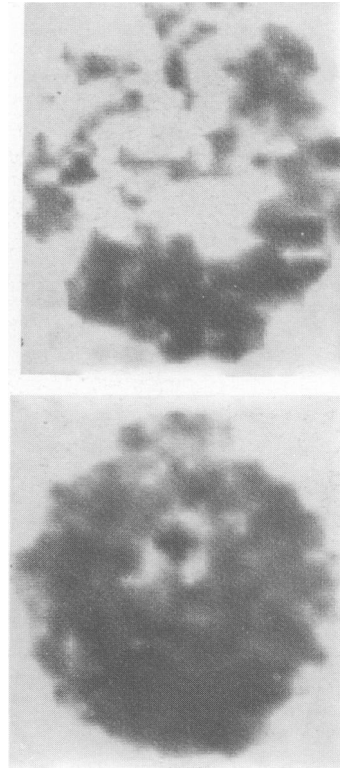


Figure 13 SPECT images from a schizophrenic middle-aged woman after an injection of technetium-99m HM-PAO. The scintigram at the top was acquired while she was severely disabled by classical schizophrenic symptoms such as auditory and visual hallucinations and shows very poor frontal-zone uptake (the 'hypofrontality' of schizophrenia). The scintigram below shows her in remission, when the equivalent section is indistinguishable from normal. Her medication had not changed.

chelate known as *N*-piperidinyldiaminodithiol (NEPDADT) which crosses the blood-brain barrier,¹⁷ but the possibility of labelling glucose with technetium-99m has not yet arrived. However, Goodman *et al.* have developed an iodine-123 2-deoxy-2-iodovinyl altrose derivative, which is close!¹⁸

Conclusions

Assuming that there is no access for most centres in the UK to positron-emission tomographic facilities, what are the major indications for the more ubiquitous single-photon emission tomographic imaging used IMP or HM-PAO? The following seem the most likely clinical indications: (1) The diagnosis of acute cerebral infarction, where the transmission computed tomographic images may be normal for several days after the event and where, in any case, the physiological abnormality may exceed the morphological abnormality. (2) To diagnose and differentiate the dementias. The multi-infarct and Alzheimer defects are now familiar. (3) In patients with epilepsy where the extent and location of the hypoperfused/hypometabolic area may be important to management. (4) Before and

after carotid endarterectomy to assess the effectiveness of surgery. (5) In patients where neither clinical examination nor transmission computed tomography provide an answer. (6) As one of the criteria for determining brain death (Figure 14).

When Professor Henry N. Wagner, Jr. closed the Society of Nuclear Medicines' Annual Meeting in 1985 he stated that 'PET is it'. In 1986 he said that 'SPECT is also it' and advocated that all nuclear medicine departments should aim for routine SPECT technology.³ Nevertheless, in the Annual Lecture at the British Nuclear Medicine Society this year, he recommended that in spite of the large economic outlay, all nuclear medicine departments should try and obtain PET systems, saying that

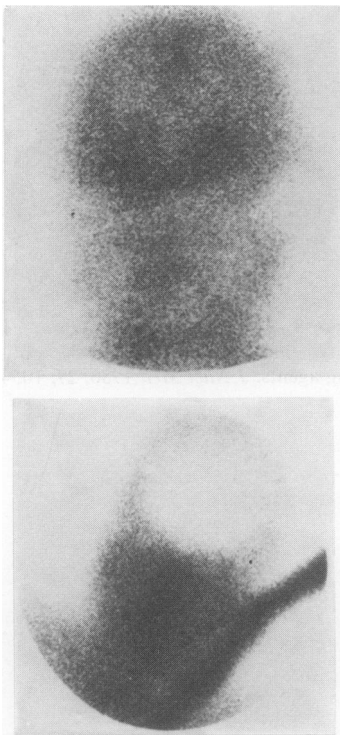


Figure 14 The use of technetium-99m HM-PAO in the diagnosis of cerebral death (top). The image below shows the normal equivalent planar image for comparison. The brain-death appearances using technetium-99m HM-PAO must not be confused with the normal planar images using technetium-99m as pertechnetate!

even his own prestigious Johns Hopkins Medical Institutions had taken no less than 17 years to do so. With the commercial sector making cheaper cyclotrons this is now not impossible and so all major departments are urged to start their fund-raising.

The description above of workers mapping out the extent of tumours with carbon-11 methionine has reminded Wagner of the time in 1951 when neurosurgeons at the Mayo Clinic used probes in the theatre to locate brain tumours. The phoenix has certainly risen again!

Acknowledgements

I would like to thank Mr Nigel Soper, Principal Physicist in the Regional Department of Radiation Physics, and Miss Anne Gerrity, Senior Radiographer, John Radcliffe Hospital, Oxford, for producing all the SPECT images illustrated, and all the consultants who have referred cases for study. Dr Ruth English and Miss Pel Fursdon have been of great help in correlating the program. I thank Mr Stan Ashington for his expert photography and as always, my gratitude to my secretary, Mrs Betty Harvey, for typing the manuscript. Above all, I am indebted to Dr Louis Kreeel, until his recent retirement Director of Radiology, Newham General Hospital, Plaistow, for suggesting I write up this fascinating topic.

References

1. Kuhl, D.E. & Edwards, R.O. Image separation radioisotope scanning. *Radiology* 1963, **80**: 653-661.
2. Holman, B.L., Hill, T.C. & Magistretti, P.L. Brain imaging with emission computed tomography and radiolabelled amines. *Invest Radiol* 1982, **17**: 206-215.
3. Wagner, H.J. Jr. SPECT and PET advances herald new era in human biochemistry. *J Nucl Med* 1986, **27**: 1227-1283.
4. Holmes, R.A. A reawakening of interest in radionuclide brain imaging. Editorial. *J Nucl Med* 1986, **27**: 299-301.
5. Winchell, H.S., Baldwin, R.M. & Lin, T.H. Development of I-123-labelled amines for brain studies: localization of I-123 iodophenylalkyl amines in rat brain. *J Nucl Med* 1980, **21**: 940-946.
6. Kuhl, D.E. Imaging local brain function with emission computed tomography. *Radiology* 1984, **150**: 625-631.
7. Phelps, M.E., Kuhl, D.E. & Mazziotta, J.C. Metabolic mapping of the brain's response in visual stimulation: studies in humans. *Science* 1981, **211**: 1445-1448.
8. Mazziotta, J.C., Phelps, M.E., Carson, R.E. & Kuhl, D.E. Tomographic mapping of human cerebral metabolism: auditory stimulation. *Neurology* 1982, **32**: 921-937.
9. Kuhl, D.E., Metter, E.J., Riege, W.M. & Phelps, M.E. Effects of human aging on patterns of local cerebral glucose metabolism determined by the (F-18) fluorodeoxy glucose method. *J Cereb Blood Flow Metab* 1982, **2**: 163-171.
10. Frost, J.J., Mayberg, H.S., Berlini, F. *et al.* Alteration in brain opiate receptor binding in man following sexual arousal using C-11 carfentanil and positron emission tomography. *J Nucl Med* 1986, **27**: 1027.

11. Kuhl, D.E., Metter, E.J., Riege, W.H. *et al.* Local cerebral glucose utilization in elderly patients with depression, multiple infarct dementia and Alzheimer's disease. *J Cereb Blood Flow Metab* 1983, **3** (Suppl. 1): 5494-5495.
12. Baxter, L.R., Phelps, M.E., Mazziotta, J.C. *et al.* Cerebral metabolic rates for glucose in mood disorders studied with positron emission tomography (PET) and (F-18)-fluoro-2-deoxyglucose (FDG). *Arch Gen Psychiatry* 1985, **42**: 441-447.
13. Kuhl, D.E., Engl, J. Jr., Phelps, M.E. & Selin, C. Epileptic patterns of local cerebral metabolism and perfusion in humans determined by emission computed tomography of ^{18}F FDG and ^{13}N H₃. *Ann Neurol* 1980, **8**: 348-360.
14. Wong, D.F., Gjedde, A., Wagner, H.N. Jr *et al.* *In vivo* quantification of absolute D2 dopamine receptor density using positron emission tomography: Preliminary human studies. *J Nucl Med* 1986, **27**: 954-955.
15. Yeh, S.H., Liu, R.S., Hu, H.H. *et al.* Brain SPECT imaging with Tc-99m-Hm-PAO in the early detection of cerebral infarction: Comparison with transmission computed tomography. *J Nucl Med* 1986, **27**: 888.
16. Kung, H.F., Billings, J.B. & Guo, Y-Z. *In vivo* biodistribution of SKF-103108A: a potential D1 receptor-site specific imaging agent. *J Nucl Med* 1986, **27**: 906.
17. Goldfarb, H.W., Scheffel, U., Lever, S.Z., Burns, H.D. & Wagner, H.N. Jr. Comparison of Tc-99m aminoethyl diaminodithiol analogs from brain blood flow imaging. *J Nucl Med* 1986, **27**: 1050.
18. Goodman, M.M., Knapp, F.F. Jr & Callahan, A.P. Synthesis and evaluation of radioiodinated 2-deoxy-2-iodovinyl altrose derivatives as potential brain imaging agents. *J Nucl Med* 1986, **27**: 1054.